

Histopathological lesions caused by experimental *Toxocara canis* and *Toxascaris leonina* infections in farm mink (*Neovison vison*)

Maciej Klockiewicz¹, Małgorzata Sobczak-Filipiak², Tadeusz Jakubowski³, Ewa Długosz¹

¹Division of Parasitology and Invasiology, Department of Pre-Clinical Sciences, Faculty of Veterinary Medicine, Warsaw University of Life Sciences, 02-786 Warsaw, Poland

²Division of Pathology in Exotic, Laboratory, Non-domesticated Animals and Fish, Department of Pathology and Veterinary Diagnostics, Faculty of Veterinary Medicine, Warsaw University of Life Sciences, 02-786 Warsaw, Poland

³Department of Large Animals Diseases with Clinic, Faculty of Veterinary Medicine, Warsaw University of Life Sciences, 02-797 Warsaw, Poland
maciej_klockiewicz@sggw.pl

Received: October 12, 2018 Accepted: April 29, 2019

Abstract

Introduction: Canine roundworm *T. canis* and *T. leonina* infections were investigated in experimentally infected farm mink (*Neovison vison*) to describe the pattern of pathological lesions in this paratenic host. **Material and Methods:** Infections in mink developed following ingestion of embryonated eggs of either parasite or mice tissue infected with both parasite species. **Results:** Comparative analysis of haematoxylin- and eosin-stained slides showed essential differences among the experimental groups. The lesions observed included eosinophil and mononuclear inflammatory infiltrates of the intestinal wall and local lymph nodes, inflammation and haemorrhages in liver tissues, and interstitial inflammation and mineralisation of the kidneys and lungs. Larvae migrating through the minks' bodies also caused particularly salient enlargement of lymphoid follicles in the spleen and inflammatory infiltrates of mononuclear cells in skeletal and heart muscles. **Conclusions:** It is assumed that histopathological lesions appeared as a local and general host response to invasive L3 *T. canis* and *T. leonina* larvae migrating through the tissues of infected farm mink. Interestingly, mink infected with embryonated eggs had more pronounced lesions than animals infected with tissue larvae. Detailed histopathological examinations of parenchymal organs and striated muscles revealed lesions resembling those observed in other paratenic host species due to toxocarosis.

Keywords: farm mink (*Neovison vison*), *Toxocara canis*, *Toxascaris leonina*, histopathological lesions, toxocarosis.

Introduction

As the mink industry has grown intensively for the last three decades in Poland, more focus has come onto all possible factors that might be intrinsic to husbandry conditions. The breeding of mink (*Neovison vison*) provides many profits. As well as generating direct income out of the sale of furs, mink rearing contributes positively in reduction of animal origin by-product waste (used as a source of feed for mink) and natural fertilisation of soil (with mink manure).

As was discussed in our previous paper, it was presumed that farm mink would have theoretically been

involved in the epidemiology of the canine parasites *T. canis* and *T. leonina* via small free-living rodents which are always near to and on mink farms. However, that uncertainty has been elaborately investigated and experimentally resolved. It was confirmed that farm mink are not the definitive host, but they may be a paratenic host to these zoonotic nematodes. Additionally, it helped to conclude that farm mink were not involved in the epidemiology of human toxocarosis (12).

Many studies were performed to investigate the course of *T. canis* infection in different paratenic host species such as mice, rats, gerbils, hamsters, pigs,

poultry, pigeons, and others (19). The patterns of canine and feline roundworm infections observed in various paratenic hosts are used in comparative studies concerning human toxocarosis, which is recognised as a serious public health concern (17).

It is commonly assumed that *T. canis* and *T. leonina* are the causative agents of inflammatory reactions in many paratenic host species. Toxocarosis develops due to migration of infectious L3 larvae through the tissue of parenchymal organs and striated muscles of an infected host. It therefore results in a wide range of clinical manifestations and pathological lesions exemplified in humans as ocular larva migrans (OLM) and visceral larva migrans (VLM) syndromes (13). Furthermore several paratenic host species that are involved in the transmission of toxocarosis (e.g. mice, rats) provide the risk of infection for the definitive host (dog) and/or other paratenic hosts including humans.

It looks quite likely that farm mink could be exposed to canine roundworm infections for example *via* infected small rodents that might contaminate fresh feed. As *T. canis* and/or *T. leonina* infections had never been studied in farm mink, there was a lack of scientific reports concerning lesions that could have developed as a result of these infections. It was presumed that farm mink as a paratenic host should develop a range of lesions like some described in a number of different paratenic hosts including humans. Therefore the aim of the study was to recognise the problem in farm mink and describe the histopathological lesions due to toxocarosis in this paratenic host. The lesions could then be used in differential diagnosis of mink and/or as a set of data useful in comparative studies on toxocarosis.

Material and Methods

Animals. A total of 50 randomly chosen farm mink were taken from a breeding farm and kept in special wire cage facilities for mink on the Obory farm of Warsaw University of Life Sciences. The mink were subdivided into four equal experimental and one control group. Each group consisted of equal numbers (5/5) of females and males. The mink were fed commercial feed and could take water *ad libitum*. BALB/c mice were used to obtain the paratenic hosts tissue infected with somatic larvae of both investigated roundworm species. The study was accepted by and conducted in accordance with the guidelines of the 3rd Local Ethical Committee for Experiments on Animals.

Infection. Two groups of mink as well as two groups of mice were infected with embryonated *Toxocara canis* or *Toxascaris leonina* eggs. After three weeks of incubation at room temperature according to a protocol by Oakes and Kayes (14), larvated eggs were used to infect mink directly and/or indirectly through the mice as a paratenic host. The infective dose was approximately 500 eggs of each parasite species. First,

mice were inoculated orally by pipette. Subsequently, a month later tissue of infected mice was homogenised and used to infect mink. Mink received their infective doses by ingesting round pellets of meat containing larvated eggs or homogenised mouse tissue (12).

Post mortem examination. According to the schedule all experimental and control mink underwent autopsies at 16 weeks post infection. During autopsy, samples of the small intestines, intestinal (mesenteric) lymph nodes, liver, spleen, kidneys, lungs, and striated and skeletal muscles were taken for histopathological examination.

Histopathological examinations. Tissue samples were routinely fixed in 10% neutral buffered formalin, embedded in paraffin (Paraplast, Sigma-Aldrich), and subsequently cut on a rotatory microtome. Preparations of 4 µm thickness were automatically stained with haematoxylin and eosin (HE, Varistain Gemini Thermo Scientific, U.K.).

The microscopic analysis of HE slides was carried out with a BX43 light microscope equipped with an SC30 digital camera (Olympus Optical, Japan). Pictures were analysed and recorded by computer software (CellSens Entry 2011, Olympus Lifescience). In compliance with good laboratory practice 10 randomly chosen slides of every organ from all experimental and control groups were analysed.

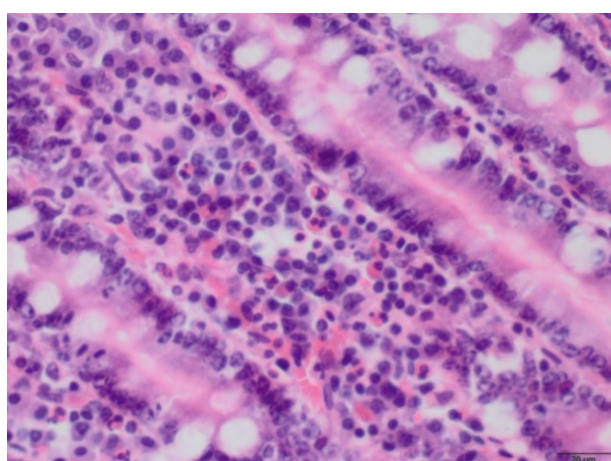
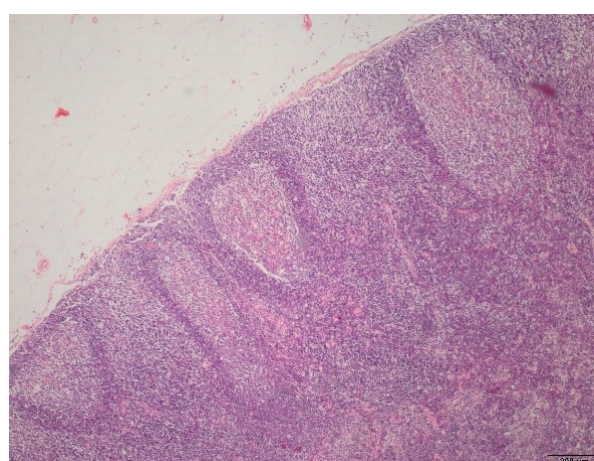
Results

Lesions found in HE slides of different organs are assorted, enumerated elaborately, and summarised in Tables 1 to 5 according to the presumed natural order of *T. canis* and *T. leonina* larvae movement through the organism of infected mink. Characteristic lesions found in particular tissues are also shown in figures of HE slides.

1. Intestines and mesentery lymph nodes. The pattern of lesions noted at this stage reflected the situation from several weeks after the beginning of the infection, when *T. canis* and *T. leonina* larvae previously hatched from eggs or released from tissues (in the stomach and small intestine) penetrated through the gut wall. It was clearly seen that migrated larvae provoked a stronger reaction of local immune cells in experimental groups than in control mink. The inflammatory infiltrate in experimental mink was slightly more massive and complex. The presence of eosinophils in all infected mink reflected the immune reaction against parasites. The slightly less intense inflammatory reaction in mesenteric lymph nodes of infected mink also confirmed possible contact with penetrating canine roundworm larvae. Secondary lymphoid nodules with germinal centres, eosinophils and macrophages noted in infected mink might be due to prolonged contact with parasite antigens.

Table 1. Histopathological (HP) lesions of intestines and mesentery lymph nodes in experimental groups compared to the control group

Group/HP lesions	Group 1 <i>Toxocara canis</i> – eggs	Group 2 <i>Toxocara canis</i> – larvae	Group 3 <i>Toxascaris leonina</i> – eggs	Group 4 <i>Toxascaris leonina</i> – larvae	Control
Intestines	Inflammatory infiltrate – 5 mink	Inflammatory infiltrate – 5 mink; (massive inflammation – 1 mink)	Inflammatory infiltrate – 5 mink	Inflammatory infiltrate – 5 mink	Inflammatory infiltrate – 4 mink (single mononuclear cells)
	Eosinophils in the intestinal mucosa – 5 mink	Eosinophils in the intestinal mucosa – mink (numerous in 1 mink)	Eosinophils in the intestinal mucosa	Eosinophils in the intestinal mucosa – 5 mink (numerous in 2 mink)	Not found
	Not found	Hypertrophy of lymphoid nodules – 1 mink	Not found	Not found	Not found
	Not found	Not found	Hyperaemia – 1 mink	Not found	Not found
Mesentery lymph nodes	Hypertrophy of lymphatic / lymphoid nodules – 5 mink	Hypertrophy of lymphatic / lymphoid nodules – 3 mink	Hypertrophy of lymphatic / lymphoid nodules – 5 mink	Hypertrophy of lymphatic / lymphoid nodules – 5 mink	Hypertrophy of lymphatic / lymphoid nodules – 4 mink
	Secondary lymphatic nodules with germinal centres – 1 mink	Not found	Not found	Secondary lymphatic nodules with germinal centres – 1 mink	Not found
	Eosinophils – 2 mink	Not found	Eosinophils – 3 mink	Eosinophils – 3 mink	Not found
	Macrophages in the sinus (marginal or intermediate, or medullary) – 3 mink	Macrophages in the sinus (marginal or intermediate, or medullary) – 3 mink (numerous – 1 mink)	Not found	Macrophages in the sinus (marginal or intermediate, or medullary) – 5 mink	Not found
	Not found	Not found	Hyperaemia – 1 mink	Not found	Hyperaemia – 1 mink

**Fig. 1a.** Inflammatory infiltrate with numerous eosinophils in the mucous membrane of small intestines – group 1 (mink infected with *T. canis* eggs)**Fig. 1b.** Secondary lymphatic nodules with germinal centres in the mesentery lymph node – group 4 (mink infected with *T. leonina* tissue larvae)

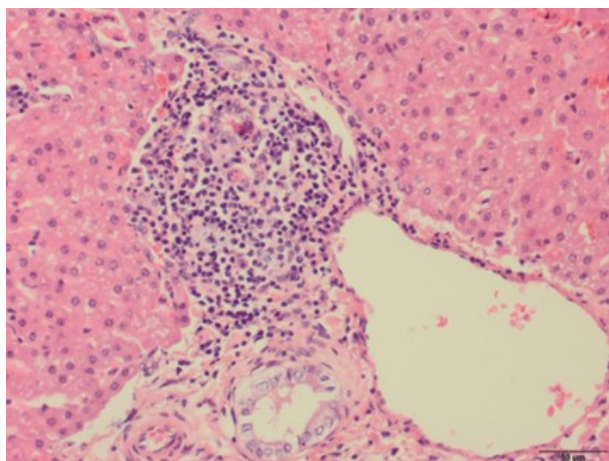


Fig. 2. Inflammatory infiltrate around the portal triad, fatty degeneration of hepatocytes – group 2 (mink infected with *Toxocara canis* larvae)

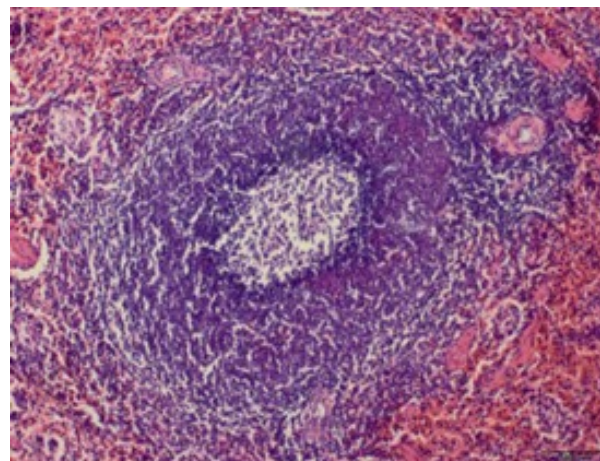


Fig. 3. Secondary follicle with germinal centre in the spleen, hyperaemia of the red matrix – group 4 (mink infected with *Toxascaris leonina* larvae)

2. Liver. It can be assumed that after gut wall penetration larvae are transferred by the circulatory system to the liver and other parenchymal organs. HP lesions at this stage displayed the status of the immune cell reaction towards penetrating larvae. The necrosis of hepatocytes and the inflammatory infiltrate composed of various cells reflected a post factum reaction to larvae destroyed by the immune system. The granuloma probably developed upon the death of larvae. The fibrosis (as a later stage) was probably the result of the reparative process of the damaged parenchymal tissue due to migrating larvae. The fatty degeneration and hyperaemia and/or congestion were likely to have been caused by another factor or other

factors not related to the parasitic infection as those were present both in experimental and in control mink.

3. Spleen. Secondary follicles with germinal centres are the main lesions that exhibited influence of roundworm larvae in the spleen of infected mink. Those were not present in control mink. Similarly, hypertrophy of lymphoid follicles was likely to partially reflect infected status, nevertheless this was also found in control mink, but definitely less strongly expressed in this group than in experimental groups. In turn, the hyperaemia and haematopoiesis found in both infected and control mink looked not to be related to the infection.

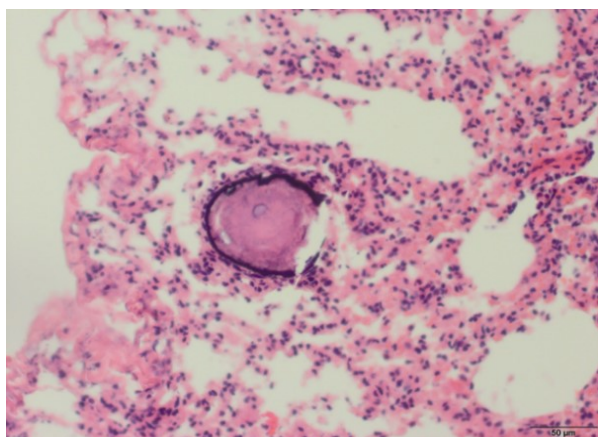
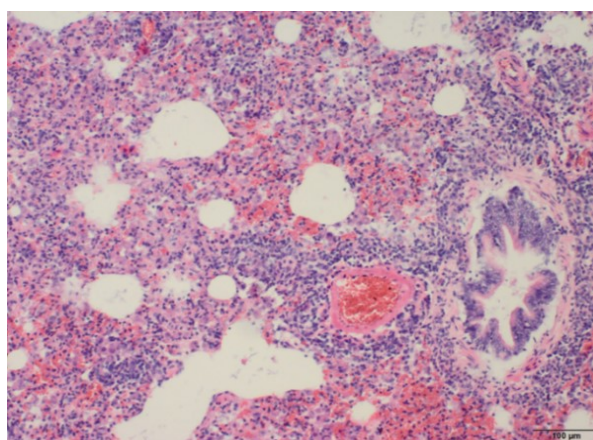
Table 2. Histopathological lesions of the liver in experimental groups compared to the control group

Group/HP lesions	Group 1 <i>Toxocara canis</i> – eggs	Group 2 <i>Toxocara canis</i> – larvae	Group 3 <i>Toxascaris leonina</i> – eggs	Group 4 <i>Toxascaris leonina</i> – larvae	Control
Liver	Fatty degeneration – 4 mink	Fatty degeneration – 4 mink	Fatty degeneration – 4 mink	Fatty degeneration – 3 mink	Fatty degeneration – 5 mink
	Necrosis of hepatocytes – 2 mink	Necrosis of hepatocytes – 2 mink	Necrosis of hepatocytes – 2 mink	Not found	Not found
	Hyperaemia / congestion – 1 mink	Hyperaemia / congestion – 1 mink	Hyperaemia / congestion – 3 mink	Hyperaemia / congestion – 1 mink	Hyperaemia / congestion – 5 mink
	Inflammatory infiltrate of mononuclear cells – 5 mink / around portal triads – 3 mink; numerous inflammatory cells – 1 mink	Inflammatory infiltrate of lymphocytes, plasma cells, and macrophages – 4 mink / around portal triads – 2 mink; numerous inflammatory cells – 1 mink	Inflammatory infiltrate of lymphocytes and plasma cells – 4 mink / around portal triads; also in the liver parenchyma – 3 mink	Inflammatory infiltrate of mononuclear cells – 5 mink / around portal triads – 2 mink; numerous inflammatory cells – 1 mink	Not found
	Fibrosis – 1 mink	Not found	Not found	Not found	Not found
	Not found	Not found	Not found	Granuloma – 1 mink	Not found
	Not found	Not found	Not found	Not found	Atrophy of hepatocytes – 1 mink

Table 3. Histopathological splenic lesions (including measurements of lymphoid follicles) in experimental groups compared to the control group

Group/HP lesions	Group 1 <i>Toxocara canis</i> – eggs	Group 2 <i>Toxocara canis</i> – larvae	Group 3 <i>Toxascaris leonina</i> – eggs	Group 4 <i>Toxascaris leonina</i> – larvae	Control
Spleen	Hyperaemia / congestion – 3 mink	Hyperaemia / congestion – 2 mink	Hyperaemia / congestion – 4 mink	Hyperaemia / congestion – 3 mink	Hyperaemia / congestion – 2 mink
	Haematopoiesis – 3 mink	Haematopoiesis – 4 mink / very strong – 1 mink	Haematopoiesis – 4 mink	Haematopoiesis – 4 mink	Haematopoiesis – 4 mink
	Hypertrophy of lymphoid follicles – 5 mink	Hypertrophy of lymphoid follicles – 5 mink	Hypertrophy of lymphoid follicles – 5 mink	Hypertrophy of lymphoid follicles – 5 mink	Hypertrophy of lymphoid follicles – 1 mink
	Secondary follicles with germinal centres – 3 mink	Secondary follicles with germinal centres – 3 mink	Secondary follicles with germinal centres – 2 mink	Secondary follicles with germinal centres – 2 mink	Not found
Diameter of lymphoid follicles (µm)	769.6 (737.4–803.0)	744.7 (584.0–925.3)	666.3 (624.7–688.2)	764.1 (718.6–848.2)	465.7 (383.9–598.5)

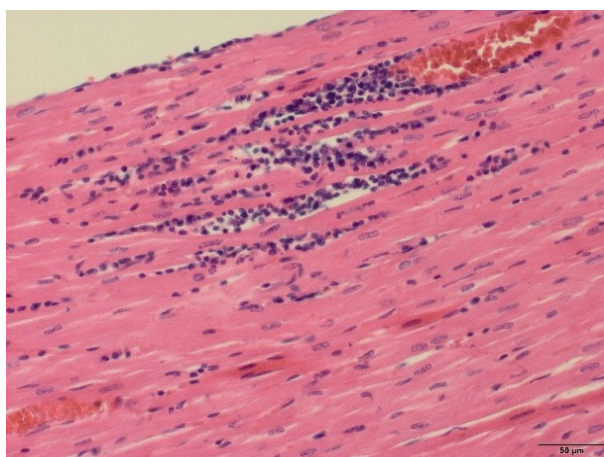
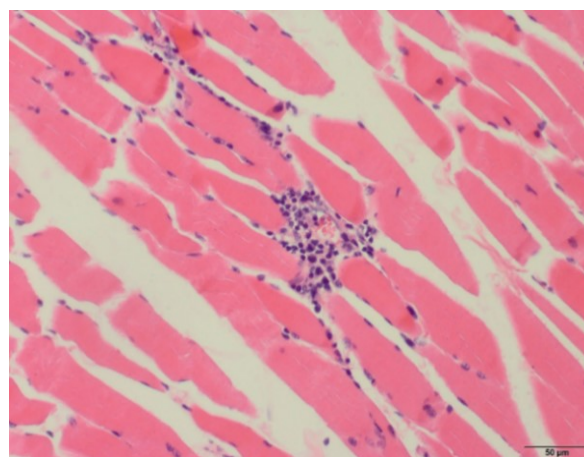
4. Lungs. The HP picture of pulmonary lesions presented a more recent stage of the infection. It looked as if larvae which had already targeted the organ provoked an intense local immune response in some mink. That was reflected by the infiltration of lymphocytes and macrophages in peribronchial areas of the lungs. The collation of *T. canis*- and *T. leonina*-infected mink slides disclosed a slightly more complex reaction of the immune system against *T. canis* larvae at that site. The presence of macrophages and eosinophils in the alveoli of mink in the *T. leonina*-egg-infected group represented the reaction to the migrating larvae. The pictures revealed that mink immune system reactions against *T. canis* and *T. leonina* developed in a similar way to the mineralisation. That was noted in slides of mink infected with both parasite species. The presence of *T. leonina* larvae in lung parenchyma would indicate a slightly milder mink immune system reaction against that parasite. Hyperaemia did not appear to be induced by the infection, as noted in all experimental and control mink.

**Fig. 4a.** Mineralisation of *T. canis* larva and scant inflammatory infiltrate (predominantly macrophages and lymphocytes) in the lung parenchyma – group 1 (mink infected with *Toxocara canis* eggs)**Fig. 4b.** Interstitial pneumonia – inflammatory infiltrates around vessels and bronchi – group 2 (mink infected with *Toxocara canis* tissue larvae)

5. Heart muscle and skeletal muscles. HP analysis revealed the local inflammatory reaction of heart and skeletal muscles to both canine roundworm species migrating larvae. The inflammatory infiltrate being composed of mononuclear cells around vessels in heart muscle, or lymphocytes and macrophages in skeletal muscles also reflected the reaction of immune cells against migrating larvae. The process seemed to be slightly stronger in the cases of *T. canis*- and *T. leonina*-egg-infected mink. Additionally, the presence of necrotic and mineralisation lesions in heart muscles probably reflected a local immune response to migrating roundworm larvae. It looked slightly more advanced in *T. canis*- than *T. leonina*-affected mink. The haemorrhagic lesions presented in G1 and G3 mink (groups infected by eggs) would also be a part of the histopathological lesions *in situ*. The hypoxia observed in some affected mink heart muscles could also have reflected the infection.

Table 4. Histopathological lesions of the lungs in experimental groups compared to the control group

Group/HP lesions	Group 1 <i>Toxocara canis</i> – eggs	Group 2 <i>Toxocara canis</i> – larvae	Group 3 <i>Toxascaris leonina</i> – eggs	Group 4 <i>Toxascaris leonina</i> – larvae	Control
Lungs	Hyperaemia / congestion – 5 mink	Hyperaemia / congestion – 4 mink	Hyperaemia / congestion – 5 mink	Hyperaemia / congestion – 5 mink	Hyperaemia / congestion – 5 mink
	Oedema – 2 mink	Oedema – 4 mink	Oedema – 4 mink	Oedema – 3 mink	Oedema – 5 mink
	Peribronchial cuffing of lymphocytes and macrophages (in 1 case – single mast cells) – 3 mink, perivascular – 3 mink	Peribronchial cuffing of lymphocytes and macrophages – 1 mink, perivascular – 3 mink; plasmatic & mast cells – 2 mink	Peribronchial cuffing of lymphocytes and macrophages – 1 mink	Peribronchial cuffing of lymphocytes and macrophages – 2 mink	Not found
	Inflammatory infiltrates of mononuclear cells in the lungs parenchyma – 4 mink / single cells only – 1 mink, numerous – 1 mink; also neutrophils in the lumen of bronchi – 1 mink	Inflammatory infiltrates of mononuclear cells in the lungs parenchyma – 1 mink	Inflammatory infiltrates of inflammatory cells in the lungs parenchyma – 1 mink	Inflammatory infiltrates of mononuclear cells in the lungs parenchyma – 3 mink / single plasma cells – 2 mink; single mast cells – 3 mink	Inflammatory infiltrates of mononuclear cells – 2 mink (single cells only)
	Macrophages in the alveoli – 1 mink	Macrophages in the alveoli – 3 mink	Macrophages & single eosinophils in the alveoli – 1 mink	Macrophages in the alveoli – 2 mink	Not found
	Mineralisation – 2 mink	Mineralisation – 1 mink	Not found	Mineralisation – 2 mink	Not found
	Not found	Not found	Presence of larva – 2 mink	Presence of larva – 1 mink	Not found

**Fig. 5a.** Inflammatory infiltrates of mononuclear cells around the vessel and among cardiomyocytes – group 3 (mink infected with *Toxascaris leonina* eggs)**Fig. 5b.** Inflammatory infiltrate of lymphocytes and macrophages around the vessel – skeletal muscle, group 1 (mink infected with *Toxocara canis* eggs)

The composition of other lesions as hyperaemia/congestion, cardiomyocyte hypertrophy and hyaline degeneration did not appear to reflect pathological lesions due to larvae migration. The quite common

lesions in skeletal muscle found in almost all experimental and control mink had to have been provoked by other factor(s).

Table 5. Histopathological lesions of the heart and skeletal muscles in experimental groups compared to the control group

Group/HP lesions	Group 1 <i>Toxocara canis</i> – eggs	Group 2 <i>Toxocara canis</i> – larvae	Group 3 <i>Toxascaris leonina</i> – eggs	Group 4 <i>Toxascaris leonina</i> – larvae	Control
Heart	Inflammatory infiltrates of mononuclear cells around vessels – 3 mink	Inflammatory infiltrates of mononuclear cells around vessels under epicardium – 1 mink	Inflammatory infiltrates of mononuclear cells around vessels or among cardiomyocytes – 2 mink	Not found	Not found
	Hyperaemia / congestion – 3 mink	Hyperaemia / congestion – 3 mink	Hyperaemia / congestion – 5 mink	Hyperaemia / congestion – 2 mink	Hyperaemia / congestion – 4 mink
	Haemorrhages – 1 mink	Not found	Haemorrhages – 3 mink	Not found	Not found
	Hypertrophy of cardiomyocytes – 4 mink	Hypertrophy of cardiomyocytes – 2 mink	Hypertrophy of cardiomyocytes – 3 mink	Hypertrophy of cardiomyocytes – 1 mink	Hypertrophy of cardiomyocytes – 2 mink
	Not found	Not found	Hypertrophy of vessel's walls – 1 mink	Not found	Not found
	Necrosis – 3 mink	Necrosis – 2 mink	Necrosis – 1 mink	Necrosis – 1 mink	Not found
	Hypoxia – 2 mink	Hypoxia – 1 mink	Not found	Hypoxia – 1 mink	Not found
	Not found	Hyaline degeneration – 1 mink	Hyaline degeneration – 3 mink	Hyaline degeneration – 3 mink	Hyaline degeneration – 3 mink
	Not found	Parenchymatous degeneration – 2 mink	Not found	Not found	Not found
	Not found	Mineralisation – 1 mink	Not found	Not found	Not found
Skeletal muscles	Inflammatory infiltrate of single lymphocytes and macrophages – 3 mink	Inflammatory infiltrate of single lymphocytes and macrophages around vessels – 2 mink	Inflammatory infiltrate of lymphocytes and macrophages – 1 mink	Not found	Not found
	Hyaline degeneration – 4 mink	Hyaline degeneration – 3 mink	Hyaline degeneration – 5 mink	Hyaline degeneration – 4 mink	Hyaline degeneration – 4 mink
	Lesions – all mink	No lesions – 1 mink	Lesions – all mink	No lesions – 1 mink	No lesions – 1 mink

Discussion

As other animals might be, farm mink also might be exposed to canine roundworm infections by ingestion of feed contaminated with tissue of other previously infected paratenic hosts, e.g. mice or rats. This can happen during feed preparation on the farm. Such an infection route, by ingestion of infected tissue, was confirmed experimentally in mice fed chicken liver containing *T. canis* larvae (6). Taira *et al.* (20) confirmed that *T. canis* larvae isolated from pig and chicken tissue exhibited high infectivity for mice and pigs. The infection in those animals was confirmed by isolation of migrating larvae from parenchymal organs, some pathological lesions such as white spots in the liver, and detection by ELISA of the specific IgG anti-larval *T. canis* excretory/secretory antibodies. Similarly, it was confirmed for feline roundworm *Toxocara cati*, which is

also involved in human toxocarosis. Researchers proved that chicken viscera infected with *T. cati* could cause toxocarosis (1, 21). Additionally, it was found that half of visceral *T. cati* larvae obtained from previously inoculated rats remained infective for mice for at least six months (22). These data strongly indicate that small rodents as paratenic hosts might be involved in transmission of *Toxocara* spp. within the environment, such as on a mink farm.

After ingestion, *T. canis* infective L3 larvae hatch in the small intestine and penetrate the gut wall. Then larvae within both the definitive (dog) and paratenic hosts are transmitted throughout the host body *via* the circulatory system towards visceral organs and skeletal muscles. After reaching the target tissues, roundworm larvae might remain there as “somatic larvae” (10). Although to our knowledge the migration routes of *T. canis* larvae have never been previously investigated

in farm mink, presumably they ought to be similar to those reported in other paratenic hosts. There are reports that *T. canis* larvae were recovered from a range of organs of various paratenic hosts (10, 19). It was generally assumed that the most problematic are those localised within the ocular bulb or such parenchymal tissues as the brain. Those are known to be responsible for the OLM and/or VLM syndromes in humans (10). Domagała (3) reported that in humans during parasitic infection a local tissue reaction was noticed where there was larvae or egg presence rather than adult presence. This reaction was also observed mostly surrounding more dead than live parasites. The inflammatory response against *Onchocerca* spp. and other filarial nematodes consisted of eosinophils, lymphocytes, plasmatic cells, neutrophils, and giant cells. At the beginning the eosinophils dominate among inflammatory cells and afterwards are replaced by macrophages and epithelioid cells. While the larvae remain alive the response is usually weak, but dead larvae (e.g. of *cysticercus*) induce a stronger reaction, and then fibrotic connective tissue and scar tissue are formed. This process can be associated with mineralisation, which is quite often spherical.

It has been assumed that when invading the definitive host such as a dog or a cat, *Toxascaris leonina* does not migrate throughout the body and all pre-adult and adult stages develop within the intestines. In contrast, *T. leonina* larvae invading the paratenic host were found in many tissues and organs. This is very similar to the biology of *T. canis* larvae. Strube *et al.* (19) suggested that the pattern of the somatic larvae distribution seems to be characteristic of particular paratenic host species.

The first step of HE slide analysis revealed that the mink immune reaction of the intestinal wall against *T. canis* and *T. leonina* larvae was quite similar in all experimental groups. The eosinophils, as cells particularly involved in the defence against parasites because their basophilic proteins are toxic to parasites (4), were present in at least half of the slides of all infected mink, but not observed in control mink slides. A slightly stronger reaction occurred in single mink infected with *T. canis*, in which the hypertrophy of lymphoid nodules was also noticed. One could assume that the local reaction was generally against infection of both roundworm species. Although low-level coccidian infection was noticed in some experimental and control mink, it was not clinically manifested and was recognised as an irrelevant factor. Coccidiosis in mink is generally considered pathogenic in kits, but not in adults. Adult mink usually act as carriers but do not present clinical symptoms (5). The lymph nodes of the intestines displayed eosinophil lymphadenitis with reactive centres. It should also be considered that at the moment of sampling (16 weeks p.i.) most larvae could have already left the intestinal wall and local lymph nodes and some other lesions could have disappeared as well.

There were massive inflammatory infiltrates of mononuclear cells present in the liver of all experimental mink. But in contrast no inflammatory reaction was found in control mink. Thus it can be concluded that those lesions definitely appeared as the liver tissue (local) reaction to the migrating roundworm larvae. According to Othmann *et al.* (15), both CD4+ and CD8+ T lymphocytes were detected within and around *Toxocara*-induced granulomas as well as in isolated inflammatory foci in the portal tracts or within the hepatic parenchyma. During experimental infection with *T. cati* in pigs, periportal and perilobular hepatitis were observed (18). Moreover, hepatocytic necrosis was noticed in both *T. canis*-infected groups and *T. leonina*-egg-infected mink. The foci of the necrosis and fibrosis found in *T. canis*-egg-infected mink may illustrate the tissue reaction to disrupted larvae. But the presence of granuloma in mink infected with *T. leonina* larvae might be explained by the possibly weaker immune response to these larvae. On the other hand, such lesions as fatty degeneration and hyperaemia of the organ were observed in most infected and control mink, so these seemed not to be related to the roundworm infections.

The secondary follicles were recognized as the main characteristic lesions of toxocarosis found in the spleens of all infected mink. Moreover, intense hypertrophy of primary lymphoid follicles was noted in half of all experimental mink, but also occurred in a single control mink. This observation may reflect strong stimulation of the immune system by ongoing tissue invasion by roundworm larvae. The secondary follicle proliferation seemed to be slightly more pronounced in *T. canis*- than in *T. leonina*-infected mink. In comparison to the control mink, the average size of lymphoid follicles in particular groups of *T. canis*- and *T. leonina*-infected animals was approximately 60% larger than in control specimens. It is very likely that these findings appeared as a result of immune system response to the presence of both parasite species larvae. According to Kayes (11), *T. canis* in mice elicits a striking splenomegaly as early as one week after oral inoculation and it is suggested that the splenomegaly may be due, in large part, to proliferation of the white pulp. Moreover at least some of lymphoproliferations are antigen specific. But the set of other lesions, being hyperaemia/congestion and haematopoiesis, were likely to be associated with other unidentified conditions as all these lesions occurred equally in each of the four experimental and control groups.

Histopathology of the lungs (these organs being a following stage of larvae movement in the mink host) revealed the most enhanced lesions due to both *T. canis* and *T. leonina* infections. It is commonly found that in humans (as a definitive host) migration of *Ascaris lumbricoides* larvae through the lung tissue might result in transient interstitial pneumonia with a characteristic infiltration of eosinophils (termed Loeffler syndrome) (3).

These lesions might be associated with a pulmonary haemorrhage, because parasites (*e.g. Ascaris* sp.) release protease inhibitors which may delay the thromboplastin and thrombin generation. In animals, lesions depend on the parasite species, and for example during *Dictyocaulus* sp. infection in cattle the massive involvement of eosinophils is noted at an early stage of pneumonia. Subsequently, lesions became localised around bronchi and bronchioles, where lymphoid nodules may also develop (4). In natural infections these two phases are associated with hyperplastic lymphadenitis in the related lymph nodes. A similar host organism response is observed during *Aelurostrongylus* sp. infections in cats – lymphocytic nodules are formed around vessels and airways. The airway tract is also infiltrated with immune cells in mice (as a paratenic host) during *T. leonina* invasion (1). Similarly, during lungworm *Muellerius* invasions in small ruminants, particularly when the worms die, calcified nodules persist as spherical masses of calcium salts, surrounded by a fibrous capsule (4).

There were peribronchial cuffings of lymphocytes and macrophages found in lung slides of all infected mink. Additionally, single mast as well as plasmatic cells were noticed in *T. canis*-infected mink (of both groups). These findings probably illustrate the more intense reaction of interstitial lung tissue to *T. canis* than to *T. leonina* migrating larvae. Interestingly, the inflammatory infiltrates of mononuclear cells were also found in lung parenchyma of control mink, but it was noted how significantly more massive cell infiltrates were found in *T. canis* and *T. leonina* infected mink compared with control animals. That would have been caused by other unidentified co-factor(s) and/or co-pathogen(s). Macrophages noted in the alveoli of all infected groups would have presumably been involved in the destruction of parasite larvae, which were already dead in the lung parenchyma. Normal larvae were only found in lung slides of *T. leonina*-infected mink. Additionally, the mineralisation was noted in both *T. canis*- and *T. leonina*-infected mink, but it was not present in control mink. These lesions emerged as the final parasite larvae destruction brought about by immune cells of the mink host. Similarly, *T. leonina* larvae in white mice were found in the lungs of 96% of infected mice on days 4–135 p.i. (15).

Parasite larvae origin lesions in heart muscles were mostly illustrated by the mononuclear inflammatory infiltrate around vessels (and less often among cardiomyocytes), which were found in both *T. canis*- and *T. leonine*-egg-infected mink. Even though that was not found in mink infected with *T. leonina* tissue larvae, definitely these lesions had to be due to a response to migrating larvae. Similarly as in the lungs, the foci of necrosis (all infected groups), hypoxia (except *T. leonina*-infected mink), the parenchymatous degeneration and mineralisation (only in the *T. canis*-larvae-infected group) found in the heart muscles also represented larvae destruction by the immune system of infected mink. But

within the heart muscles the process was less pronounced, probably due to fewer larvae having been able to reach the organ. Contrarily, there were more haemorrhages observed in mink infected with *T. canis* and *T. leonina* eggs in comparison to mink infected with larvae and control mink. That could be due to the possibly more intense larvae penetration of the heart muscle in those two experimental groups.

According to Cardillo *et al.* (2), during experimental inoculations of *T. cati* larval eggs in 18 BALB/c mice, inflammatory infiltrates can be observed in muscle and degenerated muscle, especially surrounding a parasite larva. The same lesions were observed in the myocardium and pericardium. The inflammatory cells present in all the tissues investigated were lymphocytes, neutrophils, and a few eosinophils.

It should be mentioned that the hyperaemia and the oedema of the lungs as well as the hyperaemia found in heart muscle tissue could be interpreted as a result of routine euthanasia procedures, but hypertrophy of cardiomyocytes and hyaline degenerations are more likely to have been caused by other conditions, as those were equally noted in parasite-infected and uninfected mink.

In conclusion, the results of the study revealed the pattern of characteristic lesions found in farm mink of all experimental groups. These were not particularly different between the experimental groups, but considerable differences were observed among parasite-infected individuals and uninfected control animals.

The analysis of HE slides revealed histopathological lesions, which expressed the local as well as general response of the farm mink immune system against invasive L3 migrating *T. canis* and *T. leonina* larvae. Interestingly, farm mink infected with embryonated eggs generally expressed more pronounced lesions compared with animals infected with tissue larvae, probably due to a high number of migrating *T. canis* or *T. leonina* larvae.

Our results might be considered useful data in some clinical observations during differential diagnosis of farm mink and in comparison studies on toxocarosis in other paratenic hosts.

Conflict of Interests Statement: The authors declare that there is no conflict of interests regarding the publication of this article.

Financial Disclosure Statement: The animals, commercial feed, and laboratory reagents used during the study were provided by the Polish Society of Breeders and Producers of Fur Animals, which was not involved in experimental study design or performance. The article publication fee was funded by the Faculty of Veterinary Medicine, Warsaw University of Life Sciences.

Animal Rights Statement: The project was approved by the 3rd Local Ethical Committee for Experiments on

Animals at Warsaw University of Life Sciences – no. 54/2012.

Acknowledgments: The authors are grateful to the Polish Society of Breeders and Producers of Fur Animals, Warsaw, Poland for supplying the animals, commercial feed, and laboratory reagents necessary to perform this study.

References

1. Azizi S., Oryan A., Sadjjadi S.M., Zibaei M.: Histopathologic changes and larval recovery of *Toxocara cati* in experimentally infected chickens. *Parasitol Res* 2007, 102, 47–52.
2. Cardillo N., Rosa A., Ribicich M., López C., Sommerfelt I.: Experimental infection with *Toxocara cati* in BALB/c mice, migratory behaviour and pathological changes. *Zoonoses Public Health* 2009, 56, 198–205.
3. Domagała W.: Choroby zakaźne i pasożytnicze (Infectious and parasitic diseases). In: *Patologia znaczy słowo o chorobie*, vol I, PAU, Wydział Lekarski, Kraków 2016.
4. Dungworth D.L.: The respiratory system, chapter 6. In: *Pathology of Domestic Animals*. vol 2, edited by K.V.F. Jubb, P.C. Kennedy, N. Palmer, Academic Press London, Orlando, 1985, pp. 413–536.
5. Duszyński D.W., Kvičerová J., Seville R.S.: The biology and identification of the Coccidia (Apicomplexa) of carnivores of the world. Elsevier Inc. 2018, pp. 32–33.
6. Dutra G.F., Pinto N.S.F., de Avila L.F., Dutra P.C., Telmo P. de L., Rodrigues L.H., Silva A.M.W.A., Scaini C.J.: Risk of infection by the consumption of liver of chickens inoculated with low doses of *Toxocara canis* eggs. *Vet Parasitol* 2014, 203, 87–90.
7. Gawor J., Borecka, A., Marczyńska M., Dobosz S., Żarnowska-Prymek H.: Risk of human toxocarosis in Poland due to *Toxocara* infection of dogs and cats. *Acta Parasitol* 2015, 60, 99–104.
8. Gundlach J.L., Sadzikowski A.B., Tomczuk K.: Prevalence of *Toxocara canis* in foxes and contamination of farm environments with this nematode's eggs. *Med Weter* 1999, 55, 255–258.
9. Kang S.A., Mi-Kyung Park M.K., Cho M.K., Yu H.S.: Alteration of cytokine production during visceral larva migrans by *Toxascaris leonina* in mice. *Korean J Parasitol* 2013, 51, 583–588.
10. Kassai T.: *Veterinary Helminthology*. Butterworth-Heinemann, Oxford 1999.
11. Kayes S.G.: Spleen cell responses in experimental murine toxocarosis. *J Parasitol* 1984, 70, 522–529.
12. Klockiewicz M., Jakubowski T., Sobczak-Filipiak M., Bartosik J., Długosz E.: Experimental infection of *Toxocara canis* and *Toxascaris leonina* in farm mink (*Neovison vison*). *J Vet Res* 2019, 63, DOI:10.2478/jvetres-2019-0033.
13. Magnaval J.F., Glickman L.T., Dorchies P., Morassin B.: Highlights of human toxocarosis. *Korean J Parasitol* 2001, 39, 1–11.
14. Oaks J.A., Kayes S.G.: Artificial hatching and culture of *Toxocara canis* second stage larvae. *J Parasitol* 1979, 65, 969–970.
15. Othman A.A., Ashour D.S., Mohamed D.A.: *Toxocara*-induced hepatic inflammation: immunohistochemical characterization of lymphocyte subpopulations and Bcl-2 expression. *Exp Parasitol* 2013, 134, 76–81.
16. Overgaauw P.A.M.: Aspects of *Toxocara* epidemiology: toxocarosis in dogs and cats. *Crit Rev Microbiol* 1997, 23, 233–251.
17. Overgaauw P.A.M., Van Knapen F.: Veterinary and public health aspects of *Toxocara* spp. *Vet Parasitol* 2013, 193, 398–403.
18. Sommerfelt I.E., Duchene A., Daprato B., Lopez C.M., Cardillo N., Franco A.J.: Experimental infection with *Toxocara cati* in pigs: migratory pattern and pathological response in early phase. *Rev Inst Med Trop Sao Paulo* 2014, 56, 347–352.
19. Strube C., Heuer L., Janecek E.: *Toxocara* spp. infections in paratenic hosts. *Vet Parasitol* 2013, 193, 375–389.
20. Taira K., Saeed I., Permin A., Kapel C.M.O.: Zoonotic risk of *Toxocara canis* infection through consumption of pig or poultry viscera. *Vet Parasitol* 2004, 121, 115–124.
21. Taira K., Saitoh Y., Kapel C.M.O.: *Toxocara cati* larvae persist and retain high infectivity in muscles of experimentally infected chickens. *Vet Parasitol* 2011, 180, 287–291.
22. Taira K., Yanagida T., Akazawa N., Saitoh Y.: High infectivity of *Toxocara cati* larvae from muscles of experimentally infected rats. *Vet Parasitol* 2013, 196, 397–400.