

## ORIGINAL ARTICLE

# Utility and validation of bone mineral density measurements at forearm in predicting trabecular microarchitecture and central-site osteoporosis in aging Indian postmenopausal women—a promising surrogate?

Krishna Prabha Gautam | Kripa Elizabeth Cherian  | Nitin Kapoor | Nihal Thomas | Thomas Vizhalil Paul

Department of Endocrinology, Christian Medical College and Hospital, Vellore, India

**Correspondence**

Kripa Elizabeth Cherian, Department of Endocrinology, Christian Medical College and Hospital, Vellore, Tamil Nadu – 632004, India.

Email: kripaec@gmail.com

**Abstract**

**Objective:** The objective of this paper was to present the results of our study of the utility of bone mineral density (BMD) measurements at various segments of distal forearm in predicting central-site osteoporosis and deteriorated trabecular microarchitecture.

**Methods:** This was a cross-sectional study and BMD at the femoral neck, lumbar spine, and distal forearm were assessed using the dual-energy X-ray absorptiometry (DXA) scanner and bone microarchitecture at lumbar spine by trabecular bone score (TBS). The utility of forearm BMD in predicting osteoporosis as well as the deteriorated TBS was assessed by a receiver operating characteristic analysis.

**Results:** A total of 352 postmenopausal women with mean (SD) age of 60.7 (6.8) years were included. The odds of having osteoporosis at femoral neck [odds ratio (OR) = 14.1, 95% confidence interval (CI): 7.8–25.2] and lumbar spine (OR = 7.5, 95% CI: 4.6–12.1) was highest with the mid-distal radius. A derived *T*-score cut off  $\leq -1.6$ ,  $-1.9$ , and  $-1.7$  at any segment of the forearm was elucidated to predict osteoporosis at the central-site, femoral neck, and lumbar spine, respectively, with sensitivity of 80%–88% and specificity of 60%–70%. The *T*-scores at all three forearm segments  $\leq -1.2$  showed fair performance in predicting degraded trabecular microarchitecture. The *T*-scores thus derived were further validated in cohort of 360 Bengali postmenopausal women.

**Conclusion:** BMD assessment at the forearm may be utilized in prediction of trabecular microarchitecture and central site osteoporosis at the femoral neck and lumbar spine in postmenopausal women.

**KEYWORDS**

forearm BMD, India, osteoporosis, postmenopausal women, trabecular bone score

This is an open access article under the terms of the Creative Commons Attribution-NonCommercial-NoDerivs License, which permits use and distribution in any medium, provided the original work is properly cited, the use is non-commercial and no modifications or adaptations are made.

© 2022 The Authors. *Aging Medicine* published by Beijing Hospital and John Wiley & Sons Australia, Ltd.

## 1 | INTRODUCTION

Osteoporosis is a systemic skeletal disease characterized by low bone mass and microarchitectural deterioration of bone tissue leading to an increase in bone fragility and an enhanced susceptibility to fractures.<sup>1</sup> Osteoporosis results from a decrease in the number of trabeculae coupled with trabecular thinning as well as loss of connectivity, a decrease in cortical thickness, and an increase in bone porosity.<sup>2</sup> Fragility fractures due to osteoporosis commonly occur in areas with high rates of bone loss, such as the spine, hips, or wrist.<sup>3</sup> The International Society for Clinical Densitometry (ISCD) guidelines recommend that osteoporosis be diagnosed at a bone mineral density (BMD) *T*-score of  $\leq -2.5$ , at the femoral neck, total hip, or lumbar spine as measured by dual energy x-ray absorptiometry (DXA).<sup>4</sup>

The distribution of cortical and trabecular bone varies in the distal forearm. Although the ultra-distal forearm is chiefly composed of trabecular bone, the distal one third and mid-distal segments are predominantly composed of cortical bone.<sup>5</sup> At sites in the radius and ulna commonly used in the photon absorptiometric method of bone mineral mass measurement, the percentage of trabecular bone varies between 10% and 50%. The content of trabecular bone in the most distal 10% of the length of the radius and ulna remains approximately constant with age. However, the percentage of trabecular bone in the radial segment, which lies between 30% and 40% of the length as measured from the styloid process, increases with age.<sup>6</sup>

BMD assessment at the distal radius is not routinely used in the diagnosis of osteoporosis, except in certain circumstances where central sites (hips and lumbar spine) are nonevaluable, in cases of primary hyperparathyroidism and marked obesity when the patient's body weight exceeds the weight limit of the DXA table.<sup>4</sup> Thus, the forearm represents an alternative DXA scan site for patient groups for whom standard scan sites are not practical or appropriate. The forearm is an upper body appendicular skeletal site and is not often subjected to weight bearing, and patient positioning is less burdensome compared to other DXA scan locations.

Previous studies have shown that the BMD assessment at the distal forearm may be used as a surrogate for the spine and upper femur and has shown to yield data as good as the lumbar spine for hip fracture.<sup>7</sup> The correlation coefficient between bone density at the distal third of radius and the lumbar spine or femoral neck has been reported to be between 0.53 and 0.67.<sup>8,9</sup>

Trabecular bone score (TBS) is a novel densitometric tool that evaluates pixel gray-level variations in the lumbar spine DXA image, providing an indirect measure of bone microarchitecture.<sup>10</sup> TBS improves fracture-risk prediction beyond that provided by BMD and clinical risk factors, and can be incorporated to the Fracture Risk Assessment tool (FRAX) to enhance fracture prediction.<sup>11</sup>

To the best of our knowledge, the utility of BMD assessment at various segments of the distal forearm in predicting osteoporosis at the hip and spine has not been studied in Indian postmenopausal women. Moreover, there is paucity of data on whether the forearm BMD may be used as a surrogate measure to predict trabecular microarchitecture. In this study, we aimed to evaluate the utility of

BMD measurements at the forearm in predicting the TBS indicative of microarchitectural deterioration at the lumbar spine as well as central site osteoporosis defined as the presence of osteoporosis at either the neck of femur, lumbar spine, or both, and whether this would serve as a useful surrogate in prediction of osteoporosis.

## 2 | METHODOLOGY

This was a cross-sectional study conducted over a period of 1 year in community-dwelling ambulatory postmenopausal women from southern India, aged 50 years or more, recruited through simple random sampling and after obtaining a written informed consent. Subjects with concomitant hepatic or renal disease, malabsorption, women on corticosteroids, hyperthyroidism, and those with a history of fractures and metal implants were excluded. The cutoffs of forearm BMD *T*-scores obtained from this cohort used to predict central osteoporosis or a low TBS were further validated in a cohort of healthy, ambulant postmenopausal women, hailing from the state of West Bengal in eastern India. These women were the next-of-kin of patients seeking treatment in this hospital for various ailments, and they were not known to have any major disease that could potentially impair bone health. This study was approved by the institutional review board and ethics committee.

### 2.1 | Anthropometry

Height (cm) and weight (kg) were measured by standard methods. Height was measured to the nearest cm using a wall-mounted stadiometer, with feet together, heels against the wall, knees straight, without headgear and footwear, and looking straight ahead. Weight was measured using a calibrated digital weighing scale (Tulaman HT 500 series with accuracy up to 100 g), with the patient barefoot, in light clothing, one foot on each side of the scale, facing forward, and arms by the side of the body. Body mass index (BMI) was calculated as weight (kg)/height (in meters).<sup>2</sup>

### 2.2 | Assessment of BMD

Areal BMD ( $\text{g}/\text{cm}^2$ ) at the femoral neck and lumbar spine (L1–L4) were assessed using DXA scanner Hologic Discovery A series. The categorization of BMD into osteoporosis, osteopenia, and normal was done based on *T*-scores, as defined by the ISCD guidelines.<sup>4</sup> The reference used was of White women from the National Health and Nutrition Examination Survey (NHANES) database as a previous study done at our center, demonstrated suboptimal performance of available Indian reference database in diagnosing osteoporosis even in subjects with hip fractures.<sup>12</sup> The coefficient of variation (CV) for measurement of BMD at the forearm and lumbar spine was less than 1% and 2–3% for the femoral neck. The distal part of the forearm was divided into three regions of interest (ROIs): the distalmost region

(termed the “ultra-distal” radius), consisting of a 15-mm section adjacent to the end plate of the radius; the proximal region (termed the “one-third distal” radius), consisting of a 20-mm section one-third of the distance between the ulnar styloid and the olecranon; and the intermediate region (termed the “mid-distal” radius), consisting of the remaining section between the two aforementioned sites.<sup>13</sup>

## 2.3 | Assessment of TBS

TBS is a novel noninvasive method that evaluates pixel gray-level variations in the spine DXA image and helps in assessing the microarchitecture of the bone. A TBS (unitless) value of more than 1.350 indicates normal microarchitecture, 1.200–1.350 indicates partially degraded microarchitecture, and a TBS < 1.200 indicates degraded bone microarchitecture.<sup>14</sup> TBS (L1–L4) measurements were performed using TBS iNsite software version 3 (Med-Imaps, Bordeaux, France). In this study, a TBS value that was  $\leq 1.238$  was classified as “low TBS” based on the mean (SD) value of TBS being 1.238 (0.094) in the study cohort.

## 2.4 | Statistical analyses

Statistical analyses of the data were performed using the SPSS program (version 23.0, for Windows, IBM Corp.). Measurements of central tendency (mean) and dispersion (standard deviation, range) were used for continuous variables and distribution of frequencies for categorical variables. Differences for the variables of interest between comparison groups were made by the Student's *t* test for continuous variables when the data were normally distributed and the Mann-Whitney *U* test for data that did not follow a normal

distribution. The Pearson chi-square test or Fisher exact test was used to compare categorical variables. The relationship between the quantitative variables was analyzed using the Pearson or Spearman bivariate correlations test. The performance of various segments of the forearm in predicting central-site osteoporosis or low TBS were assessed using the area under the receiver operating characteristic (ROC) curve, which is an indicator of the overall accuracy of a diagnostic test. An area under the curve (AUC) of 1.0 represents perfect fit, while an AUC of 0.5 indicates a performance that is no different from chance. For all calculations, a *P* value < 0.05 for two tails was considered significant.

## 3 | RESULTS

The derivation cohort had a total of 352 women with mean (SD) age of 60.7 (6.8) years and BMI of 25.1 (4.8) kg/m<sup>2</sup>. In the derivation cohort 4/352 (4%) had a BMI that was  $\geq 35$  kg/m<sup>2</sup>. The baseline characteristics of the study population are shown in Table 1. At baseline, the prevalence of osteoporosis at the femoral neck, lumbar spine, and distal third of the forearm were 101 of 352 (28.7%), 145 of 352 (41.2%), and 123 of 352 (34.9%), respectively. Osteoporosis at either the lumbar spine or femoral neck was present in 166 of 352 (47.2%) of the study subjects.

### 3.1 | Correlation of forearm BMD with bone mineral density at the lumbar spine and femoral neck and TBS

A significant positive correlation existed between all segments of the distal forearm and the TBS ( $r = 0.4$ ,  $p < 0.001$ ). Significant positive

Variable	Derivation cohort (N = 352) Mean (SD)	Validation cohort (N = 360) Mean (SD)
Age, y	60.7 (6.8)	65.4 (5.1)
Height, cm	152.3 (5.2)	150.8 (6.0)
Weight, kg	58.4 (12.0)	59.6 (12.4)
BMI, kg/m <sup>2</sup>	25.1 (4.8)	26.1 (5.1)
BMD at femoral neck, g/cm <sup>2</sup>	0.649 (0.109)	0.614 (0.112)
T-score	-1.8 (0.9)	-2.1 (1.0)
BMD at lumbar spine, g/cm <sup>2</sup>	0.817 (0.152)	0.802 (0.141)
T-score	-2.1 (1.3)	-2.2 (1.2)
BMD at forearm, distal 1/3, g/cm <sup>2</sup>	0.576 (0.086)	0.549 (0.077)
T-score	-1.8 (1.4)	-2.3 (1.3)
BMD at forearm, mid-distal, g/cm <sup>2</sup>	0.481 (0.077)	0.451 (0.072)
T-score	-2.1 (1.4)	-2.5 (1.3)
BMD at forearm, ultra-distal, g/cm <sup>2</sup>	0.325 (0.067)	0.298 (0.062)
T-score	-1.7 (1.3)	-2.2 (1.2)
Trabecular bone score	1.238 (0.094)	1.189 (0.086)

TABLE 1 Baseline characteristics of the study population

Abbreviations: BMD, bone mineral density; BMI, body mass index.

correlation was also seen between the BMD at the distal third of forearm and the BMD at the femoral neck ( $r = 0.65$ ,  $p < 0.001$ ) and lumbar spine ( $r = 0.62$ ,  $p < 0.001$ ). Similar positive correlation was noted between the BMD at the mid-distal radius and the BMD at the femoral neck ( $r = 0.68$ ,  $p < 0.001$ ) and the lumbar spine ( $r = 0.62$ ,  $p < 0.001$ ). The BMD at the ultra-distal radius was also seen to have a significant positive correlation with BMD at these sites ( $0.65$ ,  $p < 0.001$  for the lumbar spine and  $r = 0.70$ ,  $p < 0.001$  for the femoral neck).

### 3.2 | Utility of forearm in predicting central site osteoporosis

In the whole cohort, the odds of having central osteoporosis (defined as the presence of osteoporosis either at the neck of femur or lumbar spine or both) were significantly higher ( $p < 0.001$ ) in those with osteoporosis at the forearm than those without forearm osteoporosis; odds ratio (OR) = 9.6, 95% confidence interval [CI]: 5.7–16.3) for the distal third of the forearm, OR = 9.0 (95% CI: 5.2–15.7) for the ultra-distal radius, and OR = 10.1 (95% CI: 6.1–16.2) for the mid-distal forearm.

### 3.3 | Differential utility of forearm segments in predicting osteoporosis at femoral neck and lumbar spine

Among the 145 subjects with osteoporosis at the lumbar spine, 85 had osteoporosis at the distal third of radius, 99 had osteoporosis at the mid-distal radius, and 77 had osteoporosis at the ultra-distal radius. Among the 101 subjects with femoral neck osteoporosis, 74 subjects had osteoporosis at the distal third, 83 had osteoporosis at the mid-distal, and 64 had osteoporosis at the ultra-distal radius. This is depicted in Figure 1. The odds of having osteoporosis at the femoral neck (OR = 14.1, 95% CI: 7.8–25.2) and the lumbar spine

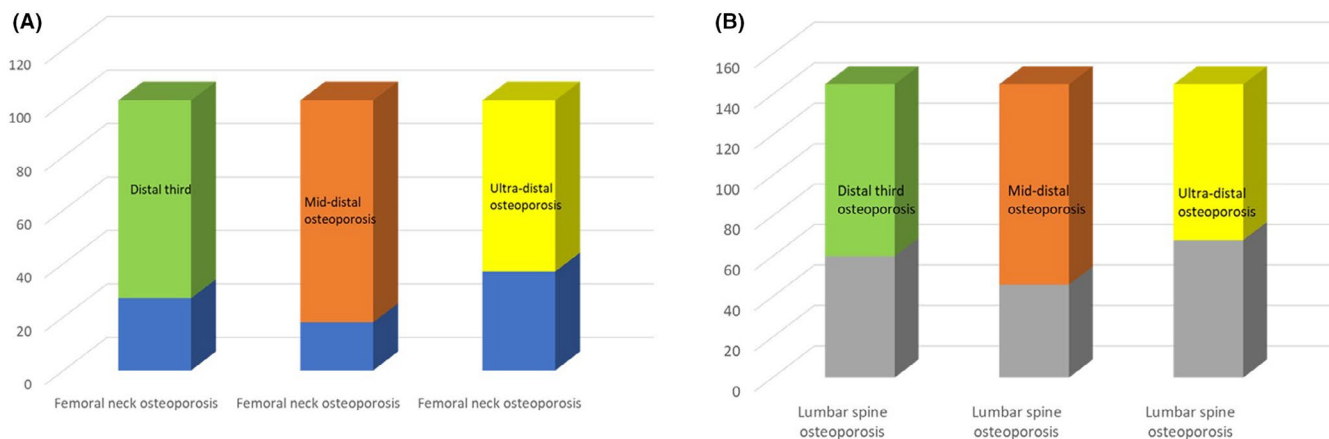
(OR = 7.5, 95% CI: 4.6–12.1) was highest with the mid-distal radius as compared to the distal third (OR = 6.3, 95% CI: 3.8–10.2 for the lumbar spine and OR = 11.3, 95% CI: 6.5–19.3 for the femoral neck) and ultra-distal sites (OR = 7.2, 95% CI: 4.3–12.1 for the lumbar spine and OR = 8.8, 95% CI: 5.2–14.9 for the femoral neck).

### 3.4 | ROC analysis

On performing an ROC analysis, the performance of T-scores at all segments of the forearm was good in predicting osteoporosis at central sites combined as well as individually for the femoral neck and lumbar spine, with an AUC > 0.800 ( $p < 0.001$  for all analyses). A T-score cutoff  $\leq -1.6$ ,  $-1.9$  and  $-1.7$  at any segment of the forearm, predicted central-site osteoporosis, osteoporosis at the femoral neck and lumbar spine, respectively, with a sensitivity of 80–88% and specificity of 60–70%. These results are further elaborated in Table 2 and Figure 2. Moreover, the T-scores at the ultra-distal forearm segment  $< -1.2$  showed fair performance in predicting degraded trabecular microarchitecture (TBS  $\leq 1.238$ ), with an AUC of 0.700 ( $p < 0.001$ ; Table 2).

### 3.5 | Validation of T-score cutoffs to diagnose low TBS and central osteoporosis

The validation cohort comprised 360 ambulant postmenopausal women from West Bengal, located in eastern India. The mean (SD) age and BMI were 65.4 (5.2) years and 26.1 (5.1) kg/m<sup>2</sup>, respectively. In the validation cohort, 21 of 360 (5.8%) had a BMI that was  $\geq 35$  kg/m<sup>2</sup>. The prevalence of osteoporosis at the lumbar spine and femoral neck was 44.4% (160/360) and 40.8% (147/360), respectively. Osteoporosis at either site (central osteoporosis) was present in 56.7% (204/360) of the validation cohort. A cutoff of  $\leq -1.2$  at the ultra-distal, mid-distal, and distal third of forearm could correctly identify 87.6%, 89.6%, and 86.6% of women with a degraded



**FIGURE 1** (A) Prevalence of osteoporosis at different forearm segments as a proportion of femoral neck osteoporosis. (B) Prevalence of osteoporosis at different forearm segments as a proportion of lumbar spine osteoporosis

TABLE 2 Receiver operating characteristic analysis of various forearm segments predicting osteoporosis

Forearm segment	AUC	95% CI	T-score cutoff	Sensitivity (%)	Specificity (%)	P value
Central site osteoporosis						
Distal-third	0.836	0.795–0.876	−1.6	81	67	<0.001
Mid-distal	0.825	0.783–0.868	−1.6	83	61	<0.001
Ultra-distal	0.833	0.791–0.874	−1.6	80	69	<0.001
Femoral neck osteoporosis						
Distal-third	0.841	0.797–0.886	−1.9	86	67	<0.001
Mid-distal	0.847	0.803–0.882	−1.9	88	61	<0.001
Ultra-distal	0.832	0.785–0.879	−1.9	81	70	<0.001
Lumbar spine osteoporosis						
Distal-third	0.806	0.761–0.850	−1.7	80	66	<0.001
Mid-distal	0.800	0.754–0.846	−1.7	83	60	<0.001
Ultra-distal	0.818	0.775–0.861	−1.7	80	70	<0.001
Trabecular bone score						
Distal-third	0.700	0.632–0.743	−1.2	82	49	<0.001
Mid-distal	0.674	0.617–0.730	−1.2	88	43	<0.001
Ultra-distal	0.684	0.628–0.640	−1.2	83	46	<0.001

Abbreviations: AUC, area under the curve; CI, confidence interval.

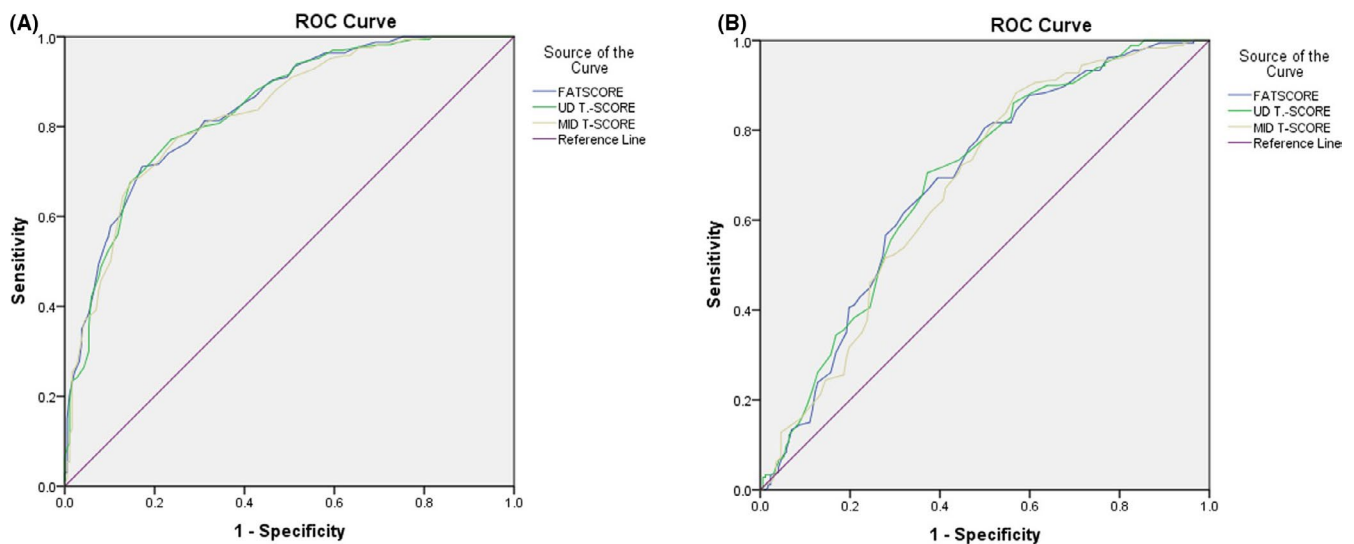


FIGURE 2 (A) Receiver operating characteristic (ROC) curves showing the performance of forearm segments in predicting central osteoporosis. ROC curves showing the performance of forearm segments in predicting low trabecular bone score (TBS)

microarchitecture, yielding a positive predictive value of 74.3%, 72.8%, and 76% respectively. Similarly, a T-score cutoffs  $\leq -1.6$  at the ultra-distal, mid-distal, and distal third of the forearm could correctly identify 83.8%, 90.2%, and 88.2% of women with central osteoporosis with positive predictive values of 67.6%, 67.4%, and 70.9%, respectively. These results are depicted in Tables 3 and 4.

## 4 | DISCUSSION

This study undertaken in 352 postmenopausal women highlights the utility of BMD measurements at various segments of the forearm

in predicting the trabecular microarchitecture as well as osteoporosis at the femoral neck and lumbar spine. The BMD at all segments of the forearm showed significant positive correlation with the trabecular microarchitecture as well as the BMD at the lumbar spine and femoral neck. The odds of encountering partially degraded microarchitecture were highest with ultra-distal osteoporosis. Osteoporosis at either the femoral neck and/or the lumbar spine was also more frequently noted among subjects with osteoporosis at the forearm, the odds being highest for the mid-distal radius. Moreover, all segments of the forearm performed fair in predicting a partially degraded microarchitecture as well as osteoporosis at the lumbar spine and femoral neck with an AUC of 0.674–0.700. The T-score

TABLE 3 Validation of *T*-scores in predicting low TBS

Category	TBS ≤ 1.238	TBS > 1.238	Total	Statistic	Value	95% CI
UD ≤ -1.2	220	76	296	Sensitivity	87.6%	82.9–91.4%
UD > -1.2	31	33	64	Specificity	30.2%	21.8–39.8%
Total	251	109	360	Positive likelihood ratio	1.26	1.10–1.43
				Negative likelihood ratio	0.41	0.26–0.63
				Positive predictive value	74.3%	71.7–76.7%
				Negative predictive value	51.6%	40.7–62.2%
				Accuracy	70.3%	65.2–74.9%
MID ≤ -1.2	225	84	309	Sensitivity	89.6%	85.2–93.1%
MID > -1.2	26	25	51	Specificity	22.9%	15.4–31.9%
Total	251	109	360	Positive likelihood ratio	1.16	1.04–1.3
				Negative likelihood ratio	0.45	0.27–0.75
				Positive predictive value	72.8%	70.6–74.9%
				Negative predictive value	49.0%	36.8–61.3%
				Accuracy	69.4%	64.4–74.2%
FA ≤ -1.2	216	68	284	Sensitivity	86.1%	81.1–90.1%
FA > -1.2	35	41	76	Specificity	37.6%	28.5–47.4%
Total	251	109	360	Positive likelihood ratio	1.38	1.18–1.61
				Negative likelihood ratio	0.37	0.25–0.55
				Positive predictive value	76.1%	73.1–78.7%
				Negative predictive value	53.9%	44.2–63.4%
				Accuracy	71.4%	66.4–76.0%

Abbreviations: CI, confidence interval; FA, forearm; MID, mid-distal; TBS, trabecular bone score; US, ultra-distal.

cutoffs derived from the study cohort were further validated in a distinct cohort of postmenopausal women from West Bengal, and were found to be useful in detecting a low TBS and central osteoporosis, with a good sensitivity.

In the United States, among adults, about two-thirds were found to be obese and about 15% were found to have morbid obesity (BMI > 35 kg/m<sup>2</sup>).<sup>15</sup> The trends in obesity prevalence has shown that in men, the prevalence of obesity has increased from 27.5% (1999–2000) to 43% (2017–2018) and in women from 33.4% (1999–2000) to 41.9% (2017–2018).<sup>16</sup> In a study done at the authors' center, about 61% of postmenopausal women were found to be obese.<sup>17</sup> Overall, in India, the prevalence of overweight/obesity were observed to be 38.4% and 36.2%, respectively.<sup>18</sup> From the Medicare data in the United States, the prevalence of degenerative spine disease was about 27%.<sup>19</sup> Similar data on degenerative disc disease in the Indian population were not available. Assessment of BMD at the forearm will be of utility in such individuals with morbid obesity where the weight of the individual exceeds the weight limit of the DXA table and in cases of degenerative disease involving the spine or at the hip that makes these sites nonevaluable.

In this study, the BMD at all sites showed a significant positive correlation with BMD at the lumbar spine, and the femoral neck, as well as the TBS. Similar positive correlation between the peripheral and axial BMD measurements were observed in a study on 242 postmenopausal women by Pouilles et al.<sup>20</sup> A study by Damilakis et al.<sup>21</sup> also showed that BMD assessment at the forearm could be used as

a pre-screening tool to identify women with low BMD at the axial skeleton. The good correlation between peripheral and central sites probably indicates that the bone loss that occurs at the forearm parallels the reduction in bone density observed at axial sites and therefore may be used as a proxy measure in rare instances that render the axial sites nonevaluable. The BMD measurements at the forearm may also be used to detect early microarchitectural deterioration at the lumbar spine, as reflected by the significant positive correlation between the two measures.

Moreover, the odds of having osteoporosis at either the femoral neck, the lumbar spine, or at both sites were highest for the mid-distal radius. The proportion of trabecular bone remains constant in the distal 10% of the radius, whereas it increases with age in the segment that lies between the 30% and 40% of the radius as measured from the styloid process.<sup>6</sup> This probably accounts for the greater odds of femoral neck and lumbar spine osteoporosis in subjects with mid-distal osteoporosis in this aging cohort. However, further follow-up studies are needed in this regard. The odds of having a partially degraded microarchitecture, however, was highest for the ultra-distal site. A plausible explanation for this discrepancy would be that the cortical and trabecular bone compartments behave differently at different periods of time. Trabecular bone loss starts much earlier in life, around the time of menopause or even earlier, and follows an exponential decline in the first 10–15 postmenopausal years.<sup>22</sup> This probably reflects the higher odds of detecting a partially degraded TBS in individuals with osteoporosis at the ultra-distal site.

TABLE 4 Validation of *T*-scores in central osteoporosis

Category	Osteoporosis	No osteoporosis	Total	Statistic	Value	95% CI
UD ≤ -1.6	171	82	253	Sensitivity	83.8%	78.0–88.6%
UD > -1.6	33	74	107	Specificity	47.4%	39.4–55.6%
Total	204	156	360	Positive likelihood ratio	1.59	1.36–1.87
				Negative likelihood ratio	0.34	0.24–0.49
				Positive predictive value	67.6%	63.9–71.0%
				Negative predictive value	69.2%	61.2–76.2%
				Accuracy	68.1%	62.9–72.8%
MID ≤ -1.6	184	89	273	Sensitivity	90.2%	85.2–93.1%
MID > -1.6	20	67	87	Specificity	42.9%	35.4–51.1%
Total	204	156	360	Positive likelihood ratio	1.58	1.37–1.82
				Negative likelihood ratio	0.23	0.14–0.36
				Positive predictive value	67.4%	64.2–70.5%
				Negative predictive value	77.0%	68.0–84.1%
				Accuracy	69.7%	64.1–74.4%
FA ≤ -1.6	180	74	254	Sensitivity	88.2%	83.0–92.3%
FA > -1.6	24	82	106	Specificity	52.6%	44.4–60.6%
Total	204	156	360	Positive likelihood ratio	1.86	1.57–2.21
				Negative likelihood ratio	0.22	0.15–0.34
				Positive predictive value	70.9%	67.2–74.3%
				Negative predictive value	77.3%	69.5–83.7%
				Accuracy	72.8%	67.8–77.3%

Abbreviations: CI, confidence interval; FA, forearm; MID, mid-distal; US, ultra-distal.

Moreover, on doing an ROC analysis, it was found that all segments of the forearm predicted osteoporosis at either the femoral neck, the lumbar spine, or both as well as a partially degraded microarchitecture with a good area under the ROC curve. Similar studies evaluating forearm BMD in predicting central-site osteoporosis and in low TBS are limited in the Indian context and in literature. A study by Martin AR showed a moderate to high correlation between different segments of the distal forearm.<sup>23</sup> A similar study done on 187 black postmenopausal women demonstrated that the distal radius performed well with an AUC of 0.818 and 0.771 for osteoporosis at the hip and lumbar spine.<sup>24</sup> A thorough literature search did not yield similar studies evaluating the utility of BMD at the forearm in predicting a low TBS. As TBS predicts fragility fractures independent of BMD, the distal forearm may be used as a surrogate for deterioration of the trabecular microarchitecture at the lumbar spine.

This is the first study from the Indian subcontinent that has evaluated the usefulness of BMD assessment at the forearm in predicting central site osteoporosis. To the best of our knowledge, this is also the first study that has assessed the utility of BMD measurement at the forearm in predicting low TBS. The validation of *T*-score cutoffs from the derivation group, in a separate cohort of postmenopausal women, further authenticates these findings. It is true that forearm BMD assessment does not supplant central DXA measurements in diagnosing osteoporosis; neither is it recommended for the

diagnosis of osteoporosis. Current guidelines advocate that BMD *T*-scores ≤ -2.5 at the lumbar spine, neck of the femur, or hip be used in the diagnosis of osteoporosis. Nevertheless, in exceptional settings where the spine or the hip are nonevaluable, the forearm may be utilized as a surrogate in predicting bone loss at central sites as well as a degraded trabecular microarchitecture.

Our study is not without limitations. Vertebral fracture assessment was not obtained in this cohort of study subjects. Bone turnover markers, which reflects the prevailing state of bone remodeling, was not performed. Moreover, even if treatment is initiated based on the results of the forearm *T*-score cutoffs, as mentioned in this study, serial monitoring of forearm BMD may not predict long-term changes in overall BMD at the spine and femoral neck.<sup>25</sup> These instances may warrant serial measurement of biochemical markers of bone turnover to decide on continuation or withdrawal of anti-osteoporotic medication.

## 5 | CONCLUSION

This study from southern India showed that the BMD as measured by DXA at the forearm had a role in predicting both central site osteoporosis at the lumbar spine and the femoral neck as well as the trabecular microarchitecture in Indian postmenopausal women and could be a promising surrogate to whole body DXA scan.

## CONFLICT OF INTEREST

There are no conflicts of interest to disclose.

## AUTHOR CONTRIBUTIONS

**Conceptualization:** Paul, Thomas, and Kapoor. **Data collection:** Gautam, Paul, Kapoor, and Cherian. **Data analysis and interpretation:** Cherian, Kapoor, and Paul. **Drafting the article:** Gautam and Cherian. **Critical appraisal of the article:** Kapoor, Thomas, and Paul. **Final approval of the version to be published:** Gautam, Cherian, Kapoor, Thomas, and Paul.

## ORCID

Kripa Elizabeth Cherian  <https://orcid.org/0000-0001-9249-3719>

## REFERENCES

- Compston JE, McClung MR, Leslie WD. Osteoporosis. *Lancet*. 2019;393(10169):364-376.
- Consensus development conference: diagnosis, prophylaxis, and treatment of osteoporosis. *Am J Med*. 1993;94(6):646-650.
- Khosla S, Riggs BL, Atkinson EJ, et al. Effects of sex and age on bone microstructure at the ultradistal radius: a population-based noninvasive in vivo assessment. *J Bone Miner Res*. 2006;21(1):124-131.
- Schousboe JT, Shepherd JA, Bilezikian JP, Baim S. Executive summary of the 2013 international society for clinical densitometry position development conference on bone densitometry. *J Clin Densitom*. 2013;16(4):455-466.
- Kindler JM, Kalkwarf HJ, Lappe JM, et al. Pediatric reference ranges for ultradistal radius bone density: results from the bone mineral density in childhood study. *J Clin Endocrinol Metab*. 2020;105(10):e3529-e3539.
- Schlenker RA, VonSeggen WW. The distribution of cortical and trabecular bone mass along the lengths of the radius and ulna and the implications for in vivo bone mass measurements. *Calcif Tissue Res*. 1976;20(1):41-52.
- Cummings SR, Black DM, Nevitt MC, et al. Bone density at various sites for prediction of hip fractures. *Lancet*. 1993;341(8837):72-75.
- Ryan PJ, Blake GM, Fogelman I. Measurement of forearm bone mineral density in normal women by dual-energy X-ray absorptiometry. *Br J Radiol*. 1992;65(770):127-131.
- Martin JC, Reid DM. Appendicular measurements in screening women for low axial bone mineral density. *Br J Radiol*. 1996;69(819):234-240.
- Rajan R, Cherian KE, Kapoor N, Paul TV. Trabecular bone score—An emerging tool in the management of osteoporosis. *Indian J Endocrinol Metab*. 2020;24(3):237.
- Hans D, Šteňová E, Lamy O. The Trabecular Bone Score (TBS) complements DXA and the FRAX as a fracture risk assessment tool in routine clinical practice. *Curr Osteoporos Rep*. 2017;15(6):521-531.
- Shetty S, Kapoor N, Naik D, Asha HS, Thomas N, Paul TV. The impact of the Hologic vs the ICMR database in diagnosis of osteoporosis among South Indian subjects. *Clin Endocrinol (Oxf)*. 2014;81(4):519-522.
- Shepherd JA, Cheng XG, Lu Y, et al. Universal standardization of forearm bone densitometry. *J Bone Miner Res*. 2002;17(4):734-745.
- Silva BC, Broy SB, Boutroy S, Schousboe JT, Shepherd JA, Leslie WD. Fracture risk prediction by non-BMD DXA measures: the 2015 ISCD official positions part 2: Trabecular Bone Score. *J Clin Densitom*. 2015;18(3):309-330.
- Ogden CL, Carroll MD, Flegal KM. Prevalence of obesity in the United States. *JAMA*. 2014;312(2):189-190.
- Ogden CL, Fryar CD, Martin CB, et al. Trends in obesity prevalence by race and Hispanic origin-1999-2000 to 2017-2018. *JAMA*. 2020;324(12):1208-1210.
- Sridharan K, Cherian KE, Kurian ME, Asha HS, Paul TV, Kapoor N. Utility of anthropometric indicators in predicting osteoporosis in ambulant community dwelling rural postmenopausal women from southern India. *Trop Doct*. 2020;50(3):228-232.
- Verma M, Das M, Sharma P, Kapoor N, Kalra S. Epidemiology of overweight and obesity in Indian adults - a secondary data analysis of the National Family Health Surveys. *Diabetes Metab Syndr*. 2021;15(4):102166.
- Parenteau CS, Lau EC, Campbell IC, Courtney A. Prevalence of spine degeneration diagnosis by type, age, gender, and obesity using Medicare data. *Sci Rep*. 2021;11(1):5389.
- Pouillès JM, Tremollières FA, Martinez S, Delsol M, Ribot C. Ability of peripheral DXA measurements of the forearm to predict low axial bone mineral density at menopause. *Osteoporos Int*. 2001;12(1):71-76.
- Damilakis J, Papadokostakis G, Perisinakis K, Hadjipavlou A, Gourtsoyiannis N. Can radial bone mineral density and quantitative ultrasound measurements reduce the number of women who need axial density skeletal assessment? *Osteoporos Int*. 2003;14(8):688-693.
- Boyanov M. Diagnostic discrepancies between two closely related forearm bone density measurement sites. *J Clin Densitom*. 2001;4(1):63-71.
- Martin AR, Holder LE, Buie V, et al. Measurement of distal forearm bone mineral density: can different forearm segments be used interchangeably? *J Clin Densitom*. 1999;2(4):381-387.
- Kruger I, Kruger M, Doak C, Kruger A. Cut-off values of distal forearm bone density for the diagnosis of central osteoporosis in black postmenopausal South African women. *J Endocrinol Metab Diabetes S Afr*. 2012;17(2):78-83.
- Bouxsein ML, Parker RA, Greenspan SL. Forearm bone mineral densitometry cannot be used to monitor response to alendronate therapy in postmenopausal women. *Osteoporos Int*. 1999;10(6):505-509.

**How to cite this article:** Gautam KP, Cherian KE, Kapoor N, Thomas N, Paul TV. Utility and validation of bone mineral density measurements at forearm in predicting trabecular microarchitecture and central-site osteoporosis in aging Indian postmenopausal women—a promising surrogate? *Aging Med*. 2022;5:30-37. doi:[10.1002/agm2.12191](https://doi.org/10.1002/agm2.12191)