

Single Case – General Neurology

# Probable Creutzfeldt-Jakob Disease Presenting Dementia and Urinary Retention

Yosuke Aiba<sup>a</sup> Ryuji Sakakibara<sup>a</sup> Ayako Imura<sup>a</sup> Chiaki Inoue<sup>a</sup>  
Keiichiro Terayama<sup>a</sup> Keiko Suzuki<sup>b</sup> Shuichi Katsuragawa<sup>b</sup>  
Fuyuki Tateno<sup>a</sup> Tsuyoshi Ogata<sup>a</sup>

<sup>a</sup>Dementia Support Team, Sakura Medical Center, Toho University, Sakura, Japan;

<sup>b</sup>Incontinence/Retention Care Team, Sakura Medical Center, Toho University, Sakura, Japan

## Keywords

Creutzfeldt-Jakob disease · Urinary retention · Alzheimer's disease

## Abstract

We describe the case of an 80-year-old woman with probable Creutzfeldt-Jakob disease (CJD) presenting dementia and urinary retention. Although the number of patients previously examined, including ours, is small for conclusion, provided that other etiologies of urinary retention are carefully excluded, urinary retention seems to become a feature in CJD, presumably reflecting spinal cord pathology in CJD. Physicians are advised to evaluate pelvic floor function in CJD particularly by checking post-void residuals.

© 2020 The Author(s)  
Published by S. Karger AG, Basel

## Introduction

Urinary retention has not been a feature in Creutzfeldt-Jakob disease (CJD) thus far. In contrast, recent reports [1, 2] have suggested that urinary retention can be a feature in CJD, presumably reflecting spinal cord pathology in CJD [3]. Here, we add such a case.

## Case Report

An 80-year-old active woman, without family history, was referred to our clinic because of a 3-month history of mild cognitive impairment and gait problem. For the past 2 years, she experienced mild nocturnal urinary frequency (none to twice a night) but no difficulty in urination. She had regular bowel movement (7 times a week) without difficulty. She underwent a Mini-Mental State Examination (MMSE) at a local clinic and scored 20/30 (normal >24). While she had no rigidity or tremor, she had mild gait festination on walking but without wide base. She had no ataxia, myoclonus, apraxia, visual hallucination, or other neurological abnormalities. She had no autonomic symptoms such as overactive bladder, postural dizziness, constipation, or sleep apnea/stridor. Laboratory examinations were normal. T1- and 2-weighted images of a brain magnetic resonance imaging (MRI) scan showed mild hippocampal atrophy with moderate white matter lesions. At this moment, she was suspected of having Alzheimer's disease (AD) with a vascular component.

However, soon after that, she developed urinary retention with a large post-void residual of 300 mL. Urine infection, pelvic organ prolapse, hematuria, or pain were not observed. An indwelling Foley catheter was inserted. Since urinary retention in AD is extremely rare, and urinary retention in women is also rare, we performed a workup in order to explore the etiology of her urinary retention [4]. Neurological examination of the lower half of the body, including the perineal area, was normal. She had no pelvic organ prolapse. Spinal/pelvic MRI and a nerve conduction study were normal. While she did not undergo urodynamic study, considering two previous reports [1, 2], CJD has been listed as a cause of urinary retention. Parallel with this, her MMSE score declined to 13/30 and slight myoclonus in posture was observed. Electroencephalography showed frontal-dominant periodic synchronized discharges. Diffusion-weighted MRI images showed diffuse cortical ribbon-like lesions (Fig. 1) [5], while the cerebrospinal fluid (CSF) 14–3–3 protein was negative (CSF tau and gene test was not performed). The above clinical features led to the diagnosis of possible CJD in this case. At that time, she became constipated and needed occasional enema. She was able to communicate to some extent and to maintain self-possession, until she was referred to another hospital.

## Discussion

Our case raises two clinical issues. The first issue is that the clinical features of older-age onset CJD mimic those of AD. Most CJD occurs at the age of 60–80 years. However, CJD at age >80 years may lack myoclonus and ataxia that are frequently observed in those aged 60–80 years [5, 6]. Of 6,000 clinically diagnosed AD patients, 7 (0.12%) proved to be clinically unsuspected, pathology-verified CJD [7]. Therefore, we should not miss such a case in memory clinics.

The second issue is that urinary retention can be a feature in CJD. Previous reports of a typical form [1] and spinal predominant form [2] of CJD reported that urinary retention did occur. These findings are in clear contrast with the evidence that urinary retention in AD is extremely rare, provided that other etiologies of urinary retention are carefully excluded. Other common etiologies of urinary retention in the elderly include prostate hypertrophy in men, pelvic organ prolapse in women, and diabetic neuropathy and lumbar spondylosis in both men and women. Our case did not have any of these etiologies. After excluding these etiologies, Yano et al. [1] further urodynamically examined two CJD cases. Case 1 (a 67-year-

old man) had typical acute cognitive deterioration with urinary retention that needed a Foley catheter, while case 2 (a 62-year-old woman) had subacute cognitive deterioration (that started after admission) and nocturia. Urodynamic features of these cases are detrusor overactivity during bladder filling, detrusor underactivity during voiding (inconclusive), decreased bladder sensation, and neurogenic change in the motor unit potentials of external sphincter electromyogram (EMG). These urodynamic findings are in accordance with the reported pathology in CJD, e.g., an involvement of the anterior horn, Clarke's column, intermediolateral column, and posterior column [3].

Although the number of patients examined is too small for conclusion, provided that other etiologies of urinary retention are carefully excluded, urinary retention seems to become a feature in CJD. Therefore, physicians are advised to evaluate pelvic floor function in CJD particularly by checking post-void residuals.

### Statement of Ethics

This study was conformed to the Ethical Standards of Helsinki and approved by the Ethics Committee of the Sakura Medical Center, Toho University. The patient's family has given written informed consent to publish this case (including publication of images).

### Disclosure Statement

The authors have no conflicts of interest to disclose.

### Funding Sources

No funding was received.

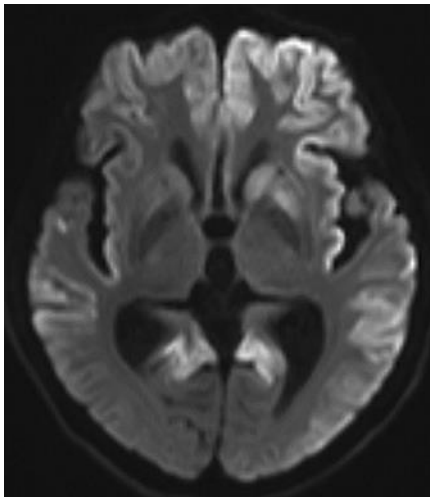
### Author Contributions

Aiba Y. participated in the acquisition, analysis, and interpretation of data. Sakakibara R. participated in the study concept and design, acquisition of data, analysis, and manuscript editing. Iimura A. participated in the acquisition of data. Inoue C. participated in the acquisition of data. Terayama K. participated in the acquisition of data. Suzuki K. participated in the acquisition of data. Katsuragawa S. participated in the acquisition of data. Tateno F. participated in the acquisition of data. Ogata T. participated in the acquisition of data.

### References

- 1 Yano M, Sakakibara R, Tateno F, Takahashi O, Nakamura H, Sugiyama M, et al. Urodynamic findings in patients with Creutzfeldt-Jakob disease: a case report. *Int Urol Nephrol*. 2016 Oct;48(10):1579–83.
- 2 Grant D, Loomis S. Progressive neurodegenerative disease in presumed spinal cord injury: case report of a patient with prion disease. *J Spinal Cord Med*. 2003;26(3):259–61.
- 3 Iwasaki Y, Yoshida M, Hashizume Y, Kitamoto T, Sobue G. Neuropathologic characteristics of spinal cord lesions in sporadic Creutzfeldt-Jakob disease. *Acta Neuropathol*. 2005 Nov;110(5):490–500.

- 4 Nakamura H, Sakakibara R, Sugiyama M, Tateno F, Yano M, Takahashi O, et al. Neurologic diseases that cause female urinary retention. *Bladder (San Franc)*. 2016;3(1):20.
- 5 Maddox RA, Blase JL, Mercaldo ND, Harvey AR, Schonberger LB, Kukull WA, et al. Clinically unsuspected prion disease among patients with dementia diagnoses in an Alzheimer's disease database. *Am J Alzheimers Dis Other Demen*. 2015 Dec;30(8):752–5.
- 6 Brandel JP, Salomon D, Hauw JJ, Haïk S, Alperovitch A. [Creutzfeldt-Jakob disease in patients before and after 80 years of age]. *Psychol Neuropsychiatr Vieil*. 2008 Sep;6(3):219–24. French.
- 7 Fragoso DC, Gonçalves Filho AL, Pacheco FT, Barros BR, Aguiar Littig I, Nunes RH, et al. Imaging of Creutzfeldt-Jakob disease: imaging patterns and their differential diagnosis. *Radiographics*. 2017 Jan-Feb;37(1):234–57.



**Fig. 1.** Diffusion-weighted image of a brain MRI scan of the patient. Diffuse cortical ribbon-like lesions that are typical of CJD were seen. She also lacked occipital lobe involvement.