

## Oncology

Urinary Bladder Leiomyosarcoma: Primary Surgical Treatment<sup>☆</sup>

Hakim Slaoui\*, Rafael Sanchez-Salas, Pierre Validire, Eric Barret, François Rozet, Marc Galiano, Xavier Cathelineau

Department of Urology, Institut Mutualiste Montsouris, 42 boulevard Jourdan 75014 Paris, France

## ARTICLE INFO

## Article history:

Received 7 May 2014

Accepted 8 May 2014

## Keywords:

Leiomyosarcoma

Nonurothelial bladder tumor

## ABSTRACT

Cases of bladder leiomyosarcoma represent 0.1% of all nonurothelial tumors. We present a case report of a 73-year-old man who underwent a radical cystoprostatectomy for a high-grade bladder leiomyosarcoma with an ileal diversion. The patient recovered uneventfully and no surgical margins were verified in final pathology. Early follow-up at 3 months shows no signs of computed tomography recurrence and adequate adaptation to ileal diversion. Although bladder sarcomas were once thought to have a grim prognosis, recent studies suggest that adequate surgical treatment is able to achieve optimal cancer control outcomes.

© 2014 The Authors. Published by Elsevier Inc. All rights reserved.

## Introduction

Nonurothelial neoplasms of the bladder account for <5% of all bladder tumors. Urinary bladder leiomyosarcoma is a very rare disease with few cases reported in literature. Given its scarcity, little is known about its etiology and consensus is lacking on therapeutic management. Herein, we present the case of a patient diagnosed with a bladder leiomyosarcoma and treated with radical cystoprostatectomy and ileal diversion.

## Case presentation

A 73-year-old man with medical history of hypertension and a transurethral resection of the prostate consulted for gross hematuria. The patient did not have history of any radiotherapy or chemotherapy treatment. Physical examination revealed a suspicious pelvic mass. A contrast-enhanced computed tomography (CT) scan showed a well-defined, heterogeneous, enhancing endophytic, 5-cm bladder tumor on the right anterior wall with no upper tract obstruction (Fig. 1).

The patient underwent a complete transurethral resection of the tumor. Surgical pathology showed a possible sarcomatoid carcinoma without excluding the possibility of a bladder leiomyosarcoma. Thoracic CT scan and bone scintigraphy were normal. Patient was referred to our institution, where radical surgical

treatment was indicated. The patient underwent a laparoscopic radical cystoprostatectomy with ileal conduit urinary diversion and an extended pelvic lymph node dissection. Final pathologic examination showed an invasive 6-cm high-grade myxoid leiomyosarcoma (Figs. 2, 3) with negative surgical margins and no lymph node metastasis (0/12).

On postoperative day 8, the patient was reoperated because of evisceration without any significant abdominal finding. The patient recovered uneventfully and experienced complete resolution of his urologic symptoms. The follow-up CT scan 3 months after surgery showed no sign of recurrence.

## Discussion

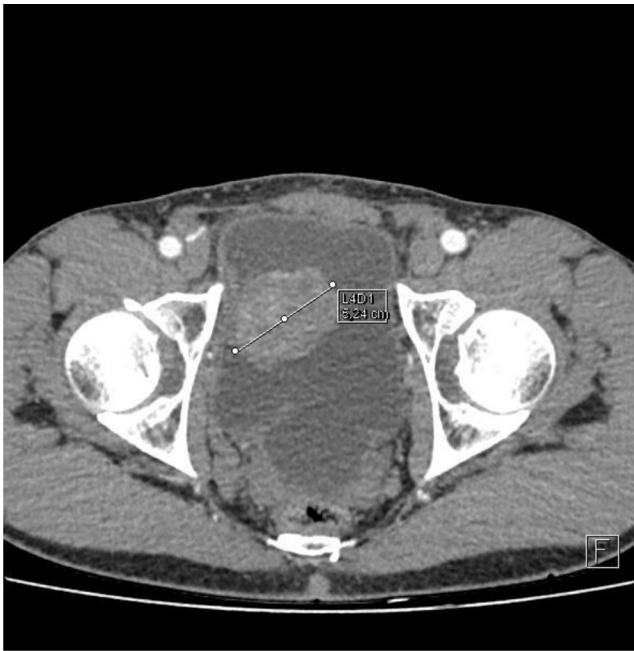
Only about 100 cases of bladder leiomyosarcoma have been reported in the literature, which represent 0.1% of all nonurothelial tumors.<sup>1</sup> Sarcoma constitutes the most usual mesenchymal malignancy of the bladder with leiomyosarcomas being the most common type of sarcomas in adults.<sup>2</sup> Gross hematuria is the most common presenting symptom with more than 80% of the cases.<sup>1,3</sup> There is strong evidence that the incidence of leiomyosarcomas is increased in patients receiving pelvic radiotherapy or systemic chemotherapy such as cyclophosphamide.<sup>2,3</sup> On the other hand, tobacco use seems not to increase the incidence of bladder leiomyosarcomas.<sup>2</sup>

There is no general consensus on the treatment, but it is considered as a highly aggressive entity that requires an aggressive surgical extirpation with wide margins. The best prognostic factor is the presence of tumor-free margins.<sup>1,2,4</sup> In the 1992 Memorial Sloan-Kettering Cancer Center study examining adult urologic sarcomas, Russo et al<sup>4</sup> included other favorable prognostic

<sup>☆</sup> This is an open access article under the CC BY-NC-ND license (<http://creativecommons.org/licenses/by-nc-nd/3.0/>).

\* Corresponding author. Tel.: +33 627239905; fax: +33 156616640.

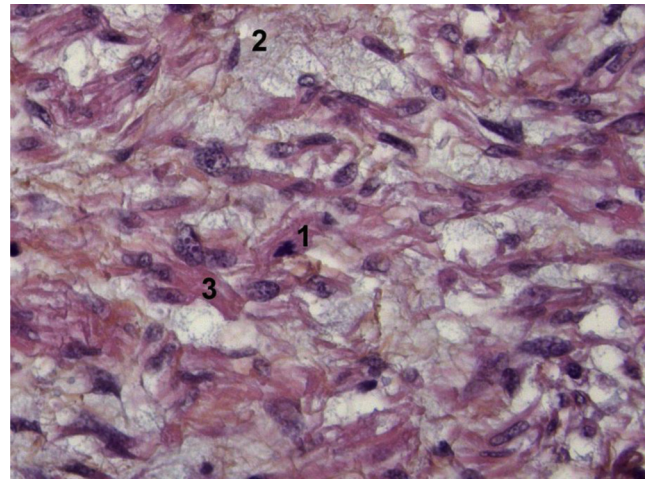
E-mail address: [slaoui7hakim@gmail.com](mailto:slaoui7hakim@gmail.com) (H. Slaoui).



**Figure 1.** Computed tomography of the pelvis with intravenous contrast showing the mass on the right anterior part of the bladder.

variables, such as a tumor diameter of <5 cm, low histologic grade, and paratesticular or bladder tumor site. The Memorial Sloan-Kettering Cancer Center sarcoma staging was able to predict survival in these patients, suggesting a behavioral similarity between urologic sarcomas and other soft tissue sarcomas.

The standard surgical technique (en bloc removal of the bladder with prostate and seminal vesicles in men and the uterus, cervix, and vaginal cuff in women, including a bilateral pelvic lymph node dissection) may result in low rates of positive surgical margins and low rates of local tumor recurrence. It is also recommended to completely remove the urachus and perivesical fat enveloping the upper hemisphere of the bladder.<sup>4</sup> Patients with locally advanced disease might benefit from neoadjuvant chemotherapy which would ultimately allow a radical surgery.<sup>5</sup> Minimally invasive



**Figure 3.** Histologic appearance of myxoid leiomyosarcoma of the bladder. Hematoxylin-eosin stain  $\times 630$ . 1, Abnormal mitosis; 2, moderately differentiated leiomyosarcoma with a fascicular growth pattern; 3, pools of hyaluronic acid showing the myxoid character.

treatment such as transurethral resection and adjuvant chemoradiation is an alternative for patients refusing a radical treatment and must be used for patients with small tumors. Partial cystectomy with sole resection of the mass should be considered as a palliative treatment and is only possible with certain locations of the tumor.<sup>1,2</sup>

Contemporary studies suggest that these tumors may have a better prognosis with 5-year disease-specific survival rates of 84% making bladder leiomyosarcoma survival rates better than the rates for patients with sarcomas of other organs.<sup>4</sup> The overall local recurrence rate is about 16% and most recurrences are seen in the pelvis.<sup>1,2</sup> Local recurrences should be treated with systemic chemotherapy and/or pelvic external radiotherapy.<sup>2</sup> Although bladder sarcomas were once thought to have a grim prognosis, it seems that some patients are able to achieve long-term survival, especially if an adequate surgical approach is deployed as primary treatment.

## Conclusion

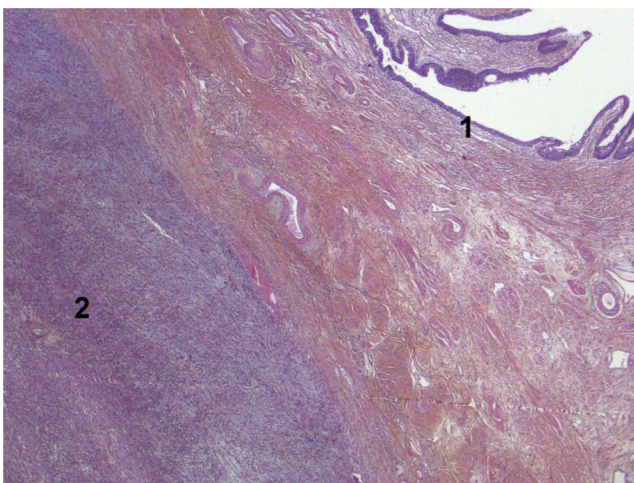
Leiomyosarcomas of the bladder have always been considered as a highly aggressive disease with poor prognosis. We present the case of a high-grade myxoid leiomyosarcoma primarily treated with minimally invasive surgery and harboring negative margins in final pathology. Recent studies suggest that radical surgery results in low rates of positive margins and low rates of local tumor recurrence.

## Conflict of interest

The authors declare that they have no conflicts of interest.

## References

- Gupta DK, Singh V, Sinha RJ, et al. Leiomyosarcoma, a nonurothelial bladder tumor: a rare entity with therapeutic diversity. *Korean J Urol.* 2013 Jun;54:409–411.
- Labanaris AP, Zugar V, Meyer B, et al. Urinary bladder leiomyosarcoma in adults. *Int Urol Nephrol.* 2008;40:311–316.
- Parekh DJ, Jung C, O'Conner J, et al. Leiomyosarcoma in urinary bladder after cyclophosphamide therapy for retinoblastoma and review of bladder sarcomas. *Urology.* 2002 Jul;60:164.
- Russo P, Brady MS, Conlon K, et al. Adult urological sarcoma. *J Urol.* 1992 Apr;147:1032–1036.
- Rosser CJ, Slaton JW, Izawa JI, et al. Clinical presentation and outcome of high-grade urinary bladder leiomyosarcoma in adults. *Urology.* 2003 Jun;61:1151–1155.



**Figure 2.** Histologic appearance of myxoid leiomyosarcoma of the bladder. Hematoxylin-eosin stain  $\times 25$ . 1, Normal urothelium; 2, massive invasion of the muscularis propria.