



Since January 2020 Elsevier has created a COVID-19 resource centre with free information in English and Mandarin on the novel coronavirus COVID-19. The COVID-19 resource centre is hosted on Elsevier Connect, the company's public news and information website.

Elsevier hereby grants permission to make all its COVID-19-related research that is available on the COVID-19 resource centre - including this research content - immediately available in PubMed Central and other publicly funded repositories, such as the WHO COVID database with rights for unrestricted research re-use and analyses in any form or by any means with acknowledgement of the original source. These permissions are granted for free by Elsevier for as long as the COVID-19 resource centre remains active.

# The role of penicillin in benign skin rashes in childhood: A prospective study based on drug rechallenge

Jean-Christoph Caubet, MD,<sup>a</sup> Laurent Kaiser, MD,<sup>b</sup> Barbara Lemaître, MS,<sup>b</sup> Benoît Fellay, PhD,<sup>c</sup> Alain Gervais, MD,<sup>a</sup> and Philippe A. Eigenmann, MD<sup>a</sup> *Geneva and Fribourg, Switzerland*

**Background:** Delayed-onset urticarial or maculopapular rashes are frequently observed in children treated with  $\beta$ -lactams. Many are labeled “allergic” without reliable testing.

**Objective:** Determine the etiology of these rashes by exploring both infectious and allergic causes.

**Methods:** Children presenting to the emergency department with delayed-onset urticarial or maculopapular rashes were enrolled. Acute and convalescent sera were obtained for viral screening along with a throat swab. Subjects underwent intradermal and patch skin testing for  $\beta$ -lactams 2 months after presentation. Anti- $\beta$ -lactam blood allergy tests were also obtained. All subjects underwent an oral challenge test (OCT) with the culprit antibiotic.

**Results:** Eighty-eight children were enrolled between 2006 and 2008. There were 11 (12.5%) positive intradermal and no positive patch tests. There were 2 (2.3%) positive blood allergy tests. There were 6 (6.8%) subjects with a positive OCT, 2 were intradermal-negative, and 4 were intradermal-positive. No OCT reactions were more severe than the index event. Most subjects had at least 1 positive viral study, 54 (65.9%) in the OCT negative group.

**Conclusion:** In this situation,  $\beta$ -lactam allergy is clearly overdiagnosed because the skin rash is only rarely reproducible (6.8%) by a subsequent challenge. Viral infections may be an important factor in many of these rashes. OCTs were positive in a minority of intradermal skin test–positive subjects. Patch testing and blood allergy testing provided no useful information. OCTs should be considered in all children who develop a delayed-onset urticarial or maculopapular rash during treatment with a  $\beta$ -lactam. (*J Allergy Clin Immunol* 2011;127:218-22.)

**Key words:** Drug allergy, virus, skin rash, children, penicillin,  $\beta$ -lactam, cephalosporin, oral challenge, skin test, blood allergy test

## Abbreviations used

CMV:	Cytomegalovirus
EBV:	Epstein-Barr virus
HHV6:	Human herpes virus 6
MDM:	Minor determinant mixture
OCT:	Oral challenge test
PPL:	Penicilloyl-polylysine

Antibiotics are the most frequent drugs prescribed in children worldwide. The  $\beta$ -lactams are the most prescribed group of antibiotics, with somewhere between 3.6 g and 23 g per 1000 people per day prescribed in Europe.<sup>1</sup> In children treated with  $\beta$ -lactams, skin rashes, mostly described as maculopapular or urticarial, are frequently reported by primary care physicians.<sup>2</sup>

Such rashes are frequently assumed to be a drug-related allergy, although viral infection is also often considered on the differential diagnosis.<sup>3</sup> It has been suggested that most of these rashes are actually not allergic in origin.<sup>4,5</sup> However, in clinical practice, the large majority of these children are labeled “penicillin-allergic” without appropriate testing, mostly for fear of a more severe allergic reaction. Most of the time, this diagnosis persists until adulthood. As a result, they may be denied the optimal antimicrobial coverage of first choice antibiotic treatment and are often treated with a more costly antibiotic. On average, prescription costs are 30% to 40% higher in patients with a suspected penicillin allergy.<sup>6</sup>

Currently, clear figures on the rate of true penicillin allergy among children who develop a rash during  $\beta$ -lactam treatment, and a useful investigational protocol for these patients, are lacking. Several immunologic mechanisms can cause allergy to  $\beta$ -lactams. Identification of IgE-mediated allergy, with its potential for anaphylactic, life-threatening reaction, is essential. This type of reaction generally occurs within 1 hour of receiving the medication and is classified as an immediate reaction.<sup>7</sup> The incidence of these potentially severe reactions is very low (1/100,000).<sup>8</sup> Nonimmediate reactions, which usually manifest as maculopapular or urticarial rashes, occur more than 1 hour after drug intake<sup>9</sup> and are far more common. It is suspected that these rashes are T-cell-mediated.<sup>10</sup>

Currently, the diagnosis is mostly assessed by using skin tests (to exclude an IgE-mediated allergy), and in negative skin test patients an oral challenge test (OCT), considered the gold standard, is occasionally performed.<sup>9</sup> Better diagnosis in children with suspected penicillin allergy would directly benefit affected children, provide better treatment guidance for their physicians, and might contribute to lower health costs.

The primary aim of our study was to investigate infectious and allergic causes of urticarial or maculopapular skin rashes in children treated with  $\beta$ -lactams. Our secondary objective was to evaluate the diagnostic accuracy of allergy tests.

From <sup>a</sup>the Department of Child and Adolescent, and <sup>b</sup>the Laboratory of Virology, Division of Infectious Diseases and Division of Laboratory Medicine, University Hospitals of Geneva and Medical School of the University of Geneva; and <sup>c</sup>the Cantonal Hospital of Fribourg, Central Laboratories.

Supported by a Geneva University Hospitals Research & Development Award #06-L-7 and in part by a Swiss National Foundation research grant (3200B-101670).

Disclosure of potential conflict of interest: L. Kaiser has received research support from the Swiss National Foundation. P. A. Eigenmann has received speakers' honoraria from Phadia. The rest of the authors have declared that they have no conflict of interest. Received for publication November 4, 2009; revised July 16, 2010; accepted for publication August 9, 2010.

Available online October 28, 2010.

Reprint requests: Philippe A. Eigenmann, MD, Hôpitaux Universitaires de Genève, Département de Pédiatrie, 6 rue Willy-Donzé, CH-1211 Genève 14, Switzerland. E-mail: Philippe.Eigenmann@hcuge.ch.

0091-6749/\$36.00

© 2010 American Academy of Allergy, Asthma & Immunology  
doi:10.1016/j.jaci.2010.08.025

## METHODS

### Patients and study setting

This prospective observational study included consecutive children referred for evaluation of possible  $\beta$ -lactam allergy to the Pediatric Emergency Department of the Geneva University Hospitals from 2006 to 2008. The study was approved by the Ethics Committee of the Geneva University Hospitals, Switzerland.

The study subjects were between 0 and 16 years old, with an urticarial or maculopapular rash during or up to 72 hours after treatment with a  $\beta$ -lactam antibiotic. Patients with rashes clearly suggestive of childhood infectious diseases (rubella, measles, chicken pox, scarlet fever) or related to potentially severe reactions (Stevens Johnson or Lyell syndrome, Drug Rash with Eosinophilia and Systemic Symptoms, anaphylaxis with respiratory or cardiovascular involvement) were excluded.

### Procedures

The investigation was conducted in 3 steps (Fig 1).

At the inclusion visit, patients underwent clinical evaluation composed of a medical history and physical examination, and pictures of the skin lesions were taken. Urticaria was defined as disseminated, rapidly evolving, and transient itchy wheals with individual lesions lasting less than 24 hours. A maculopapular rash was defined as small confluent erythematous maculae or papules persisting more than 24 hours, also disseminated over different parts of the body. Blood was drawn to measure for antibodies to viruses known to be associated with childhood skin rashes (Epstein-Barr virus [EBV], human herpes virus 6 [HHV6], cytomegalovirus [CMV], parvovirus B19). All patients also had a throat swab for respiratory virus screening by PCR according to previously published methods.<sup>11,12</sup> Viruses screened for via throat swab included picorna, corona, human metapneumovirus, bocavirus, influenza, and parainfluenza viruses.<sup>13</sup>

During the second visit (2 months later), a second determination of viral serologies (EBV, CMV, HHV6, and parvovirus B19) was performed, and all patients underwent a complete allergy work-up following European Network for Drug Allergy/European Academy of Allergy and Clinical Immunology guidelines for work-up of subjects with a suspicion of nonimmediate reaction to  $\beta$ -lactams.<sup>9</sup> Intradermal skin tests were performed on the forearm with penicilloyl-polylysine (PPL) and minor determinant mixture (MDM; Diater, Madrid, Spain) with a standard concentration, and with amoxicillin (Clamoxyl; GlaxoSmithKline, Munchenbuchsee, Switzerland), at a concentration of 25 mg/mL after dilution in 0.9% NaCl. On the basis of our experience and to limit painful skin testing, we did not perform a first test at a lower concentration than 25 mg/mL. If a cephalosporin was incriminated, the work-up was completed with an intradermal skin test to the soluble form of the suspected drug if available (ie, ceftriaxone; Rocephin; Roche Pharma, Basle, Switzerland; and cefuroxime; Zinacef; GlaxoSmithKline; both at concentrations of 3 mg/mL).<sup>3</sup> Skin test responses were assessed at 15 to 20 minutes. A wheal equal or superior than 3 mm in diameter in the absence of a wheal to the control solution (diluent; Diater) and in the presence of a positive response to histamine (skin prick test, 10 mg/mL) was defined as an immediate positive response. Patch test solutions were prepared by mixing the incriminated drug in petrolatum at a concentration of 5%.<sup>9</sup> Negative controls were performed with petrolatum alone in each individual tested. All reagents were applied to uninvolved skin on the interscapular region of the patient's back by using acrylate adhesive strips with small plates attached for test allergens (IQ ultra chambers; Dormer Laboratories, Rexdale, Ontario, Canada).

Before skin testing, blood samples were taken from all subjects. *In vitro* assays for antigen-specific IgE to penicilloyl G, penicilloyl V, and amoxicillin were performed by using UniCAP (Phadia AB, Uppsala, Sweden). Specific IgE was considered negative when the result was below 0.1 kU/L.

An OCT with the implicated  $\beta$ -lactam drug was performed in all children under strict hospital surveillance by a physician with full resuscitation backup. The OCT protocol was adapted to the results of the skin tests, as follows:

1. If the intradermal skin tests were all negative, the patient received 150% of the therapeutic dose (calculated by weight) at once. This amount was given to provide a safety margin for exclusion of reactions only occurring with a higher dose.

2. If any skin tests were positive, an initial dose of 50% of the therapeutic dose was administered. If no reaction appeared, 30 minutes later, the remaining 100% of the therapeutic dose was given. All patients were observed for 2 hours after the last dose. The involved drug, at the therapeutic dose, was given at home for a further 48 hours to all the patients without immediate reactions.

A third visit occurred 2 days later for patch test and late intradermal skin test reading. The patch tests were read 15 minutes after removal of the strips and graded as recommended.<sup>9</sup>

### Statistical analysis

The sample size was calculated to control the accuracy (the length of the 95% CI) on the estimate of the proportion of real allergic reactions in children developing a rash during a  $\beta$ -lactam treatment (primary endpoint).<sup>14</sup> On the basis of rates described in previous studies<sup>5</sup> and to obtain a 95% CI of 1% to 11% around an expected prevalence of 6%, the sample size required was calculated to be  $N = 87$ . Patient characteristics were described by median and range or by frequencies. The 95% CIs of the proportions were calculated by using the exact method of Clopper-Pearson. The rate of positive OCTs was compared to the intradermal test by using a Fisher exact test. The sensitivities, specificities, positive and negative predictive values of intradermal skin tests, patch tests, and specific IgE were also assessed in all patients and in the subgroups tested with cephalosporins and penicillins, and given with the 95% CIs.

## RESULTS

Characteristics of the patients are listed in Table I. A total of 88 children (44 girls and 44 boys) with an average age of 3.5 years (range, 0.5-14.5) completed all 3 visits of the study. Twenty patients did not agree to the allergy work-up, mostly because of fear of pain from intradermal skin tests. The initial reactions in these patients were comparable to those who completed the study. As required by the inclusion criteria, all the recruited patients initially presented with a mild nonimmediate reaction, occurring by definition more than 1 hour after the last dose.

The culprit antibiotic was amoxicillin in 43 patients (48.9%), amoxicillin-clavulanic acid in 34 patients (38.6%), and a cephalosporin in 11 patients (12.5%). In most cases, the drug was administered orally; only 2 patients received it parenterally (2.3%). The skin reaction was diagnosed as predominantly urticarial in 47 patients (53.4%) and as predominantly maculopapular in 41 patients (46.6%). The rash appeared an average of 4.9 days (SD, 3.4 days) after initiation of treatment and lasted for a mean of 3.8 days (SD, 3.7 days).

The second visit occurred an average of 10.8 weeks (SD, 3.8 weeks) after the index event. Intradermal skin tests were positive in 11 of the 88 tested patients (12.5%), with a wheal size greater than 5 mm in all patients. An OCT with the incriminated drug was carried out in a total of 88 patients. A reaction was reproduced in 6 patients (1 with amoxicillin, 3 with amoxicillin-clavulanic acid, and 2 with cephalosporin; Table II). The skin rashes observed after OCT were all similar to the initial ones. The reaction was immediate (30 minutes) in 1 patient and delayed in the others (mean, 9 hours; range, 7-12 hours). Only 4 of the 6 subjects who went on to have a positive OCT displayed immediate positive responses to skin test reagents (Table III). However, patients with positive intradermal tests did have a higher rate of positive OCTs than those without ( $P < .05$  by Fisher exact test). The overall sensitivity determined for intradermal skin testing was 66.7%, and the specificity was 91.5%. The intradermal skin test in the subgroup of patients with an urticarial reaction displayed a sensitivity of 75% and a specificity of 97.3%, whereas in patients who developed a

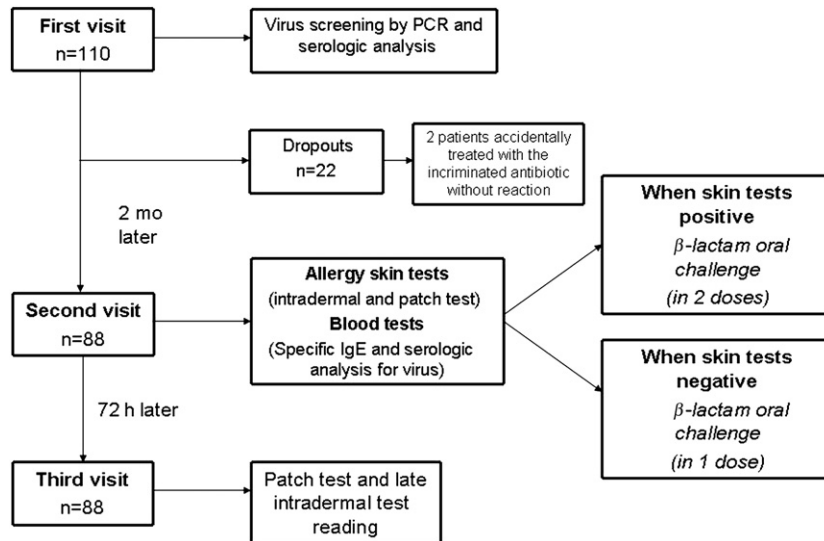


FIG 1. Trial profile.

maculopapular rash, the sensitivity was 50% and the specificity was 86.7%. Patch tests and delayed intradermal skin tests were negative in all 88 tested patients, including the 6 patients with positive OCTs. Serum specific IgE antibody titers to  $\beta$ -lactams were negative ( $<0.1$  kU/L) in 86 of 88 patients. Only 2 patients, both of whom had negative OCTs, had specific IgE higher than 0.1 kU/L, and both were below 0.35 kU/L. A history of allergy was equally prevalent in the personal and family histories of children with positive and negative OCTs.

The results of the screening for a viral infection by PCR and serum antibody testing are presented in Table IV. A viral trigger for the initial rash was suspected in most of the patients with a negative OCT [54/82; 65.9%]. The viruses most frequently identified were enteroviruses (picornavirus). Interestingly, 3 of the patients with a positive OCT (50%) had findings suggestive of an acute EBV infection or of a recent EBV infection (less than 3 months before testing). An acute EBV infection was also identified in 3 patients with a negative OCT (3.7%).

## DISCUSSION

In this prospective study, we aimed to find the cause of the rash children presented during a treatment with  $\beta$ -lactam drugs and to determine the risk of developing a similar rash on rechallenge with the same antibiotic. To our knowledge, this is the first prospective study of drug allergy prevalence in which all subjects, regardless of skin test outcome, were rechallenged. In this study, a rash was reproduced on OCT in only 6 of 88 challenged patients (6.8%; 95% CI, 2.5-14.2). These findings are highly relevant to clinical practice because most of these patients would otherwise have been falsely labeled "penicillin-allergic."

Rashes are frequent in childhood, with an estimated incidence of approximately 150 cases per 10,000.<sup>15</sup> There are many potential causes of pediatric rashes, especially among children with an intercurrent illness being treated with antibiotics. Viral infections are the most common cause of maculopapular or urticarial eruptions, independent of medication. The rate of exanthema in viral infection is highly variable depending on the virus.<sup>13,16</sup> In our study, we screened for viruses most commonly known to be

TABLE I. Patient characteristics at the first visit (n = 88)

Age (y)	
Median	3.5
(Range)	(0.5-14.5)
Sex, n (%)	
Male	44 (50)
Female	44 (50)
Type of infections, n (%)	
Ear, nose, and throat	74 (84.1)
Others	14 (15.9)
Antibiotics, n (%)	
Amoxicillin	43 (48.9)
Amoxicillin-clavulanic acid	34 (38.6)
Cephalosporins	11 (12.5)
Type of skin rash, n (%)	
Maculopapular	41 (46.6)
Urticarial	47 (53.4)

associated with a rash by using PCR and serologic analysis. The vast majority of children with a negative subsequent OCT tested positive for viral infection, mostly enteroviruses (picornavirus), at their initial visit. These viruses could be the cause of the index rash in some of these patients. Similar to nonimmediate allergic reactions, viral-induced exanthemas are immunologically mediated, with T cells playing a central role. However, major differences have been shown in the immunologic mechanism suspected.<sup>17</sup> The negative viral screening results in patients with a subsequent negative OCT may be a result of limitations in testing technique or other infectious triggers, such as viruses not screened for, or bacterial infections.

An allergic reaction is a far more common cause for a rash after intake of a  $\beta$ -lactam antibiotic in adults than in children.<sup>4,5</sup> Reactions are referred to as drug allergy when immunologic mechanisms, either antibody-mediated or cell-mediated, can be demonstrated. By definition, these reactions are reproducible. In our study, this reproducibility was demonstrated in only a low proportion of patients (6.8%). Potentialization of a drug-related rash by the inflammatory reaction of an infection can certainly not be excluded. The pathogenesis of cutaneous drug reactions

**TABLE II.** Characteristics of patients with positive oral  $\beta$ -lactam challenge tests

Patient (no.)	Age (y)	Sex	Antibiotic	Antibiotic prescribed for	Type of initial rash	Intradermal skin test results	Delay between OCT and rash (h)	Tests positive for:
1	8.7	F	Cefaclor	Otitis	U	Positive to cefuroxime	0.5	Picornavirus
2	1.4	M	ACA	Otitis	U	Negative	12	EBV
3	8.4	M	ACA	Sinusitis	MP	Negative	11	EBV
4	8.5	M	ACA	Bronchitis	MP	Positive to MDM, PPL	8	—
5	1.7	M	AMX	Otitis	U	Positive to PPL	7	EBV
6	7	F	Cefprozil	Pharyngitis	U	Positive to cefuroxime	8	Picornavirus

ACA, Amoxicillin-clavulanic acid; AMX, amoxicillin; F, female; M, male; MP, maculopapular rash; U, urticarial rash.; —, no virus detected.

**TABLE III.** Results of intradermal skin testing

	OCT to penicillins		OCT to cephalosporins	
Patients, n (%)	77 (87.5)		11 (12.5)	
OCT results, n (%)	Negative 73 (94.8)	Positive 4 (5.2)	Negative 9 (81.8)	Positive 2 (18.2)
Intradermal skin testing results, n (%) (classified by the results of OCT and the antibiotic)	Positive* 6 (8.2)	Positive† 2 (5.0)	Positive‡ 1 (11.1)	Positive§ 2 (100)
	Negative 67 (91.8)	Negative 2 (5.0)	Negative 8 (88.9)	Negative 0 (0)
Value of intradermal skin testing:	50 (6.7-93.2), 91.8 (83-96.9)		100 (15.8-100), 88.9 (51.8-99.7)	
Sensitivity, % (95% CI), specificity, % (95% CI) PPV, % (95% CI), NPV, % (95% CI)	25 (3.2-65.1), 97.1 (89.9-99.6)		33.3 (0.8-90.6), 100 (63.1-100)	
	Results combining penicillins and cephalosporins			
	66.7 (22.2-95.7), 91.5 (83.2-96.5)			
	36.4 (10.9-69), 97.4 (90.9-99.7)			

NPV, Negative predictive value; PPV, positive predictive value.

\*Three patients were positive to PPL and MDM, 1 to PPL, 1 to amoxicillin, and 1 to PPL, MDM, and amoxicillin.

†One patient was positive to MDM and PPL and the other to PPL.

‡This patient was positive to PPL.

§These 2 patients reacted to cefuroxime.

during viral infections may involve viral-induced polyclonal activation of lymphocytes, other reactions involving cellular immunity, or alterations of drug metabolism.<sup>18</sup> EBV is the best known example of a viral risk factor for cutaneous drug reactions. Reactions in patients subsequently found to be infected with EBV are traditionally not considered to belong to drug allergies. An intriguing result of our study is that 3 of the 6 patients who had a positive OCT tested positive for an acute EBV infection. In these cases, the persistence of an EBV-induced inflammation could have favored the reaction induced by the OCT. It is also possible that EBV infections might change the pattern of reactivity to antibiotics, because persistent delayed-type reactions to amoxicillin, instead of the classic transient decrease in drug tolerance during EBV infection, have been reported.<sup>19</sup> Although these conclusions are speculative, they should encourage further investigations in patients with amino-penicillin-induced exanthema during EBV infection.

The diagnostic allergy work-up in patients who developed a rash remains controversial. We strongly emphasize that the patient's history is essential for confirming the diagnosis—for example, by using the ENDA questionnaire.<sup>20</sup> Although a recent study investigated diagnostic tests to differentiate between a viral and a drug-induced exanthema, no test has been validated so far.<sup>21</sup> The analysis of the diagnostic value of common allergy tests (skin tests and specific IgE) was hampered by the surprisingly low number of patients with a positive OCT. Our study does show a good specificity (91.5%) for intradermal skin tests but a sensitivity of only 66.7%, a number slightly higher than previously reported.<sup>22</sup> A low rate of reactions in skin test-positive patients after re-

exposure to the antibiotic has also been reported by others in a retrospective study.<sup>23</sup> Current guidelines suggest that immediate reading of intradermal skin tests should be done only in immediate reactions suspected to be IgE-mediated.<sup>9</sup> In our study, only 1 patient developed an immediate reaction. If immediate readings of intradermal tests were considered to predict only immediate reactions, the sensitivity would be even lower (16.7%), with a specificity of 87.8%. As in previous studies,<sup>24,25</sup> we found a very high negative predictive value for intradermal skin tests (97.4%).

Although T cells have clearly been demonstrated to play a role in nonimmediate reactions, patch tests were negative in all patients investigated here. This may be explained by the low sensitivity of these tests, as previously observed by others,<sup>9</sup> or by the low number of patients with a positive OCT. Serum specific IgE antibody titers to  $\beta$ -lactams were negative in all patients with a positive OCT, suggesting that IgE measurement in nonimmediate reactions is not useful.

The OCT remains the gold standard for the diagnosis of a drug allergy, and it should be emphasized that none of the 6 patients with a positive OCT developed a more severe reaction than the index event. A recent study in patients with a history of a nonlife-threatening allergic reaction to penicillin showed that positive penicillin skin tests were not associated with a higher rate of positive OCT to penicillin than negative skin test results.<sup>25</sup> These authors concluded that challenges should be performed only in patients in whom skin testing is not feasible. Our results suggest that we would have had to perform painful and time-consuming skin tests in 88 children to predict a positive challenge in only 4 patients. We demonstrate here that an OCT is the best diagnostic

**TABLE IV.** Results of viral tests in patients with positive and negative OCT

	Negative OCT	Positive OCT
No. of patients with 1 or more positive PCR (throat swab) for a virus screened	46/82 (56.1%)	2/6 (33.3%)
Viruses found positive by PCR	Picornavirus (n = 30), coronavirus (n = 6), bocavirus (n = 5), hMPV (n = 4), influenza A-B (n = 4), parainfluenza 1-3 (n = 3), respiratory syncytial virus (n = 6)	Picornavirus (n = 2)
No. of patients with a positive serum antibody test	13/82 (15.9%)	3/6 (50%)
Viruses found positive by serum antibody test	EBV (n = 3), HHV6 (n = 6), parvovirus (n = 2), CMV (n = 2)	EBV (n = 3)

tool in benign skin rashes in children. A complete allergy work-up (skin tests, specific IgE measurement, followed or not by an OCT) is required only in patients with a history suggesting anaphylaxis. Our protocol included a 2-step OCT to reduce the risk of an immediate, potentially severe allergic reaction in patients with positive skin tests. However, none of these patients developed an immediate and/or a severe reaction. Thus, a 1-dose OCT in patients with a history of a benign reaction can be considered safe. In the meantime, we have challenged more than 150 children in our referral clinic with the 1-dose protocol, followed by a 30-minute observation, without any significant reactions. Nevertheless, it needs to be emphasized that this procedure requires careful primary evaluation by an experienced allergist and cannot be performed in patients suspected of a more severe reaction.

In conclusion, in children who present with a benign skin rash in the absence of any other symptom while treated with  $\beta$ -lactams, we suggest performing a 1-dose initial OCT under medical supervision, followed by standard  $\beta$ -lactam dosing for 48 hours at home. This protocol has been proven to be safe and efficient for a work-up of possible reaction to antibiotics in children with a benign rash. By challenging all patients with benign rashes, we will avoid denying future use of  $\beta$ -lactam antibiotics to a large number of patients who would otherwise have been diagnosed with penicillin allergy.

We thank the Pediatric Clinical Research Platform nurses and staff for their excellent assistance. We also thank Trimedal (Bruttisellen, Switzerland) for kindly providing the test kits for intradermal skin testing and Phadia (Uppsalla, Sweden) for kindly providing the tests for specific IgE measurement. Methodologic support was provided by the Clinical Research Center, University of Geneva and Geneva University Hospitals (Christophe Combesure).

**Clinical implications: In children who develop a benign skin rash while on  $\beta$ -lactams, a physician-supervised OCT administered as 1 dose followed by standard dosing for 48 hours at home is a safe and efficient diagnostic procedure.**

#### REFERENCES

- Cars O, Molstad S, Melander A. Variation in antibiotic use in the European Union. *Lancet* 2001;357:1851-3.
- Adkinson NF, Jr. Risk factors for drug allergy. *J Allergy Clin Immunol* 1984;74:567-72.
- Romano A. Recognising antibacterial hypersensitivity in children. *Paediatr Drugs* 2000;2:101-12.
- Bierman CW, Pierson WE, Zeitz SJ, Hoffman LS, VanArsdel PP, Jr. Reactions associated with ampicillin therapy. *JAMA* 1972;220:1098-100.
- Ponvert C, Weilenmann C, Wassenberg J, Walecki P, Bourgeois ML, de Blic J, et al. Allergy to betalactam antibiotics in children: a prospective follow-up study in retreated children after negative responses in skin and challenge tests. *Allergy* 2007;62:42-6.
- MacLaughlin EJ, Saseen JJ, Malone DC. Costs of beta-lactam allergies: selection and costs of antibiotics for patients with a reported beta-lactam allergy. *Arch Fam Med* 2000;9:722-6.
- Torres MJ, Blanca M, Fernandez J, Romano A, Weck A, Aberer W, et al. Diagnosis of immediate allergic reactions to beta-lactam antibiotics. *Allergy* 2003;58:961-72.
- Idsoe O, Guthe T, Willcox RR, de Weck AL. Nature and extent of penicillin side-reactions, with particular reference to fatalities from anaphylactic shock. *Bull World Health Organ* 1968;38:159-88.
- Romano A, Blanca M, Torres MJ, Bircher A, Aberer W, Brockow K, et al. Diagnosis of nonimmediate reactions to beta-lactam antibiotics. *Allergy* 2004;59:1153-60.
- Blanca M, Posadas S, Torres MJ, Leyva L, Mayorga C, Gonzalez L, et al. Expression of the skin-homing receptor in peripheral blood lymphocytes from subjects with nonimmediate cutaneous allergic drug reactions. *Allergy* 2000;55:998-1004.
- Tapparel C, Junier T, Gerlach D, Van Belle S, Turin L, Cordey S, et al. New respiratory enterovirus and recombinant rhinoviruses among circulating picornaviruses. *Emerg Infect Dis* 2009;15:719-26.
- Garbino J, Soccia PM, Aubert JD, Rochat T, Meylan P, Thomas Y, et al. Respiratory viruses in bronchoalveolar lavage: a hospital-based cohort study in adults. *Thorax* 2009;64:399-404.
- Cherry JD. Cutaneous manifestations of systemic infections. In: Feigin RD, Cherry JD, Demmler-Harrison GJ, Kaplan SL, editors. *Textbook of pediatric infectious diseases*. 6th ed. Philadelphia: Saunders Elsevier; 2009. p. 755-80.
- Machin D, Campbell M, Fayers P, Pinol A. Sample size tables for clinical studies. In: Blackwell science. 2nd ed. Oxford: Blackwell Science 1997. p. 132.
- Vega AT, Gil CM, Rodriguez Recio MJ, de la Serna HP. [Incidence and clinical characteristics of maculopapular exanthemas of viral aetiology]. *Aten Primaria* 2003;32:517-23.
- Hope-Simpson RE, Higgins PG. A respiratory virus study in Great Britain: review and evaluation. *Prog Med Virol* 1969;11:354-407.
- Fernandez TD, Canto G, Blanca M. Molecular mechanisms of maculopapular exanthema. *Curr Opin Infect Dis* 2009;22:272-8.
- Cohen AD, Friger M, Sarov B, Halevy S. Which intercurrent infections are associated with maculopapular cutaneous drug reactions? a case-control study. *Int J Dermatol* 2001;40:41-4.
- Jappe U. Amoxicillin-induced exanthema in patients with infectious mononucleosis: allergy or transient immunostimulation? *Allergy* 2007;62:1474-5.
- Demoly P, Kropf R, Bircher A, Pichler WJ. Drug hypersensitivity: questionnaire. EAACI interest group on drug hypersensitivity. *Allergy* 1999;54:999-1003.
- Stur K, Karhofer FM, Stingl G. Soluble FAS ligand: a discriminating feature between drug-induced skin eruptions and viral exanthemas. *J Invest Dermatol* 2007;127:802-7.
- Blanca-Lopez N, Zapatero L, Alonso E, Torres MJ, Fuentes V, Martinez-Molero MI, et al. Skin testing and drug provocation in the diagnosis of nonimmediate reactions to aminopenicillins in children. *Allergy* 2009;64:229-33.
- Macy E, Burchette RJ. Oral antibiotic adverse reactions after penicillin skin testing: multi-year follow-up. *Allergy* 2002;57:1151-8.
- Langley JM, Halperin SA, Bortolussi R. History of penicillin allergy and referral for skin testing: evaluation of a pediatric penicillin allergy testing program. *Clin Invest Med* 2002;25:181-4.
- Goldberg A, Confino-Cohen R. Skin testing and oral penicillin challenge in patients with a history of remote penicillin allergy. *Ann Allergy Asthma Immunol* 2008;100:37-43.