

Available online at www.sciencedirect.com

ScienceDirect

journal homepage: www.elsevier.com/locate/radcr

Case Report

Clinical case of successful treatment of internal carotid artery dissection during aneurysm embolization in acute period of subarachnoid hemorrhage [☆]

Alexander V. Korotkikh, MD^{a,*}, Darya A. Korotkikh, MD^a, Dmitriy A. Nekrasov, MD^a, Anton A. Khilchuk, MD^{b,c}, Sergey G. Scherbak, MD, Doctor of Sciences, professor^c, Andrey M. Sarana, MD, PhD^c

^a Regional Vascular Center, Regional Clinical Hospital №2, Mel'nikaite str. 75, Tyumen 625039, Russian Federation

^b Department of Interventional Radiology, City Hospital №40, Sestroretsk, Saint-Petersburg, Russian Federation

^c Medical Faculty, Saint-Petersburg State University, Saint-Petersburg, Russian Federation

ARTICLE INFO

Article history:

Received 11 May 2020

Revised 17 May 2020

Accepted 17 May 2020

Keywords:

Dissection

Internal carotid artery

Subarachnoid hemorrhage

Aneurysms

Hemorrhage

ABSTRACT

Artery dissection during embolization of an intracranial aneurysm is not a frequent complication. In most cases, the tactics of treatment are limited to the appointment of anticoagulants or balloon angioplasty. We present a clinical case of successful treatment of a woman of 47 years. Dissection of the internal carotid artery occurred during aneurysm embolization in the acute period of subarachnoid hemorrhage and required coronary stent implantation. The absence in the long-term period of signs of restenosis or mechanical damage to the coronary stent in the installed position indicates the possibility of implanting it in the indicated position in urgent situations. The clinical significance of the described case consists in combining sequentially rarely occurring events one after another.

© 2020 The Authors. Published by Elsevier Inc. on behalf of University of Washington.

This is an open access article under the CC BY-NC-ND license.

(<http://creativecommons.org/licenses/by-nc-nd/4.0/>)

Introduction

Dissection of the internal carotid artery (ICA), as an independent pathology, is one of the main causes of cerebrovascular disease at a young age [1]. The main reason for dissection is arterial wall dysplasia, a provoking factor - head injury, usually

mild, movement in the cervical spine, uncomfortable static position of the head with its bend, turn or tilt, physical exertion with tension in the muscles of the neck, banal infection, contraceptive use by women [2-5]. When performing endovascular procedures, in particular embolization of an intracranial aneurysm, the cause of ICA dissection is a breakdown of intima by a catheter or guide. The frequency of occurrence

[☆] Competing Interests: The authors declare no conflict of interests.

* Corresponding author.

E-mail address: ssemioo@rambler.ru (A.V. Korotkikh).

<https://doi.org/10.1016/j.radcr.2020.05.038>

1930-0433/© 2020 The Authors. Published by Elsevier Inc. on behalf of University of Washington. This is an open access article under the CC BY-NC-ND license. (<http://creativecommons.org/licenses/by-nc-nd/4.0/>)

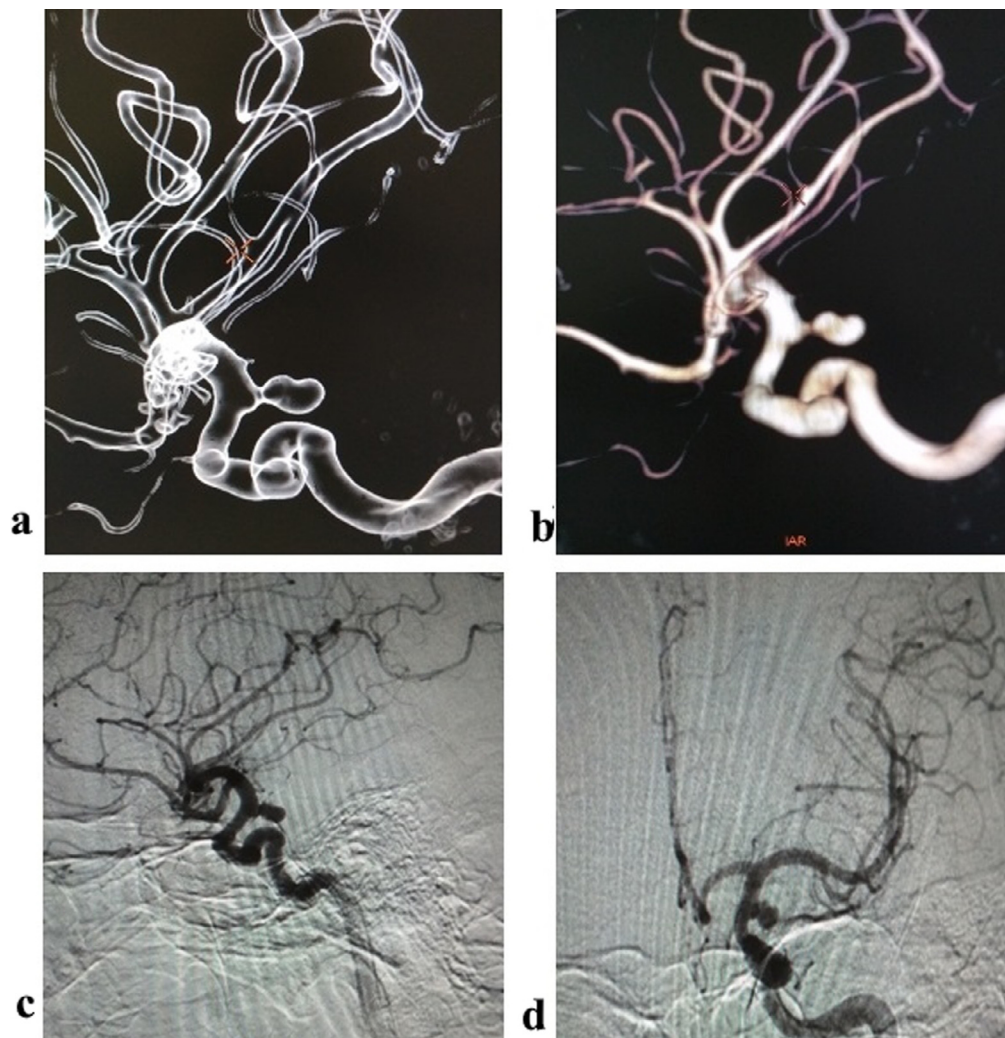


Fig. 1 – Cerebral angiograms, aneurysm of the left ICA: (a) and (b) 3D models in various processing; (c) lateral projection; (d) frontal projection.

according to domestic authors varies from 0.6% to 3.6% [6]. In most cases, with this complication, it is possible to confine oneself to anticoagulant therapy, but in a number of observations stent implantation at the dissection level is required [6].

Case report

Patient B, 47 years old, admitted to the emergency department with complaints of severe headache, nausea, and vomiting. These complaints were disturbed for 2.5 hours. Partial paresis of the oculomotor nerve and lowering of the eyelid on the left side appeared about 2 months ago. She treated and examined by an ophthalmologist at the place of residence. Upon admission, the patient was in serious condition, conscious, GCS 15 points, contact, compensated, hemodynamically stable. There was a neurological deficit in the form of headache, nausea, smoothness of the nasolabial fold on the right, weakening of convergence, partial paresis of the oculomotor nerve and ptosis of the eyelid on the left. Hunt-Hess 2 points.

The following data were obtained from computed tomography of the brain: subarachnoid hemorrhage, lamellar subdural hematoma on the left with a volume of up to 10 ml, displacement of the middle structures to the right up to 0.3 mm, aneurysm of the cerebral part of the ICA on the left with dimensions of 7.0×5.0 mm with a neck of 2.0 mm; Fischer–3.

The patient sedated after 6 hours from the onset of the disease in the Cath lab. Cerebral angiography performed through the right femoral access, where surgeon revealed an aneurysm of the mouth of the posterior connective artery of the left ICA basin with dimensions of 6.4×4.6 mm, neck 1.7 mm (Fig. 1).

Tracheal intubation performed after angiography, and inhalation anesthesia started. The 0.035" hydrophilic wire (Uni-Qual, Asahi) was inserted into the initial sections of the left ICA and a guide catheter (Chaperon, Microvention) was inserted through it. The guide catheter did not move well. Stagnation of contrast with a complete absence of blood flow above the mouth of the left ICA was revealed on angiography (Fig. 2).

The complication was regarded as dissection. It was not possible immediately enter 0.014" cerebral wire by into the

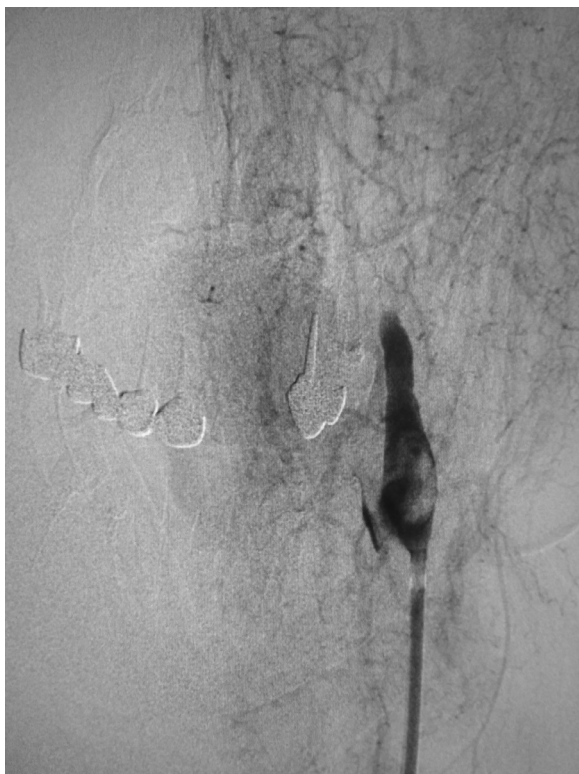

Fig. 2 – Stagnation of contrast at the mouth of the left ICA.

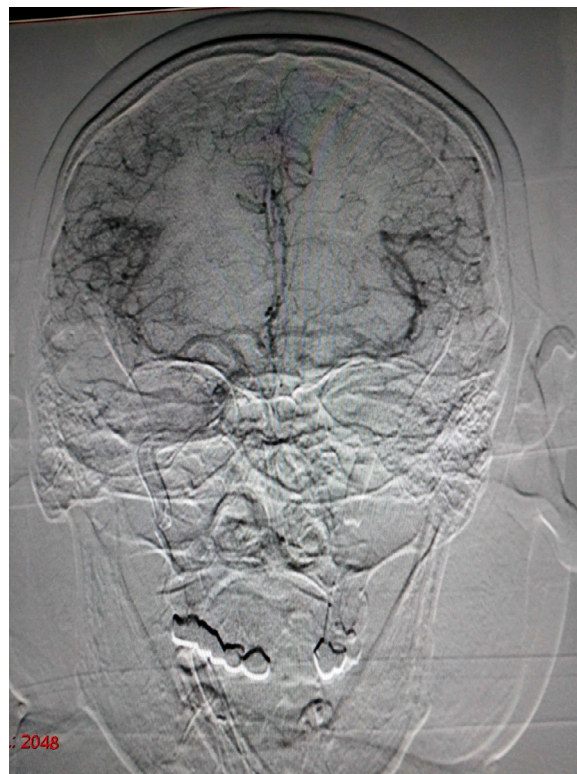

Fig. 3 – Angiography of the right ICA.

true lumen. The anesthesiologist administered 5000 IU of heparin intravenously to prevent thrombosis of the left ICA. Collateral blood flow and the absence of left cerebral artery thrombosis were evaluated by angiography of the right ICA (Fig. 3).

With repeated angiography of the left ICA, a weak blood flow appeared in the true lumen. 0,014" cerebral wire (Traxcess, Microvention) got to true lumen. Dilation of the dissection zone by coronary balloons 2.0 × 12 mm, 3.0 × 15 mm, and 3.5 × 15 mm was performed (Fig. 4).

After dilatation with a 3.5 × 15 mm balloon at a pressure of 10 atm. a limiting dissection remained in the lumen, blocking more than 70% of the lumen of the vessel. Considering the introduced 5000 units of heparin and the high risk of recurrent subarachnoid hemorrhage, the need for compulsory embolization of the aneurysm and possible re-occlusion of the ICA during the insertion of a guiding catheter, surgeon decided to perform stenting of the dissection site. The patient received double antiplatelet therapy through a nasogastric tube: 300 mg of acetylsalicylic acid and 300 mg of clopidogrel. A coronary drug-eluting coronary balloon stent was used according to the diameter of the artery (Fig. 5).

After the stent was installed, embolization was performed according to the standard method with the institution of a 0.021" microcatheter (Headway, Microvantage) into the aneurysm cavity and implantation of three coils (Axium, Medtronic) 6 mm X 15 cm, 5 mm X 15 cm, 3 mm X 10 cm. I radical class of aneurysm occlusion according to the modified Raymond-Roy classification was obtained. The blood flow was intracranial TICI III. The anterior cerebral artery was in

mild vasospasm. The stent design is passable without signs of residual stenosis or local leaks (Fig. 6).

The patient was extubated 6 hours after surgery. The patient was without worsening neurological deficit. On computed tomography in a day without negative dynamics. The anesthetist transferred the patient from intensive care to the neurological department on the 3rd day. During treatment, there was a positive dynamics in the form of a decrease in cerebral, focal symptoms (partial paresis of the oculomotor nerve of the left eye is preserved). The patient was discharged for rehabilitation, treatment and surveillance by a neurologist on the 16th day with recommendations to continue double antiplatelet therapy for 12 months.

The patient admitted for control cerebral angiography after 3 months. The ICA stent design was passable, without restenosis on the angiography. Aneurysm was additionally embolized in the neck zone (Fig. 7).

The neurologist established neurologically good positive dynamics in the form of a regression of focal neurological symptoms; a complete absence of cerebral symptoms. After additional embolization, the patient left hospital on the 3rd day for surveillance and treatment by a neurologist with recommendations to continue double antiplatelet therapy for 9 months. At the follow-up examination after 1 year, the patient returned to work completely. According to the ultrasound scan, the stent construction was passable, without signs of restenosis. Surgeon recommended monotherapy of 75 mg of acetylsalicylic acid.

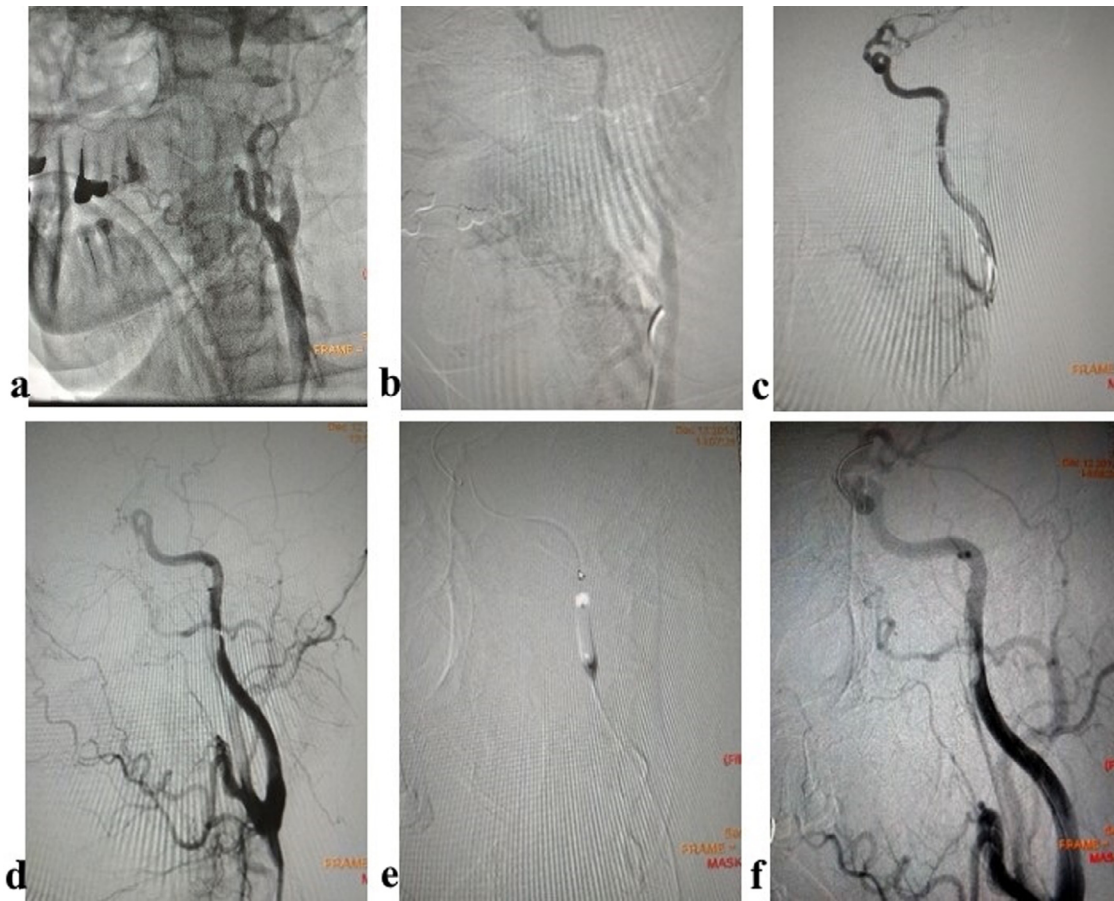

Fig. 4 – Angiography for dissection and balloon angioplasty: (a) weak blood flow in the true lumen, (b) passage through a micro wire, (c) angiography after dilatation with a 2.0 × 12 mm balloon, (d) angiography after dilatation with a 3.0 × 15 mm balloon, (e) dilatation with a 3.5 × 15 mm balloon, (f) angiography after dilatation with a 3.5 × 15 mm balloon.

Discussion

The cause of dissection is associated with mechanical damage to the wall of the left ICA by a hydrophilic wire and its further detachment when a guide catheter is inserted through it. From our point of view, the correct tactics have been applied in assessing the state of collateral blood flow and the administration of heparin. According to the data of clinical cases, after dissection, thrombosis of the extra- and intracranial ICA parts can quickly occur and, as a result, the need for thrombectomy and the development of ischemic complications [7]. However, in rare cases, during dissection of the ICA, an asymptomatic flow with complete vessel occlusion is observed [8]. In our case, from the moment of closure of the vessel to the installation of the stent and the start of the main blood flow along the left ICA, about 20 minutes passed, which made it possible quickly perform embolization of the aneurysm and not to get hemorrhagic and ischemic complications. The absence in the long-term period of signs of restenosis or mechanical damage to the coronary stent in the installed position indicates the possibility of implanting it in the indicated position in urgent situations.

According to the literature, the optimal treatment and clinical outcomes of mechanical dissection are not clearly established, and at present, only 3 studies that are devoted to iatrogenic dissections during neurointervention procedures can be guided [9-11]. The total number of all dissections studied was 98, while the frequency of occurrence varied from 0.15% to 0.6% [10-9]. The most common lesions were vertebral arteries and minimal tearing of intima [11]. The authors include vascular diseases in the manipulation zone, pronounced tortuosity of vessels, the use of large diameter guide catheters and manipulations with wire as predictors of dissection. Ischemic complications can occur both against the background of thrombosis and complete vessel occlusion, and against the background of severe stenosis. The authors distinguish three treatment options: drug antiplatelet and/or anticoagulant therapy to reduce the risk of thromboembolism; there is no treatment, mainly where antiplatelet/anticoagulant therapy is contraindicated; endovascular stenting to restore blood flow [11]. In iatrogenic dissections that do not restrict blood flow, in the acute phase a short course of heparin was suggested followed by antiplatelet therapy for several months [9]. There are no clear indications for stenting, most often it was performed in the absence of contralateral flows. In addition,

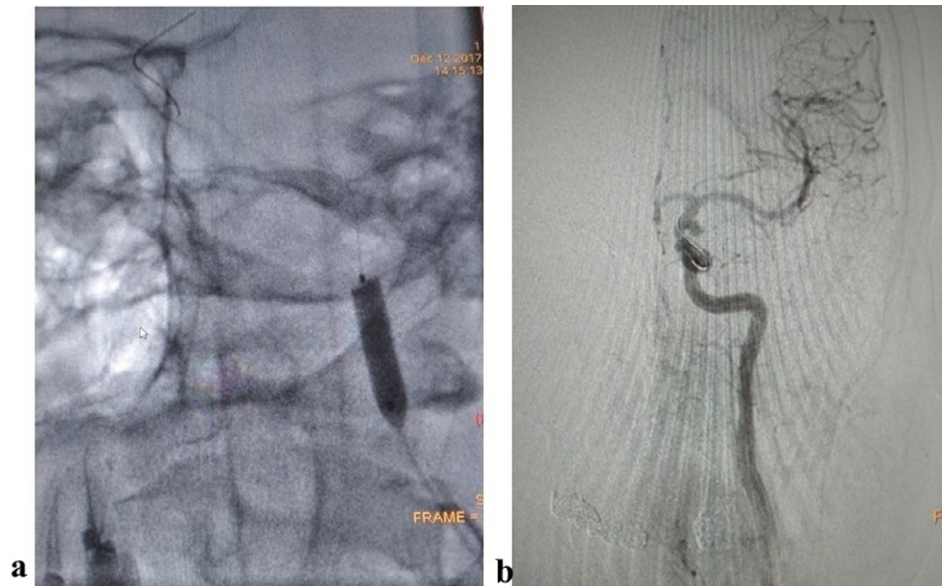


Fig. 5 – Stenting of the dissection area of the left ICA: (a) stent implantation, (b) angiography after implantation.

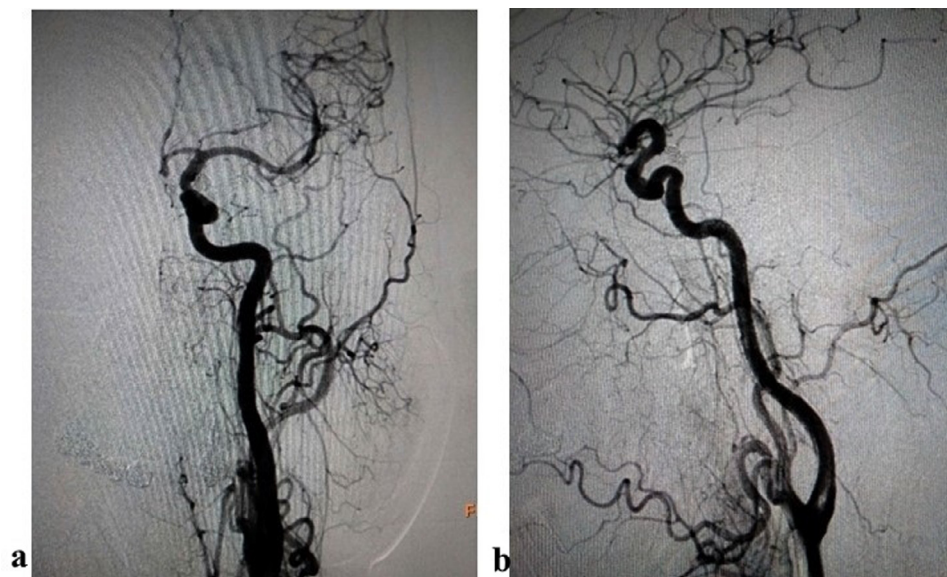

Fig. 6 – Final angiography: (a) frontal projection, (b) lateral projection.

when intraoperative complications develop during a planned procedure, it is suggested in the literature to try again after some time, if possible, after careful consideration of all possible treatment options [12]. In the presented studies, most operations were performed on planned patients. Follow-up was tracked in few cases to 5 years maximum; it was noted that

the maximum risk of stroke, in the absence of stenting, occurs in the first 2 weeks, which is similar to symptomatic ICA stenosis [11]. Complete healing after 6 months, with residual stenosis may be observed, but the risk of stroke recurrence is very low [11,13].

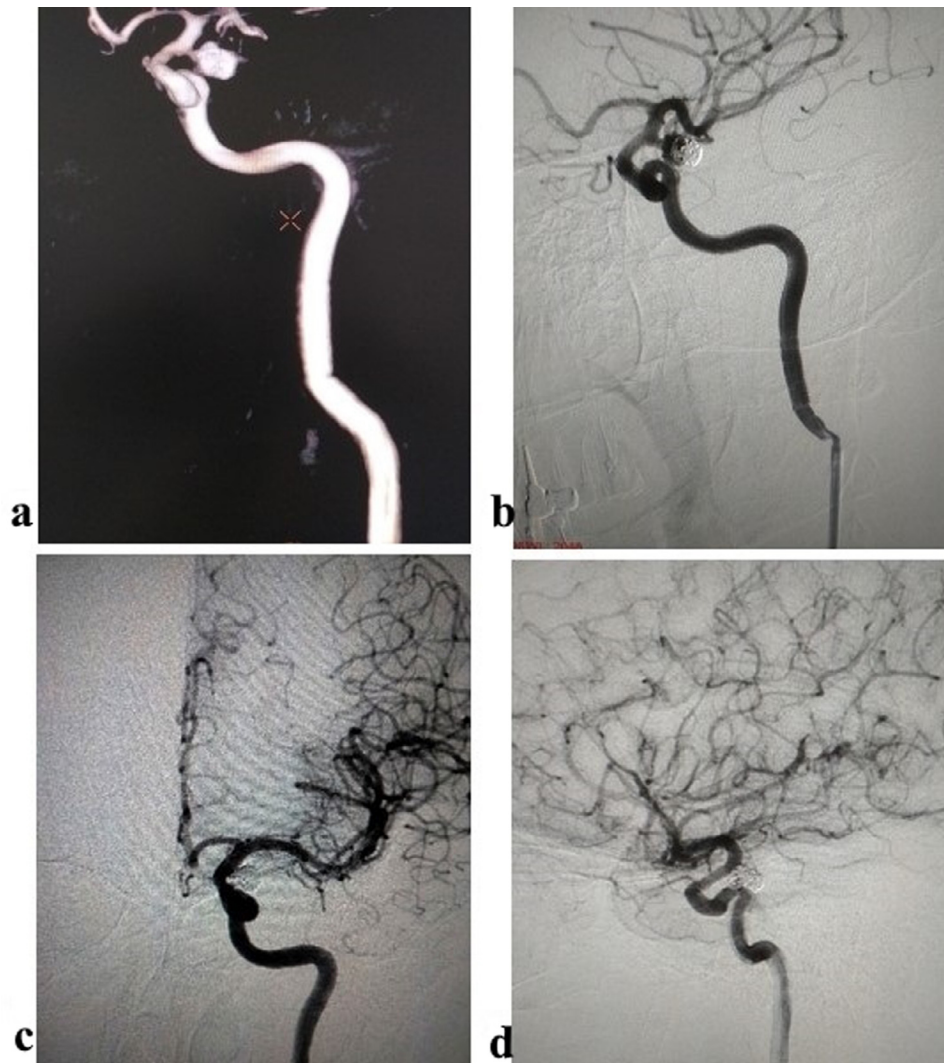


Fig. 7 – Control after 3 months: (a) 3D reconstruction, (b) angiography, (c) after additional embolization of the aneurysm neck, frontal projection, (d) after additional embolization of the aneurysm neck, lateral projection.

Conclusion

In a critical situation, the optimal decision should be made as quickly as possible based on the skills and abilities of the surgeon in the absence of a convincing evidence base that defines a specific treatment tactic.

REFERENCE

- [1] Kalashnikova LA, Chaykovskaya RP, Dobrynina LA, Sakharova AV, Gulevskaya TS, Dreval MV, et al. Internal carotid artery dissection as a cause of severe ischemic stroke with lethal outcome. *S.S. Korsakov J Neurol Psychiatry. Specvypuski*. 2015;115(12):19–25 (In Russ.). doi:[10.17116/jnevro201511512219-25](https://doi.org/10.17116/jnevro201511512219-25).
- [2] Guy N., Deffond D., Gabrillargues J. Spontaneous internal carotid artery dissection with lower cranial nerve palsy. *Can J Neurol Sci* 200; 28(3): 265–269. DOI: [10.1017/s031716710000144x](https://doi.org/10.1017/s031716710000144x)
- [3] Paciaroni M, Georgiadis D, Arnold M, Gandjour J, Keseru B, Fahrni G, et al. Seasonal variability in spontaneous cervical dissection. *J Neurol Neurosurg Psychiatry* 2006;77:677–9. doi:[10.1136/jnnp.2005.077073](https://doi.org/10.1136/jnnp.2005.077073).
- [4] Rubinstein SM, Peerdeman SM, van Tulder MW. A systematic review of the risk factors for cervical artery dissection. *Stroke* 2005;36:1575–80. doi:[10.1161/01.STR.0000169919.73219.30](https://doi.org/10.1161/01.STR.0000169919.73219.30).
- [5] Schievink WI. Spontaneous dissection of the carotid and vertebral arteries. *N Engl J Med* 2001;344:898–906. doi:[10.1056/NEJM200103223441206](https://doi.org/10.1056/NEJM200103223441206).
- [6] edited by Kandyba DV, Svistov DV, Babichev KN. *Endovascular treatment of intracranial aneurysms*. In: B Alekyan M, editor. *Endovascular surgery, V.3 Litterra*; 2017. edited by p. 177–218.

-
- [7] Zelenin VV, Kudryavtsev OI, Merkulov DV, Verbitskiy OP, Akhmetov VV, Dudanov IP. Successful treatment of dissection of the internal carotid artery. *Research'n Pract Med J* 2018;5(2):121–9. doi:[10.17709/2409-2231-2018-5-2-13](https://doi.org/10.17709/2409-2231-2018-5-2-13).
- [8] Akpınar S, Yılmaz G. Dissection of extracranial internal carotid artery due to balloon guiding catheter resulting in asymptomatic internal carotid artery occlusion. *Iran J Radiol* 2016;13(3):e28209. doi:[10.5812/iranjradiol.28209](https://doi.org/10.5812/iranjradiol.28209).
- [9] Paramasivam S, Leesch W, Fifi J, Ortiz R, Niimi Y, Berenstein A. Iatrogenic dissection during neurointerventional procedures: a retrospective analysis. *J Neurointerv Surg* 2012;4(5):331–5. doi:[10.1136/neurintsurg-2011-010103](https://doi.org/10.1136/neurintsurg-2011-010103).
- [10] Cloft HJ, Jensen ME, Kallmes DF, Dion JE. Arterial dissections complicating cerebral angiography and cerebrovascular interventions. *Am J Neuroradiol* 2000;21(3):541–5.
- [11] Groves AP, Kansagra AP, Cross DT, Moran CJ, Derdeyn CP. Acute management and outcomes of iatrogenic dissections during cerebral angiography. *J Neurointerv Surg* 2017;9(5):499–501. doi:[10.1136/neurintsurg-2016-012285](https://doi.org/10.1136/neurintsurg-2016-012285).
- [12] To CY, Badr Y, Richards B. Treatment of acute cervical internal carotid artery dissection using the Solitaire FR revascularization device. *BMJ Case Rep* 2012 2012 Dec 19. doi:[10.1136/bcr-2012-010519](https://doi.org/10.1136/bcr-2012-010519).
- [13] Lee VH, Brown RD, Mandrekar JN, Mokri B. Incidence and outcome of cervical artery dissection A population-based study. *Neurology* 2006;67(10):1809–12. doi:[10.1212/01.wnl.0000244486.30455.71](https://doi.org/10.1212/01.wnl.0000244486.30455.71).