

Experimental *Helicobacter marmotae* infection in A/J mice causes enterohepatic disease

Mary M. Patterson, Arlin B. Rogerst and James G. Fox

Correspondence

James G. Fox

jgfox@mit.edu

Division of Comparative Medicine, Massachusetts Institute of Technology,
77 Massachusetts Avenue, Building 16-825, Cambridge, MA 02139, USA

Helicobacter marmotae has been identified in the inflamed livers of Eastern woodchucks (*Marmota monax*) infected with woodchuck hepatitis virus (WHV), as well as from the livers of WHV-negative woodchucks. Because the majority of WHV-positive woodchucks with hepatic tumours were culture or PCR positive for this helicobacter, and WHV-negative woodchucks with *H. marmotae* had hepatitis, the bacterium may have a role in tumour promotion related to chronic inflammation. In this study, the type strain of *H. marmotae* was inoculated intraperitoneally into 48 male and female A/J mice, a strain noted to be susceptible to *Helicobacter hepaticus*-induced liver tumours. Sixteen mice served as mock-dosed controls. At 6, 12 and 18 months post-inoculation (p.i.), there were statistically significant ($P < 0.05$) differences in mean inflammation scores for the caecum and proximal colon between experimentally infected and control mice. Differences in hepatic inflammation were significant ($P < 0.05$) at 6 and 12 months p.i. between the two groups but not at the 18 month time point. Two infected male mice had livers with severe hepatitis, and the liver samples were culture positive for *H. marmotae*. Serum IgG levels in the mice dosed with *H. marmotae* were elevated for the duration of the study. These results demonstrate that the woodchuck helicobacter can successfully colonize mice and cause enterohepatic disease. In the future, a mouse-adapted strain of *H. marmotae* could be selected to maximize colonization and lesion development. Such a woodchuck helicobacter-infected mouse model could be used to dissect potential mechanisms of microbial co-carcinogenesis involved in tumour development in woodchucks with WHV and in humans with hepatitis B virus.

Received 15 March 2010

Accepted 8 July 2010

INTRODUCTION

Although the impact that gastric helicobacter species, particularly *Helicobacter pylori*, have had on our current understanding of gastrointestinal disease cannot be over-estimated, the ability of enterohepatic helicobacters to cause disease is also being examined. Naturally occurring enterohepatic species have been found associated with pathological conditions in humans and animals on numerous occasions. For example, *Helicobacter cinaedi* was isolated from bacteraemic humans and from the liver of a rhesus macaque with hepatitis and idiopathic colitis (Cimolai *et al.*, 1987; Fox *et al.*, 2001; Orlicek *et al.*, 1993; Vandamme *et al.*, 1990). The liver of a puppy with multifocal hepatitis was colonized with *Helicobacter canis*, and the organism was cultured from diarrhoeic faeces of a child and bacteraemic humans (Burnens *et al.*, 1993; Fox *et al.*, 1996a). '*Helicobacter rappini*' (now classified in the *Helicobacter bilis* taxon) was recovered from ovine fetuses

with hepatic necrosis, and has been described in association with gastroenteritis and bacteraemia in humans (Archer *et al.*, 1988; Kirkbride *et al.*, 1985; Weir *et al.*, 1999). A novel helicobacter belonging to the *H. bilis* taxon has been identified in the livers and colons of hamsters with hepatobiliary and intestinal disease (Fox *et al.*, 2009). Similarly, the inflamed livers of mice were shown to be naturally infected with *H. bilis* (Fox *et al.*, 1995, 2004). Aged male A/JCr mice infected with *Helicobacter hepaticus* have an increased incidence of hepatomas and hepatocellular carcinomas, whilst infected immunodeficient mice not only develop chronic hepatitis but also inflammatory bowel disease and colon cancer (Erdman *et al.*, 2003, 2009; Fox *et al.*, 1996b; Li *et al.*, 1998; Ward *et al.*, 1996). Other studies have also involved *H. hepaticus* inoculation into helicobacter-free mice, with the result of liver lesions or inflammatory bowel disease depending on mouse strain and experimental design (Cahill *et al.*, 1997; Fox *et al.*, 1996b, c, 2010; Whary *et al.*, 1998).

A novel enterohepatic helicobacter named *Helicobacter marmotae* has been detected, by culture and PCR, from the inflamed livers of Eastern woodchucks (*Marmota monax*), some of which were infected with woodchuck hepatitis

†Present address: Campus Box 7431, University of North Carolina, Chapel Hill, NC 27599-7431, USA.

Abbreviations: H and E, haematoxylin and eosin; p.i., post-inoculation; WHV, woodchuck hepatitis virus.

virus (WHV), and from the faeces of commercially raised cats (Fox *et al.*, 2002). For years, the woodchuck–WHV system has been used as a model of hepatitis B virus infection in humans (Menne & Cote, 2007; Tennant & Gerin, 2001). Its popularity is sustained because woodchucks with chronic WHV infection develop hepatocellular carcinomas and hepatitis at a high frequency, with lesions similar to those in humans with hepatitis B virus. As nine out of ten WHV-infected woodchucks that had hepatic tumours and all WHV-negative woodchucks that had inflamed livers were either culture or PCR positive for *H. marmotae*, the question arises as to whether chronic inflammation associated with the presence of *H. marmotae* can act as a tumour promoter. Besides the gastric helicobacters *H. pylori* and *Helicobacter mustelae*, precedence for helicobacter involvement in carcinogenesis has been demonstrated with *H. hepaticus* in A/J, AxB, B6C3F1, AB6F1 and B6Afl mice (Fox & Wang, 2000; Fox *et al.*, 1997; Garcia *et al.*, 2008; Hailey *et al.*, 1998; Ihrig *et al.*, 1999; Ward *et al.*, 1994). In the present study, male and female A/J mice were inoculated with the type strain of *H. marmotae* to evaluate features of colonization, concomitant pathology and serological response. Achieving *H. marmotae* colonization in mice for future experiments has obvious advantages over using the original woodchuck host, such as a shorter generation time and the availability of inbred and genetically engineered strains.

METHODS

Animals. Thirty-two male and thirty-two female A/J mice of 4–6 weeks of age received from The Jackson Laboratory were helicobacter-free and free of antibody to specific murine viruses. During the study, four same-sexed mice per cage were housed in microisolator cages within an Association for Assessment and Accreditation of Laboratory Animal Care-accredited facility. All animal manipulations were pre-approved by the Committee on Animal Care of the Massachusetts Institute of Technology.

Bacterial inoculation and study design. *H. marmotae* (ATCC BAA-546) was grown under microaerobic conditions at 37 °C in sterile *Brucella* broth (Difco Laboratories) containing 5% fetal calf serum (Summit Biotechnology). After 48 h of incubation on a rotary shaker, the culture was centrifuged at 9300 g for 20 min at 4 °C. Phase microscopy and Gram staining were used to assure the purity of the culture. The bacterial pellet was resuspended in sterile PBS to a concentration of approximately 10⁷ organisms ml⁻¹ based on spectrophotometric examination. Using a previously published inoculation strategy, experimental mice (24 males, 24 females) received 0.2 ml inoculum by intraperitoneal injection, whilst control mice (8 males, 8 females) were given 0.2 ml sterile PBS (McCarthy *et al.*, 1999; Shomer *et al.*, 2001). One mouse from each cage (total of two control and six experimental mice of each sex) was necropsied at 6 and 12 months after dosing; necropsies on the remaining mice were performed when the study was concluded at 18 months post-inoculation (p.i.).

Reisolation of *H. marmotae* from faeces, caeca and livers. Pooled faeces (three to four pellets) from each cage of mice were collected at 1, 3, 6 and 9 months p.i. and placed in 500 µl *Brucella* broth with 30% glycerol. At necropsy, liver samples were excised

aseptically and the caeca were gently scraped to remove luminal contents prior to storage in the *Brucella* broth/glycerol freezer medium. Faecal and tissue samples were frozen at –70 °C until further processing. To culture for *H. marmotae*, the sample material was homogenized in the freezer medium and the supernatant passed through a 0.45 µm filter. Filtered aliquots were placed on blood agar plates containing cefoperazone, vancomycin, and amphotericin B (CVA medium; Remel). The plates were incubated for up to 2 weeks in a microaerobic environment at 37 °C.

Analysis of faecal, caecal and hepatic DNA by PCR. Faecal pellets were also collected from each cage at 1, 3, 6 and 9 months p.i. to assess for the presence of helicobacter DNA. Three to four faecal pellets were homogenized in 1 ml PBS and DNA was extracted from the supernatant solution following the kit manufacturer's instructions (QIAamp DNA mini kit and QIAamp DNA blood mini kit; Qiagen). DNA from caecal and liver tissue was obtained using a High Pure PCR template preparation kit (Roche Molecular Biochemicals). PCR was performed using either all-helicobacter primers (C97 and C98) or primers designed specifically for *H. marmotae* (Fox *et al.*, 1998, 2002). An aliquot of the PCR product was electrophoresed through a 6% Visigel separation matrix (Stratagene) followed by ethidium bromide staining and visualization.

Histology. Caecal and liver tissues were fixed in 10% neutral buffered formalin, sectioned at 5 µm and stained with haematoxylin and eosin (H and E) for histopathological analysis. In a blinded manner, ileocaecal junction and liver morphology were evaluated by criteria that included inflammation, hyperplasia and necrosis. Lesions were scored on a scale of 0–4: 0, none; 1, minimal to mild; 2, mild to moderate; 3, moderate to severe; 4, diffusely severe. A Warthin–Starry silver stain was used for visual detection of *H. marmotae*.

ELISA for anti-*H. marmotae* IgG in serum. An outer-membrane antigen preparation of *H. marmotae* was obtained using methods previously described for *H. hepaticus* antigen (Whary *et al.*, 1998). A *Brucella* broth culture of the bacteria (see above) was washed in PBS three times. Following microscopic examination for purity, the bacterial pellet was resuspended in 4 ml 1% *N*-octyl-β-glucopyranoside for 30 min at room temperature. Ultracentrifugation at 100 000 g for 1 h was used to remove insoluble material. After dialysis against PBS at 4 °C for 24 h, the supernatant protein concentration was determined. Serum was collected from each mouse at necropsy and stored at –20 °C. For serum IgG determination, 96-well plates were coated with 100 µl *H. marmotae* outer-membrane antigen preparation (1 µg ml⁻¹) per well in carbonate buffer (pH 9.6) overnight at 4 °C. Biotinylated goat anti-mouse IgG was used as a secondary antibody. Incubation with ExtrAvidin peroxidase (Sigma-Aldrich) was followed by 2,2'-azino-bis(3-ethylbenzthiazoline-6-sulfonic acid) for colour development. Serum samples were diluted 1:100, and IgG results were reported as mean A₄₀₅ values, with all samples run in duplicate.

Statistical analysis. Mice were grouped by inoculation/colonization status, time point p.i. and gender. For comparison of control and experimental groups, a Mann–Whitney non-parametric test was applied. Serological data were assessed by analysis of variance of the differences between the groups.

RESULTS

Colonization of *H. marmotae* in A/J mice

Based on cultures of pooled faeces, five out of six cages housing inoculated male A/J mice had evidence of

H. marmotae colonization at 1 month p.i., whereas none of the cages containing inoculated female mice had positive faecal cultures (Table 1). However, by 3 months p.i., females inoculated with *H. marmotae* housed in two of the six cages had positive faecal cultures. For the later time points at 6 and 9 months p.i. when pooled faeces were assessed, the same experimental cages of male (five out of six) and female (two out of six) A/J mice remained persistently colonized with *H. marmotae*. Faecal cultures from the mock-infected mice cages were always negative for *H. marmotae*. When faeces collected from cages at 1 month p.i. were examined by PCR, all of the cages containing male experimental mice (six out of six) were positive. All other post-dosing PCR results on pooled faeces concurred with the culture results.

Caecal and liver cultures from control mice were consistently negative for *H. marmotae*. At 6, 12 and 18 months p.i. when necropsies were performed (Table 1), the caeca of experimental male and female mice taken from cages that had positive pooled faecal cultures were positive for *H. marmotae* by culture. There were no positive *H. marmotae* caecal cultures from experimental mice that came from cages where detectable *H. marmotae* infection was never established, as demonstrated by negative pooled faecal cultures and PCR. *H. marmotae* was cultured from the liver samples of one experimental male A/J mouse necropsied at 12 months p.i. and one male mouse at 18 months p.i.; these mice also had positive caecal cultures.

A subset of tissue samples chosen at random was analysed by PCR using *H. marmotae*-specific primers. The data (not shown) confirmed the tissue culture results in that the

caeca and livers of dosed but uninfected experimental mice were negative for *H. marmotae* DNA at the three necropsy time points. Also, of the infected experimental mice, only the livers from which *H. marmotae* was cultured were positive by the PCR method.

Histopathological evaluation

Mice infected with *H. marmotae* developed typhlocolitis and hepatitis. Inflammation in the large bowel was most severe at the caecocolic junction and proximal colon. In more severely affected animals, the caecocolic inflammation extended midway to the caecal apex and through the mid-distal colon. Inflammatory cells were composed primarily of lymphocytes, with fewer plasma cells and macrophages. Neutrophils comprised a minor percentage of some inflammatory infiltrates, and rare tissue sections contained eosinophils. Necrosis and hyperplasia were not important histological features in the large bowel. Caecocolic inflammation and oedema were limited to the lamina propria in most instances, although extension to the submucosa was prominent in more severe cases (Fig. 1). Multifocal hepatic inflammation was centred on portal triads, but occasional foci were random in distribution (Fig. 2). Inflammatory populations in liver samples were composed chiefly of mononuclear cells (Fig. 3); however, more severe cases had evidence of chronic periportal and random hepatitis with mixtures of mononuclear and polymorphonuclear cells. Bacteria with morphology consistent with *H. marmotae* were visible in the Warthin–Starry-stained liver sections of mice with positive liver cultures (Fig. 4). Infected mice with the most severe liver lesions exhibited mild to moderate intralesional hepatocellular apoptosis and/or necrosis with little evidence of hyperplasia.

Table 1. Culture and PCR results for A/J mice dosed with *H. marmotae*

Experiment	Time p.i. (months)					
	1	3	6	9	12	18
Male A/J mice						
Pooled faeces cultures*	5/6	5/6	5/6	5/6	ND	ND
Pooled faeces PCR*	6/6	5/6	5/6	5/6	ND	ND
Caecal culture†	ND	ND	5/6	ND	5/6	8/10
Liver culture†	ND	ND	0/6	ND	1/6	1/10
Female A/J mice						
Pooled faeces cultures*	0/6	2/6	2/6	2/6	ND	ND
Pooled faeces PCR*	0/6	2/6	2/6	2/6	ND	ND
Caecal culture†	ND	ND	2/6	ND	2/6	2/7
Liver culture†	ND	ND	0/6	ND	0/6	0/7

ND, Not done.

*Number of positive cages/total number of cages sampled.

†Number of positive mice/total number of mice in group.

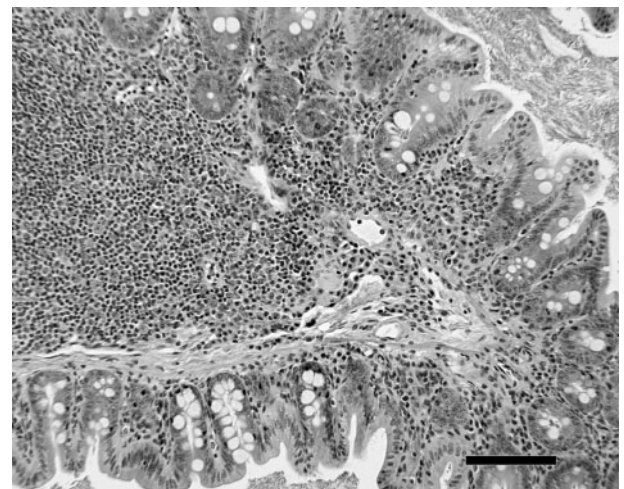


Fig. 1. Chronic typhilitis in the caecum of a male A/J mouse infected with *H. marmotae* for 12 months. H and E stained. Bar, 250 µm.

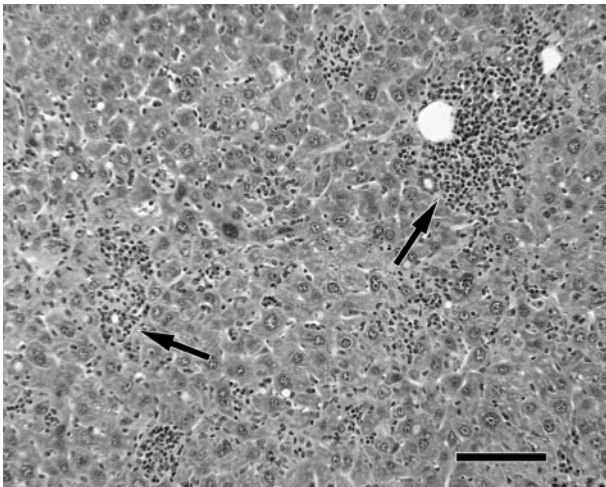


Fig. 2. Periportal hepatitis (indicated by arrows) and random hepatitis in a male A/J mouse infected with *H. marmotae* for 12 months. H and E stained. Bar, 250 µm.

Lesion scores were higher in *H. marmotae* experimentally infected mice than in mock-dosed controls (Table 2); experimental mice that were never colonized by *H. marmotae* were not included in the statistical analyses. Regarding caecal and hepatic inflammation there was no significant difference attributable to gender, except at the 18 month time point when some control female mice had developed low-grade hepatitis (median lesion score of 1.5 versus 0.5 for the control male mice at 18 months p.i.) commonly noted in aged inbred mice. Hence, the data on caecal/proximal colon and hepatic lesion scores from male and female mice were combined. At 6, 12 and 18 months p.i., statistically higher ($P < 0.05$) mean inflammation

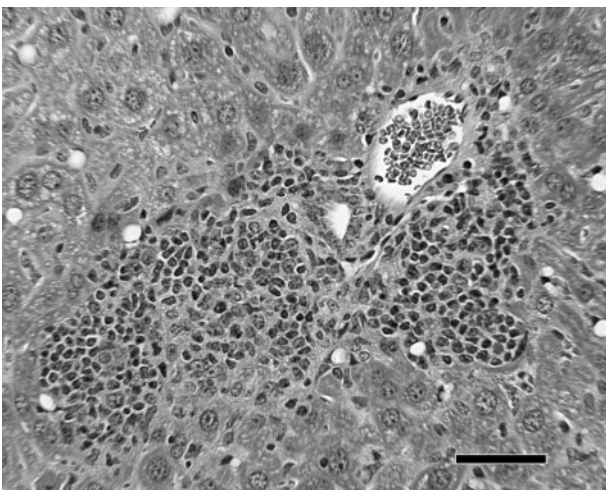


Fig. 3. Higher magnification view of primarily mononuclear cell infiltrate in the hepatic portal region. H and E stained. Bar, 125 µm.

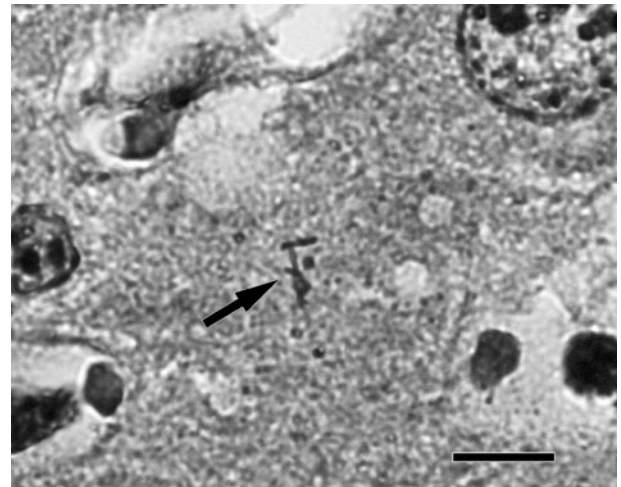


Fig. 4. Three spiral argyrophilic *H. marmotae* bacteria (indicated by an arrow) in a hepatic canaliculus from a culture-positive liver. Warthin–Starry stained. Bar, 10 µm.

scores for the caecum and proximal colon were observed in the colonized experimental mice compared with the control mice. Differences in hepatic inflammation were significant at 6 and 12 months p.i. between the two groups ($P < 0.05$).

Serum IgG responses to *H. marmotae*

Mice experimentally dosed with *H. marmotae*, whether or not colonization occurred, generated an IgG response that was statistically different ($P < 0.05$) from the titres of the mock-inoculated group (Fig. 5). The IgG levels in the experimental groups did not change appreciably between the 6 and 18 month p.i. time points.

DISCUSSION

Intraperitoneal inoculation of *H. marmotae* and subsequent colonization by the bacterium resulted in statistically significant typhlocolitis in A/J mice at 6, 12 and 18 months p.i. compared with mock-dosed mice, and animals with positive caecal cultures had more severe inflammation. These results are similar to those reported when a urease-negative novel *Helicobacter* sp. was inoculated intraperitoneally in A/J mice (Shomer *et al.*, 2001); likewise, *H. hepaticus* caused typhlitis in A/J mice when given by oral gavage (Whary *et al.*, 1998). Findings of lower-bowel pathology in immunocompetent mice caused by *Helicobacter* species are important for modelling inflammatory bowel disease in humans. In the present study, significant hepatitis was also related to *H. marmotae* infection at 6 and 12 months p.i. Hepatic lesions at 18 months p.i. remained higher in the experimental mice, but these were not statistically significant because spontaneous focal, mild hepatitis had developed in selected control mice, a lesion

Table 2. Caecal/proximal colon and hepatic lesion scores in *H. marmotae*-colonized A/J mice and controls

Scores are given as the median (range).

Time p.i.	Control mice*	Experimental infected mice
6 months		
Caecal/proximal colon scores	0.25 (0–0.5)	2.0 (1.0–2.5)†
Hepatic scores	0 (0)	1.0 (0–2.0)†
No. of mice	Two males, two females	Five males, two females
12 months		
Caecal/proximal lesion scores	0.5 (0.5)	2.5 (2.0–3.0)†
Hepatic scores	0.25 (0–0.5)	1.0 (0.5–3.0)†
No. of mice	Two males, two females	Five males, two females
18 months		
Caecal/proximal lesion scores	1.0 (0.5–1.0)	2.25 (1.5–3.0)†
Hepatic scores	0.5 (0.5–1.5)	1.0 (0–3.5)
No. of mice	Three males, two females	Eight males, two females

*Mice euthanized early due to health concerns were added into the analysis with data for the closest time point if cultures and complete necropsies were performed.

† $P < 0.05$ compared with value for control mice (Mann–Whitney test).

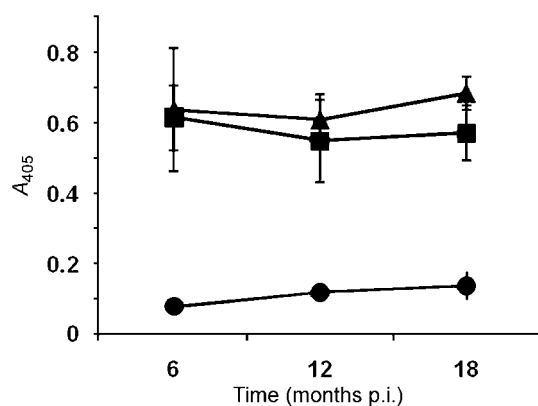
commonly observed in aged inbred mice (Sundberg *et al.*, 1997). Overall, the pathology that developed was inflammatory in nature, without the hyperplasia and necrosis that characterizes infection in mice with *H. hepaticus* (Fox *et al.*, 1996c; Ward *et al.*, 1994), except for severely affected experimental mice with hepatitis.

Another difference not observed in *H. hepaticus* infection in A/J mice was that *H. marmotae*-associated lesions did not progress dramatically from 6 to 18 months. Pathogenic mechanisms may be different in these two urease-positive helicobacters, although *H. marmotae*, like *H. hepaticus*, *Helicobacter pullorum*, *H. bilis*, *H. cinaedi* and *Campylobacter jejuni*, expresses cytolethal distending toxin, which causes cell-cycle arrest (Chien *et al.*, 2000). The presence of the toxin in *H. hepaticus* and *H. cinaedi* promotes

helicobacter-associated typhlocolitis in interleukin-10-deficient mice (Shen *et al.*, 2009; Young *et al.*, 2004). Whether this toxin plays a similar role in A/J mice with *H. marmotae*-induced gastrointestinal disease requires further studies.

Once the mice in a given cage were positive by faecal culture for *H. marmotae*, all of the animals in that cage became persistently colonized as shown by caecal cultures at necropsy. However, whilst the majority of male A/J mice (five out of six cages) became infected, only one-third of the females housed in cages were successfully colonized by the organism. It also took longer for colonization to be detected in the female mice, as at 1 month p.i. all of the cultures and PCR analyses of faeces pooled from female cages were negative for *H. marmotae*. In addition, the two liver samples that were culture positive for *H. marmotae*, presumably by intestinal translocation, occurred in male mice. Sporadic liver colonization, despite persistent colonization of the lower bowel, is also characteristic of *H. hepaticus* infection in A/J mice (Fox *et al.*, 1996b). Even though the overall lesion severity indices were similar in *H. marmotae*-colonized male and female mice, the highest hepatitis scores assigned during the study belonged to the two male mice that had livers from which the organism was recovered by culture. Female A/J mice may be able to limit bacterial colonization more effectively than male mice, perhaps by immune or hormonal mechanisms. The same gender bias has also been documented in A/J and AXB mice infected with *H. hepaticus* (Fox *et al.*, 1996b; Ihrig *et al.*, 1999; Ward *et al.*, 1994).

One factor that could have negatively affected infection rate and lesion severity in A/J mice dosed with *H. marmotae* is that the bacterial strain used in this study was obtained

**Fig. 5.** IgG response to *H. marmotae* in the sera of infected (▲), *H. marmotae*-inoculated but uninfected (■) and control (●) A/J mice.

from an infected woodchuck and was not adapted to mice. In an earlier report, mice were allowed to self-select human strains of *H. pylori*; this resulted in mouse-adapted strains, e.g. SS1, which could efficiently colonize the stomach and induce inflammation (Lee *et al.*, 1997). Woodchucks and mice are both members of the order Rodentia; however, they are distinct enough from one another to be placed in different families, Scuriidae and Muridae, respectively. It is unknown whether woodchucks infected with *H. marmotae* have lower-bowel colonization and concurrent intestinal inflammation. We have recently cultured *H. marmotae* from the intestines of prairie dogs and identified it by PCR in prairie dog livers (J. G. Fox, unpublished data), thereby increasing its natural host range. To date, *H. marmotae* has not been cultured from wild mice.

At 6, 12 and 18 months p.i., A/J mice of both sexes dosed intraperitoneally mounted a stable IgG serological immune response to *H. marmotae*. Likewise, in an earlier study designed to examine the immune responses of male A/JCr mice infected orally with *H. hepaticus*, essentially unchanged immunoglobulin levels were measured between 3 and 11 months after infection (Whary *et al.*, 1998). Of interest in the present study was that serum IgG levels remained elevated at 18 months p.i. in all of the experimentally dosed mice, even in those where persistent colonization was not evident. A long-term immunological response to the bacterial antigens could be a consequence of the intraperitoneal route by which *H. marmotae* was administered. Given that *H. marmotae* is a Gram-negative bacterium, low-level shedding of Gram-negative enteric antigens into the portal circulation could elicit ongoing anamnestic immune responses to shared *H. marmotae* antigens. Similarly, serum IgG levels were high in Swiss Webster outbred mice dosed intraperitoneally with *H. pylori*, even though only a minority (one out of eight) of the mice was colonized with *H. pylori* 1 month after dosing. The serum titres were considerably greater than antibody titres measured in orally dosed mice (McCarthy *et al.*, 1999). In mice dosed intraperitoneally with an enteric helicobacter, the organism was not isolated from various tissues (blood, lung, spleen, liver and kidneys) 30 days p.i., but was cultured from faeces (McCarthy *et al.*, 1999). Based on these earlier findings, we also believe it is unlikely that *H. marmotae* colonized extraintestinal tissue, which could have been responsible for the sustained immune response in experimentally inoculated, but uninfected mice. Although intraperitoneal versus oral administration of *Helicobacter* species has been used successfully in the past (McCarthy *et al.*, 1999; Shomer *et al.*, 2001; Ward *et al.*, 1994), oral gavage of *H. marmotae* in subsequent experiments will clarify the immunological effects of the dosing route used.

A high prevalence of *H. marmotae* DNA has been documented in WHV-infected woodchuck livers with hepatic tumours, and WHV-negative woodchucks with *H. marmotae* infection had evidence of comparable hepatitis (Fox *et al.*, 2002). Others have also described hepatic

lesions in woodchucks seronegative for WHV (Roth *et al.*, 1985, 1991), although the *H. marmotae* status of the woodchucks was not established. *H. marmotae* in woodchucks may induce chronic inflammation that in turn promotes neoplastic changes in liver parenchyma. The present report demonstrates that *H. marmotae* can successfully colonize both the lower bowel and liver of A/J mice, and cause substantial gastrointestinal disease. Recently, we reported that *H. hepaticus* infection promoted liver tumours in hepatitis C transgenic mice as well as in mice treated with aflatoxin (Fox *et al.*, 2010). Future murine studies with a mouse-adapted *H. marmotae* will be useful for studying mechanisms of microbially induced co-carcinogenesis, and by extension the possible carcinogenic role of *Helicobacter* spp. in humans infected with hepatitis B and C viruses.

ACKNOWLEDGEMENTS

This work was supported by National Institutes of Health grants RO1-AI37750 and T32-RR07036. The authors thank Dr Melanie Ihrig for providing assistance with the statistical analyses.

REFERENCES

- Archer, J. R., Romero, S., Ritchie, A. E., Hamacher, M. E., Steiner, B. M., Bryner, J. H. & Schell, R. F. (1988). Characterization of an unclassified microaerophilic bacterium associated with gastroenteritis. *J Clin Microbiol* **26**, 101–105.
- Burnens, A. P., Stanley, J., Schaad, U. B. & Nicolet, J. (1993). Novel *Campylobacter*-like organism resembling *Helicobacter fennelliae* isolated from a boy with gastroenteritis and from dogs. *J Clin Microbiol* **31**, 1916–1917.
- Cahill, R. J., Foltz, C. J., Fox, J. G., Dangler, C. A., Powrie, F. & Schauer, D. B. (1997). Inflammatory bowel disease: an immunity-mediated condition triggered by bacterial infection with *Helicobacter hepaticus*. *Infect Immun* **65**, 3126–3131.
- Chien, C. C., Taylor, N. S., Ge, Z., Schauer, D. B., Young, V. B. & Fox, J. G. (2000). Identification of *cdtB* homologues and cytolethal distending toxin activity in enterohepatic *Helicobacter* spp. *J Med Microbiol* **49**, 525–534.
- Cimolai, N., Gill, M. J., Jones, A., Flores, B., Stamm, W. E., Laurie, W., Madden, B. & Shahrabadi, M. S. (1987). “*Campylobacter cinaedi*” bacteremia: case report and laboratory findings. *J Clin Microbiol* **25**, 942–943.
- Erdman, S. E., Poutahidis, T., Tomczak, M., Rogers, A. B., Cormier, K., Plank, B., Horwitz, B. H. & Fox, J. G. (2003). CD4⁺ CD25⁺ regulatory T lymphocytes inhibit microbially induced colon cancer in Rag2-deficient mice. *Am J Pathol* **162**, 691–702.
- Erdman, S. E., Rao, V. P., Poutahidis, T., Rogers, A. B., Taylor, C. L., Jackson, E. A., Ge, Z., Lee, C. W., Schauer, D. B. & other authors (2009). Nitric oxide and TNF- α trigger colonic inflammation and carcinogenesis in *Helicobacter hepaticus*-infected, Rag2-deficient mice. *Proc Natl Acad Sci U S A* **106**, 1027–1032.
- Fox, J. G. & Wang, T. C. (2000). Overview of *Helicobacter pylori*. In *Infectious Causes of Cancer: Targets for Intervention*, pp. 371–388. Edited by J. J. Goedert. Totowa, NJ: Humana Press.
- Fox, J. G., Yan, L. L., Dewhirst, F. E., Paster, B. J., Shames, B., Murphy, J. C., Hayward, A., Belcher, J. C. & Mendes, E. N. (1995). *Helicobacter bilis* sp. nov., a novel *Helicobacter* species isolated from

- bile, livers, and intestines of aged, inbred mice. *J Clin Microbiol* **33**, 445–454.
- Fox, J. G., Drolet, R., Higgins, R., Messier, S., Yan, L., Coleman, B. E., Paster, B. J. & Dewhirst, F. E. (1996a).** *Helicobacter canis* isolated from a dog liver with multifocal necrotizing hepatitis. *J Clin Microbiol* **34**, 2479–2482.
- Fox, J. G., Li, X., Yan, L., Cahill, R. J., Hurley, R., Lewis, R. & Murphy, J. C. (1996b).** Chronic proliferative hepatitis in A/JCr mice associated with persistent *Helicobacter hepaticus* infection: a model of helicobacter-induced carcinogenesis. *Infect Immun* **64**, 1548–1558.
- Fox, J. G., Yan, L., Shames, B., Campbell, J., Murphy, J. C. & Li, X. (1996c).** Persistent hepatitis and enterocolitis in germfree mice infected with *Helicobacter hepaticus*. *Infect Immun* **64**, 3673–3681.
- Fox, J. G., Dangler, C. A., Sager, W., Borkowski, R. & Gliatto, J. M. (1997).** *Helicobacter mustelae*-associated gastric adenocarcinoma in ferrets (*Mustela putorius furo*). *Vet Pathol* **34**, 225–229.
- Fox, J. G., Dewhirst, F. E., Shen, Z., Feng, Y., Taylor, N. S., Paster, B. J., Ericson, R. L., Lau, C. N., Correa, P. & other authors (1998).** Hepatic *Helicobacter* species identified in bile and gallbladder tissue from Chileans with chronic cholecystitis. *Gastroenterology* **114**, 755–763.
- Fox, J. G., Handt, L., Sheppard, B. J., Xu, S., Dewhirst, F. E., Motzel, S. & Klein, H. (2001).** Isolation of *Helicobacter cinaedi* from the colon, liver, and mesenteric lymph node of a rhesus monkey with chronic colitis and hepatitis. *J Clin Microbiol* **39**, 1580–1585.
- Fox, J. G., Shen, Z., Xu, S., Feng, Y., Dangler, C. A., Dewhirst, F. E., Paster, B. J. & Cullen, J. M. (2002).** *Helicobacter marmotae* sp. nov. isolated from livers of woodchucks and intestines of cats. *J Clin Microbiol* **40**, 2513–2519.
- Fox, J. G., Rogers, A. B., Whary, M. T., Taylor, N. S., Xu, S., Feng, Y. & Keys, S. (2004).** *Helicobacter bilis*-associated hepatitis in outbred mice. *Comp Med* **54**, 571–577.
- Fox, J. G., Shen, Z., Muthupalani, S., Rogers, A. R., Kirchain, S. M. & Dewhirst, F. E. (2009).** Chronic hepatitis, hepatic dysplasia, fibrosis, and biliary hyperplasia in hamsters naturally infected with a novel helicobacter classified in the *H. bilis* cluster. *J Clin Microbiol* **47**, 3673–3681.
- Fox, J. G., Feng, Y., Theve, E. J., Raczynski, A. R., Fiala, J. L., Doernte, A. L., Williams, M., McFaline, J. L., Essigmann, J. M. & other authors (2010).** Gut microbes define liver cancer risk in mice exposed to chemical and viral transgenic hepatocarcinogens. *Gut* **59**, 88–97.
- Garcia, A., Ihrig, M. M., Fry, R. C., Feng, Y., Xu, S., Boutin, S. R., Rogers, A. B., Muthupalani, S., Samson, L. D. & Fox, J. G. (2008).** Genetic susceptibility to chronic hepatitis is inherited codominantly in *Helicobacter hepaticus*-infected AB6F1 and B6AF1 hybrid male mice, and progression to hepatocellular carcinoma is linked to hepatic expression of lipogenic genes and immune function-associated networks. *Infect Immun* **76**, 1866–1876.
- Hailey, J. R., Haseman, J. K., Bucher, J. R., Radovsky, A. E., Malarkey, D. E., Miller, R. T., Nyska, A. & Maronpot, R. R. (1998).** Impact of *Helicobacter hepaticus* infection in B6C3F1 mice from twelve National Toxicology Program two-year carcinogenesis studies. *Toxicol Pathol* **26**, 602–611.
- Ihrig, M., Schrenzel, M. D. & Fox, J. G. (1999).** Differential susceptibility to hepatic inflammation and proliferation in AXB recombinant inbred mice chronically infected with *Helicobacter hepaticus*. *Am J Pathol* **155**, 571–582.
- Kirkbride, C. A., Gates, C. E., Collins, J. E. & Ritchie, A. E. (1985).** Ovine abortion associated with an anaerobic bacterium. *J Am Vet Med Assoc* **186**, 789–791.
- Lee, A., O'Rourke, J., De Ungria, M. C., Robertson, B., Daskalopoulos, G. & Dixon, M. F. (1997).** A standardized mouse model of *Helicobacter pylori* infection: introducing the Sydney strain. *Gastroenterology* **112**, 1386–1397.
- Li, X., Fox, J. G., Whary, M. T., Yan, L., Shames, B. & Zhao, Z. (1998).** SCID/NCr mice naturally infected with *Helicobacter hepaticus* develop progressive hepatitis, proliferative typhlitis, and colitis. *Infect Immun* **66**, 5477–5484.
- McCathey, S. N., Shomer, N. H., Schrenzel, M. D., Whary, M. T., Taylor, N. S. & Fox, J. G. (1999).** Colonization and tissue tropism of *Helicobacter pylori* and a novel urease-negative *Helicobacter* species in ICR mice are independent of route of exposure. *Helicobacter* **4**, 249–259.
- Menne, S. & Cote, P. J. (2007).** The woodchuck as an animal model for pathogenesis and therapy of chronic hepatitis B virus infection. *World J Gastroenterol* **13**, 104–124.
- Orlicek, S. L., Welch, D. F. & Kuhls, T. L. (1993).** Septicemia and meningitis caused by *Helicobacter cinaedi* in a neonate. *J Clin Microbiol* **31**, 569–571.
- Roth, L., King, J. M., Hornbuckle, W. E., Harvey, H. J. & Tennant, B. C. (1985).** Chronic hepatitis and hepatocellular carcinoma associated with persistent woodchuck hepatitis virus infection. *Vet Pathol* **22**, 338–343.
- Roth, L., King, J. M. & Tennant, B. C. (1991).** Hepatic lesions in woodchucks (*Marmota monax*) seronegative for woodchuck hepatitis virus. *J Wildl Dis* **27**, 281–287.
- Shen, Z., Feng, Y., Rogers, A. B., Rickman, B., Whary, M. T., Xu, S., Clapp, K. M., Boutin, S. R. & Fox, J. G. (2009).** Cytolethal distending toxin promotes *Helicobacter cinaedi*-associated typhlocolitis in interleukin-10-deficient mice. *Infect Immun* **77**, 2508–2516.
- Shomer, N. H., Dangler, C. A., Schrenzel, M. D., Whary, M. T., Xu, S., Feng, Y., Paster, B. J., Dewhirst, F. E. & Fox, J. G. (2001).** Cholangiohepatitis and inflammatory bowel disease induced by a novel urease-negative *Helicobacter* species in A/J and Tac:ICR:Hascidf RF mice. *Exp Biol Med (Maywood)* **226**, 420–428.
- Sundberg, J. P., Fox, J. G., Ward, J. M. & Bedigian, H. G. (1997).** Idiopathic focal hepatic necrosis in inbred laboratory mice. In *Digestive System*, 2nd edn, pp. 213–217. Edited by T. C. Jones, J. A. Popp & V. Mohr. New York: Springer.
- Tennant, B. C. & Gerin, J. L. (2001).** The woodchuck model of hepatitis B virus infection. *ILAR J* **42**, 89–102.
- Vandamme, P., Falsen, E., Pot, B., Kersters, K. & De Ley, J. (1990).** Identification of *Campylobacter cinaedi* isolated from blood and feces of children and adult females. *J Clin Microbiol* **28**, 1016–1020.
- Ward, J. M., Fox, J. G., Anver, M. R., Haines, D. C., George, C. V., Collins, M. J., Jr, Gorelick, P. L., Nagashima, K., Gonda, M. A. & other authors (1994).** Chronic active hepatitis and associated liver tumors in mice caused by a persistent bacterial infection with a novel *Helicobacter* species. *J Natl Cancer Inst* **86**, 1222–1227.
- Ward, J. M., Anver, M. R., Haines, D. C., Melhorn, J. M., Gorelick, P., Yan, L. & Fox, J. G. (1996).** Inflammatory large bowel disease in immunodeficient mice naturally infected with *Helicobacter hepaticus*. *Lab Anim Sci* **46**, 15–20.
- Weir, S., Cuccherini, B., Whitney, A. M., Ray, M. L., MacGregor, J. P., Steigerwalt, A., Daneshvar, M. I., Weyant, R., Wray, B. & other authors (1999).** Recurrent bacteremia caused by a “*Flexispira*”-like organism in a patient with X-linked (Bruton’s) agammaglobulinemia. *J Clin Microbiol* **37**, 2439–2445.
- Whary, M. T., Morgan, T. J., Dangler, C. A., Gaudes, K. J., Taylor, N. S. & Fox, J. G. (1998).** Chronic active hepatitis induced by *Helicobacter hepaticus* in the A/JCr mouse is associated with a Th1 cell-mediated immune response. *Infect Immun* **66**, 3142–3148.
- Young, V. B., Knox, K. A., Pratt, J. S., Cortez, J. S., Mansfield, L. S., Rogers, A. B., Fox, J. G. & Schauer, D. B. (2004).** In vitro and in vivo characterization of *Helicobacter hepaticus* cytolethal distending toxin mutants. *Infect Immun* **72**, 2521–2527.