



Diagnostic confusion resolved by being upbeat

Puneet Kakar • Ami Kamdar • Hemanth Prabhudev •
Sandeep Buddha • Diego Kaski • Paul Bentley

Imperial College Cerebrovascular Research Unit, Imperial College London, Charing Cross Campus, Fulham Palace Road, London W6 8RF, UK

Correspondence to: Paul Bentley. Email: p.bentley@imperial.ac.uk

DECLARATIONS

Competing interests

There are no competing interests in the publication of this article by any of the authors. The authors were the medical physicians responsible for medical care of this patient

Funding

No external funding was applied for

Ethical approval

No ethical approval was sought

Guarantor

Written patient consent has been recorded in the medical notes

Contributorship

All authors were significantly involved in developing this manuscript

Acknowledgements

None

Summary

The classical stroke presentation – captured by the public health campaign mnemonic FAST (face, arm, speech, time) – does not apply in a large number of stroke cases; yet establishing a prompt diagnosis is imperative for optimal management. Here, we describe a patient with acute bulbar weakness, numbness in all extremities and an apparently normal magnetic resonance imaging (MRI) of the brain upon admission for whom even the fundamental question of whether this reflected a central or peripheral nervous system process was unclear. The critical localizing sign was upbeat nystagmus that denotes a brainstem cause. MRI of the brain in the second week confirmed a diagnosis of medial medullary infarction.

Case history

An 80-year-old woman presented with acute numbness and weakness in all extremities, bulbar weakness and blurred vision. Limb symptoms developed over one hour in the hands and lower legs, followed by dysarthria, dysphagia and visual symptoms that worsened over the following day. She denied diplopia but complained of objects in her visual environment appearing to move upwards. She did not have a headache or systemic symptoms. Past medical history consisted of arthritis for which she took intermittent simple analgesics, and she recalled an episode of 'paralysis' 20 years earlier which lasted for a few weeks and necessitating bed rest.

On examination, weakness was restricted to left ankle dorsiflexion (Medical Research Council Grading 4 + /5), but she was unable to stand due to ataxia. Tone and reflexes were normal except for an extensor left plantar response. Sensory disturbance was present in a glove-and-stocking distribution, to the wrists and lower knees,

symmetrically, to light touch and pinprick. She had bifacial and cervical weakness, slight bilateral ptosis, bulbar dysarthria and dysphonia. She had upbeat nystagmus (UBN) in primary gaze that worsened with gaze deviation to either side, but eye movements were conjugate and full in all planes. Examination of other systems was normal.

Investigations on admission revealed normal routine blood tests (renal, liver, bone function, C-reactive protein, glucose and full blood count), chest X-ray and electrocardiogram. Magnetic resonance imaging (MRI) of the brain, including diffusion-weighted imaging (DWI), cervical spine MRI and cervical computed tomography angiogram were reported as normal apart from an old right temporal infarct. Cerebrospinal fluid (CSF) was acellular, CSF glucose 2.9 mmol/L (serum glucose, 6.5 mmol/L), protein 0.52 g/L, with normal electrophoresis and herpes species polymerase chain reaction (PCR). The following serological tests were negative: antinuclear, antineutrophil cytoplasmic antibody, antiganglioside and antineuronal antibodies and HIV, syphilis and

borrelia. Nerve conduction studies were normal on day 5. Echocardiography and 24-hour electrogastrography telemetry were normal.

She was treated with aspirin, simvastatin and one-week course of both intravenous immunoglobulins (IV Igs) and intravenous acyclovir. She developed severe headache, photophobia and neck stiffness that were attributed to IV Ig, which settled after one week with analgesics. Her presenting neurological symptoms gradually improved such that after two weeks she could walk a few steps with assistance, and swallow pureed food, at which point she was transferred to a rehabilitation unit.

A repeat MRI of the brain on day 11 disclosed a T2 hyperintensity within the medial medulla that conformed to the arterial territory of the medial

medullary artery (and adjacent perforators), predominantly right sided, but with some left-sided involvement (Figure 1). Upon re-evaluation of the original T2 MRI, a faint hyperintensity in the same medullary location was apparent, as well as a single hyperintense voxel on DWI at the same location. A diagnosis of medial medullary infarction was made.

Discussion

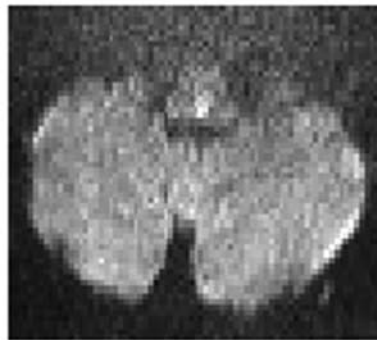
Clinical syndrome

Brainstem strokes frequently present challenges to diagnosis from both clinical and radiological standpoints. Yet being able to diagnose brainstem

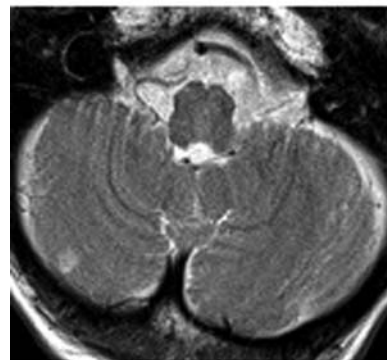
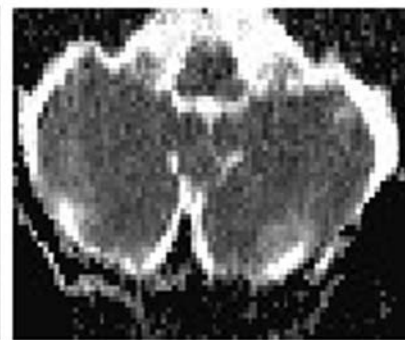
Figure 1

Representative MRI from the patient on admission shows a single voxel of hyperintensity on DWI in dorsal paramedian medulla, equivocal hypointensity of the equivalent apparent diffusion co-efficient (ADC) voxel and subtle hyperintensity of the medial medulla at the same time point. In the second week, a repeat MRI shows unequivocal T2 hyperintensity within a paramedian medullary distribution

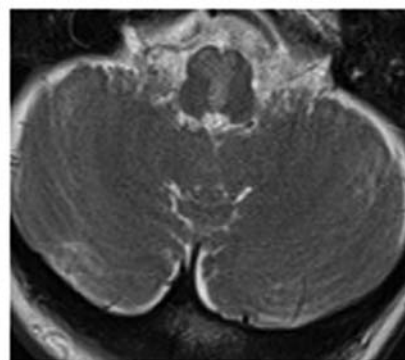
Day 1 - DWI



Day 1 - ADC



Day 1 - T2



Day 11 - T2

strokes rapidly may be critical in instituting the most appropriate management (e.g. thrombolysis). Compared with the majority (~75%) of strokes that affect either cerebral hemisphere, brainstem strokes tend to be associated with profound functional deficits, including sometimes impaired consciousness, for a relatively small volume of brain affected. Moreover, deficits can involve peripheral (afferent or lower motor neuron) fibres, and be bilateral, by virtue of the brainstem's arterial supply, and proximity of fibres supplying right and left body parts. However, certain clinical features can be very helpful in distinguishing brainstem from a strictly peripheral or spinal cord cause, with which they may be mistaken.

Our patient presented with numbness and weakness in all extremities, coming on over the course of a day – a picture that would most reasonably suggest an acute peripheral neuropathy such as Guillain–Barre syndrome (GBS, or strictly, acute inflammatory demyelinating polyneuropathy).^{1,2} The subsequent development of bulbar, facial and eyelid weakness would also be in keeping with this (especially, the Miller Fisher variant of GBS), while also introducing the diagnostic possibilities of a neuromuscular or muscular disease (e.g. myasthenia gravis,³ botulism or myositis). Her prominent ataxia, which in GBS is attributed to a combination of impaired proprioception (sensory ataxia) and cross-reactivity of pathogenic antibodies with spinocerebellar fibres, was also consistent with GBS. However, it is notable that the ataxia here was predominantly truncal, rather than of the limbs; this is suggestive of a central cause because the peripheral nerves supplying the trunk are relatively short and tend not to be affected in peripheral neuropathies until late. Furthermore, GBS is typically associated with areflexia and a high CSF protein (often >1 g/L) – which did not occur in this case. However, these features may not occur in the first few days of GBS, and so cannot be regarded as *sine qua non* for GBS.

An additional confounding fact here is that, although numbness in the extremities suggests a length-dependent peripheral neuropathy (such as GBS), this is also commonly the distribution of sensory impairment in central nervous lesions. This phenomenon is thought to arise from greater sensitivity and a greater cortical

representation of limb extremities than more proximal parts.⁴

The critical diagnostic clue in this case was the presence of UBN. Vertical nystagmus is a central oculomotor disturbance that reflects a functional impairment of the brainstem vertical oculomotor centres.⁵ UBN is less common than downbeat nystagmus, and has a less well-defined neuroanatomical localization (downbeat nystagmus being caused by lesions of the cervicomedullary junction). Patients with UBN can have lesions to the midbrain, affecting the interstitial nucleus of Cajal,⁵ the pontine ventral tegmental tract,⁶ or (as is the case here) paramedian dorsal lesions in the medulla, affecting the nucleus intercalatus of Staderini.⁷ Pathological causes of vertical nystagmus are typically stroke, multiple sclerosis, neoplasm or Wernicke's encephalopathy.

Several other clinical clues are recognized that distinguish brainstem from peripheral signs. When horizontal or torsional nystagmus is present, these may reflect either a peripheral vestibulopathy or a lesion to central vestibular connections.⁸ A simple bedside test to distinguish these is the 'head impulse test' that tests the vestibulo-ocular reflex, and whose impairment strongly suggests dysfunction of peripheral pathways. The test is performed by the examiner rapidly rotating the head to either side while asking the patient to fixate straight ahead at a set point (e.g. the examiner's nose). Normally, the subject's eyes will move in the opposite direction, and at the same speed, as the induced movement, so as to enable continuous visual fixation. An abnormal test occurs when the eyes are not able to be maintained at the fixation point, and so subjects make a delayed 'catch-up' saccade back to fixation. There are three additional features of central nystagmus: it cannot be suppressed by fixation, whereas peripheral nystagmus becomes worse in darkness (with removal of fixation); it may be bidirectional (i.e. to the right and to the left), whereas peripheral nystagmus is only ever unilateral; and if nystagmus can be provoked by postural changes (e.g. Hallpike manoeuvre), then central causes are associated with nystagmus without latency and without habituation (unlike peripheral nystagmus).

Other signs that may suggest a brainstem cause are 'crossed-syndromes' in which a unilateral, ipsilesional, lower motor neuron or peripheral

afferent cranial neuropathy (or Horner's syndrome or cerebellar ataxia) coexist with sensorimotor disturbance in opposite-sided limbs. This arises from the fact that a brainstem lesion is often sandwiched between a more rostral level at which fibres destined for cranial nerves or the cerebellum have already right-left crossed over (relative to cerebral hemispheres), and a more caudal level at which crossing over of spinally destined fibres is yet to occur.

Neuroimaging

The clinical impression of brainstem dysfunction was not corroborated on (initial) brain MRI, a fact that may have thrown the unwary clinician off the scent. However, a normal brain MRI does not exclude organic brain disease and, in particular, limitations of the sensitivity of brainstem imaging with MRI must be appreciated.

Several case series looking at the diagnostic accuracy of MRI in detecting brain infarctions suggest that up to one-third of brainstem infarcts (especially in the medulla) can be missed on initial MRI, but can be detected on repeat MRI.^{9,10} This compares with an MRI false-negative rate of approximately 5% across all brain infarct locations.¹¹

The reasons behind false-negative diffusion weighted MRI scans pertain to resolution capacity of diffusion MRI,¹¹ susceptibility artefacts that cause distortions in brain stem imaging¹² and the fact that reduction in blood flow may be above the threshold for diffusion-related effects and yet severe enough to cause neuronal dysfunction.^{13,14} Often, a combination of T2 and fluid-attenuated inversion recovery imaging rather than DWI is required to detect acute ischaemia of the brainstem.

In our patient, a medullary lesion only became apparent on a repeat MRI performed on day 5. In retrospect, a faint signal hyperintensity could be made out on the equivalent slice from the original T2 and DWI/apparent diffusion co-efficient MRI. In the context of the clinical presentation, this early scan should be interpreted as being relevant. However, without knowing this information, it is reasonable for a radiologist to have categorized it within the normal range of artefacts found in the brainstem.

Pathological diagnosis and treatment

Having established that a brainstem process was the most likely cause, subsequent management involved searching for the pathological basis for this and treatment of likely candidates. Other than stroke, common causes of acute brainstem dysfunction are infection (i.e. meningoencephalitis) and autoimmunity (e.g. multiple sclerosis or paraneoplastic syndrome). To exclude meningitis (especially *Listeria* that often targets the brainstem), a CSF examination is mandatory. In this case, there were only slight CSF biochemical abnormalities (as can occur secondary to brain infarction), but importantly no white cells that effectively exclude meningitis. Similarly, viral rhombencephalitis – such as that due to herpes zoster or enterovirus – was also unlikely given the CSF findings. However, as there is usual delay in a CSF herpes PCR test, and because viral encephalitis can cause bland CSF findings in the first few days, aciclovir was administered to cover the possibility of herpes encephalitis.

A further diagnostic consideration in this case was a combined central and peripheral nervous system syndrome given the presence of both brainstem signs and an apparent glove-and-stocking pattern of sensory loss (suggesting peripheral neuropathy). One such condition is Bickerstaff's encephalitis, which is a primary brainstem inflammatory process that often coexists or overlaps in presentation with GBS.^{15,16} The diagnosis requires serological positivity for antigangliosides GQ1b or GD1b, which are the same auto-antibodies found in GBS and its Miller Fisher variant. However, given a delay in the ability to exclude Bickerstaff's and GBS, the patient was treated with IV Ig (i.e. the treatment for both conditions). In fact, ganglioside antibodies of the patient were negative and her nerve conduction studies were normal, making GBS-Bickerstaff's unlikely. T2 MRI brain hyperintensities have been reported in GBS-Bickerstaff's (and also with infective rhombencephalitis) and so their presence or absence does not especially help with the diagnosis.

The eventual diagnosis of ischaemic stroke here is reliant on the second MRI scan that shows a well-defined hyperintensity within the territory of the medial medullary artery, as well as a corresponding single voxel of restricted diffusion

present on her earlier scan. The patient's clinical course of gradual improvement and negative results of tests for other conditions also support this conclusion.

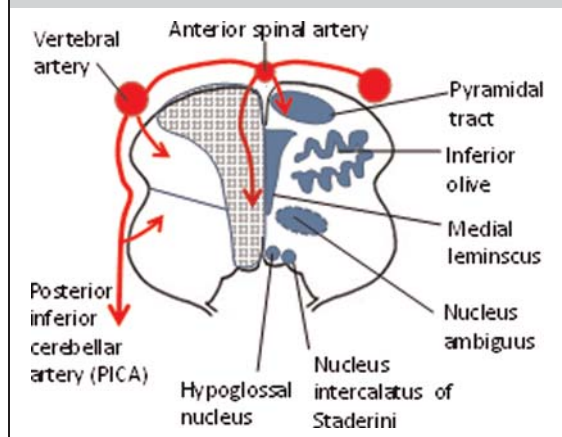
Medial medullary infarction is an uncommon stroke syndrome, especially when compared with the dorsolateral medullary (Wallenberg) syndrome caused by posterior inferior cerebellar artery (PICA) infarction. One reason for this is that the medial medullary artery is supplied by the anterior spinal artery, which itself is formed from both vertebral arteries (allowing for protection against unilateral vertebral occlusion), whereas the PICA originates from only a single vertebral artery (Figure 2).¹⁷ The most classical presentation of medial medullary stroke is Dejerine syndrome,^{18–22} which consists of the triad of ipsilateral hypoglossal palsy, contralateral hemiparesis and contralateral lemniscal (spinothalamic) sensory impairment (including reports of burning and pricking sensations in the face and limbs).²³ However, a bilateral pattern of sensory impairment can occur, as can a staggering onset,¹⁷ both of which occurred

with our patient, when there is occlusion of the common stem of bilateral medial medullary arteries. The most common eye movement abnormality is UBN, as also described here, although horizontal or more complex forms of nystagmus (e.g. seesaw or bowtie nystagmus) have been described. Other signs include truncal lateropulsion²⁴ (i.e. falling to one side), although for lesions that cross the midline the resultant sign is truncal ataxia, which was the main reason for impaired mobility in our patient.

Conclusion

This case draws attention to the fact that stroke can present atypically – even by mimicking an acute peripheral neuropathy, such as GBS. This may delay diagnosis and treatment of stroke. Certain bedside physical signs such as vertical nystagmus or crossed cranial nerve strongly point to brainstem pathology, whereas other signs such as impaired vestibular–ocular reflex strongly point to a purely peripheral (and, therefore, usually benign) process. This highlights the importance of applying clinical acumen and more soberly demonstrates the potential fallibility of neuroimaging including MRI.

Figure 2
Schematic neuroanatomy of the medulla showing, on the left side, the arterial supply and arterial territories (note similarity of medial medullary artery territory with patient's T2 lesion). On the right side, the most relevant anatomical structures for this case are shown, including nucleus intercalatus which acts as a neural integrator for vertical eye movements; medial lemniscus which conveys spinothalamic fibres; and nucleus ambiguus which conveys efferent vagal fibres to swallowing muscles



References

- Mori M, Kuwabara S, Fukutake T, Yuki N, Hattori T. Clinical features and prognosis of Miller Fisher syndrome. *Neurology* 2001;**56**:1104–6
- Derakhshan I, Lotfi J, Kaufman B. Ophthalmoplegia, ataxia and hyporeflexia (Fisher's syndrome). With a midbrain lesion demonstrated by CT scanning. *Eur Neurol* 1979;**18**:361–6
- Ito K, Mizutani J, Murofushi T, Mizuno M. Bilateral pseudointernuclear ophthalmoplegia in myasthenia gravis. *ORL J Otorhinolaryngol Relat Spec* 1997;**59**:122–6
- Lee SH, Kim DE, Song EC, Roh JK. Sensory dermatomal representation in the medial lemniscus. *Arch Neurol* 2001;**58**:649–51
- Kim JS, Yoon B, Choi KD, Oh SY, Park SH, Kim BK. Upbeat nystagmus: clinicoanatomical correlations in 15 patients. *J Clin Neurol* 2006;**2**:58–65
- Pierrot-Deselligny C, Milea D. Vertical nystagmus: clinical facts and hypotheses. *Brain* 2005;**128**:1237–46
- Janssen JC, Larner AJ, Morris H, Bronstein AM, Farmer SF. Upbeat nystagmus: clinicoanatomical correlation. *J Neurol Neurosurg Psychiatry* 1998;**65**:380–1
- Kaski D, Seemungal BM. The bedside assessment of vertigo. *Clin Med* 2010;**10**:402–5
- Narisawa A, Shamoto H, Shimizu H, Tominaga T, Yoshimoto T. Diffusion-weighted magnetic resonance

- imaging (MRI) in acute brain stem infarction. *No To Shinkei* 2001;**53**:1021–6
- 10 Seo MJ, Roh SY, Kyun YS, Yu HJ, Cho YK. Diffusion weighted imaging findings in the acute lateral medullary infarction. *J Clin Neurol* 2006;**2**:107–12
 - 11 Oppenheim C, Stanescu R, Dormont D, *et al.* False-negative diffusion-weighted MR findings in acute ischemic stroke. *AJNR Am J Neuroradiol* 2000;**21**:1434–40
 - 12 Lövblad KO, Jakob PM, Chen Q, *et al.* Turbo spin-echo diffusion-weighted MR of ischemic stroke. *AJNR Am J Neuroradiol* 1998;**19**:201–8
 - 13 Ginsberg M. The new language of cerebral ischemia. *Am J Neuroradiol* 1997;**18**:1435–45
 - 14 Sharbrough FW, Messick JM Jr, Sundt TM Jr. Correlation of continuous electroencephalograms with cerebral blood flow measurements during carotid endarterectomy. *Stroke* 1973;**4**:674–83
 - 15 Stevenson VL, Ferguson SM, Bain PG. Bickerstaff's brainstem encephalitis, Miller Fisher syndrome and Guillain-Barre syndrome overlap with negative anti-GQ1b antibodies. *Eur J Neurol* 2003;**10**:187
 - 16 Odaka M, Yuki N, Yamada M, *et al.* Bickerstaff's brainstem encephalitis: clinical features of 62 cases and a subgroup associated with Guillain-Barré syndrome. *Brain* 2003;**126**:2279–90
 - 17 Norrving B. Medullary infarcts and haemorrhages. In: Bogousslavsky J, Caplan L eds. *Stroke Syndromes*. Cambridge: Cambridge University Press, 2001:534–9
 - 18 Bassetti C, Bogousslavsky J, Mattle H, Bernasconi A. Medial medullary stroke: report of seven patients and review of the literature. *Neurology* 1997;**48**:882–90
 - 19 Searls DE, Pazdera L, Korbel E, Vysata O, Caplan LR. Symptoms and signs of posterior circulation ischemia in the New England Medical Center Posterior Circulation Registry. *Arch Neurol* 2012;**69**:346–51
 - 20 Gan R, Noronha A. Medullary vascular syndromes revisited. *J Neurol* 1995;**242**:195–202
 - 21 Hirose G, Ogasawara T, Shirakawa T, *et al.* Primary position upbeat nystagmus due to unilateral medial medullary infarction. *Ann Neurol* 1998;**43**:403–6
 - 22 Toyoda K, Imamura T, Saku Y, *et al.* Medial medullary infarction analyses of eleven patients. *Neurology* 1996;**47**:1141–7
 - 23 Jong S, Kim JS, Choi-Kwon J. Sensory sequelae of medullary infarction differences between lateral and medial medullary syndrome. *Stroke* 1999;**30**:2697–703
 - 24 Kim JS, Han YS. Medial medullary infarction: clinical, imaging, and outcome study in 86 consecutive patients. *Stroke* 2009;**40**:3221–5

© 2012 Royal Society of Medicine Press Ltd

This is an open-access article distributed under the terms of the Creative Commons Attribution License (<http://creativecommons.org/licenses/by-nc/2.0/>), which permits non-commercial use, distribution and reproduction in any medium, provided the original work is properly cited.