

Modified Retroperitoneoscopic Port Sites for Surgery of Upper Urinary Tract

Dongliang Hu, MD, Xinghuan Wang, MD, Wanli Hu, MD

ABSTRACT

Background and Objectives: Our objective was to introduce our experience using modified retroperitoneoscopic port positions for operations of the upper urinary tract.

Methods: We designed different trocar positions or incisions according to different surgical procedures and specimen sizes. A total of 116 patients, comprising patients with common adrenal, kidney, and ureter diseases, underwent retroperitoneoscopic operations by use of modified incisions. These patients comprised 23 with adrenal diseases, 84 with kidney diseases, and 9 with ureter diseases. The specimen was retrieved, as much as possible, through a transverse incision to produce a hidden scar after recovery. By contrast, 143 patients underwent the same or similar procedures using classical 3-port incisions. The operative time was defined as the time from skin incision to skin closure.

Results: There were no significant differences in age, estimated blood loss, oral intake, and hospital stay between groups. A significant difference in favor of the modified group was noted with respect to analgesia use (diclofenac sodium, 50 mg vs 100 mg; $P < .05$) in all 3 modified methods, as well as in cosmetic outcome in the groups undergoing the first modification (score, 8.9 ± 2.2 VS 7.3 ± 2.8 ; $P < .05$) and second modification (score, 8.7 ± 2.5 VS 7.1 ± 2.4 ; $P < .05$). In addition, the mean operative time in patients undergoing ureter operations was shorter than that in the conventional group using classical 3-port positions (55 ± 11 minutes vs 70 ± 15 minutes, $P < .05$).

Conclusions: Our modified retroperitoneoscopic incision is a safe, cosmetic alternative procedure for opera-

tions of the upper urinary tract. Different diseases and specimen sizes can be treated with the personalized or suitable incisions that we have introduced.

Key Words: Upper urinary tract, Laparoscope, Incision, Modified approach.

INTRODUCTION

In recent years laparoscopic and minimally invasive techniques have developed rapidly in urology. Such techniques cover almost all urologic operations. Several approaches can be applied in laparoscopic operations: transperitoneal approach, extraperitoneal approach, lateral retroperitoneal access, and so on. Generally speaking, the basic technology and incision differences are not very obvious in the lower urinary tract because most operations mainly concentrate on the prostate and bladder. However, in operations of the upper urinary tract, such as adrenal gland, kidney, and ureter operations, different institutions and urologists often have different habits and propensities in which they are skilled.¹⁻³ Hence the operative approaches and incision choices vary widely, especially with the introduction of new equipment. Surgeons have discussed the merits and demerits of each surgical method and incision,^{4,5} but the conclusions have not been consistent. A perfect urologic operation with minimally invasive surgery should include, as much as possible, the following: fewer and smaller incisions, hidden scars, flexible operating without clashing of instruments, conformity to ergonomics, and so on.

A personalized incision and successful operation are equally important for patients because they, unlike surgeons, do not understand surgical technology and the operation itself. In our opinion personalized incisions or port positions often have different cosmetic results. We introduce our experience using modified retroperitoneoscopic port positions for operations of the upper urinary tract. Our goal is not to determine the superiority of the modified port positions in different laparoscopic approaches or classical 3-port retroperitoneoscopic incisions. Rather, we are trying to introduce alternative and individual procedures based on standard methods.

Department of Urology, Zhongnan Hospital of Wuhan University, Wuhan, China (all authors).

This study was supported by a grant from the National Natural Science Foundation of China (No. 81200579).

Address correspondence to: Xinghuan Wang, Department of Urology, Zhongnan Hospital of Wuhan University, 169 Donghu Road, Wuhan, China. Telephone: 86-027-67813104, E-mail: urologistwxh@gmail.com

DOI: 10.4293/JSLs.2014.00206

© 2014 by JSLs, Journal of the Society of Laparoendoscopic Surgeons. Published by the Society of Laparoendoscopic Surgeons, Inc.

MATERIALS AND METHODS

Patients

From March 2012 to April 2013, a total of 116 patients underwent retroperitoneoscopic operations of the upper urinary tract by use of modified port positions by a single surgeon. Of these 116 patients, 84 had kidney diseases, 23 had adrenal diseases, and 9 had ureter diseases. The detailed disease categories of all 116 patients are listed in **Table 1**. We assessed the operative time, estimated blood loss, oral intake, hospital stay, analgesia use, and so on. Cosmetic aspects, including the appearance of the postoperative scar, and the degree of satisfaction were scored from 0 to 10 at discharge. The clinical data were compared with those of 143 patients who had undergone the same or similar procedures by use of classical 3-port incisions from July 2011 to December 2012.

Preoperative evaluations, including computed tomography (CT), intravenous urography, abdominal radiography Kidney-ureter-bladder (KUB), retrograde pyelography, and endocrine evaluation, were selectively used for different diseases. All of these preoperative preparations followed classical principles reported in previous publications or the latest guidelines.⁶ Patients with urinary tract infections received antibiotic therapy according to the results of the urine bacterial culture.

Table 1.

Disease Category for All 116 Patients Treated by Modified Approach

Disease Category	No. of Patients
Adrenal	
Adrenal cortical adenoma	18
Adrenocortical hyperplasia	3
Pheochromocytoma	2
Kidney	
Renal cell carcinoma	59
Hamartoma	4
Nonfunctional or atrophic kidney	6
Renal cyst	12
Renal staghorn stone	2
Chyluria	1
Ureter	
Proximal ureteral stone	7
Ureteropelvic junction obstruction	2

Technique

Step 1: Patient position. The patients were placed in the full lateral decubitus position with overexpression under general anesthesia.

Step 2: Trocar insertion. We designed different trocar positions or incisions according to different operations and specimen sizes. In brief, the first 2 ports were the same as those for conventional retroperitoneoscopic surgery for all patients: the first trocar (5 or 12 mm) was placed in a 2-cm incision below the 12th rib at the posterior axial line. The retroperitoneal working space was created by use of a balloon dilator with inflation of 800 mL of air through a port. The second trocar (10 mm) was placed above the iliac crest at the midaxillary line for the laparoscope. However, the other trocars were inserted through modified port positions: modification 1 (M1), modification 2 (M2), and modification 3 (M3).

For M1, the third trocar (5 mm) was placed at about 5 cm in the ventral aspect of the second trocar using a modified port position (**Figure 1**). The distance (5 cm) described earlier was determined or estimated based on the specimen size and patient weight. On the basis of our experience in practice, this distance was suitable for most common operations. If the distance is too close, it might lead to clashing of instruments and the laparoscope. In contrast, if the distance is too far, it might cause peritoneal injuries. Using this modified method, we performed a series of operations, such as adrenalectomy and nephrectomy for tumors <5 cm, nephrectomy for a nonfunctioning kidney, renal pedicle lymphatic disconnection, ureterolithotomy, renal cyst decortication, and pyeloplasty.

For M2, the fourth trocar (5 mm) was inserted under the subcostal margin in the anterior axillary line on the basis

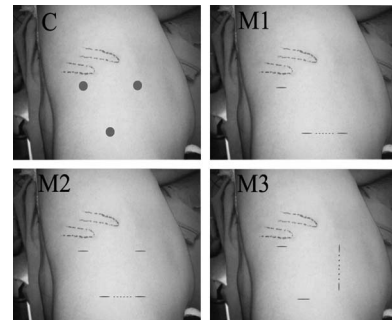


Figure 1. Port positions of classical approach (C), M1, M2, and M3. The dotted line indicates the postoperative incision for specimen retrieval, and the definitive distance was determined by the specimen size and patient weight.

of M1 (**Figure 1**). This method is particularly useful for some renal and adrenal lesions whose location is deeper or difficult to expose, although the specimen size may not be so large. In this situation the assistant will help the surgeon finish the operation smoothly using this port, such as in partial nephrectomy.

Under rare circumstances, the mass was very large and needed to be retrieved in an intact manner as much as possible. Usually, an auxiliary port was needed to grasp the mass or assist the surgeon because of a large tumor. In this case (M3), the third trocar (5 mm) was inserted under the subcostal margin at the anterior axillary line except the first 2 ports (described earlier), and the fourth trocar (5 mm) was placed under the third trocar in a straight line (**Figure 1**). The distance between them was determined by the specimen diameter. Often, the final size of the incision can be <1 cm compared with the actual size on the CT scan because of elasticity when retrieving them.

Step 3: Surgical procedures. Just as in conventional retroperitoneal laparoscopic surgery, the methods and procedures were identical to those in previously publications.^{1,7}

Step 4: Incision and specimen retrieval. The goal of our modified incisions was to achieve less injury and a hidden scar. Hence the specimen was retrieved through the dissected incision linking the second and third ports in M1 and M2 (or the third and fourth ports in M3) (**Figure 1**). We just connected the intrinsic two ports rather than prolonged any one port of them. By use of a transverse incision, the abdominal muscles were simply pulled instead of being cut when retrieving the specimen in M1 and M2.

Step 5: Drainage. A rubber drainage tube was usually placed through the port incision in the second trocar port (midaxillary line) into the surgical field. Finally, the skin incisions were closed. Patients were kept in bed for 2 days postoperatively, except for patients undergoing partial nephrectomy, who were kept in bed for 7 days. The tube was removed if the drainage output was <10 mL within 24 hours.

The conventional 3-port retroperitoneal laparoscopic port positions were used with insertion as described previously⁷ (**Figure 1**). For most surgeons, the specimen was often retrieved by extending the incision at the anterior or posterior axillary line.

The differences between the two groups were analyzed with the Student *t* test or analysis of variance. $P < .05$ was

considered significant. Statistical analyses were performed with SPSS software, version 15.0 (SPSS, Chicago, Illinois).

RESULTS

Of the 116 patients in the modified cohort with different upper urinary tract diseases, 1 required open conversion because of inferior vena cava injury when undergoing retroperitoneoscopic nephrolithotomy. Perioperative complications were limited to 2 cases of low fever and 1 case of wound infection. Oral intake was resumed 1.8 days (range, 1–3 days) after surgery. The drainage tube was removed at 2.1 days (range, 1–4 days). The mean length of hospitalization was 7.3 days (range, 6–13 days) because of the health insurance system in China. Besides, most patients preferred to be discharged after the stitches had been removed.

Adrenalectomy

The mean operative time for patients undergoing adrenalectomy was 58 minutes (range, 47–81 minutes). The mean estimated blood loss was 23 mL (range, 15–103 mL). Of the 23 patients, 18 were diagnosed with adrenal cortical adenoma, 3 with adrenocortical hyperplasia, and 2 with pheochromocytoma based on the postoperative pathologic results. All the patients were followed up at 1 and 3 months postoperatively, including blood tests, serum biochemistry analyses, endocrine examinations, and CT scans. The patients who had hypertension showed normalization after 3 months' follow-up.

Kidney Surgery

The concrete surgical methods were performed as described earlier. Of the 84 patients with kidney diseases, 59 were diagnosed with renal cell carcinomas, 4 with hamartomas, 6 with nonfunctional or atrophic kidneys, and 12 with renal cysts. Two patients had large staghorn stones and underwent either retroperitoneoscopic pyelolithotomy or nephrolithotomy. One patient with chyluria underwent renal pedicle lymphatic disconnection. The mean operative time was 72 minutes (range, 63–121 minutes). The mean blood loss was 29 mL (range, 18–135 mL). Only 1 case was converted to open surgery because of inferior vena cava injury when undergoing nephrolithotomy. One case presented with wound infection when she was about to be discharged. No serious postoperative complications were observed. All the patients, except for the patient with chyluria, were followed up at 1 month after surgery. No tumor or stone recurrence was detected. The patient with chyluria showed normalization immediately after surgery.

Ureter Surgery

Of the 9 patients with ureter diseases, 7 with proximal ureteral stones underwent retroperitoneoscopic ureterolithotomy and 2 with congenital ureteropelvic junction obstruction underwent retroperitoneoscopic pyeloplasty. The mean operative time was 55 minutes (range, 40–86 minutes). The mean blood loss was 13 mL (range, 10–18 mL). In 2 patients, a low fever developed on the second day, with a duration of 3 days, and the temperature recovered to normal after increasing the transfusion and administration of antibiotics. The double J stent was removed at 1 month after surgery. There were no obvious stones detected on postoperative CT re-examination.

Conventional Cohort

The conventional cohort of patients who had undergone standard laparoscopic retroperitoneal surgery by the same surgeon during the past 2 years was identified. The baseline demographic and operative data were extracted correspondingly and are listed in **Table 2**.

Comparisons of Modified and Conventional Cohorts

When the modified cohort was retrospectively compared with the group who had undergone conventional retroperitoneal laparoscopic operations, no significant differences were noted with respect to age, estimated blood loss, oral intake, and hospital stay. A significant difference

in favor of the modified group was noted with respect to analgesia use (diclofenac sodium, 50 mg vs 100 mg; $P < .05$) and cosmetic outcome (score, 8.9 ± 2.2 vs 7.3 ± 2.8 ; $P < .05$) for all 3 modified methods, as well as cosmetic outcome for the M1 and M2 methods (score, 8.7 ± 2.5 vs 7.1 ± 2.4 ; $P < .05$). In addition, the mean operative time for ureter operations was shorter than that in the conventional group with classical 3-port positions (55 ± 11 minutes vs 70 ± 15 minutes, $P < .05$) (**Table 2**).

DISCUSSION

Compared with open surgery, laparoscopic surgery incisions greatly depend on the trocar site and the application of new equipment, but the former is relatively constant. Different equipment requires different puncturing locations or auxiliary positions.⁸ As a result, such equipment will produce different results in terms of trauma and appearance. Therefore, the minimally invasive laparoscopic incision is relatively variable. In recent years many new technologies have emerged and have been reported by different institutions and surgeons, such as laparoendoscopic single-site surgery (LESS), natural orifice transluminal endoscopic surgery (NOTES), and hand-assisted or robot-assisted laparoscopic surgery.^{9–13} However, the goal of these new technologies was essentially the pursuit of more cosmetic incisions because they used the same or similar surgical procedures. The differences among them mainly manifested in the port size, position, and number,

Table 2.
Perioperative Data

	Modified Group (n = 116)	Conventional Group (n = 143)	P Value
Age (range) (y)	43 (19–78)	45 (16–72)	.65
Operative time (range) (min)			
Adrenal	58 (47–81)	61 (50–95)	.52
Kidney	72 (43–121)	75 (51–142)	.47
Ureter	55 (40–86)	70 (45–110)	<.05
Evaluated blood loss (range) (mL)	21 (10–135)	23 (15–150)	.11
Oral intake (range) (d)	1.8 (1–3)	1.9 (1–3)	.08
Hospital stay (range) (d)	7.3 (6–13)	7.5 (6–15)	.16
Analgesia use (range) (mg)	50 (0–100)	100 (0–150)	<.05
Cosmetic score (\pm SD)			
M1	8.9 ± 2.2	7.3 ± 2.8	<.05
M2	8.7 ± 2.5	7.1 ± 2.4	<.05
M3	7.2 ± 1.6	7.1 ± 2.1	.33

as well as the specimen extraction approach. We thought that an ideal urologic operation should include a combination of a smaller incision and convenient surgical manipulation rather than simply providing one of the two.

The typical 3-port technique for retroperitoneoscopic surgery was used as previously described.⁷ The specimen was often retrieved by suitably extending one of the ports. However, this was inconsistent with the initial incision direction and prolonged incision choice after surgery. We have made subtle changes and designed some personalized port positions for patients with upper urinary tract diseases. Of the 116 cases, 115 successfully underwent retroperitoneoscopic operations of the upper urinary tract by use of the modified port positions. Only 1 case required conversion to open surgery because of inferior vena cava injury when undergoing nephrolithotomy. The modified approaches made surgeon easier to handle compared with LESS or NOTES, and the skin incision was hidden and beautiful after surgery.

We have summarized the feasibility and features of the modified port positions for urologists. A suitable surgical procedure could be found for almost all of the upper urinary tract operations, as exemplified herein: (1) If the specimen size is <5 cm, the operation can be performed by the M1 method. (2) The M2 method is particularly suitable in cases in which the mass is not so large but the location is poorly exposed, such as partial nephrectomy for a ventral tumor or adrenalectomy in obese patients. The auxiliary trocar, in this case, makes the operation simple and easy, thereby reducing the operative difficulty and time. Specimen retrieval is identical to that for M1. The postoperative scar appears hidden and cosmetic because it can be covered by a belt. (3) The M3 method is especially useful for patients with very large renal or adrenal masses. In this situation this method can avoid peritoneal injuries due to excessive extension of the incision if one is using the M1 or M2 method. For patients, the main advantages are as follows: (1) The chief incision in the M1 and M2 methods, as a transverse incision, simply connected the 2 intrinsic ports rather than extending either port. Therefore, the abdominal muscles were addressed in a less invasive manner because they were simply pulled rather than being cut. (2) The incision was hidden and cosmetic because the scar was parallel with the skin stripes and waist belt after recovery. (3) There were relatively few patients requiring the M3 method because of huge specimens. Compared with the waist oblique incision of traditional open surgery, patients still prefer to undergo the M3 method based on our clinical experience.

In this work we found that patients in the modified cohort had less trauma than the conventional group according to the analgesia doses used. In fact, the same operating procedure is used for these two kinds of retroperitoneoscopic incisions. The differences between them mainly relate to skin or muscle trauma. Obviously, in the modified cohort, the 2 intrinsic ports were simply connected and the muscles were pulled as much as possible. It is possible that the cutaneous nerve lesions were less disturbed and patients had decreased postoperative pain. In addition, compared with the conventional cohort, the cosmetic results were better in patients undergoing the M1 and M2 methods. This finding should be attributed to hidden scars because the incision is parallel to the skin stripes or waist belt. The scar can be covered by a belt after recovery. Finally, for ureter operations, the M1 method had a shorter operative time than that in the conventional group with classical 3-port positions. The surgical field for ureter operations is lower than that for kidney operations. The third port in the M1 method is also lower than that in the conventional 3-port method and is closer to the ureter. Thereby, the assistant will not be as tired because he or she does not need to lift the laparoscope excessively. Consequently, effective and convenient cooperation reduce the operative time.

With the rapid development of minimally invasive techniques, there have been many new technologies derived from standard laparoscopic surgery, such as the operations mentioned earlier. We thought that the essential purpose of these new technologies was to pursue less invasive incisions or more advanced progress. However, some authors have expressed reserved and cautious opinions because of the technologies' defects.¹⁴ On the basis of our experience with modified port positions for retroperitoneoscopic surgery, we thought their use was safe and feasible. Compared with the previously described new technologies or surgical procedures, the advantages or features of the modified port positions can be summarized as follows: (1) Unlike LESS or NOTES, our modified operations are still characterized by independent 3-trocar positions. This kind of incision can avoid instrument clashing and conform to ergonomics. As a result, the operative difficulty and time were reduced accordingly. (2) A single port in current LESS often requires an auxiliary incision in most cases. Moreover, a commercial single port was not actually so small in diameter. On the contrary, the operative time and trauma were prolonged because of inconvenient manipulation. (3) As far as most NOTES procedures are concerned, they often interfere with the viscera and increase the chance of organ injury, regardless

of whether performed by a transvaginal or transumbilical approach. Scars make it more difficult for the urologist to perform the second operation in some patients who have undergone the first abdominal surgical procedure. In addition, they can affect the patient's normal organs or function, for example, the avoidance of sexual activity after surgery by the transvaginal approach.¹⁵ (4) To some hand-assisted or robot-assisted laparoscopic operations, it is useful for accurate positioning and careful operations. We lack sufficient experience performing these operations, but they often require more robot arms and trocars to finish the operations. Perhaps the advantage with regard to scarring and port numbers was not as obvious as the reductions in hemorrhage and trauma.

So far, many surgeons have focused on technique and the operation itself. We believed that the most important point was satisfaction for both the surgeon and the patient. Therefore, we have introduced our experience using modified retroperitoneoscopic port positions for operations of the upper urinary tract as an alternative choice. Their use provides references for urologists who decide to use new technology and perform new types of surgical procedures, especially those who want to achieve a perfect combination of operative effect and incisional beauty.

References:

1. Zhang X, Fu B, Lang B, et al. Technique of anatomical retroperitoneoscopic adrenalectomy with report of 800 cases. *J Urol.* 2007;177:1254–1257.
2. Chueh SC, Sankari BR, Chung SD, et al. Feasibility and safety of retroperitoneoscopic laparoendoscopic single-site nephrectomy: technique and early outcomes. *BJU Int.* 2011;108:1879–1885.
3. Ou CH, Yang WH. Hand assisted retroperitoneoscopic nephroureterectomy with the patient spread-eagled: an approach through a completely supine position. *J Urol.* 2008;180:1918–1922.

4. Farres H, Felsher J, Brodsky J, et al. Laparoscopic adrenalectomy: a cost analysis of three approaches. *J Laparoendosc Adv Surg Tech A.* 2004;14:23–26.
5. Naya Y, Nagata M, Ichikawa T, et al. Laparoscopic adrenalectomy: comparison of transperitoneal and retroperitoneal approaches. *BJU Int.* 2002;90:199–204.
6. Flávio Rocha M, Faramarzi-Roques R, Tauzin-Fin P, et al. Laparoscopic surgery for pheochromocytoma. *Eur Urol.* 2004;45:226–232.
7. Zhang X, Ye ZQ, Chen Z, et al. Comparison of open surgery versus retroperitoneoscopic approach to chyluria. *J Urol.* 2003;169:991–993.
8. Wolf JS Jr. Selection of patients for hand-assisted laparoscopic surgery. *J Endourol.* 2004;18:327–332.
9. Perretta S, Allemann P, Asakuma M, et al. Adrenalectomy using natural orifice transluminal endoscopic surgery (NOTES): a transvaginal retroperitoneal approach. *Surg Endosc.* 2009;23:1390.
10. Gill IS, Canes D, Aron M, et al. Single port transumbilical (E-NOTES) donor nephrectomy. *J Urol.* 2008;180:637–641.
11. Gettman MT, Box G, Averch T, et al. Consensus statement on natural orifice transluminal endoscopic surgery and single-incision laparoscopic surgery: heralding a new era in urology? *Eur Urol.* 2008;53:1117–1120.
12. Capolicchio JP, Saemi A, Trotter S, et al. Retroperitoneoscopic nephrectomy with a modified hand-assisted approach. *Urology.* 2011;77:607–611.
13. Stein RJ, White WM, Goel RK, et al. Robotic laparoendoscopic single-site surgery using GelPort as the access platform. *Eur Urol.* 2010;57:132–136.
14. Canes D, Desai MM, Aron M, et al. Transumbilical single-port surgery: evolution and current status. *Eur Urol.* 2008;54:1020–1029.
15. Alcaraz A, Musquera M, Peri L, et al. Feasibility of transvaginal natural orifice transluminal endoscopic surgery-assisted living donor nephrectomy: is kidney vaginal delivery the approach of the future? *Eur Urol.* 2011;59:1019–1025.