

# Qualitative ultrasound elastography assessment of benign thyroid nodules: Patterns and intra-observer acquisition variability

Alexis Lacout, Carole Chevenet<sup>1</sup>, Juliette Thariat<sup>2</sup>, Andrea Figl<sup>3</sup>, Pierre-Yves Marcy<sup>4</sup>

Centre d'imagerie Médicale, 47 Boulevard du Pont Rouge, 15000 Aurillac, <sup>1</sup>Centre de Pathologie, 23 av République, 15000 Aurillac, <sup>2</sup>Department of Radiation Oncology, <sup>3</sup>Department Oncology Breast Surgery, Antoine Lacassagne Cancer Research Center, 33 Avenue Valombrose, 06189 NICE cedex 1, <sup>4</sup>Department of Medical Imaging, François Baclesse Center, 3, Avenue du Général-Harris, 14076 Caen cedex 05, France

**Correspondance:** Dr. Alexis Lacout, Centre d'imagerie Médicale, 47, Boulevard du Pont Rouge, 15000 Aurillac France.  
E-mail: lacout.alexis@wanadoo.fr

## Abstract

**Purpose:** To report and evaluate qualitative elastography patterns by using gray-scale and Doppler ultrasound (US) in patients presenting with benign thyroid nodules and to evaluate the reproducibility of US elastography examinations. **Materials and Methods:** Institutional review board approval was obtained, and all patients provided informed consent. Over a 3-month time period, all consecutive adult patients were referred to our institution to undergo a thyroid nodule fine-needle aspiration biopsy (FNAB) procedure. Patients presenting with benign cytology according to the Bethesda 2008 classification were prospectively enrolled in the study. Each thyroid nodule was assessed by using gray-scale, Doppler US, and elastography acquisitions by a single operator (A. L.). Multiple elastography acquisitions per thyroid nodule were performed and elastography scorings of the nodules were compared with each other. **Results:** Nineteen patients (16 women and 3 men, mean age 58 years) with 22 thyroid nodules were included in the present study. Elastographic patterns 1, 2, and 3 were reported (23% nodules showed pattern 3). The elastography pattern showed a strong variability in 13 nodules (59%). The elastography acquisition result variability involved the "malignant" pattern 3 in 36% of cases. **Conclusion:** Almost one-third of benign thyroid nodules displayed pattern 3 on qualitative US elastography. The intra-observer variability of the benign thyroid elastography scoring is wide, thus limiting the thyroid nodule US examination accuracy. In FNAB-proven benign thyroid nodules, elastography pattern 3 is frequent and cannot be used as a strong indicator of thyroid malignancy.

**Key words:** Elastography; pattern; thyroid; variability

## Introduction

The increasing use of neck ultrasound (US) examination has led to the detection of a growing number of asymptomatic

thyroid nodules.<sup>[1]</sup> Of these nodules, approximately 5% are malignant.<sup>[2]</sup>

Fine-needle aspiration biopsy (FNAB) is the best method to help differentiating benign from malignant thyroid nodules with the disadvantage of being minimally invasive and time consuming.<sup>[3]</sup> Specific gray-scale and Doppler US features will help to select patients who should undergo FNAB.<sup>[4]</sup>

Elastography US examination has been proposed to assess the tissue elasticity of undetermined thyroid nodules, as it may discriminate benign (soft) from malignant nodules (hard). Four different patterns have

### Access this article online

#### Quick Response Code:



**Website:**  
www.ijri.org

**DOI:**  
10.4103/0971-3026.125612

been described [Figure 1] including “patterns 3 and 4” that suggest malignancy while “patterns 1 and 2” indicate thyroid nodule benignity.<sup>[5,6]</sup>

The purpose of this study was to first assess the different patterns, which can be observed in FNAB-benign thyroid nodules according to the Bethesda 2008 cytological classification. We also looked for a correlation between these patterns and gray scale–Doppler features and assessed the per nodule intraoperator reproducibility of elastography examinations.

## Materials and Methods

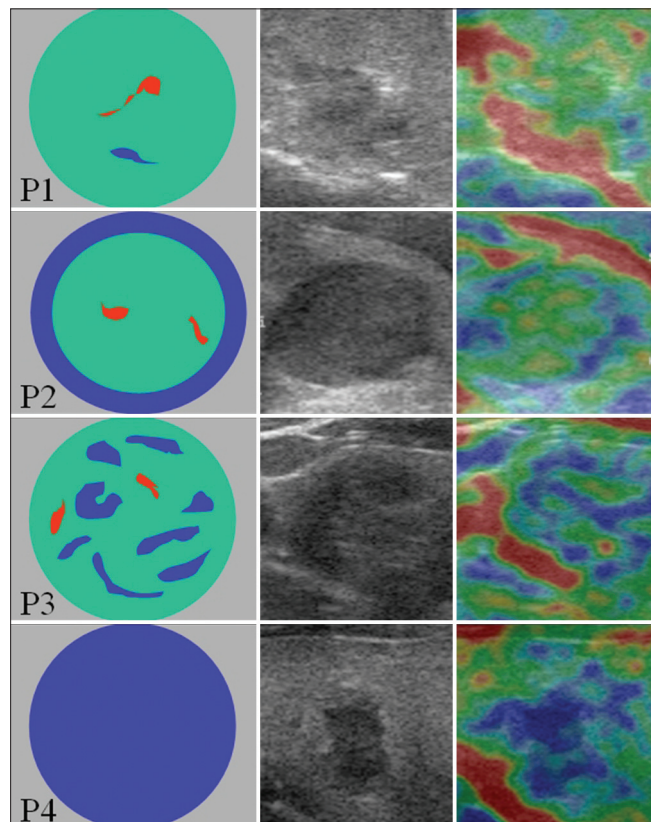
Institutional review board approval was obtained as well as informed consent from all patients prior to each FNAB.

### Patients

The study was performed a tertiary care center of Aurillac, France, from November 2010 to February 2011. During this time period, 21 consecutive adult patients who underwent US-guided FNAB and displayed benign results on cytopathology examination were included in the present study.

### Imaging

Thyroid US examinations were performed by a single radiologist (A. L.) who had a 6-year experience in thyroid imaging.



**Figure 1:** The four different qualitative US elastography patterns

All gray-scale and power Doppler US examinations were performed by using a 4-13 MHz linear probe (Mylab 70; Esaote, Genova, Italy), after having focused and magnified the thyroid nodule.

Gray-scale US features of all thyroid nodules were recorded as follows: volume (ml), anteroposterior/transverse diameter ratio, margin characteristics (regular, irregular), component [solid (homogenous–heterogeneous), predominant solid, mixed, predominant cystic components], echogenicity (hypo, iso, hyperechoic compared to the non-nodular thyroid gland), presence of microcalcifications, macrocalcifications, colloid granulations, perinodular halo, and absence of suspicious sign for malignant adjacent lymph node.

Power Doppler examinations were performed by using the standard equipment settings dedicated to thyroid imaging and a pulse repetition frequency (PRF) of 750 MHz. The vascularization of the nodules was classified in four types as follows: type 0, no Doppler flow within the nodule; type 1, low vascularization; type 2, mild vascularization; and type 3, rich intranodular vascularity. The distribution of the vascularization within the nodule included: predominant central, predominant peripheral, and no predominance of distribution. Whenever possible, the thyroid nodule resistance index (RI) was measured on an intranodular artery. Suspicious malignant qualitative Doppler US features such as rich anarchic intranodular vascularization and large afferent vessels were also sought for.

Qualitative elastography was performed using slight pressing up and down motion of the probe on the patient’s neck. Image acquisitions and interpretation of the examination were performed except in case of thyroid nodules exhibiting a cystic component of mixed echostructure (liquid/solid). The transducer pressure applied on the patient’s neck was standardized by real-time measurement on a numerical scale which was displayed lateral to the elastograms. The thyroid nodule strain elastography image was displayed by using a 256-color mapping scale. The degree of strain within the region of interest was assigned to a given color by using a scale from red (greatest strain, softest component) to green (average strain, intermediate component) to blue (no strain, hardest component). Elastography types were classified into four main patterns: pattern 1, nodule homogenous colored in light green; pattern 2, periphery of the nodule colored in blue; pattern 3, heterogeneous nodule with a mixture of red, green, and blue; and pattern 4, the whole nodule colored in blue. During each thyroid nodule examination, multiple elastography acquisitions per nodule were performed per nodule. We considered the pattern found to be predominant over the multiple acquisitions having been performed per nodule as the “true pattern” of the assessed thyroid nodule.

The elastograms were stored in a picture archiving and communication system and were retrospectively reviewed by a single author (A. L.) blinded to the values at diagnosis. This procedure was chosen to assess the true intra-observer variability.

#### US-guided FNAB

US examination and US-guided FNAB of the thyroid nodule were performed by the same radiologist operator (A. L.) on the same day. Thyroid nodule FNAB was repeated three times on the same nodule by using a 21-G needle under real-time US guidance. The cytopathology sample was smeared across a glass microscope slide for subsequent staining and microscopic examination and sent to the cytopathologist (C. C.). The cytopathologist properly fixed the smear that was identified and labeled.

#### Cytology

All cytologic examinations were performed by the same cytopathologist (C. C.) who had a 10-year experience in thyroid cytology assessment. The results were recorded according to the Bethesda 2008 classification. The degree of cellularity and the abundance of colloid substance were estimated (abundant/poor/absent).

#### Data and statistical analysis

Links between each gray-scale, power Doppler US feature, and cytology (abundance of cellularity–colloid substance) and the different elastographic patterns were calculated by using the  $\chi^2$  test.

## Results

#### Gray scale–Doppler US–cytologic and elastographic pattern features

A total of 19 consecutive patients (16 women and 3 men; mean age 58 years, range 44–76 years) underwent US and US-guided FNAB that represented 22 thyroid nodules (1 nodule in 16 patients and 2 nodules in 3 patients; 1.15 assessed thyroid nodule per patient).

The mean volume of the nodules was 4.7 ml (range 0.22–6.08 ml). The nodule did not exhibit any cystic component in 13 cases (59%). The solid component was found heterogeneous in 14 cases (64%). Colloid granulations were observed in three nodules (14%) and macrocalcifications in two nodules (9%). The operator did not find any microcalcification within the study nodules that were examined. The mean anteroposterior/transverse diameter ratio was 0.74 (0.45–1). Four (18%) nodules showed hypoechogenicity. The nodule margins were ill-defined in two cases (9%). Nine nodules (40%) showed a well-limited halo at the periphery. Four nodules (18%) showed limited vascularization at the nodule periphery exclusively. Regarding thyroid nodule vascularization classification, five nodules (23%) exhibited type 1, 15 (68%) type 2, and 2 (9%)

showed type 3 at quantitative vascularization assessment. Assessment of the RI was performed in 16 nodules, which showed a mean value of 0.55 (range 0.4–0.7 2).

Of 22 thyroid nodules that were examined on qualitative elastography, the strain pattern included a pattern type 1 in 7 patients (32%), pattern 2 in 10 patients (45%), and pattern 3 in 5 patients (23%). Pattern 4 was not found in any case.

Three thyroid nodules (14%) showed poor, 17 (77%) moderate, and 2 (9%) showed abundant cellularity on cytopathological sample assessment. Some colloid substance was found in 10 thyroid nodules (45%).

#### Variability

Five elastography acquisitions were performed in 22 nodules and four in 1 nodule. In 13 nodules (59%), we noted a variation in the pattern among the different acquisitions as follows. In three cases, the three patterns 1, 2, and 3 were displayed. The elastography acquisition result variability involved the “malignant” pattern 3 in 36% of cases [Figure 2].

We did not find any statistically significant correlation ( $P < 0.05$ ) between the elastography patterns and the gray-scale, power Doppler US, and cytological features that were studied. The pattern 3 was linked to the (non-cystic) solid thyroid nodule echostructure ( $P < 0.05$ ).

## Discussion

Theoretically, qualitative US elastography technique may help to select, among the undetermined thyroid nodule group, those that are more suspicious (patterns 3 and 4) of malignancy, thus leading to subsequent thyroidectomy indication. It is presumed to be a useful tool to add to the US semiology of thyroid nodule assessment, and henceforward will be integrated in the Thyroid Imaging Reporting and Data System (TIRADS) classification of thyroid nodules.<sup>[7]</sup> In particular, it has been suggested that the hardness of a thyroid nodule may be indicative for malignancy. US elastography allows the evaluation of the tissue stiffness by grading the degree of tissue distortion under the application of an external force. In this study, we performed qualitative elastographic examinations. As reported in literature, results were displayed into four different patterns reflecting increasing tissue stiffness [Figure 1].<sup>[6]</sup>

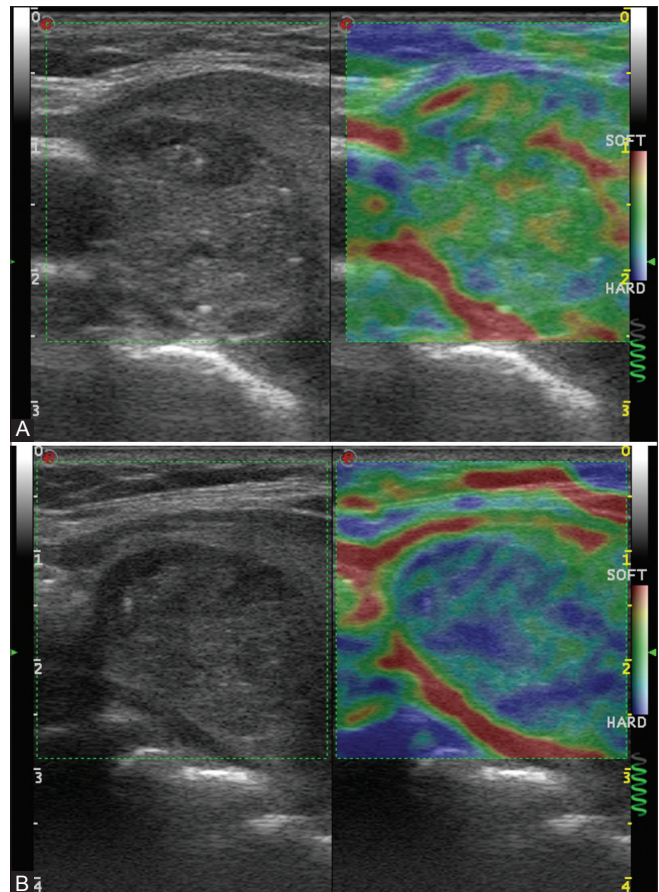
In their prospective study,<sup>[6]</sup> Kagoya *et al.* found 36% (13 out of 36) of benign nodules and 72% (8 out of 11) of malignant nodules showing either pattern 3 or 4. However, the authors did not mention how many benign/malignant nodules exhibited pattern 3 and how many exhibited pattern 4. In the present study, all the examined thyroid nodules were cytologically proven benign on US-guided FNAB

examination and 23% of these benign nodules showed pattern 3. As this pattern was sometimes noted in benign nodules, we state that this pattern is not strongly specific of malignancy, thus should not be taken alone as a strong indicator leading to thyroidectomy. According to our 2-year thyroid nodule qualitative elastography experience, pattern 4 (that was not reported in this series of benign nodules) seems to be far more specific of malignancy. However, we found that when a malignant thyroid nodule exhibited pattern 4 on elastography examination, in any case, the B-mode ultrasonography was found to be strongly suggestive of the thyroid nodule malignancy. As a matter of fact, at least one of the following items including “strong hypoechogenicity,” “microcalcifications,” and “ill-defined margin features” was observed, leading to the scoring as grade 4 or 5, according to the TIRADS classification, whatever thyroid nodule elastography pattern was found.<sup>[4,7]</sup>

Multiple elastography acquisitions per single thyroid nodule were performed to assess the intra-observer reproducibility. We noted a poor reproducibility of the elastography grading including at least two different patterns per nodule that was found in half of the examined nodules. In three cases, the three patterns 1, 2, and 3 were displayed. Although we consider that misgrading patterns 1 and 2 when involving “benign” thyroid nodules does not have any consequences on the patient’s prognosis and follow-up, the intra-observer variability of grading pattern 3 is more challenging. Such variability (23%) suggests that the qualitative elastographic examination may not be so accurate to guide the patient management (e.g. follow-up, FNAB, or surgery). Ning *et al.*, found that a semi-quantitative strain ratio between the nodule and the adjacent normal thyroid tissue was a useful characterization index.<sup>[8]</sup> In their study, thyroid lesions were assessed at least three times and strain average value was recorded. However, information regarding each of these different values was not given; therefore, one cannot draw any definitive conclusion on the strain measurement variability. Finally, recent studies highlighted the presence of a significant inter-observer variability of US elastography in thyroid and breast lesions.<sup>[9,10]</sup>

We guess that the intra-observer variability may be explained by the basic technical aspect of elastography pattern acquisition. As a matter of fact, elastography measurement acquisition requires iterative up and down US probe pressures that indeed depend on the operator strength and also may vary over time with the same individual. Thus, it explains that the elastography acquisition pattern might vary for each acquisition. It has been argued that the use of carotid artery pulsations as a compression source may reduce such an acquisition variability.<sup>[11]</sup>

Conversely, the true quantitative shearwave elastography<sup>[12,13]</sup> does not require iterative compressions and is quite promising due to its insensitivity to lesion



**Figure 2 (A, B):** A 60-year-old man with a 2.2-ml nodule of the right thyroid lobe. The nodule displayed a solid pattern, colloid granulations, and regular margins. Bethesda 2008 cytologic examination showed benignity, presence of colloid substance, and a moderate cellularity. (A) First elastography acquisition showing a pattern type 1; (B) second elastogram showing a pattern type 3

size, reproducibility (operator independence), quality, and accuracy. This technique, which allows true quantitative measures of the examined tissue stiffness (in kPa), may also show intra-/inter-observer variability.<sup>[14]</sup> Indeed, we guess that performing a ratio between absolute strain measure of tumor and normal adjacent thyroid tissue may be more objective and reproducible than qualitative color elastogram acquisition, therefore diminishing the intra- and inter-observer variability.

One limitation of our study was the absence of histopathologic examination as the reference standard to assess the thyroid nodule benignity. Indeed, a false-negative rate of 1–11% is expected when using a sample cytologic examination. As a matter of fact, the diagnosis of follicular carcinoma might be particularly uneasy even with histopathologic examination. Thus, one cannot rule out that some cases exhibiting pattern 3 might be malignant thyroid follicular neoplasms. Another limitation of our study was the absence of assessment of the inter-observer variability. Finally, the results of our study, which only involved 26 patients, must

be corroborated in a larger population study.

## Conclusion

In conclusion, although US elastography is easy to perform and not very time consuming, the intra-observer variability is high, thereby decreasing the US examination accuracy in differentiating benign from malignant thyroid nodules. Indeed, the elastography pattern 3 that was frequently reported among benign thyroid nodules (23%) cannot be used as a strong indicator of potential malignancy. Further studies might be necessary to determine whether the quantitative elastography is a more effective and reproducible technique.

## References

- Guth S, Theune U, Aberle J, Galach A, Bamberger CM. Very high prevalence of thyroid nodules detected by high frequency (13 MHz) ultrasound examination. *Eur J Clin Invest* 2009;39:699-706.
- Baier ND, Hahn PF, Gervais DA, Samir A, Halpern EF, Mueller PR, *et al.* Fine-needle aspiration biopsy of thyroid nodules: Experience in a cohort of 944 patients. *Am J Roentgenol* 2009;193:1175-9.
- Gharib H, Goellner JR. Fine-needle aspiration biopsy of the thyroid: An appraisal. *Ann Intern Med* 1993;118:282-9.
- Kim EK, Park CS, Chung WY, Oh KK, Kim DI, Lee JT, *et al.* New sonographic criteria for recommending fine-needle aspiration biopsy of nonpalpable solid nodules of the thyroid. *AJR Am J Roentgenol* 2002;178:687-91.
- Ophir J, Céspedes I, Ponnekanti H, Yazdi Y, Li X. Elastography: A quantitative method for imaging the elasticity of biological tissues. *Ultrason Imaging* 1991;13:111-34.
- Kagoya R, Monobe H, Tojima H. Utility of elastography for differential diagnosis of benign and malignant thyroid nodules. *Otolaryngol Head Neck Surg* 2010;143:230-4.
- Horvath E, Majlis S, Rossi R, Franco C, Niedmann JP, Castro A, *et al.* An ultrasonogram reporting system for thyroid nodules stratifying cancer risk for clinical management. *J Clin Endocrinol Metab* 2009;94:1748-51.
- Ning CP, Jiang SQ, Zhang T, Sun LT, Liu YJ, Tian JW. The value of strain ratio in differential diagnosis of thyroid solid nodules. *Eur J Radiol* 2012;81:286-91.
- Yoon JH, Kim MH, Kim EK, Moon HJ, Kwak JY, Kim MJ. Interobserver variability of ultrasound elastography: How it affects the diagnosis of breast lesions. *AJR Am J Roentgenol* 2011;196:730-6.
- Park SH, Kim SJ, Kim EK, Kim MJ, Son EJ, Kwak JY. Interobserver agreement in assessing the sonographic and elastographic features of malignant thyroid nodules. *AJR Am J Roentgenol* 2009;193:W416-23.
- Luo S, Lim DJ, Kim Y. Objective ultrasound elastography scoring of thyroid nodules using spatiotemporal strain information. *Med Phys* 2012;39:1182-9.
- Sebag F, Vaillant-Lombard J, Berbis J, Griset V, Henry JF, Petit P, *et al.* Shear wave elastography: A new ultrasound imaging mode for the differential diagnosis of benign and malignant thyroid nodules. *J Clin Endocrinol Metab* 2010;95:5281-8.
- Bercoff J, Tanter M, Fink M. Supersonic shear imaging: A new technique for soft tissue elasticity mapping. *IEEE Trans Ultrason Ferroelectr Freq Control* 2004;51:396-409.
- Marcy PY, Thariat J, Lacout A. Should we catch the train of shear-wave elastography? *AJR Am J Roentgenol* 2012;198:W624-5.

**Cite this article as:** Lacout A, Chevenet C, Thariat J, Figl A, Marcy P. Qualitative ultrasound elastography assessment of benign thyroid nodules: Patterns and intra-observer acquisition variability. *Indian J Radiol Imaging* 2013;23:337-41.

**Source of Support:** Nil, **Conflict of Interest:** None declared.