

## Pan-urethral condylomata acuminata – A primary treatment recommendation based on our experience

Brennan Timm<sup>a,b,\*</sup>, Thea Connor<sup>b</sup>, Peter Liodakis<sup>a,b</sup>, Jyotsna Jayarajan<sup>a,b</sup>

<sup>a</sup> Department of Urology, Austin Health, Heidelberg, VIC, Australia

<sup>b</sup> North Eastern Urology, Heidelberg, VIC, Australia

### ARTICLE INFO

#### Keywords:

Condylomata acuminata  
Urethral warts  
Condyloma acuminatum

### ABSTRACT

We present a case of a 28 year old man presenting with obstructive urinary tract symptoms and cystoscopic findings of pan-urethral, occlusive condylomata acuminata (urethral genital warts). We describe the in rooms administration process of 5-fluorouracil over an 8 week period with follow up cystoscopy results. Urine flow rates improved early in the treatment course from a maximum flow of 7ml/s to 19ml/s and a post void residual improvement from 311ml to 160ml. Significant volume reduction of the warts was achieved allowing for limited treatment with cold excision to minimise urethral stricture risk in a young man.

### Introduction

Isolated urethral condylomata acuminata (CA) is an unusual subgroup of genital warts encountered in 0.5–5% of cases.<sup>1</sup> HPV is sexually transmitted and the low risk groups, DNA types 6 and 11, most commonly cause genital, perineal and anal lesions, which lend themselves to topical treatment.<sup>2</sup> Urethral lesions present a challenge in application particularly if the proximal urethra is involved. First described by Dretler & Klein in 1975<sup>3</sup>, administration of 5-fluorouracil (5FU) to the urethra has been used in the treatment of urethral CA with promising outcomes, although exact administration details are vague.<sup>4</sup> Surgical treatment of intraurethral warts by laser has been successful, although carries with it the risk of fibrosis and in the younger age population we believe the risk of stricture formation is too high.<sup>5</sup> We describe our technique for distribution of topical 5FU treatment to the entire urethra for the treatment of extensive pan-urethral CA and its outcomes in a patient where maximum flow rate (Qmax), post void residual (PVR) and cystoscopy evaluation were used as measures of response.

### Case report

A 28 year old immunocompetent male presented with increasing difficulty voiding over 6 months on a background of previous cystoscopic investigation denoting no cause for obstruction. He was sexually active without concurrent sexually transmitted infection and no history

or examination findings of genital warts. Repeat cystoscopy was undertaken following a result of a Qmax of 7ml/s and PVR of 311ml on a urine flow study. Cystoscopy demonstrated circumferential, pan-urethral polyps from navicular fossa to bladder neck (Fig. 1). The lesions were biopsied and demonstrated acanthopapillomatosis, surface hyperkeratosis and developed koilocytes, which pathologists agreed was consistent with condylomatous histology (Fig. 2). Immunohistochemical staining with p16 was positive which is highly suggestive of human papilloma virus (HPV) infection.

### Discussion

Condylomata acuminata are a frequent presentation of the most common sexually transmitted disease, HPV. CA is associated with low risk HPV (strains 6 and 11) in up to 90% of cases.<sup>5</sup> While CA is associated with low risk HPV, it does not exclude the possibility of malignancy and therefore histological assessment is advised.

A treatment protocol was developed in coordination with the Melbourne Sexual Health Centre. Weekly rather than daily instillation of 5FU was elected for treatment as more significant side effect profiles have been encountered with daily application.<sup>1,2,4</sup> The previous report by Wein et al. utilising self-instillation described as a “squeeze” of 5FU via urethral applicator after every void caused significant meatal ulcers, erosions and burning following treatment.<sup>1</sup> Our induction treatment of 10g of 5FU weekly for 8 weeks avoided complications and was associated with only mild irritative symptoms.

\* Corresponding author. Level 3.02/10 Martin St, Heidelberg, North Eastern Urology and Department of Urology, Austin Health, VIC, 3084, Australia.  
E-mail address: [bttimmz@gmail.com](mailto:bttimmz@gmail.com) (B. Timm).

<https://doi.org/10.1016/j.eucr.2020.101149>

Received 12 February 2020; Received in revised form 25 February 2020; Accepted 27 February 2020

Available online 29 February 2020

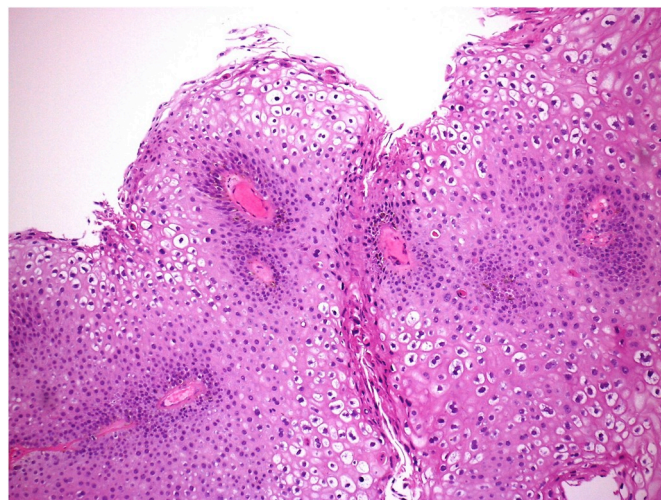
2214-4420/© 2020 Published by Elsevier Inc. This is an open access article under the CC BY-NC-ND license (<http://creativecommons.org/licenses/by-nc-nd/4.0/>).

Combination therapy of surgical and topical treatment has shown improved outcomes compared with single modality treatment alone in recurrent urethral CA.<sup>5</sup> Extensive surgical treatment may lead to stricture formation and therefore we advocate for debulking medical treatment prior to surgical intervention in extensive pan-urethral disease.

Equipment required for our 5FU instillation method: 2% lignocaine gel 10ml, 5FU 10g, Sterile gloves, normal saline, penile clamp, dressing pack (gauze and plastic pots/forceps). NB – all surfaces must be non-metal to preserve function of 5FU.

Procedure: Tube of 5FU is weighed to ensure correct dosage (If > 10g tubes available, able to be split and stored for multiple applications - in consultation with pharmacy). Sterile drape is placed on scales including a sterile pot from catheter tray and contents of tube of 5FU are squeezed into pot and weighed to ensure correct dosage. A 10 ml Lignocaine gel 2% is added to pot with 5FU and mixed with plastic forceps. Using lignocaine syringe, mixture is drawn up and applicator tip is replaced (Fig. 3). The glans penis is cleansed with normal saline and Lignocaine syringe is inserted gently into the urethral meatus where the mixture is slowly instilled. The meatus is manually occluded while the remaining volume of mixture is re-collected and administration is completed. A penile clamp or patient compression at distal glans penis is applied for 30minutes. Following release, the glans is cleansed with normal saline soaked gauze and the patient returns home to void and shower in an effort to avoid irritant side effects.

Following the 8 week induction course, an improvement in Qmax and PVR was demonstrated, most notably prior to the third instillation. Measures of Qmax and PVR following instillation at 1st, 2nd and 8th instillation were 7ml/s, 15ml/s, 19ml/s and 311ml, 230ml and 160ml respectively. Subjective and objective improvement in flow was notable after a single instillation. Increased sloughy debris was noted following fifth treatment, although testing for infection was negative. Surveillance cystoscopy at 9 weeks demonstrated significant volume reduction of the lesions, however a small volume of residual CA at the bladder neck and navicular fossa remained (Fig. 1). These were removed by cold cup biopsy forceps without cautery or laser. The application of 5FU over 8 weeks was repeated a further time in an effort to reduce the risk of recurrence. At check cystoscopy there remained a single papilloma at the navicular fossa which was removed again by cold cup biopsy forceps. Both Wallin et al. and Wein et al. encountered similar difficulties with clearance of CA within the navicular fossa using 5FU.<sup>1,4</sup> Following the findings of recurrence of CA in the navicular fossa after 2 courses of 5FU, we adopted the patient occluding the most distal portion of the glans in an effort to improve instillation time of 5FU and reduce risk of glans



**Fig. 2.** H&E 100x magnification, features suggestive of condylomata acuminata - papillomatosis, surface hyperkeratosis and koilocytic change.

irritation.

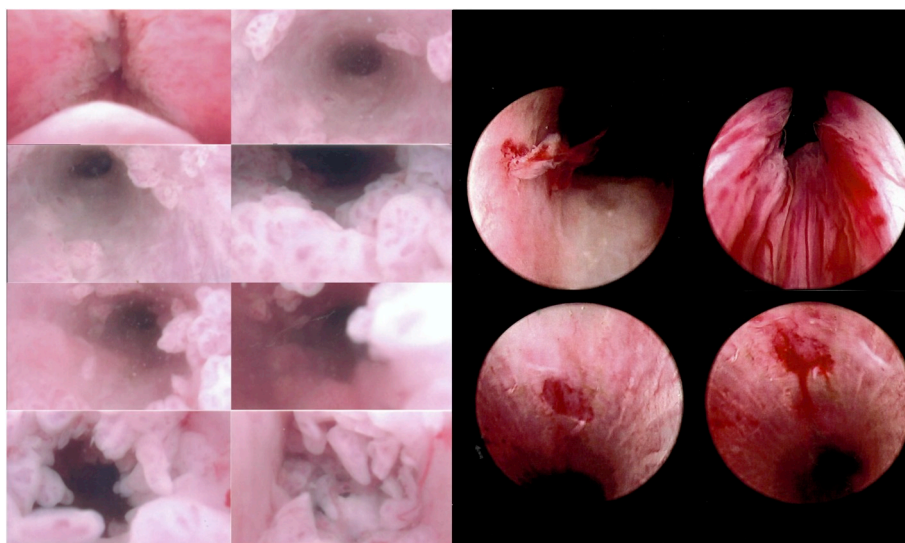
In conclusion in the absence of readily available premixed 5FU compounds for intraurethral application, sterile combination of 5% 5FU with lignocaine 2% gel allows for a technically feasible and tolerable treatment regimen to minimise disease burden. This decrease in disease volume diminishes the need for extensive surgical intervention which may lead to urethral strictures in the younger populations. Notably since the introduction of Quadrivalent HPV vaccination in 2007 there has been a declining incidence of genital warts, and, in time, urethral warts are likely to be relegated to the annals of historical curiosities.

#### Consent

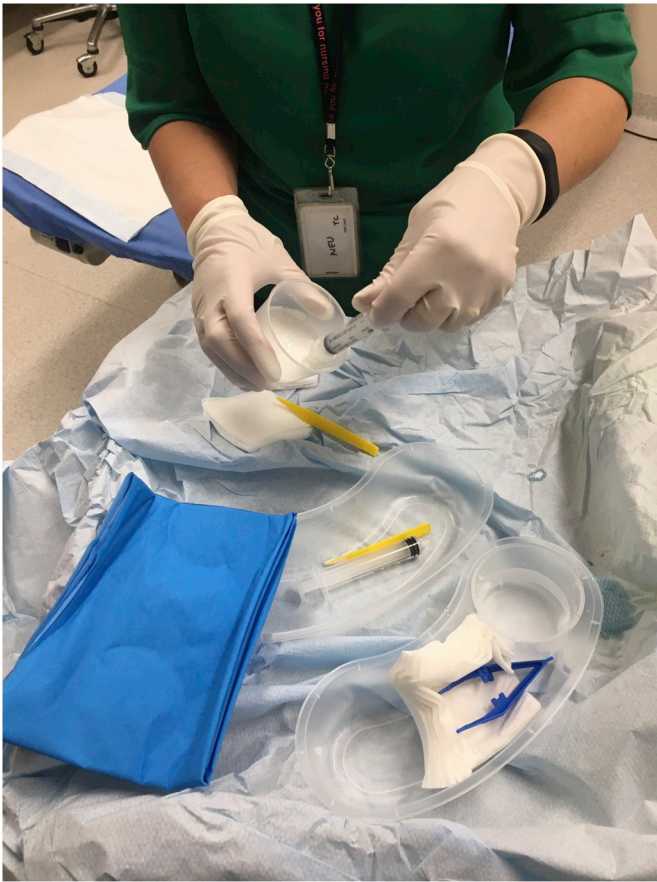
Written consent was obtained from the patient in regard to the publication of photographs and article content for educational purposes.

#### Declaration of competing interest

We declare no conflicts of interest and no funding sources in the presentation of these works.



**Fig. 1.** Cystoscopy findings pre-treatment and post treatment with urethral 5FU and focal surgical treatment.



**Fig. 3.** Equipment set up and administration preparation by our practise nurse. NB – Importance of all plastic utensils to avoid metal ion binding and making the 5FU less effective.

### References

1. Wein AJ, Benson GS. Treatment of urethral condyloma acuminatum with 5-fluorouracil cream. *Urology*. 1977;9(4):413–415.
2. Gammon DC, Reed KA, Patel M, Balaji KC. Intraurethral fluorouracil and lidocaine for intraurethral condyloma acuminata. *Am J Health Syst Pharm*. 2008;65(19):1830–1833.
3. Dretler SP, Klein LA. The eradication of intraurethral condyloma acuminata with 5 per cent 5-fluorouracil cream. *J Urol*.113(2):195-198.
4. Wallin J. 5-Fluorouracil in the treatment of penile and urethral condylomata acuminata. *Br J Vener Dis*. 1977;53(4):240–243.
5. Florin HJ, Snoeck R, Van Cleynenbreugel B, Albersen M. Treatment of intraurethral condylomata acuminata with surgery and cidofovir instillations in two immunocompromised patients and review of the literature. *Antivir Res*. 2018;158:238–243.