

Clinical Article

Surgical Outcomes and Complications after Occipito-Cervical Fusion Using the Screw-Rod System in Craniocervical Instability

Sung Ho Choi, M.D., Sang Gu Lee, M.D., Ph.D., Chan Woo Park, M.D., Ph.D., Woo Kyung Kim, M.D., Ph.D.,
Chan Jong Yoo, M.D., Ph.D., Seong Son, M.D.

Department of Neurosurgery, Gachon University, Gil Hospital, Incheon, Korea

Objective : Although there is no consensus on the ideal treatment of the craniocervical instability, biomechanical stabilization and bone fusion can be induced through occipito-cervical fusion (OCF). The authors conducted this study to evaluate efficacy of OCF, as well as to explore methods in reducing complications.

Methods : A total of 16 cases with craniocervical instability underwent OCF since the year 2002. The mean age of the patients was 51.5 years with a mean follow-up period of 34.9 months. The subjects were compared using lateral X-ray taken before the operation, after the operation, and during last follow-up. The Nurick score was used to assess neurological function pre and postoperatively.

Results : All patients showed improvements in myelopathic symptoms after the operation. The mean preoperative Nurick score was 3.1. At the end of follow-up after surgery, the mean Nurick score was 2.0. After surgery, most patients' posterior occipito-cervical angle entered the normal range as the pre operation angle decreased from 121 to 114 degree. There were three cases with complications, such as, vertebral artery injury, occipital screw failure and wound infection. In two cases with cerebral palsy, occipital screw failures occurred. But, reoperation was performed in one case.

Conclusion : OCF is an effective method in treating craniocervical instability. However, the complication rate can be quite high when performing OCF in patients with cerebral palsy, rheumatoid arthritis. Much precaution should be taken when performing this procedure on high risk patients.

Key Words : Atlanto-occipital joint · Postoperative complications · Cerebral palsy · Rheumatoid arthritis.

INTRODUCTION

The occipito-cervical junction is a unique, complex, biomechanical interface between the cranium and the upper cervical spine³³. Instability at the craniocervical junction may cause compression of the spinal cord or medulla oblongata, triggering myelopathy, intractable neck pain or progressive disability³². Although there is no consensus on the ideal treatment of the occipito-cervical instability, biomechanical stabilization and bone fusion can be induced through occipito-cervical fusion (OCF).

OCF is a method that has been used to achieve stabilization in congenital deformities causing instability and dislocation of the skull and cervical vertebrae, post-traumatic deformities, rheumatoid arthritis, and tumors in the upper cervical verte-

brae³⁴. The goals of OCF are to stabilize the mechanically compromised occipito-cervical junction, correct deformity or displacement, and decompress compromised neural structures. The goals of instrumentation are to provide immediate stability, improve fusion rate, diminish the need for postoperative external immobilization, and decrease rehabilitation time³².

There have, however, been many reports on the complications of such an operation. The commonly reported complications include vertebral artery injury, dura tear, cerebrospinal fluid (CSF) leakage, wound infection, nerve or cord injury, screw failure, and bone fusion failure.

The authors conducted this study based on their hospital cases to evaluate clinical results and efficacy of OCF, as well as to explore methods in reducing complications.

• Received : December 13, 2012 • Revised : February 12, 2013 • Accepted : April 8, 2013

• Address for reprints : Sang Gu Lee, M.D., Ph.D.

Department of Neurosurgery, Gachon University, Gil Hospital, 21 Namdong-daero 774beon-gil, Namdong-gu, Incheon 405-760, Korea

Tel : +82-32-460-3304, Fax : +82-32-460-3899, E-mail : samddal@gilhospital.com

• This is an Open Access article distributed under the terms of the Creative Commons Attribution Non-Commercial License (<http://creativecommons.org/licenses/by-nc/3.0>) which permits unrestricted non-commercial use, distribution, and reproduction in any medium, provided the original work is properly cited.

MATERIALS AND METHODS

All patients treated by OCF were included in this study. The patients were reviewed based on their electrical medical records regarding age, sex, clinical course, radiological results, and complications.

A total of 16 patients were chosen for this study. These subjects received OCF at our hospital since the year 2002 and were followed up for at least 12 months. Eight of them were females and eight were males. The mean follow-up period was 34.9 months (range, 12-108 months) and mean age was 51.5 years (range, 24-74 years).

The etiologies of their occipito-cervical instability included trauma, rheumatoid arthritis, degeneration, tumor and os odontoideum, tuberculosis.

The surgery was performed with the patients' head fixed with a Mayfield head holder in the prone position. Midline incisions were made, from external occipital protuberance to the cervical area in need of surgery. After adequate exposure of the suboccipital and posterior cervical areas, occipital screws and plate, C1-2 transarticular screws, lateral mass screws were placed under the fluoroscope. Then, total cervical laminectomy with or without suboccipital craniectomy was performed followed by the assembly of rods, nuts and necessary wiring. The subject re-

ceived are summarized in Table 1.

The subjects were compared using lateral neutral plain X-ray films taken before the operation, after the operation, and during last follow-up. Lateral X-rays were taken in the posterior occipito-cervical neutral posture, and the occipito-cervical angles were measured using the methods presented by Riel et al.²⁶.

The posterior occipito-cervical angle (POCA)²⁶ is defined as the angle formed by the intersection of a line drawn tangential to the flat posterior aspect of the occiput between the foramen magnum and occipital protuberance and the line determined by the posterior aspect of the third and fourth cervical facets.

The Nurick score was used to assess neurological function pre and postoperatively. An increase in the score represents deterioration of symptoms, a decrease represents improvement, and a stationary score represents no change.

Statistical analysis

SPSS version 14.0 (SPSS Inc., Chicago, IL, USA) was used to analyze all data. The paired sample t-test was used. Statistical significance was accepted for *p* values of *p*<0.05.

RESULTS

Twelve patients presented with myelopathy before the surgery and none of them experienced deterioration in neurologic function after the surgery. The mean pre operative Nurick score was 3.1 (range, 1-5), and the mean Nurick score at the end of follow-ups after the surgery was 2.0 (range, 0-5), with a mean advancement of 1.1 points (*p*=0.000).

Normal distribution of measurements in a previous report revealed that 80% of the POCA values lied between 101 and 119 degrees³³. Considering the normal POCA range to be between 101 to 119 degrees as suggested by the article above, before OCF, only four patients presented with normal POCA (range, 89-137 degree). After surgery, most patients' posterior occipito-cervical angle entered the normal range as the pre operation angle decreased from

Table 1. Clinical data of patients who received posterior occipitocervical fusion

| Patient | Sex | Age | Underlying disease | Etiology |
|---------|-----|-----|-----------------------|----------------|
| 1 | M | 57 | Multiple myeloma | Tumor |
| 2 | F | 73 | - | RA |
| 3 | F | 71 | - | Trauma |
| 4 | M | 33 | - | Trauma |
| 5 | F | 61 | - | RA |
| 6 | M | 34 | - | Trauma |
| 7 | M | 48 | Cerebral palsy | Trauma |
| 8 | M | 52 | - | Trauma |
| 9 | M | 43 | - | Trauma |
| 10 | F | 58 | - | Os odontoideum |
| 11 | F | 74 | Cerebral palsy | Degeneration |
| 12 | F | 49 | - | RA |
| 13 | F | 50 | - | Trauma |
| 14 | F | 45 | Klippel Feil syndrome | Deneration |
| 15 | F | 48 | Klippel Feil syndrome | Trauma |
| 16 | M | 35 | - | Tuberculosis |

Table 2. Clinical outcomes of patients in relation to the etiology

| Outcomes | Cases | | Etiology | | | | | |
|--------------|-------|------|----------------|----|--------|--------------|-------|--------------|
| | No. | % | Os odontoideum | RA | Trauma | Degeneration | Tumor | Tuberculosis |
| Improved | 11 | 68.8 | 1 | 2 | 5 | 1 | 1 | 1 |
| Stationary | 5 | 31.2 | | 1 | 3 | 1 | | |
| Deteriorated | 0 | 0 | | | | | | |
| Total | 16 | | 1 | 3 | 8 | 2 | 1 | 1 |

121 to 114 (range, 102-125 degree) degrees with only two cases in which the patients' POCA were not within the normal range. These data were evaluated significant correction of the POCA into the normal range ($p=0.011$).

Complications of OCF in our study include vertebral artery injury, screw failure, screw loosening and wound infection (Table 3).

Vertebral artery injury was observed in one case (patient 11). The respective patient underwent a carotid CT angiography prior to receiving OCF, which revealed an abnormal vertebral artery course. Bleeding occurred from an injury during screw fixation of the second cervical vertebrae, which was quickly controlled. No neurological injury was observed as a result of the vertebral artery injury after the surgery.

Occipital screw failure occurred in the same patient (patient 11). The subject was a known to have cerebral palsy patient with involuntary movement and resting tremor (Fig. 1). During a follow-up observation, increased cervical pain and bilateral paraplegia was observed, and screw failure was detected during routine radiological examinations. Reoperation was performed, and the range of screw fixation was extended during the second operation to ensure stabilization. As a result stabilization was observed in the following radiological examination.

Screw loosening was detected in a different cerebral palsy patient (patient 7) in a routine X-ray follow-up. Despite such findings, the patient showed no signs of neurologic deterioration, and is currently under observation. Screw instability was observed in another patient (patient 2), and reoperation was necessary to reposition the screw.

Wound infection was observed in one patient (patient 5) with rheumatoid arthritis. During follow-up observations, the screw was decided to be removed as it seemed to worsen infection. The screw was removed, yet sufficient fusion was observed and the patient did not undergo additional surgical procedures. The patient is also currently under observation. Wound infection was also observed in one different patient (patient 10). The patient recovered from the infection and was discharged after antibiotic therapy and wound debridement.

Two patients (patient 14, 15) had Klippel-Feil syndrome as an underlying disease, and is currently under observation without any complications.

Mycobacterium tuberculosis was identified in a sputum culture in a patient (patient 16) who had been diagnosed with pulmonary tuberculosis ten years ago. Tuberculosis of the spine was confirmed in this patient and the patient underwent abscess removal and OCF. This patient is also under observation without any neurologic deficit or complications.

DISCUSSION

The goals of OCF are to regain normal alignment, to ensure

Table 3. Complications of patients who received posterior occipitocervical fusion

| Complication type | No | Incidence (%) |
|---------------------------------|----|---------------|
| Screw failure | 2 | 12.5 |
| Screw loosening | 1 | 6.3 |
| Wound infection | 1 | 6.3 |
| Wound infection & screw failure | 1 | 6.3 |
| Vertebral artery injury | 1 | 6.3 |

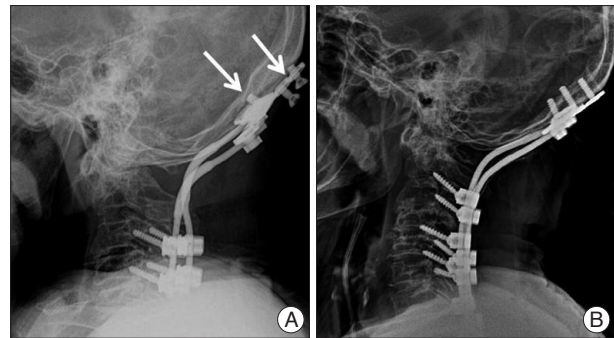


Fig. 1. Occipital screw failure in cerebral palsy patient. A : Occipital screw failure occurred at occipital plate during follow up period. B : Post reoperation plain X-ray.

adequate neural tissue decompression and to achieve structural stability. Various metallic internal fixations have been developed to increase the success of bone fusion and stabilization while reducing the necessity of external fixation. Many operational methods using anterior and posterior approaches have been reported ever since the first OCF using nasal bone graft was reported by Foerster in 1927⁴⁾.

While early methods depended on an anterior approach for an on-lay graft of the autograft bone without internal fixation, complications such as non-fusion and pseudoarthrosis occurred due to the lengthy recovery period and long-term external fixation. This resulted in the need for internal fixation using materials such as wires and screws.

Accordingly, more solid screw fixations such as metal plate and screw fixation (Roy-Camille plate, AO reconstruction plate) and Cotrel-Dubouset occipito-cervical rod were developed^{11,14,22,25,27,28,30)} and are widely used in OCF. Such metal fixation has been shown to be advantageous in reducing nerve injury and infection while obtaining stabilization.

In the current study, the authors determined through symptom improvement and follow-up neutral X-rays that OCF is effective in improving instability and neurologic injuries in craniocervical instabilities.

Diverse OCF techniques such as screw-rod and occipito-cervical hook are currently available, and they have all shown to have high fusion rates (89-100%)^{8,10,12,16,23)}. Screw-rod fixation allows for strong biomechanical fixation, obtaining stability immediately after operation and requiring no additional external fixation^{10,16,24,34)}.

The etiologies of occipito-cervical instability included os odontoideum, rheumatoid arthritis, trauma, degeneration, tumor

and tuberculosis.

Os odontoideum disease results in the formation of a separate bone structure due to abnormal fusion between the odontoid process of the second cervical vertebra and the body. In the absence of a united odontoid process, the atlanto axial movements appear to be supported only by ligaments, resulting in atlanto axial instability⁹⁾. According to some authors, in minimally symptomatic or asymptomatic patients with os odontoideum without C1-2 instability, good treatment outcomes can be obtained using conservative management without surgical treatment^{7,18,20,31)}.

Rheumatoid arthritis of the cervical spine leads to a spectrum of joint erosions and deformity resulting in spinal stability. The most common patterns of cervical instability seen in rheumatoid arthritis are atlanto axial subluxation, followed by basilar invagination and subaxial subluxation. Combined patterns of cervical instabilities are not uncommon in rheumatoid arthritis^{3,5,6,29)}.

The authors of this study observed atlanto-occipital dislocation in many cases where OCF was performed to treat traumatic injuries. Atlanto-occipital dislocations are high energy injuries that are usually fatal due to accompanying lacerations of the ponto-medullary or spino-medullary junctions¹⁷⁾. Atlanto-occipital dislocation should be immediately reduced and stabilized with halo vest immobilization. Traction should be avoided. Because of the severe ligamentous damage and the highly unstable nature of the injury, definitive fixation with occipitocervical fusion is required universally³²⁾.

Atlanto axial dislocation is the most frequent anomaly seen in cases with craniovertebral tuberculosis^{15,21)}. Behari et al.²⁾ reported the protocol of surgical management of craniocervical tuberculosis in 2003. In their study, patients with severe deficits due to significant cervico-medullary compression caused by fixed Atlanto axial dislocation or bone destruction and granulation had anterior decompression and posterior fusion done. Patients with persistent reducible Atlanto axial dislocation underwent only posterior fusion²⁾.

The authors of this study also discovered that although Klippel-Feil syndrome may not be a direct cause of craniocervical instabilities, it can facilitate them. Unlike a person with normal cervical spine structure, patients with Klippel-Feil syndrome display limitations in flexion, extension, and lateral flexion³⁵⁾. In addition, a wide range of spinal abnormalities such as scoliosis, spina bifida, hemivertebrae, occipito-atlanto fusion, basilar invagination may be accompanied in such patients. There is also a higher risk of neurologic deficit development with even minor traumatic injuries in Klippel-Feil syndrome patients. The reason is believed to be that as the traumatic force is inflicted onto the fused cervical vertebrae, the force is also transferred to the normal adjacent segments causing excessive movement¹⁹⁾.

Reported complications of OCF include screw failure, wound infection, dura tear, CSF leakage and failure to reduce neurological pain^{8,10,16)}.

Screw failure was reported to occur in 7% (1/16) in one study¹⁰⁾

and 4.2% (1/24)¹¹⁾ in another study. Additional external fixation through Halo-vest or additional screw fixation was attempted in the cases of patients that showed screw failure. At our institution, we observed screw failure in 12.5% (2/16) of the subjects and screw loosening in 6.3% (1/16). Screw loosening and failure due to involuntary movement in a cerebral palsy patient was observed. Screw failure in cerebral palsy patients have already been reported by many other studies, and in such cases occipital screw fixation should be performed with bicortical screws using biomechanical methods to prevent screw failure. The pullout strength of occipital screws is proportional to the thickness of screw purchase, and the pullout strength of a bicortical screw purchase is 50% greater than that of a unicortical screw purchase¹³⁾. Great stabilization can be obtained by performing stronger screw fixation.

Wound infection occurred in 13.3% (2/16) of patients in our study. In one case we removed the screw that was suspected as the infection source; in the other case, the subject improved with antibiotic therapy and was discharged. The patients are being followed up on an outpatient basis. Other studies have already reported wound infections; wound infection was reported in 11% (1/9)¹⁶⁾ by one study and 3.8% (1/26)¹¹⁾ by another study. In both studies, infection was treated using antibiotics without the removal of inserted materials.

Dura tear is reported in 0-4.2% of all cases when creating burr holes or performing screw fixation^{1,10,16)}. Dura tear is also known as the most frequent complication related to wire fixation during burr hole formation or wire winding, and it has been reported to occur in 25-28% of all patients^{10,16)}. Dura tear was not observed at our institute.

The authors observed improvements in myelopathic symptoms in 68.8% (11/16) of the subjects using the Nurick score, and neurological pain was reduced by 78-95% in patients who showed bone fusion^{1,10,16)}.

There is no best method for OCF, and the method of surgery should be based on the type of instability, the integrity of posterior cervical elements, the extension of decompression, comorbidities, individual anatomic variation, and the surgeon's familiarity with the techniques.

CONCLUSION

Based on the results above, the authors of this study determined that OCF is useful in the acquisition of bone fusion and spinal stabilization, as well as in the recovery of neurologic deficit.

The results of OCF in 16 cases at our hospital were generally satisfactory. OCF can result in complications due to vertebral artery injury, dura tear, non-fusion of bone, screw loosening and screw failure, wound infection, and CSF leakage.

OCF is a very useful technique in maintaining stabilization; however, as our study and previous studies have shown, the complication rate is quite high in performing such procedure on cerebral palsy, rheumatoid arthritis patients. Much more precau-

tion must be taken in performing OCF in high risk patients.

References

1. Abumi K, Takada T, Shono Y, Kaneda K, Fujiya M : Posterior occipito-cervical reconstruction using cervical pedicle screws and plate-rod systems. *Spine (Phila Pa 1976)* **24** : 1425-1434, 1999
2. Behari S, Nayak SR, Bhargava V, Banerji D, Chhabra DK, Jain VK : Craniocervical tuberculosis : protocol of surgical management. *Neurosurgery* **52** : 72-80; discussion 80-81, 2003
3. Boden SD, Dodge LD, Bohlman HH, Rehtine GR : Rheumatoid arthritis of the cervical spine. A long-term analysis with predictors of paralysis and recovery. *J Bone Joint Surg Am* **75** : 1282-1297, 1993
4. Carlson GD, Bohlman HH : Surgical techniques for occiput to C2 arthrodesis in Dillin WH, Simeone FA (eds) : *Posterior Cervical Spine Surgery*, ed 3. Philadelphia : Lippincott-Raven Publishers, 1998
5. Clark CR, Goetz DD, Menezes AH : Arthrodesis of the cervical spine in rheumatoid arthritis. *J Bone Joint Surg Am* **71** : 381-392, 1989
6. Clark CR, Keggi KJ, Panjabi MM : Methylmethacrylate stabilization of the cervical spine. *J Bone Joint Surg Am* **66** : 40-46, 1984
7. Clements WD, Mezue W, Mathew B : Os odontoideum--congenital or acquired?--that's not the question. *Injury* **26** : 640-642, 1995
8. Deutsch H, Haid RW Jr, Rodts GE Jr, Mummaneni PV : Occipitocervical fixation : long-term results. *Spine (Phila Pa 1976)* **30** : 530-535, 2005
9. Ding X, Abumi K, Ito M, Sudo H, Takahata M, Nagahama K, et al. : A retrospective study of congenital osseous anomalies at the craniocervical junction treated by occipitocervical plate-rod systems. *Eur Spine J* **21** : 1580-1589, 2012
10. Fehlings MG, Errico T, Cooper P, Benjamin V, DiBartolo T : Occipitocervical fusion with a five-millimeter malleable rod and segmental fixation. *Neurosurgery* **32** : 198-207; discussion 207-208, 1993
11. Grob D, Dvorak J, Panjabi MM, Antinnes JA : The role of plate and screw fixation in occipitocervical fusion in rheumatoid arthritis. *Spine (Phila Pa 1976)* **19** : 2545-2551, 1994
12. Grob D, Schütz U, Plötz G : Occipitocervical fusion in patients with rheumatoid arthritis. *Clin Orthop Relat Res* : 46-53, 1999
13. Hafer TR, Yeung AW, Caruso SA, Merola AA, Shin T, Zipnick RI, et al. : Occipital screw pullout strength. A biomechanical investigation of occipital morphology. *Spine (Phila Pa 1976)* **24** : 5-9, 1999
14. Heidecke V, Rainov NG, Burkert W : Occipito-cervical fusion with the cervical Cotrel-Dubousset rod system. *Acta Neurochir (Wien)* **140** : 969-976, 1998
15. Hong JM, Lee SG, Park CW, Yoo CJ, Kim WK : Tuberculosis of the craniovertebral junction with basilar impression : a case report. *Korean J Spine* **7** : 103-106, 2010
16. Hsu YH, Liang ML, Yen YS, Cheng H, Huang CI, Huang WC : Use of screw-rod system in occipitocervical fixation. *J Chin Med Assoc* **72** : 20-28, 2009
17. Jung JW, Lee SG, Kim IC, Yoo CJ, Kim WK, Park CW : A survived traumatic Atlanto-Occipital Dislocation. *Korean J Spine* **4** : 62-66, 2007
18. Kim IS, Hong JT, Jang WY, Yang SH, Sung JH, Son BC, et al. : Surgical treatment of os odontoideum. *J Clin Neurosci* **18** : 481-484, 2011
19. Kim KN, Park KS, Kim HW, Chung CK : Progressive quadriparesis following a minor trauma in a patient with Klippel-Feil syndrome : case report. *J Korean Neurosurg Soc* **31** : 192-194, 2002
20. Klimo P Jr, Kan P, Rao G, Apfelbaum R, Brockmeyer D : Os odontoideum : presentation, diagnosis, and treatment in a series of 78 patients. *J Neurosurg Spine* **9** : 332-342, 2008
21. Lal AP, Rajshekhar V, Chandy MJ : Management strategies in tuberculous atlanto-axial dislocation. *Br J Neurosurg* **6** : 529-535, 1992
22. McAfee PC, Cassidy JR, Davis RF, North RB, Ducker TB : Fusion of the occiput to the upper cervical spine. A review of 37 cases. *Spine (Phila Pa 1976)* **16 (10 Suppl)** : S490-S494, 1991
23. Motosuneya T, Hirabayashi S, Yamada H, Sakai H : Occipitocervical fusion using a hook and rod system between cervical levels C2 and C3. *J Clin Neurosci* **16** : 909-913, 2009
24. Oda I, Abumi K, Sell LC, Haggerty CJ, Cunningham BW, McAfee PC : Biomechanical evaluation of five different occipito-atlanto-axial fixation techniques. *Spine (Phila Pa 1976)* **24** : 2377-2382, 1999
25. Paquis P, Breuil V, Lonjon M, Euller-Ziegler L, Grellier P : Occipitocervical fixation using hooks and screws for upper cervical instability. *Neurosurgery* **44** : 324-330; discussion 330-331, 1999
26. Riel RU, Lee MC, Kirkpatrick JS : Measurement of a posterior occipitocervical fusion angle. *J Spinal Disord Tech* **23** : 27-29, 2010
27. Sakou T, Kawaida H, Morizono Y, Matsunaga S, Fielding JW : Occipitotlantoaxial fusion utilizing a rectangular rod. *Clin Orthop Relat Res* : 136-144, 1989
28. Sasso RC, Jeanneret B, Fischer K, Magerl F : Occipitocervical fusion with posterior plate and screw instrumentation. A long-term follow-up study. *Spine (Phila Pa 1976)* **19** : 2364-2368, 1994
29. Shen FH, Samartzis D, Jennis LG, An HS : Rheumatoid arthritis : evaluation and surgical management of the cervical spine. *Spine J* **4** : 689-700, 2001
30. Smith MD, Anderson P, Grady MS : Occipitocervical arthrodesis using contoured plate fixation. An early report on a versatile fixation technique. *Spine (Phila Pa 1976)* **18** : 1984-1990, 1993
31. Spierings EL, Braakman R : The management of os odontoideum. Analysis of 37 cases. *J Bone Joint Surg Br* **64** : 422-428, 1982
32. Vaccaro AR, Lim MR, Lee JY : Indications for surgery and stabilization techniques of the occipito-cervical junction. *Injury* **36 Suppl 2** : B44-B53, 2005
33. Vender JR, Houle PJ, Harrison S, McDonnell DE : Occipital-cervical fusion using the Locksley intersegmental tie bar technique : long-term experience with 19 patients. *Spine J* **2** : 134-141, 2002
34. Wertheim SB, Bohlman HH : Occipitocervical fusion. Indications, technique, and long-term results in thirteen patients. *J Bone Joint Surg Am* **69** : 833-836, 1987
35. Yoon SM, Park CW, Yoo CJ, Kim WK, Lee SG : Kippel-Feil syndrome associated with various anomalies in the cervical spine. *Korean J Spine* **4** : 232-235, 2007