

The Progression of Peripapillary Retinoschisis May Indicate the Progression of Glaucoma

Eun Jung Lee, Hyun Joo Kee, Jong Chul Han, and Changwon Kee

Department of Ophthalmology, Samsung Medical Center, Sungkyunkwan University School of Medicine, Seoul, Korea

Correspondence: Changwon Kee, Department of Ophthalmology, Samsung Medical Center, Sungkyunkwan University School of Medicine, Irwon-ro 81, Gangnam-gu, Seoul 06351, Korea; ckee@skku.edu.

Received: October 26, 2020

Accepted: January 24, 2021

Published: February 16, 2021

Citation: Lee EJ, Kee HJ, Han JC, Kee C. The progression of peripapillary retinoschisis may indicate the progression of glaucoma. *Invest Ophthalmol Vis Sci.* 2021;62(2):16. <https://doi.org/10.1167/iovs.62.2.16>

PURPOSE. To identify the temporal correlation between the increase in peripapillary retinoschisis (PPRS) and glaucoma progression during PPRS fluctuation.

METHODS. We performed a comparative clinical timeline analysis for PPRS and glaucomatous progression in eyes with PPRS. In particular, the interval between the increase in PPRS extent and glaucoma progression was analyzed. Temporal correlation was defined when the interval was less than one year between glaucoma progression and PPRS increase, including both de novo development and an increase in the amount of retinoschisis on serial optical coherence tomography.

RESULTS. We included 33 eyes of 30 patients, with an average follow-up period of 7.5 ± 3.0 years and a total of 253 glaucoma examinations. Glaucoma progression was observed in 21 of 33 eyes; 19 (90.5%) of the 21 eyes with glaucoma progression and 29 (74.4%) of the 39 episodes of PPRS increase showed temporal correlation. The de novo development of PPRS during the follow-up period over baseline PPRS was more frequently observed in the glaucoma progression group than in the no-progression group ($P = 0.006$).

CONCLUSIONS. In glaucomatous eyes with PPRS, the increase in PPRS temporally correlated with glaucoma progression. Possible glaucoma progression may be considered around the time of increase and de novo development of PPRS.

Keywords: Peripapillary retinoschisis, Glaucoma, Progression, Glial cells

Peripapillary retinoschisis (PPRS) is an abnormal splitting of the intraretinal layers around the optic nerve head (ONH). It is associated with glaucoma, because it is observed more frequently in patients diagnosed or suspected with glaucoma (1.0%–6.0%) than in healthy subjects (0.5%).^{1–5} Moreover, it is closely related to glaucoma progression.^{1–7} However, the specific pattern or mechanism of the relationship has not been elucidated because of its rarity. Only one study evaluated the rate of glaucoma progression associated with PPRS through a case-control design,⁷ whereas most published articles were case reports or case series.

Despite PPRS being a fluctuating phenomenon with episodic occurrences and resolution,^{3,4,7,8} its episodic variations have not been analyzed in relation to glaucoma progression. However, the concept of PPRS fluctuation has been clearly recognized. The “time span” or interval around the PPRS episodes has been considered; eyes underwent more rapid glaucoma progression over time when PPRS occurs, progressive retinal nerve fiber layer (RNFL) thinning was apparent during the “time span” over which PPRS occurrence-relapsing events transpire,⁷ and the visual field (VF) worsened “within 11 months” of its detection.⁶ Thus we suspected that the increase and decrease of PPRS might reflect the underlying status of glaucomatous damage.

In this study, we focused on dynamic changes in PPRS by using the temporal profiling method. The clinical timelines of the longitudinal course of PPRS and glaucoma were used to investigate the temporal relationship between PPRS evolution and glaucoma progression.

METHODS

The entire medical records of patients who had visited our glaucoma clinic from July 2019 to June 2020 were retrospectively reviewed to identify patients with any episode of PPRS in the follow-up period. The study protocol was approved by the Institutional Review Board of the Samsung Medical Center. The requirement for informed consent was waived owing to the retrospective nature of the study. All procedures were performed in accordance with the tenets of the Declaration of Helsinki.

Patient Inclusion and Examination

Patients diagnosed with glaucoma who had developed any episode of PPRS in the follow-up period were included, and the entire medical records were used for the analysis.

The exclusion criteria were (1) conditions that could produce retinal edema, including optic disc coloboma, congenital optic pit maculopathy, or severe epiretinal membrane; (2) poor-quality optical coherence tomography (OCT) scans; and (3) fewer than three visits with sets of glaucoma examinations, comprising the simultaneous VF test, color and red-free photographs, and OCT.

Measurements of visual acuity and refraction; Goldmann applanation tonometry for intraocular pressure (IOP); slit-lamp biomicroscopy with gonioscopy; dilated stereoscopic examination of the ONH; color, red-free, and infrared fundus photography; Humphrey Swedish interactive thresh-

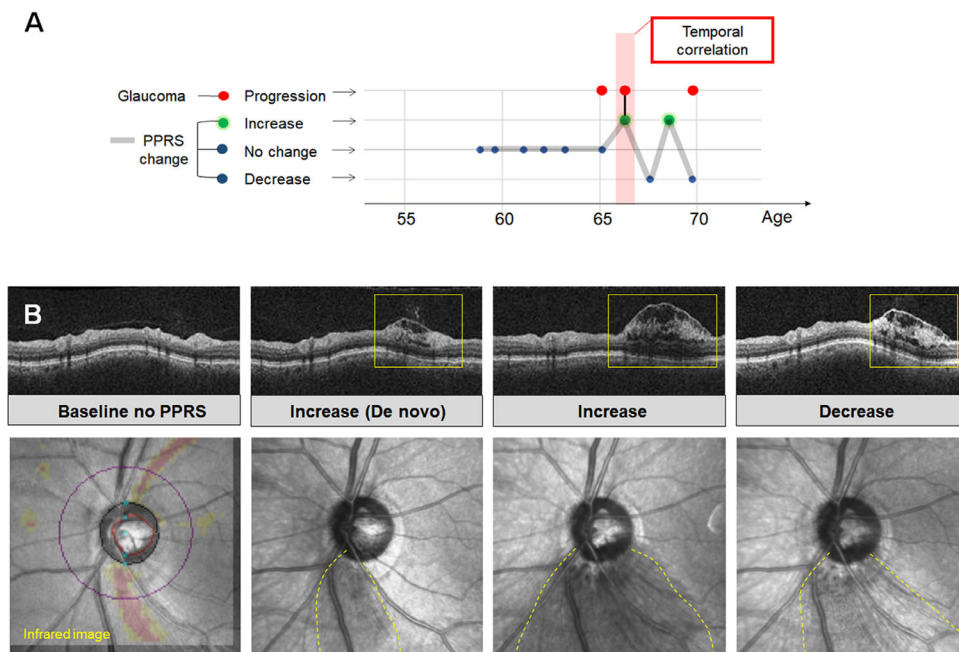


FIGURE 1. Clinical timeline of peripapillary retinoschisis (PPRS) and glaucoma progression. **(A)** The increase and decrease in the extent of PPRS were plotted by classifying them as increasing, decreasing, or no change (*gray line* shows the schematic course). Events of glaucoma progression were also plotted to identify temporal correlation when the interval between PPRS increase and glaucoma progression was less than one year (*red bar*). **(B)** The example shows the de novo development, increase, and decrease of PPRS with optical coherence tomography peripapillary circular scans and infrared images, respectively. *Yellow dotted lines* demarcate the approximate boundary of PPRS on infrared images.

old algorithm VF tests using the central 30-2 Humphrey field analyzer (HFA model 640 or model 740; Humphrey Instruments Inc., San Leandro, CA, USA); and spectral-domain OCT with Cirrus HD-OCT (Carl Zeiss Meditec, Inc., Dublin, CA, USA) were performed annually. At least one enhanced-depth imaging examination of ONH with the Spectralis OCT (Heidelberg Engineering GmbH, Dossenheim, Germany) was performed for all patients. Patients were routinely followed up with glaucoma examinations every six to 12 months, and additional visits and examinations with shorter intervals of three to six months were planned according to their condition, such as suspicious glaucoma progression, which requires additional tests for confirmation, recent rapid progression, or an increasing IOP trend.

Clinical Timeline: Schematic Plotting of PPRS Fluctuation and Temporal Correlation

We created clinical timelines of glaucoma progression events and PPRS changes. Using a timeline graph with time as the horizontal axis, the increase and decrease in the extent of PPRS were plotted schematically after classification as increasing, decreasing, or no change. Events of glaucoma progression were plotted on the same graph to identify the temporal correlation, which was defined as the occurrence of PPRS increase and glaucoma progression with an in-between interval of less than 1 year (Fig. 1A).

Increasing PPRS included both the de novo development of PPRS and an increase in PPRS extent presenting as expansion of the area of fluid-containing retinoschisis on OCT as compared to the previous OCT image. On the review of OCT images, the Cirrus HD-OCT-captured 6 × 6 mm Optic Disc

Cube scans, including the RNFL thickness map, circular and radial scans, and macular maps, were thoroughly used. Raw OCT images were directly reviewed instead of reviewing the conventional thickness report of automatic segmentation. We further confirmed the change by reviewing additional raw OCT raster volumes exported from the device (Fig. 1B). Two independent readers (EJL and HJK) masked to clinical information made all decisions, and a consensus was reached for disagreements through a discussion.

We investigated structural progression only. Isolated VF progression was not considered as glaucoma progression in this study because a transient worsening of VF sensitivity is reportedly associated with PPRS.⁴ Corresponding findings of neuroretinal rim thinning or vascular configuration change on color photographs, widening or deepening of RNFL defects on a red-free photograph or OCT scan, progressive thinning of the ganglion cell complex (GCC) on an OCT scan, or development of new RNFL defects were considered to be structural progression. In particular, consistent structural progression on subsequent photographs was required to exclude the effect of resolving/developing PPRS itself on the RNFL and optic disc.^{2,7,8} In limited circumstances where progression occurred on the most recent visit that could not be further followed, we instead confirmed at least one supportive finding, such as a corresponding neuroretinal rim (NRR) or GCC change.

Additional OCT Parameters

We also identified lamina cribrosa (LC) defects,⁹ optic pits,¹⁰ vitreous traction,⁵ and signs of the intra-disc prelaminar splitting in PPRS^{4,7,9} based on the reported association with PPRS. We used 24 radial-line B-scans of enhanced-depth

TABLE 1. Basic Characteristics of All Eyes With PPRS

| Parameter | Value |
|--|---|
| Number of eyes (number of patients) | 33 (30) |
| Sex | |
| Female | 12 |
| Male | 18 |
| Refraction, D | -2.07 ± 2.97 (-7.88 – $+3.38$) |
| Central corneal thickness, μm | 538.5 ± 31.9 (440–596) |
| Mean intraocular pressure, mm Hg | 15.7 ± 2.1 (12.0–21.7) |
| Age at the first PPRS documentation, years | 56.7 ± 15.9 (24.4–79.2) |
| Follow-up period, years | 7.5 ± 3.0 (3.4–12.4) |
| Total duration of PPRS observation, years | 4.4 ± 3.0 (0.49–11.7) |
| Number of examined visits | 7.7 ± 2.6 (4–13) |
| Location of PPRS, n (%) | |
| Superior | 14 (42.4) |
| Inferior | 14 (42.4) |
| Superior and inferior | 5 (15.2) |
| Location of RNFL defects, n (%) | |
| Inferior | 20 (60.6) |
| Superior and inferior | 12 (36.4) |
| No defect | 1 (3.0) |
| MD at the first PPRS documentation, dB | -5.11 ± 5.31 (-22.84 – $+1.56$) |
| MD at the last visit, dB | -6.56 ± 5.56 (-16.95 – -0.11) |

D, diopter; MD, mean deviation.

imaging OCT, each obtained at an angle of 7.5° and centered on the optic disc, following previously described methods.¹¹

Statistical Analysis

Among eyes with glaucoma progression, we investigated the distribution of the interval between the nearest glaucoma progression and PPRS increase and calculated the percentage of both episodes and eyes with temporal correlation. We then classified the eyes into groups with and without glaucoma progression to compare the clinical characteristics between the two groups. We used Pearson's χ^2 test for categorical variables of the sex, disease diagnosis, and locations and a generalized estimation equation model for all others to consider the effects in both eyes of each patient.

All statistical analyses were performed with SPSS software version 22.0 (SPSS, Inc., Chicago, IL, USA). *P* value < 0.05 was considered statistically significant.

RESULTS

A total of 33 eyes of 30 patients were included. From the initial 41 eyes of 37 patients, we excluded one eye with optic disc coloboma, one eye with optic pit maculopathy, one eye with myopic tractional maculopathy with severe epiretinal membrane formation, two eyes because of poor-quality OCT images, and three eyes because of fewer than three visits of the patients.

The enrolled eyes had an average follow-up period of 7.5 ± 3.0 years, with a total of 253 glaucoma examinations (mean, 7.7 ± 2.6 per eye). Table 1 shows the basic characteristics of the whole study group.

Glaucoma Progression

Of the 33 eyes, 21 showed glaucoma progression during the follow-up period, whereas 12 did not. We had 44 glaucoma progression events involving 45 RNFLDs, including one

event with two RNFLD progressions simultaneously in both hemispheres. The criteria for progression was as follows: RNFLD widening on the red-free photograph and OCT (8 [17.8%]), RNFLD and NRR change (21 [46.7%]), RNFLD widening and GCC change (5 [11.1%]), NRR change (2 [4.4%]), GCC change (2 [4.4%]), and new RNFLD (7 [15.6%]). The two simultaneous RNFLD progressions were determined by the GCC change and new RNFLD, respectively. Focusing on the presence of NRR change, progressions were supported with both RNFLD and NRR changes (27 [60.0%]), RNFLD-widening alone (14 [31.1%]), NRR changes alone (2 [4.4%]), and GCC changes (2 [4.4%]).

In our study, 16 of 44 (36.4%) structural glaucoma progression events were without distinct NRR thinning; however, indirect evidence of glaucomatous deterioration could be found. Six events were associated with a DH history at the exact corresponding location; seven events were associated with corresponding NRR changes in the follow-up period of the given eye; and three events were associated with retinoschisis involving the NRR, which could have masked NRR thinning.

For the hemispheric location of RNFL progression and location of PPRS, no particular topographic association was observed. Of a total of 44 glaucoma progression events, 15 (34.1%) occurred in different hemispheres whereas 29 (65.9%) occurred in the same hemisphere. When RNFL progressed without simultaneous PPRS, the location of the last or next PPRS was used for the analysis.

Distribution of the Interval and Temporal Correlation

Of the 21 eyes with glaucoma progression during the follow-up, the pattern of temporal correlation varied among eyes, although the coincidence was easily recognizable on the timeline, as shown with representative examples (Fig. 2A). The interval was distributed exclusively close to zero; 20 of 39 episodes had simultaneous positive conversion of

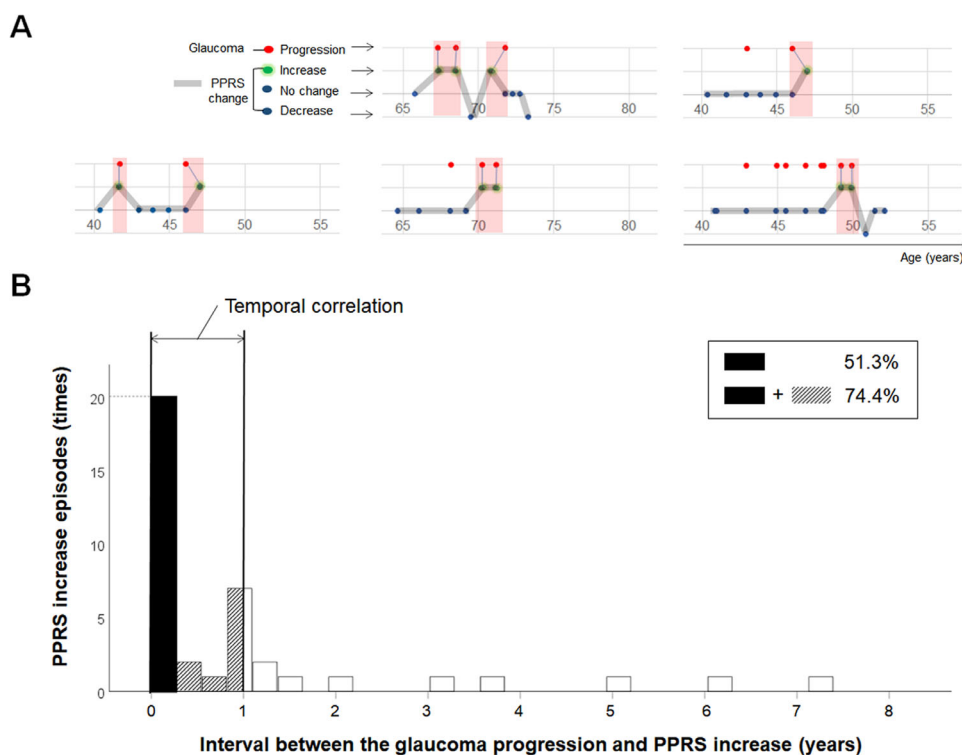


FIGURE 2. The pattern and intervals of temporal correlation between the glaucoma progression and PPRS increase. (A) Timeline analysis provides an easy recognition of temporal correlation by visual presentation. Care should be taken not to misunderstand the consecutive PPRS increase as no change. (B) The intervals are distributed exclusively around zero; one half (20 of 39 [51.3%]) of the episodes had simultaneous PPRS increase and glaucoma progression (*solid black*) and 29 episodes (29 of 39 [74.4%]) had interval less than one year (*solid black and stripes*).

PPRS and glaucoma progression (Fig. 2B). For the temporal correlation, there were 39 episodes of PPRS increase, regardless of whether they showed temporal correlation to glaucoma progression, and 29 showed temporal correlation. The results indicated that 74.4% (29 of 39) of the PPRS increase episodes were accompanied by glaucoma progression within one year. In addition, 19 out of 21 eyes with glaucoma progression (90.5%) had at least one occurrence where PPRS increase and glaucoma progression coincided within one year. There were no eyes without an increase in PPRS in the glaucoma progression group.

Eight eyes had preceding glaucoma progression before the first PPRS increase in the studied period. Excluding the ones within a one-year interval (two eyes), precedent intervals were three years (one eye), two years six months (one eye), two years one month (one eye), two years (two eyes), one year seven months (one eye), and one year two months (one eye).

Eyes Without Glaucoma Progression

PPRS increase in the group without glaucoma progression included a total of 13 times for nine eyes (thrice for one eye, twice for two eyes, and once for six eyes). A short period of PPRS detection was noted in the eyes; five eyes had been followed-up for less than four years; seven eyes had PPRS persistence for less than four years; and two eyes had developed recent PPRS, within one year. The remaining three eyes showed neither glaucoma progression nor increase in PPRS.

Comparison Between Eyes With and Without Glaucoma Progression

Between the eyes with glaucoma progression (21 eyes) and those without glaucoma progression (12 eyes), the clinical parameters did not differ significantly, except for the presence of PPRS at baseline. IOP in the follow-up period and until the last glaucoma progression event and the number of IOP-lowering medications at baseline and the last follow-up were all comparable. In the group without glaucoma progression, IOP-lowering medications were added because of elevated IOP in two eyes and VF progression in two eyes. Episodes of disc hemorrhage were more frequent in the glaucoma progression group ($P = 0.008$). The de novo development of PPRS during the follow-up period over baseline PPRS was more frequent in the glaucoma progression group than in the no progression group ($P = 0.006$; Table 2). Supplementary table shows the results of multiple regression analysis. The ONH OCT findings were not significantly different between the two groups (Table 2).

Last, Figure 3 shows the representative cases.

DISCUSSION

PPRS is associated with glaucoma progression⁷; however, its fluctuating course has not been fully analyzed in relation to glaucoma progression.^{3,4,7,8} We attempted a longitudinal approach focusing on the timing of increase in PPRS in the course of glaucoma progression. This new approach revealed nearly coincident glaucoma progression with the time of PPRS increase in up to 70% of cases.

TABLE 2. Characteristics of PPRS in Eyes With and Without Glaucoma Progression

| | With Glaucoma Progression | Without Glaucoma Progression | P Value* |
|---|---------------------------|------------------------------|----------|
| n | 21 | 12 | |
| Demographics | | | |
| Sex | | | 0.465 |
| Female | 9 | 4 | |
| Male | 10 | 8 | |
| Diagnosis, NTG/POAG/GS | 15/6/0 | 7/4/1 | 0.367 |
| Refraction, D | -1.66 ± 3.02 | -2.78 ± 2.86 | 0.322 |
| Follow-up period, years | 8.0 ± 2.4(3.8–12.3) | 6.6 ± 3.7(3.4–12.4) | 0.237 |
| Age at the first PPRS documentation, years | 60.2 ± 15.2 | 50.1 ± 15.9 | 0.056 |
| Total duration of PPRS, years | 4.1 ± 2.7 | 5.4 ± 4.0 | 0.466 |
| Clinical factors | | | |
| Central corneal thickness, μm | 533.2 ± 35.9 | 547.6 ± 21.6 | 0.161 |
| Average IOP, mm Hg | 15.4 ± 2.3 | 16.0 ± 1.7 | 0.427 |
| Average IOP until the last structural glaucoma progression, mm Hg | 15.7 ± 2.4 | 16.0 ± 1.7 | 0.665 |
| Baseline number of IOP-lowering medications | 1.1 ± 1.1 (0–4) | 1.3 ± 1.1 (0–3) | 0.781 |
| Final number of IOP-lowering medications | 1.7 ± 1.1 (1–4) | 1.6 ± 1.1 (0–3) | 0.819 |
| Episode of disc hemorrhage | 9/21 | 0/12 | 0.008 |
| Location | | | |
| RNFL defects, inferior/superior and inferior/none | 13/8/0 | 7/4/1 | 0.404 |
| PPRS, superior/inferior/superior and inferior | 8/9/4 | 6/5/1 | 0.642 |
| Glaucoma severity | | | |
| MD at the first PPRS documentation, dB | -3.91 ± 3.55 | -7.21 ± 7.19 | 0.090 |
| MD at last visit, dB | -5.44 ± 5.05 | -8.53 ± 6.06 | 0.156 |
| PPRS baseline status (present/de novo) | 6/15 | 9/3 | 0.006 |
| ONH OCT abnormalities | | | |
| Peripheral LC defects | 10/21 | 4/12 | 0.425 |
| Optic pits | 0/21 | 0/12 | NA |
| Vitreous traction | 16/21 | 10/12 | 0.626 |
| Prelaminar splitting signs | 15/21 | 9/12 | 0.826 |

NTG, normal tension glaucoma; POAG, primary open-angle glaucoma; GS, glaucoma suspect; D, diopters; MD, mean deviation; NA, not applicable.

*The χ^2 test was performed for the categories of the sex, glaucoma diagnosis, and locations of RNFL defect and PPRS. Fisher's exact test was performed for the episode of disc hemorrhage. Generalized estimation equation model was used for other variables.

The episodic occurrence of PPRS has been clearly recognized.^{6,7} In a study by Fortune et al.,⁷ 12 glaucomatous eyes with PPRS had a greater rate of mean deviation change (-0.49 vs. -0.06 dB/year) and RNFL thinning (-2.8%/year vs. -1.3%/year) than the eyes without PPRS; in particular, progressive RNFL thinning was apparent during the time span over which PPRS occurrence-relapsing events transpired. In addition, the VF worsened within 11 months of the PPRS detection in another study.⁶ These results corroborated ours in that the evolving PPRS coincided with the period of glaucoma progression, which was the primary finding of this study.

Furthermore, this study also helps explain the negative results based on the periods that excluded the initial increment phase of PPRS. With such sampling, glaucoma progression may not appear in the studied period, leading to a false-negative result. Accordingly, the PPRS eyes without glaucoma progression have been reported.^{4,8} Van der Schoot et al. investigated seven eyes in a 4-year prospective study and found no signs of glaucomatous progression related to retinoschisis.⁴ The study included at least four OCT scans in the eyes with PPRS, but in only two cases, schisis occurred within the time frame of these measurements. Thus since the sampling had not been targeted in the initial phase of PPRS evolution, the glaucoma progression could have also been excluded. Capturing the early phase of PPRS evolve-

ment may result in a higher chance of detecting glaucoma progression than capturing the phase without it.

Nevertheless, the reasons for the interval between PPRS and glaucoma progression and cause-and-effect relationship between them remain to be explained. Although the two events are not completely coincident, almost half of them showed simultaneous occurrence, mostly within 1 year (Fig. 2B). The reason for the discordance is unclear but it may be due to the absence of a relationship in the minority of cases or possibly delayed progression following a PPRS increase. A previous study reported no glaucoma progression before or after PPRS formation in 19 eyes within a 10.5-month interval⁸; this may be partly associated with the potential delay. Conversely, a long-term influence of precedent glaucoma progression on the subsequent progression of both glaucoma and PPRS is also possible, even over years. Larger long-term longitudinal studies are warranted on these issues.

In our study, we had 10 glaucoma progression events with RNFLD widening where "coincident" PPRS overlapped the location of RNFLD. Pseudo-widening of RNFLD is possible from PPRS-related hyporeflexive changes in the photograph. However, we confirmed consistent RNFLD widening in subsequent tests in eight of 10 events (80.0%). The remaining two events could not be tested for subsequent changes because they were the most recent visits; nevertheless, one had corresponding NRR loss and another had corresponding

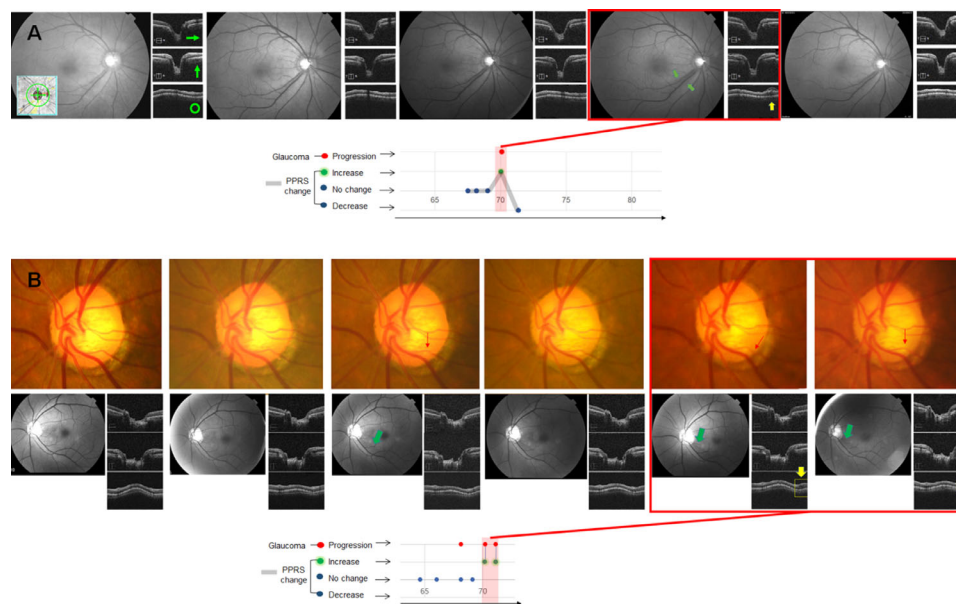


FIGURE 3. Representative cases of PPRS with glaucoma progression. **(A)** During the follow-up, new development of PPRS was detected simultaneously with the widening of an RNFL defect (*red box*). **(B)** In the two and three years after the development of RNFL defects, further widening of RNFL defect followed with the development and increase of PPRS, respectively (*red boxes*). Note the corresponding changes of vascular configuration (*red arrows*) in the NRR. *Yellow arrows and boxes* indicate PPRS increase, and *dark green arrows* indicate glaucoma progression. Horizontal, vertical, and circular OCT images are presented in the column next to the photographs (*bright green arrows* mark the scan directions).

GCC loss, which would be less affected by PPRS compared to peripapillary RNFL because retinoschisis commonly spares the macula.

In addition, our results may support the possible role of glial cells in the pathogenesis of PPRS. Previous studies on the pathogenic factors of PPRS have suggested that defects in the internal limiting membrane/RNFL defects, optic pits, and LC defects^{1,3,4,6,9,10,12} may be possible causes. Recently, a biomechanical perspective posed lateral mechanical forces on ONH as a likely contributor to the development of PPRS in glaucoma through activation of the mechanosensitive glia.^{7,13–16} The activated glial cells play an important role in progressive neurodegenerative processes in glaucoma.^{14,17} Furthermore, the glia regulates the extracellular fluid.¹ Therefore the biological background allows the possibility of the ongoing glaucomatous damages accompanying such glial dysfunction, leading to fluid collection in the peripapillary retina as an epiphenomenon of glaucoma aggravation. Moreover, the anatomic distribution of the astrocytes exactly matches that of PPRS, reinforcing the speculation. The astrocyte density is the highest around the peripapillary area in proportion to the RNFL thickness,¹⁸ and the extent of glaucomatous activation of astrocytes covers the ONH and peripapillary retina.¹⁹

In other words, in the glial perspective, we may suspect that the ongoing processes of glaucoma progression may underlie the process of PPRS formation. This viewpoint is similar with the role of disc hemorrhage in glaucoma.²⁰ The disc hemorrhage and PPRS are both transient, episodic, recurrent, and associated with glaucoma progression in a temporal manner.

At the same time, our findings are additive to and not against the factors that had been previously related to PPRS development. As we did not comprehensively investigate the factors in this study, the synergistic roles of LC defects, lack

of blood–brain barrier properties,²¹ and microhole development in the thinned area of the ONH/RNFL may exist in the mechanism of PPRS development.^{22–24}

With regard to the PPRS increases without temporally correlated glaucoma progression, our primary consideration was that the time span of association may be longer in some eyes, thereby demonstrating temporally distant episodes (over a one-year interval from the timing of nearby glaucoma progression). Another possibility is that a swollen RNFL may mask a subtle additional axonal damage because of false RNFL thickening, accentuate the RNFL striations, and blur the neuroretinal rim contour, all potentially leading to delayed glaucoma progression. In this study, we observed two cases of ganglion cell complex thinning after complete resolution of PPRS in 6 and 1.5 years, respectively. Otherwise, the glaucoma progression may be too subtle to be detected, may have occurred shortly before the initial examination (thus missed throughout the study period), or may be undetected because of a short follow-up. Further studies with an extended follow-up may confirm the significant relationship.

The current findings do not indicate that PPRS might serve as a cause of further glaucomatous damage, as the results do not show any cause-and-effect relationship. What is also unknown about the findings of this study is that gradual axonal loss and retinoschisis may involve non-glaucoma mechanisms such as ischemia. The following findings support relevance to a glaucomatous origin: (1) consistent RNFLD, optic disc, and VF findings consistent with glaucoma or glaucomatous progression; (2) close locational proximity of PPRS to the optic disc; (3) frequent intra-disc extension of PPRS; and (4) no signs of ischemic retinopathy, including venous obstruction or diabetic retinopathy, such as cotton-wool spots, retinal hemorrhage, or ghost vessels. Progressive axonal loss also accompanied coincident NRR

changes or DH at the corresponding location. Nevertheless, a direct link between the primary glaucomatous pathology in the lamina cribrosa and the study findings could not be established, and further investigations should cover the possibility of such nonglaucomatous mechanisms.

We would like to briefly address the strengths of our study design. First, the timeline assay was performed for a relatively large number of patients over a long time period. Second, reviewing the raw OCT images was free of segmentation errors due to PPRS. Furthermore, consecutive sets of examinations ensured structural progression distinct from false changes in RNFL and optic disc changes related to PPRS itself. Third, exclusion of isolated VF progression may also increase the objectivity of the results, because VF transiently may worsen during the active phase of PPRS.⁴

The limitations of this study are as follows. First, the number of included patients was small. Second, the evaluation was qualitative but not quantitative. Higher-resolution OCT scans may provide more accurate temporal profiles. Nevertheless, we reviewed all available OCT volumes, and the image resolution was considered to be sufficiently high to follow the course of PPRS, as indicated in the representative figures. For glaucoma progression, particularly those without distinct NRR changes, non-glaucomatous deterioration of axonal loss remains to be tested. Our study group showed indirect evidence of a glaucomatous origin in most cases, however, further investigations on PPRS should consider non-glaucomatous mechanisms as well. Finally, we did not investigate the interaction with other factors, such as altering levels of IOP.^{3,8,12} The dynamic interaction of all contributing factors, including IOP, LC defects/pits, or vitreous traction, may be investigated cautiously in the longitudinal relationship.

In conclusion, the increase in PPRS or de novo development of PPRS temporally correlated to glaucoma progression. Clinicians may consider the possibility of glaucoma progression around the time of increased PPRS. Future studies are warranted to determine the full mechanism.

Acknowledgments

Disclosure: **E.J. Lee**, None; **H.J. Kee**, None; **J.C. Han**, None; **C. Kee**, None

References

- Fortune B, Ma KN, Gardiner SK, Demirel S, Mansberger SL. Peripapillary retinoschisis in glaucoma: association with progression and OCT signs of Muller cell involvement. *Invest Ophthalmol Vis Sci*. 2018;59:2818–2827.
- Bayraktar S, Cebeci Z, Kabaalioglu M, Ciloglu S, Kir N, Izgi B. Peripapillary Retinoschisis in Glaucoma Patients. *J Ophthalmol*. 2016;2016:1612720.
- Lee EJ, Kim TW, Kim M, Choi YJ. Peripapillary retinoschisis in glaucomatous eyes. *PLoS One*. 2014;9:e90129.
- van der Schoot J, Vermeer KA, Lemij HG. Transient peripapillary retinoschisis in glaucomatous eyes. *J Ophthalmol*. 2017;2017:1536030.
- Grewal DS, Merlau DJ, Giri P, et al. Peripapillary retinal splitting visualized on OCT in glaucoma and glaucoma suspect patients. *PLoS One*. 2017;12:e0182816.
- Dhingra N, Manoharan R, Gill S, Nagar M. Peripapillary schisis in open-angle glaucoma. *Eye (Lond)*. 2017;31:499–502.
- Fortune B. Pulling and tugging on the retina: mechanical impact of glaucoma beyond the optic nerve head. *Invest Ophthalmol Vis Sci*. 2019;60:26–35.
- Hwang YH, Kim YY, Kim HK, Sohn YH. Effect of peripapillary retinoschisis on retinal nerve fibre layer thickness measurement in glaucomatous eyes. *Br J Ophthalmol*. 2014;98:669–674.
- Lee JH, Park HY, Baek J, Lee WK. Alterations of the lamina cribrosa are associated with peripapillary retinoschisis in glaucoma and pachychoroid spectrum disease. *Ophthalmology*. 2016;123:2066–2076.
- Song IS, Shin JW, Shin YW, Uhm KB. Optic disc pit with peripapillary retinoschisis presenting as a localized retinal nerve fiber layer defect. *Korean J Ophthalmol*. 2011;25:455–458.
- Han JC, Lee EJ, Kim SB, Kee C. The characteristics of deep optic nerve head morphology in myopic normal tension glaucoma. *Invest Ophthalmol Vis Sci*. 2017;58:2695–2704.
- Kahook MY, Noecker RJ, Ishikawa H, et al. Peripapillary schisis in glaucoma patients with narrow angles and increased intraocular pressure. *Am J Ophthalmol*. 2007;143:697–699.
- Inman DM, Horner PJ. Reactive nonproliferative gliosis predominates in a chronic mouse model of glaucoma. *Glia*. 2007;55:942–953.
- Hernandez MR. The optic nerve head in glaucoma: role of astrocytes in tissue remodeling. *Prog Retin Eye Res*. 2000;19:297–321.
- Lindqvist N, Liu Q, Zajadacz J, Franze K, Reichenbach A. Retinal glial (Muller) cells: sensing and responding to tissue stretch. *Invest Ophthalmol Vis Sci*. 2010;51:1683–1690.
- Choi HJ, Sun D, Jakobs TC. Astrocytes in the optic nerve head express putative mechanosensitive channels. *Mol Vis*. 2015;21:749–766.
- Tamm ER, Ethier CR, Lasker IIOA, Glaucomatous Neurodegeneration P. Biological aspects of axonal damage in glaucoma: a brief review. *Exp Eye Res*. 2017;157:5–12.
- Ogden TE. Nerve fiber layer astrocytes of the primate retina: morphology, distribution, and density. *Invest Ophthalmol Vis Sci*. 1978;17:499–510.
- Wang L, Cioffi GA, Cull G, Dong J, Fortune B. Immunohistochemical evidence for retinal glial cell changes in human glaucoma. *Invest Ophthalmol Vis Sci*. 2002;43:1088–1094.
- Nitta K, Sugiyama K, Higashide T, Ohkubo S, Tanahashi T, Kitazawa Y. Does the enlargement of retinal nerve fiber layer defects relate to disc hemorrhage or progressive visual field loss in normal-tension glaucoma? *J Glaucoma*. 2011;20:189–195.
- Hofman P, Hoyng P, vanderWerf F, Vrensen GF, Schlingemann RO. Lack of blood-brain barrier properties in microvessels of the prelaminar optic nerve head. *Invest Ophthalmol Vis Sci*. 2001;42:895–901.
- Zhao M, Li X. Macular retinoschisis associated with normal tension glaucoma. *Graefes Arch Clin Exp Ophthalmol*. 2011;249:1255–1258.
- Zumbro DS, Jampol LM, Folk JC, Olivier MM, Anderson-Nelson S. Macular schisis and detachment associated with presumed acquired enlarged optic nerve head cups. *Am J Ophthalmol*. 2007;144:70–74.
- Hollander DA, Barricks ME, Duncan JL, Irvine AR. Macular schisis detachment associated with angle-closure glaucoma. *Arch Ophthalmol*. 2005;123:270–272.