

# Clinical aspects of virus/immune myocarditis\*

John B. O'Connell, John A. Robinson, Rolf M. Gunnar, and Patrick J. Scanlon

Department of Medicine, Sections of Cardiology and Immunology, Loyola University Medical Center, 2160 South First Avenue, Maywood, Illinois 60153, USA

**Summary.** Although a cause-and-effect relationship between viral infection and myocarditis remains inferential, two distinct clinical syndromes can be identified. During the early viral phase, the cardiac manifestations emerge while the symptoms of active viral infection are also present. During the chronic phase, symptoms of the viral infection may be remote or nonexistent, and identification of active myocarditis is contingent upon an aggressive diagnostic approach with endomyocardial biopsy and gallium 67 imaging. The exact incidence of myocarditis in patients with heart failure of unknown cause is unclear due to lack of standardization of histologic parameters. There are no other clinical clues to the presence of myocarditis in those patients presenting with cardiomyopathy or ventricular arrhythmia. For further clarification of the incidence and various presentations of myocarditis a large multi-center trial is necessary.

Although several viruses have been implicated as the cause of myocarditis in man, some of Koch's postulates have yet to be fulfilled because isolation of a virus from the human myocardium has been demonstrated only in rare instances [1-3]. Studies of the clinical presentation of myocarditis are therefore based only on indirect evidence of viral causation. Insights into the pathogenesis of human disease may be obtained, however, by observations in animal models of myocarditis [4]. When Coxsackie virus B3 (CVB3) is inoculated into mice a biphasic disease results [5]. During the acute (virus-mediated) phase, self-limited myocardial viral replication occurs. The virus is cleared by interferon, monocytes, and humoral immune responses within 10 days of the initial infection. Histologically, foci of myocardial necrosis and a sparse inflammatory infiltrate are present. In spite of viral clearance from the myocardium, a lymphocytic inflammatory infiltration develops, marking the beginning of the chronic (immune-mediated) phase. This phase develops as a result of cell-mediated immune responses to a neoantigen that develops during the acute phase [6]. Six months following infection, the animals remain clinically normal but his-

tologically show evidence of fibrosis and myocyte hypertrophy with persistent inflammatory infiltration [7]. By 12-15 months following infection, the inflammatory infiltration subsides; however, there is chamber dilatation with mural thrombus formation and histologic evidence of myocyte hypertrophy and fibrosis similar to that seen in dilated cardiomyopathy [8]. It is at this phase that the animal first develops signs of congestive heart failure. In this model, therefore, the clinical signs of myocarditis manifested as congestive heart failure develop long after the initial viral infection. If this model reflects a similar pathophysiology occurring in man, it is easy to understand the difficulty in demonstrating a direct link between a viral infection and signs of myocarditis, since it is likely that the cardiac manifestations develop long after the initial viral infection which initiated the complex immune responses, culminating in the development of chronic cardiac failure.

## Acute viral myocarditis

Numerous viruses and prokaryotes have been postulated as causing myocarditis in man. Several of the more prominent of these are listed in Table 1 [9-32]. Absolute proof of the

**Table 1.** Causative agents in myocarditis

Viruses	Prokaryotes
Arbovirus	Chlamydia
Arenavirus	Mycoplasma
Junin virus	Rickettsia
Coronavirus	
Enterovirus	
Coxsackie a and b	
Echo	
Polio	
Herpes virus	
Cytomegalovirus	
Ebstein-Barr virus	
Herpes simplex	
Varicella/Zoster	
Influenza	
Mumps	
Rubella	
Rubeola	

\* Supported in part by the Earl M. Bane Charitable Trust

diagnosis of viral myocarditis is contingent upon the identification of replicating virus in the myocardium. This has only been possible in isolated patients with overwhelming viral infection of the myocardium [1–3]. Moderate associations of viral infection with myocarditis may be documented by rising viral antibody titers at the time of clinical presentation of an acute cardiac syndrome [33]. Using this criterion, errors can be made when a patient with latent nonviral heart disease develops clinical manifestations only during the increased metabolic demands associated with an acute febrile syndrome of any cause.

Several reports have documented electrocardiographic ST segment, T wave, and QT interval changes following screening of large populations during viral epidemics [34–37]. This implies that acute viral myocarditis is a very common disease and the vast majority of patients remain totally asymptomatic. Initial clinical clues, therefore, to the presence of acute viral myocarditis relate to the identification of the noncardiac manifestations common to the viral syndromes: fever, myalgias, pharyngitis, lymphadenopathy, diarrhea, hepatitis, nephritis, orchitis, and encephalitis. Since enteroviral and *Mycoplasma pneumoniae* infections may result in myocarditis, a febrile syndrome with associated myalgias should alert the clinician to possible myocardial involvement [30]. Other nonspecific manifestations of the viral infections include gastrointestinal complaints, hepatitis, lymphadenopathy, orchitis, nephritis, and encephalitis [12, 19, 38–40]. Nonspecific laboratory abnormalities include elevation of the erythrocyte sedimentation rate, transaminases, and creatinine phosphokinase, and atypical lymphocytes in the peripheral blood [12].

The most common cardiac presentation during the acute phase of viral myocarditis, summarized in Table 2, is pericardial pain [41, 42]. All enteroviruses causing myocarditis result in myopericarditis, and suspicion of myocardial involvement only develops when chest pain leads to noninvasive cardiac studies, such as echocardiography or radio-nuclide ventriculography, which identify myocardial dysfunction. When careful echocardiographic studies are performed in patients with suspected viral myocarditis, findings compatible with concentric left ventricular hypertrophy, but thought to be secondary to myocardial edema, are identified [43, 44]. Furthermore, segmental wall motion abnormalities or decreased ejection fraction on radionuclide ventriculography may also be seen [45]. When the evaluation includes invasive cardiac studies, a restrictive hemodynamic pattern is identified [46]. If the patient has cardiac symptoms shortly after the onset of the viral syndrome, congestive heart failure, ischemic cardiac pain, and syncope are reported [42, 47]. Although the incidence is quite low, evidence of left ventricular dysfunction, ranging from mild abnormalities to cardiogenic shock, may be present at the time of presentation. Recently, several investigators have reported ischemic cardiac pain and apparent myocardial infarction as a manifestation of acute viral myocarditis [48–53]. Akinetic segments have been identified on echocardiography [53]. Although coronary arteritis has been postulated as an etiology of this ischemic syndrome [54], transmural myocardial necrosis with resultant aneurysm formation has been shown in the murine Coxsackie virus B4 model, suggesting that a vasculopathy need not be present [55]. We have identified myocarditis by biopsy obtained from segments remote from the myocardial infarction [56].

**Table 2.** Cardiac manifestations of acute viral myocarditis

Electrocardiographic ST-T changes or prolonged QT interval
Pericardial pain/effusion
Congestive heart failure
Syncope/sudden death due to:
Ventricular arrhythmia
Complete heart block
Left ventricular hypertrophy
Restriction
Myocardial infarction

**Table 3.** Biopsy incidence of myocarditis in cardiomyopathy

Author	Location, year	Incidence [%]	n
Kunkel et al.	Frankfurt, 1978	6	66
Mason et al.	Stanford, 1980	2	400
Noda	Osaka, 1980	1	52
Baandrup and Olsen	London, 1981	25	135
Edwards et al.	Mayo Clinic, 1982	5	170
Fenoglio et al.	Columbia, 1983	25	135
Hess et al.	Virginia, 1983	26	23
Strain et al.	Montefiore, 1983	26	64
Unverferth et al.	Ohio State, 1983	6	59
Parillo et al.	Boston, 1984	25	74
Zee-Cheng et al.	St. Louis U, 1984	63	35
O'Connell et al.	Loyola, 1984	7	68
Daly et al.	King's College, 1984	17	69
Bolte and Ludwig	Munich, 1984	20	91

Syncope and complete AV block have been reported in one-third of patients presenting with acute viral myocarditis [47]. Electrocardiography has also documented ventricular arrhythmia as the etiology of the syncopal attack and may explain the 17% incidence of myocarditis seen at autopsy in children who die suddenly [57]. Although the cardiac symptoms that develop during acute myocarditis may be severe, the vast majority of patients spontaneously recover or only present to the physician during the chronic phase of the illness.

### Chronic myocarditis

Before the development of safe techniques of endomyocardial biopsy, the identification of myocarditis during the chronic phase was not possible unless a clear-cut progression from an acute viral myocarditis to a chronic dilated cardiomyopathy could be established. In patients presenting with ventricular arrhythmia or left ventricular dysfunction of recent onset, no clinical clues can aid in the diagnosis of myocarditis. Since the introduction of routine use of endomyocardial biopsy, an accurate diagnosis of chronic myocarditis has been possible histologically [58]. Following the report of Mason and others at Stanford, several centers have reported their incidence of biopsy-proven myocarditis [59]. The incidence of biopsy-proven myocarditis shown in Table 3 varies from 1% to 63% [60–72]. In updating our series of patients referred to our center with congestive heart failure of unknown cause, we verified a diagnosis of myocarditis in

**Table 4.** Clinical and hemodynamic comparison of patients with and without biopsy-proven myocarditis

	Bx +	Bx -
<i>n</i>	14	109
Age [years]	38.9 ± 16.8 <sup>a</sup>	46.4 ± 14.5
Sex (M/F)	11/3	74/35
CI III-IV CHF	11 (78%)	81 (74%)
CI [l/min/m <sup>2</sup> ]	2.3 ± 0.7	2.6 ± 0.7
PAW [mmHg]	17.4 ± 8.8	19.1 ± 10.0
PA <sub>sys</sub> [mmHg]	37.1 ± 15.8	42.4 ± 15.4
LVEDD [cm]	6.2 ± 0.8*	6.9 ± 1.0
EF [%]	17.5 ± 8.0	17.8 ± 8.4

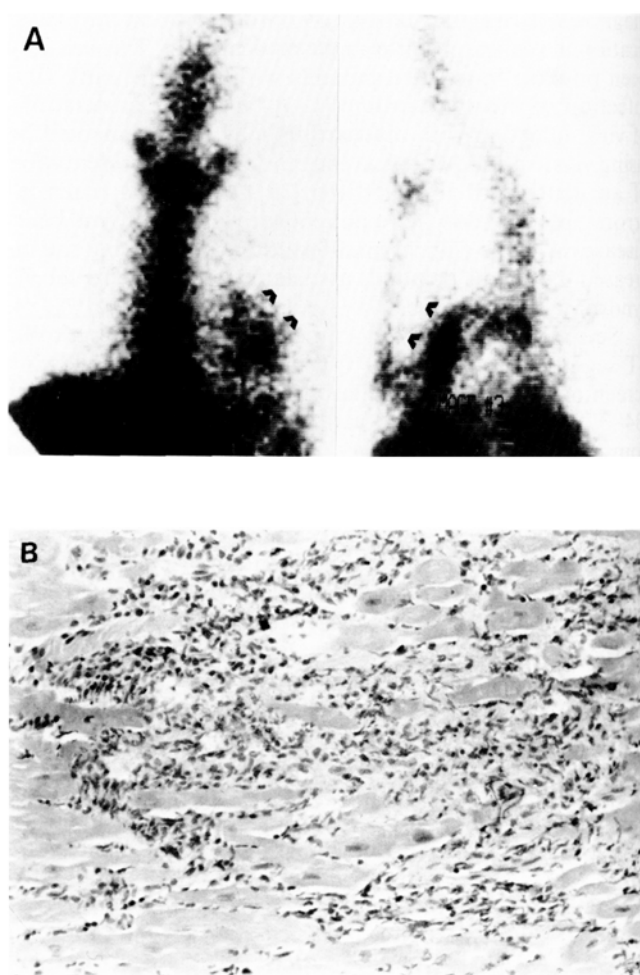
<sup>a</sup> mean ± SD\* *P* < 0.01

Bx<sup>+</sup> Biopsy-proven myocarditis, CI III-IV CHF symptomatic heart failure, NYHA class III or IV, CI cardiac index, PAW, mean pulmonary arterial wedge pressure, PA<sub>sys</sub> pulmonary arterial systolic pressure, LVEDD left ventricular end-diastolic dimension, EF ejection fraction

14 of 123 (11%). Clinical and hemodynamic parameters comparing patients with and without biopsy-proven myocarditis are presented in Table 4. The only finding of interest is that the left ventricular end-diastolic dimension on echocardiography was smaller in those patients with biopsy-proven myocarditis. Furthermore, all patients with biopsy-proven myocarditis presented to our center within 12 months of onset of symptoms, suggesting that the smaller end-diastolic diameter may be related to chronicity of disease.

Difficulty in ascertaining the true biopsy incidence of myocarditis from Table 3 is a result of the variability in histologic interpretation of the biopsies. It is likely that those centers with the highest incidence of myocarditis are most liberal in the histologic criteria for the condition. Once histologic criteria are standardized, the technique of endomyocardial biopsy, the standard against which all techniques for identification of active myocarditis are compared, will become highly specific; it may, however, still lack sensitivity due to sampling error, since myocarditis can be focal in distribution. In autopsy studies of patients dying of varicella pneumonia, myocarditis was thought to be uncommon when sought by routine sectioning; however, when careful sequential sectioning of the myocardium was done, the incidence of myocarditis rose strikingly [22]. In preliminary reports, the discrepancy between right and left ventricular histologic incidence of inflammatory infiltration was shown to be significant [73, 74].

The recent observation that gallium 67, an inflammation-avid radioisotope, can identify myocarditis may potentially obviate this underestimation of the incidence of myocarditis by endomyocardial biopsy. Following our initial description of three patients with gallium 67 myocardial uptake in patients with dilated cardiomyopathy of recent onset [75], we performed gallium 67 scans on a larger series of patients with dilated cardiomyopathy and demonstrated myocardial uptake in 19 [76]. When 15 of these patients were treated with immunosuppressive agents, six showed a dramatic clinical and hemodynamic response to therapy, suggesting that in these patients myocarditis was in fact the mechanism of gallium uptake. When parallel endomyocardial biopsies



**Fig. 1A,B.** Parallel gallium-67 scan in the anterior and 45° LAO projection **A** and endomyocardial biopsy photomicrograph **B** in the same patient, showing intense myocardial Ga-67 uptake and lymphomononuclear infiltration with myocyte necrosis compatible with myocarditis. Hematoxylin-eosin, original magnification × 20. (Heart Transplantation (1982) 2 : 13, reprinted with permission)

and gallium 67 scans were performed on a series of patients with dilated cardiomyopathy [70], gallium was avid for the myocardium in five of six patients with biopsy-proven myocarditis (Fig. 1). In the isolated patient in whom the gallium 67 scan was negative, dense uptake of the isotope was found in the posterior mediastinal lymph nodes, decreasing the possibility of visual identification of uptake over the myocardium. The overall incidence of myocarditis on biopsy in the latter series was 7%. If the gallium scan was positive, the incidence rose dramatically to 36%. When the gallium scan was negative, only 1 of 57 patients (2%) had myocarditis on biopsy.

We have also studied subgroups of patients with dilated cardiomyopathy and have reported the presence of a familial predisposition to myocarditis with documentation of biopsy-proven myocarditis in many members of two separate families [77]. Further supportive evidence was provided when a suppressor cell defect was identified in the proband of the first family. Another subset of patients with congestive heart failure of recent onset with a high incidence of histologic myocarditis is peripartur heart disease. Melvin

and co-workers first described myocarditis in three patients with peripartur heart disease and suggested immunosuppression would be a rational therapeutic modality [78]. In our series of 14 patients with peripartur heart disease, histologic myocarditis was identified in five (35%), which is a threefold higher incidence of myocarditis than in our general cardiomyopathic population [79]. In patients with life-threatening ventricular arrhythmias with otherwise normal myocardial function, the incidence of active myocarditis on biopsy has been reported as 50% [80]. Clinical, hemodynamic or electrophysiologic parameters could not differentiate those with active myocarditis from those with other myocardial histology.

## References

- Sutton GC, et al (1967) Coxsackie B<sub>4</sub> myocarditis in an adult: Successful isolation of virus from ventricular myocardium. *Aerosp Med* 38: 66-69
- Longson M, Cole FM, Davies D (1969) Isolation of a Coxsackie virus group B, type 5, from the heart of a fatal case of myocarditis in an adult. *J Clin Pathol* 22: 654-658
- Lowry PJ, Edwards CW, Nagle RE (1982) Herpes-like virus particles in myocardium of patient progressing to congestive cardiomyopathy. *Br Heart J* 48: 501-503
- Costanzo-Nordin MR, O'Connell JB (1983) Animal models of immune-mediated myocardial disease, in Robinson JA, O'Connell JB (eds): *Myocarditis: Precursor of Cardiomyopathy*. Heath, Lexington, pp 29-47
- Woodruff JF (1980) Viral myocarditis-A review. *Am J Pathol* 101: 427-479
- Paque RE, et al (1978) Assessment of cell-mediated hypersensitivity against Coxsackievirus B3 viral-induced myocarditis utilizing hypertonic salt extracts of cardiac tissue. *J Immunol* 120: 1672-1678
- Wilson FM, et al (1969) Residual pathologic changes following murine Coxsackie A and B myocarditis. *Am J Pathol* 55: 153-164
- Reyes MP, et al (1981) A mouse model of dilated type cardiomyopathy due to Coxsackie virus B<sub>3</sub>. *J Infect Dis* 144: 232-236
- Obeyesekere I, Hermon Y (1973) Arbovirus heart disease: Myocarditis and cardiomyopathy following dengue and chikungunya fever—A follow-up study. *Am Heart J* 85: 186-194
- Milei J, Bolomo NJ (1982) Myocardial damage in viral hemorrhagic fevers. *Am Heart J* 104: 1385-1391
- Datta D, Zaida A, Brendan-Devlin H (1980) Carditis associated with coronavirus infection. *Lancet* II: 100-101
- Toshima H, Ohkita Y, Shingu M (1979) Clinical features of acute Coxsackie B viral myocarditis. *Jpn Circ J* 43: 441-444
- Koontz CH, Ray CG (1971) The role of Coxsackie group B virus infections in sporadic myocarditis. *Am Heart J* 82: 750-758
- Smith WG (1970) Coxsackie B myopericarditis in adults. *Am Heart J* 80: 34-46
- Fukuhara T, et al (1983) Myopericarditis associated with ECHO type 3 infection. *Jpn Circ J* 47: 1274-1280
- Lansdown ABG (1978) Viral infections and diseases of the heart. *Prog Med Virol* 24: 70-113
- Wink K, Schmitz H (1980) Cytomegalovirus myocarditis. *Am Heart J* 100: 667-671
- Frishman W, et al (1977) Infectious mononucleosis and fatal myocarditis. *Chest* 72: 535-538
- Hudgins JM (1976) Infectious mononucleosis complicated by myocarditis and pericarditis. *JAMA* 235: 2626-2627
- Butler T, et al (1981) Infectious mononucleosis myocarditis. *J Infect* 3: 172-175
- Bell RW, Murphy WM (1967) Myocarditis in young military personnel. Herpes simplex, trichinosis, meningococemia, carbon tetrachloride, and idiopathic fibrous and giant cell types. *Am Heart J* 74: 309-323
- Hackel DB (1953) Myocarditis in association with varicella. *Am J Pathol* 29: 369-373
- Karjalainen J, Nieminen MS, Heikkilä J (1980) Influenza A1 myocarditis in conscripts. *Acta Med Scand* 207: 27-30
- Walsh J, et al (1958) A study of the effects of type A (Asian strain) influenza on the cardiovascular system of man. *Ann Intern Med* 49: 402-528
- Roberts WC, Fox III SM (1965) Mumps of the heart. Clinical and pathologic features. *Circulation* 32: 342-345
- Ainger LE, Lawyer G, Fitch DW (1966) Neonatal rubella myocarditis. *Br Heart J* 28: 691-697
- Grayston JT, Mordhorst CH, Wang S-P (1981) Childhood myocarditis associated with chlamydia trachomatis infection. *JAMA* 246: 2823-2827
- Yamane Y, Kawai C (1978) A case of myocarditis caused by *Mycoplasma pneumoniae*. *Jpn Circ J* 42: 1279-1286
- Sands MJ, et al (1977) Pericarditis and perimyocarditis associated with active *Mycoplasma pneumoniae* infection. *Ann Intern Med* 86: 544-548
- Lewis D, Rainford DJ, Lane WF (1974) Symptomless myocarditis and myalgia in viral and *Mycoplasma pneumoniae* infections. *Br Heart J* 36: 924-932
- Bradford WD, Hackel DB (1978) Myocardial involvement in Rocky Mountain Spotted Fever. *Arch Pathol Lab Med* 102: 357-359
- Walker DH, Paletta CE, Cain BG (1980) Pathogenesis of myocarditis in Rocky Mountain Spotted Fever. *Arch Pathol Lab Med* 106: 171-174
- Lerner AM, Wilson FM, Reyes MP (1975) Enteroviruses and the heart (with special emphasis on the probable role of Coxsackieviruses group B, types 1-5). II. Observations in humans. *Mod Concepts Cardiovasc Dis* 44: 11-15
- Gittleman IW, Thorner MC, Griffith GC (1951) The Q-T interval of the electrocardiogram in acute myocarditis in adults, with autopsy correlation. *Am Heart J* 41: 78-90
- Gibson TC, et al (1959) Electrocardiographic studies in Asian influenza. *Am Heart J* 57: 661-668
- Helin M, Savola J, Lapinleimu K (1968) Cardiac manifestations during a Coxsackie B5 epidemic. *Br Med J* 3: 97-99
- Heikkilä J, Karjalainen J (1982) Evaluation of mild acute infectious myocarditis. *Br Heart J* 47: 381-391
- Sun NC, Smith VM (1966) Hepatitis associated with myocarditis. Unusual manifestation of infection with Coxsackie virus group B, type 3. *N Engl J Med* 274: 190-193
- Freiji L, Norrby R, Olsson B (1970) A small outbreak of Coxsackie B5 infection with two cases of cardiac involvement and orchitis followed by testicular atrophy. *Acta Med Scand* 187: 177-181
- Burch GE, Colcolough HL (1969) Progressive Coxsackie viral pancarditis and nephritis. *Ann Intern Med* 71: 963-970
- Abelmann WH (1966) Myocarditis. *N Engl J Med* 275: 832-834
- Gardiner AJS, Short D (1973) Four faces of acute myopericarditis. *Br Heart J* 35: 433-442
- Oda T, Hamamoto K, Morinaga H (1982) Left ventricular hypertrophy in non-rheumatic myocarditis in children. *Jpn Circ J* 46: 1235-1238
- Hauser AM, et al (1983) Severe transient left ventricular "hypertrophy" occurring during acute myocarditis. *Chest* 83: 275-277
- Miklozek CL, et al (1980) Unsuspected cardiac dysfunction in viral myopericarditis. *Clin Res* 28: 616 (Abstract)
- Case Records of the Massachusetts General Hospital (1982) Weekly clinicopathological exercises. Case 20-1982 (Abelmann WH discussant). *N Engl J Med* 306: 1215-1223
- Sekiguchi M, et al (1980) Clinical and histopathological profile of sarcoidosis of the heart and acute idiopathic myocarditis. Concepts through a study employing endomyocardial biopsy. II. Myocarditis. *Jpn Circ J* 44: 264-273

48. Bullon FS, et al (1980) Disappearing signs of acute myocardial infarction in a patient with viral myocarditis. *Cardiovasc Dis Bull Texas Heart Inst* 7: 66-73
49. Miklozek CL, Abelmann WH (1981) Viral myopericarditis presenting as acute myocardial infarction. *Circulation* 64: IV-25 (Abstract).
50. Nemickas R, et al (1978) Massive myocardial necrosis in a young woman. *Am Heart J* 95: 766-774
51. Kron J, et al (1983) Myocardial infarction following an acute viral illness. *Arch Intern Med* 143: 1466-1467
52. Saffitz JE, et al (1983) Coxsackie viral myocarditis causing transmural right and left ventricular infarction without coronary narrowing. *Am J Cardiol* 52: 644-647
53. Chandraratan PAN, et al (1983) Left ventricular asynergy in acute myocarditis. Simulation of acute myocardial infarction. *JAMA* 250: 1428-1430
54. Burch GE, Shewey LL (1976) Viral coronary arteritis and myocardial infarction. *Am Heart J* 92: 11-14
55. El-Khatib MR, Chason JL, Lerner AM (1979) Ventricular aneurysms complicating Coxsackievirus group B, types I and 4 murine myocarditis. *Circulation* 59: 412-416
56. Costanzo-Nordin MR, et al (in press) Biopsy-proven myocarditis presenting as acute myocardial infarction. *Br Heart J*
57. Noren GR, et al (1977) Occurrence of myocarditis in sudden death in children. *J Forensic Sci* 22: 188-196
58. O'Connell JB, et al (1984) Endomyocardial biopsy: Techniques and applications in heart disease of unknown cause. *Heart Transplant* 3: 132-144
59. Mason JW, Billingham ME, Ricci DR (1980) Treatment of acute inflammatory myocarditis assisted by endomyocardial biopsy. *Am J Cardiol* 45: 1037-1044
60. Kunkel B, et al (1978) Light-microscopic evaluation of myocardial biopsies, in In: Kaltenbach M, Loogen F, Olsen ECG (eds) *Cardiomyopathy and myocardial biopsy*. Springer, Berlin Heidelberg New York, pp 62-70
61. Noda S (1980) Histopathology of endomyocardial biopsies from patients with idiopathic cardiomyopathy: Quantitative evaluation based on multivariate statistical analysis. *Jpn Circ J* 44: 95-116
62. Baandrup U, Olsen EGJ (1981) Critical analysis of endomyocardial biopsies for patients suspected of having cardiomyopathy. I: Morphological and morphometric aspects. *Br Heart J* 45: 475-486
63. Edwards WD, Holmes Jr DR, Reeder GS (1982) Diagnosis of active lymphocytic myocarditis by endomyocardial biopsy. Quantitative criteria for light microscopy. *Mayo Clin Proc* 57: 521-525
64. Fenoglio Jr JJ, et al (1983) Diagnosis and classification of myocarditis by endomyocardial biopsy. *N Engl J Med* 308: 12-18
65. Hess ML, Hastillo A, Mohanty PK (1983) Inflammatory myocarditis: Incidence and response to T-lymphocyte depletion. *J Am Coll Cardiol* 1: 584 (Abstract).
66. Strain JE, et al (1983) Atypical presentations of myocarditis. *Circulation* 68: III-27 (Abstract)
67. Unverferth DV, et al (1984) Human myocardial histologic characteristics in congestive heart failure. *Circulation* 68: 1194-1200
68. Parillo JE, et al (1984) The results of transvenous endomyocardial biopsy can frequently be used to diagnose myocardial disease in patients with idiopathic heart failure. Endomyocardial biopsies in 100 consecutive patients revealed a substantial incidence of myocarditis. *Circulation* 69: 93-101
69. Zee-Cheng C-S, et al (1984) High incidence of myocarditis by endomyocardial biopsy in patients with idiopathic congestive cardiomyopathy. *J Am Coll Cardiol* 3: 63-70
70. O'Connell JB, et al (1984) Gallium-67 imaging in patients with dilated cardiomyopathy and biopsy-proven myocarditis. *Circulation* 70: 58-62
71. Daly K, et al (1984) Acute myocarditis. Role of histological and virological examination in the diagnosis and assessment of immunosuppressive treatment. *Br Heart J* 51: 30-35
72. Bolte H-D, Ludwig B (1984) Viral myocarditis: Symptomatology, clinical diagnostics and haemodynamics. In: Bolte H-D (ed) *Viral heart disease*. Springer, Berlin Heidelberg New York Tokyo, pp 177-187
73. Mills AS, Hastillo A, Hess ML (1984) Lymphocytic infiltration of the myocardium in idiopathic dilated cardiomyopathy: Underestimation of myocarditis with endomyocardial biopsy. *Circulation* 70: II-401 (Abstract)
74. Weiland DS, Donalson RF, Isner JM (1984) How well does the endomyocardial biopsy represent the state of the heart. *Circulation* 70: II-401 (Abstract)
75. Robinson JA, et al (1979) Gallium-67 imaging in cardiomyopathy. *Ann Intern Med* 90: 198-199
76. O'Connell JB, et al (1981) Immunosuppressive therapy in patients with congestive cardiomyopathy and myocardial uptake of gallium-67. *Circulation* 64: 780-786
77. O'Connell JB, et al (1984) Clinical and pathologic findings of myocarditis in two families with dilated cardiomyopathy. *Am Heart J* 107: 127-135
78. Melvin KR, et al (1982) Peripartum cardiomyopathy due to myocarditis. *N Engl J Med* 307: 731-734
79. O'Connell JB, et al (1984) Peripartum cardiomyopathy: Unique features. *Circulation* 70: II-152 (Abstract).
80. Vignola PA, et al (1984) Lymphocytic myocarditis presenting as unexplained ventricular arrhythmias: Diagnosis with endomyocardial biopsy and response to immunosuppression. *J Am Coll Cardiol* 4: 812-819

## Discussion

*Discussants:* Fowles, O'Connell, Billingham, Maisch, Edwards, Rużyłło

The question of the applicability of isotope analogues in detecting allograft rejection was raised. The 72-h delay with gallium imaging was considered to be undesirable in this situation, and a shorter imaging agent is desirable, particularly for monitoring therapy in myocarditis.

Reference to studies on indium in experimental animals was made, and good correlation between these studies and the morphologic changes has been observed. A newer technique assessing changes echocardiographically has been devised with a 100% correlation between echocardiographic changes and morphology on tissue obtained by biopome.

It was, however, emphasized that examination of biopsies is reliable for acute rejection myocarditis and adriamycin toxicity, particularly when five to ten samples from each ventricle have been obtained. Agreement between the presenter and another discussant on the reduction of IgM antibodies in the late phase of myocarditis was also reached.

It was finally agreed that myocarditis may mimic myocardial infarction, causing transmural myocyte necrosis. Biopsy and coronary arteriograms which are normal in these cases should assist in making an accurate diagnosis.