

ORIGINAL PAPER

doi: 10.5455/medarch.2018.72.272-275

MED ARCH. 2018 AUG; 72(4): 272-275

RECEIVED: APR 12, 2018 | ACCEPTED: AUG 08, 2018

¹Pediatric Clinic, Clinical Center University of Sarajevo, Sarajevo, Bosnia and Herzegovina

²Clinic of Radiology, Clinical Center University of Sarajevo, Sarajevo, Bosnia and Herzegovina

³Clinic for Nuclear Medicine, Clinical Center University of Sarajevo, Sarajevo, Bosnia and Herzegovina

Corresponding author: Ass. Prof. Danka Pokrajac, MD, PhD. Pediatric Clinic, Clinical Center University of Sarajevo. Patriotske lige 81, 71000 Sarajevo, Bosnia and Herzegovina. ORCID ID: <http://0000-0002-5998-5620>. Phone: ++ 387 61 724 284. E-mail: dankapokrajac@hotmail.com

Vesicoureteral Reflux and Renal Scarring in Infants After the First Febrile Urinary Tract Infection

Danka Pokrajac¹, Irmina Sefic-Pasic², Amela Begic³

ABSTRACT

Introduction: The objective of this research was to determine whether vesicoureteral reflux (VUR) was associated with evolution to renal scarring (RS) following a febrile urinary tract infection (UTI) in infants. **Materials and methods:** Our research included 100 infants, ages up to 1 year with a first febrile UTI. The diagnostic was based on results of: laboratory findings, ultrasonography (USG), voiding cystourethrography (VCUG) and initial and control renal scintigraphy (DMSA renal scan) with technetium^{99m}Tc succimer (dimercaptosuccinic acid), to assess the acute pyelonephritis (APN), VUR and RS. **Results:** APN was proven with DMSA renal scan in 66 (66%) infants. Twenty-two infants (33.3%) had VUR in-group of patients with APN. On the control DMSA scan, performed 6 months after the first DMSA, the presence of RS was found in 18 (27.27%) infants. In infants with renal scars VUR were discovered in 9 of them (50%). **Conclusions:** The pathogenesis of RS after febrile UTI in young children is multifactorial. Children with VUR have an increased risk for APN and RS. However, VUR is not the only precondition for RS. Creating a renal scarring cannot be imagined without the inflammatory process of the upper urinary system. Therefore, early detection and treatment of febrile UTIs in children and identify children at risk for RS are of primary importance.

Keywords: urinary tract infection, acute pyelonephritis, vesicoureteral reflux, renal scarring.

1. INTRODUCTION

Acute pyelonephritis is one of the most common serious bacterial infections that occurs in febrile infants and young children. In approximately 10% to 15% of cases, UTI leads to permanent RS, characterized by proteinuria, hypertension, chronic renal disease (CKD) (10%-24%) and problems in pregnancy (1, 2). The most important risk factors for RS are male gender, younger age of the child, P-fimbriatus *Escherichia coli*, VUR, recurrent UTIs, genetic predisposition and delayed antibiotic treatment (2, 3). The goal of imaging after the first febrile UTI in patients was the early detection of congenital abnormalities of the urinary tract that may predispose the child to additional persistent or recurrent UTIs and RS (4). In order to detect VUR, one of the following diagnostic methods were performed: voiding cystourethrography (VCUG), radioisotopic cystography (RC) and voiding ultrasonography (VUS). The most widely used method for detecting VUR was the classic VCUG. The DMSA renal scintigraphy was a radionuclide scan performed to detect APN and RS and is considered the gold standard. De-

velopment of non-invasive methods and techniques remains imperative to further scientific research. Therefore, contrast-enhanced ultrasound (CEUS) is a newer technique and do not involve radiation. Hains and colleagues in their pilot study think that CEUS is a highly sensitive, rapid, and cost-effective diagnostic imaging modality for detecting and monitoring RS in children with VUR (5).

2. MATERIALS AND METHODS

This is a retrospective study of children experiencing the first episode of UTI admitted to our hospital in period of 3 years. Hundred children (16% males, 84% females) were included in this study. Patients with congenital and acquired urological abnormalities, recurrent UTIs, renal failure, and afebrile UTI were excluded from the study.

Inflammatory markers, such as positive C-reactive protein (CRP), the erythrocyte sedimentation rate (ESR) > 25, white blood cells (WBCs) >13,000/mm³, were identified. UTI was defined as growth of more than 10⁵ CFU/ml from a sterile bag attached to the perineal area, more than 10⁴ CFU/ml in urine obtained

© 2018 Danka Pokrajac, Irmina Sefic-Pasic, Amela Begic

This is an Open Access article distributed under the terms of the Creative Commons Attribution Non-Commercial License (<http://creativecommons.org/licenses/by-nc/4.0/>) which permits unrestricted non-commercial use, distribution, and reproduction in any medium, provided the original work is properly cited.

	Total UTI patients (n=100)	Patients with APN (n=66)	Patients with lower UTI (n=34)	Patients with VUR (n=22)	Patients with RS (n=18)	Patients without RS (n=82)
Male/female ratio	16/84	12/54	4/30	6/16	4/14	12/70

Table 1. Patients' characteristics

by bladder catheterization, or any growth observed in suprapubic aspirate. Laboratory tests were performed using standard laboratory techniques at the Clinical Center University of Sarajevo (CCUS).

Renal USG was performed within the first 3 days of admission by expert pediatric radiologists using an ultrasound machine General Electric Volson 730 PRO with a convex probe of 5.0 MHZ and a linear multi frequency probe with a central frequency of 7.5 MHZ at the CCUS. USG findings of APN included altered parenchymal echogenicity, pelvicalycial dilatation or fullness, undifferentiated corticomedullary junction, and renal enlargement.

APN was defined as a UTI associated with a positive DMSA renal scan. The DMSA renal scintigraphy was performed during the first week of admission by injection of 2 MBq/kg Tc- 99m DMSA. To allow the cortical uptake, we waited 3 hours before imaging (6). An abnormal acute DMSA scan suggesting APN was defined as the presence of focal or diffuse areas of decreased cortical uptake, with preservation of the renal contour (1).

VUR was identified by conventional voiding cystourethrography (VCUG) within the first 2 weeks of acute febrile UTI. The VUR was graded from I to V according to the International Reflux Study in children (7). For easier comparison we have classified VUR as mild (grades 1-2), moderate (grade 3) and severe (grades 4-5).

All children with positive DMSA renal scanning results for APN were scheduled for repeated analysis after 6-8 months in order to detect any RS at the Clinic for Nuclear Medicine of the CCUS. RS was defined as the occurrence of focal or generalized areas of diminished uptake of the isotope at the same locations as in the APN on the first DMSA scan and/or associated loss of the kidney contour or cortical thinning with reduced volume. We used the protocol to interpret control DMSA renal scans taken from Slovenian researchers (8). We evaluated the degree of renal scarring as follows: mild, moderate and severe. The study was approved by the Ethics Committee of CCUS.

Statistical analyses

Statistical analyses were performed using *IBM Statistics SPSS v19.0* with package of tools for medical research and *MedCalc v10*. We used Fisher's exact test and student's *t*-test. A *P*-value of less than 0.05 was accepted as significant.

3. RESULTS

Acute pyelonephritis with first febrile UTI was demonstrated in 66 (66%) of 100 children, with DMSA renal scan. From 66 patients with APN, 22 (33.3 %) had VUR and 18 (27.27%) had a renal scar. Patients' characteristics are presented in *Table 1*.

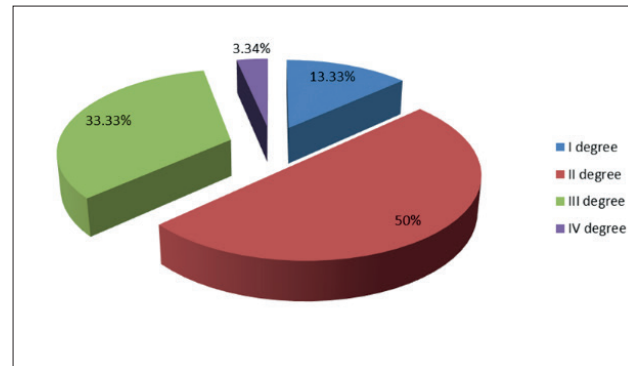


Figure 1. VUR grade determined by the number of affected renal units in infants with first febrile UTI




Figure 2. Control Tc- 99 m DMSA renal scan: severe renal scar on the left kidney in female infant. The share of left kidney in the relative renal function is 38.8% to 61.2% of the right kidney.

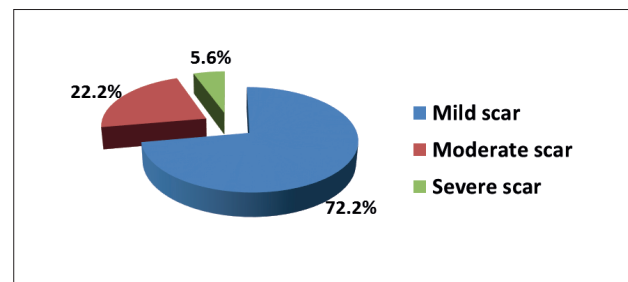


Figure 3. The severity grade of renal scarring based on the findings of the control DMSA renal scans

4. DISCUSSION

Acute pyelonephritis with the first febrile UTI by DMSA renal scan in our study was confirmed in 66 (66%) of 100 children (*Table 1*). APN had 54 (81.8%) female and 12 (18.2%) male infants. Two thirds of the male infants were between 1 and 6 months of age.

The VCUG method has been used in 66 patients with APN treated in our study and identified VUR in 22 (33.33%) infants (*Table 1*). Out of 16 boys with UTI, 6 (37.5%) had VUR and out of 84 girls with UTI, 16 (19.05%) had VUR which is a statistically significant difference in the prevalence of VUR by gender ($\chi^2 = 5.677$; $p = 0.0034$).

The frequency of VUR in children with first febrile UTI varies from country to country. Experts have found that in England VUR have 11.6% of evaluated infants, in the United States of America (USA) 18% and 39%, Sweden 18% and 26%, Spain 21%, Taiwan 29.60% and Croatia 33% (9-15).

In our study, the inflammatory parameters in infants with VUR were significantly higher than in patients without VUR. Other researchers (16) also noted such findings.

Out of the 30 kidney units affected by VUR, 96.66% children had mild and moderate forms of VUR suitable for successful treatment (*Figure 1*). All of our patients with VUR had pathological initial DMSA renal scans. On the DMSA renal scans, performed after 6 months, the presence of RS was found in 18 (27.27%) infants (*Figure 2, 3*) out of which 9 (50%) had VUR (50% male and 50% female).

The number of children with RS after the first febrile UTI in childhood ranges from surprising and unlikely 1.4% in Taiwan to 51% in Greece. Between these two extremes are the USA with 9.5%, Italy 15%, England 17%, Korea 30%, Sweden 38% and Switzerland 40% (10, 15, 17, 18, 19, 20, 21, 22). The data provided in the literature with the extremely low or high percentage of children with RS in certain countries cannot be accepted as reliable. In foreign studies, namely, patients are often not the same age, nor is the diagnosis always based on clinical-laboratory findings, the findings of ultrasound of the urinary system, VCUG and renal scintigraphy. From these groups, then, exercised evidence of RS by controlling DMSA renal scan after the past 6 months to 2 years of the first examination. It is not excluded that in this period could happen recurrent febrile UTIs which would result in a new scars. Based on the unequal distribution of RS in various countries arises conclusion that the RS is undoubtedly affected significantly by genetic and physical characteristics of individual nations.

Out of total number of 16 boys with UTI, the RS had 4 (25%) versus 14 (16.66%) girls out of 84 female infants, which was statistically significant difference regarding the presence of renal scar towards the gender of infants ($\chi^2 = 4.254$, $p = 0.042$). Out of 18 patients with RS, 13 (72.2%) of them had mild renal scar (*Figure 3*). This can be explained by the fact that it was a single febrile UTI with a relatively small proportion of VUR.

Montini concluded that VUR was poorly correlated with the resulting renal scar (19). Montini and his associates have offered new diagnostic algorithms for febrile UTIs in children so-called "top-down approach". New diagnostic algorithm suggests earlier performance of DMSA renal scan in children with UTI. After that would undergo to VCUG only the children with proven

APN and recurrent UTIs (2, 11, 12). Urology Section of the American Academy of Pediatrics has estimated that the new diagnostic trends have caused great damage to a significant number of the most vulnerable human population. Delaying the determination of accurate diagnosis would lead to a large number of children at risk of permanent RS, which is not the goal of pediatric nephrologists (23).

In theory and practice, it has long been mistakenly believed that findings of the RS were regularly triggered by VUR. Colossal technical-technological advances in diagnostics nowadays lead to a changing in interpretations of the place and role of VUR in the development of RS. Even without the presence of VUR, a renal scar appears at the site of inflammation after APN. This confirms the primary role of acute kidney inflammation in the etiology of acquired RS. Nevertheless, renal lesions have been found in lower grades or even in the VUR absence (9). Our results support the later findings.

The pathogenesis of RS following APN is multifactorial. There is no dispute that the anatomical and physiological immaturity of a child's organism is predisposing to a part of the children's population to become an object of interdependent diseases as APN, VUR and RS, especially children under 2 years of age. Today, the importance of genetic predisposition is clear for part of children's population to develop RS (24). There are number of open questions and dilemmas regarding the relationship between VUR and RS.

It is necessary to monitor the health status of patients with RS through out their lives. When the problem of RS is observed in planetary relationships, it should be noted that a large number of countries do not have the personnel, material and technical-technological opportunities for early detection of VUR and RS. Thus, a large number of children sentenced the absence of optimal treatment and further professional monitoring.

5. CONCLUSIONS

Children with VUR have an increased risk for APN and RS. However, VUR is not the only precondition for renal scars. Creating a RS cannot be observed without the inflammatory process of the upper urinary system. All the imaging studies of the urinary system in infants with febrile UTI should be adapted to each child as a separate individual and technical and technological possibilities and economic situation of the country in which the patient lives. Recent guidelines attempt to recommend imaging in high-risk children while avoiding unnecessary investigation in children who do not need them. We are hopeful that data from new studies, especially biomarkers and genetic studies can be used to develop individualized diagnostic and treatment options for children with a first febrile UTI.

- **Author's contribution:** all authors participated in all steps of preparation of this article. Final proof reading was made by the first author.
- **Conflict of interest:** none declared.

REFERENCES

1. Sheu JN, Wu KH, Chen SM, Tsai JD, Chao JH, Lue KH. Acute 99mTc DMSA scan predicts dilating vesicoureteral reflux in young children with a first febrile urinary tract infection: a population-based cohort study. *Clin Nucl Med.* 2013; 38: 163-168.
2. Pohl HG, Belman AB. The «Top- Down» Approach to the Evaluation of Children with Febrile Urinary Tract Infection. *Adv Urol.* 2009; 783-409.
3. Yilmaz S, Ozcakar ZB, Şükür KED, Bulum B, Kavaz A, Elhan AH, Yalcinkaya F. Vesicoureteral Reflux and Renal Scarring Risk in Children after the First Febrile Urinary Tract Infection. *Nephron.* 2016; 132(3): 175-180.
4. Hung TW, Tsai JD, Liao PF, Sheu JN. Role of Renal Ultrasonography in Predicting Vesicoureteral Reflux and Renal Scarring in Children Hospitalized with a First Febrile Urinary Tract Infection. *Pediatrics and Neonatology* 2016; 57: 113e-119.
5. Hains DS, Cohen HL, McCarville MB, Ellison EE, Huffman A, Glass S, Qureshi AH, Pierce KR, Cahill AL, Dixon A, Santos ND. Elucidation of Renal Scars in Children With Vesicoureteral Reflux Using Contrast-Enhanced Ultrasound: A Pilot Study. *Kidney International Reports.* 2017; 2: 420-424.
6. Ziessman HA, Majd M. Importance of methodology on (99m) technetium dimercapto-succinic acid scintigraphic image quality: imaging pilot study for RIVUR (Randomized Intervention for Children With Vesicoureteral Reflux) multicenter investigation. *J Urol.* 2009; 182: 272-279.
7. Lebowitz RL, Olbing H, Parkkulainen KV, Smellie JM, Tamminen-Möbius TE. International system of radiographic grading of vesicoureteric reflux. *International Reflux Study in Children. Pediatr Radiol.* 1985; 15: 105e.
8. Levart -Kersnik T, Kenig A, Fettich JJ, Ključevšek D, Novljan G, Kenda BR. Sensitivity of ultrasonography in detecting renal parenchymal defects in children. *Pediatr Nephrol.* 2002; 17: 1059-1062.
9. Hoberman A, Charron M, Hickey RW, Baskin M, Kearney DH, Wald ER. Imaging studies after a first febrile urinary tract infection in young children. *N Engl J Med.* 2003; 348(3): 195-202.
10. Fernandez-Menendez JM, Malaga S, Matesanz JL, Solis G, Alonso S, Perez-Mendez C. Risk factors in the development of early technetium-99m dimercaptosuccinic acid renal scintigraphy lesions during first urinary tract infection in children. *Acta Paediatr.* 2003; 92(1): 21-26.
11. Hansson S, Dhamey M, Sigström O, Sixt R, Stokland E, Wennerstrom M, Jodal U. Dimercapto-succinic acid scintigraphy instead of voiding cystourethrography for infants with urinary tract infection. *J Urol.* 2004; 172(3): 1071-1074.
12. Preda I, Jodal U, Sixt R, Stokland E, Hansson S. Normal dimercaptosuccinic acid scintigraphy makes voiding cystourethrography unnecessary after urinary tract infection. *J Pediatr.* 2007; 151(6): 581-584.
13. McDonald A, Scranton M, Gillespie R, Mahajan V, Edwards GA. Voiding cystourethrograms and urinary tract infections: how long to wait? *Pediatrics.* 2000; 105(4): E50.
14. Moorthy I, Wheat D, Gordon I. Ultrasonography in the evaluation of renal scarring using DMSA scan as the gold standard. *Pediatr Nephrol.* 2004; 19: 153-156.
15. Tseng MH, Lin WJ, Lo WT, Wang SR, Chu ML, Wang CC. Does a normal DMSA obviate the performance of voiding cystourethrography in evaluation of young children after their first urinary tract infection? *J Pediatr.* 2007; 150(1): 96-99.
16. Honkinen O, Jahnukainen T, Mertsola J, Eskola J, Ruuskanen O. Bacteremic urinary tract infection in children. *Pediatr Infect Dis J.* 2000; 19(7): 630-634.
17. Oostenbrink R, van der Heijden AJ, Mons KGM, Moll HA. Prediction of vesico-ureteric reflux in childhood urinary tract infection: a multivariate approach. *Acta Paediatr.* 2000; 89: 806-810.
18. Benador D, Benador N, Slosman DO, Mermillod B, Girardin E. Are younger children at highest risk of renal sequelae after pyelonephritis? *Lancet* 1997; 349: 17-19.
19. Montini G, Zucchetta P, Tomasi L, Talenti E, Rigamonti W, Picco G, Ballan A, Zucchini A, Serra L, Canella V, Gheno M, Venturoli A, Ranieri M, Caddia V, Carasi C, Dall'amico R, Hewitt I. Value of imaging studies after a first febrile urinary tract infection in young children: data from Italian renal infection study 1. *Pediatrics.* 2009; 123(2): e239-246.
20. Tasker AD, Lindsell DR, Moncrieff M. Can ultrasound reliably detect renal scarring in children with urinary tract infection? *Clin Radiol.* 1993; 47(3): 177-179.
21. Stokland E, Hellström M, Jacobsson B, Jodal U, Sixt R. Renal damage one year after first urinary tract infection: Role of dimercaptosuccinic acid scintigraphy. *J Pediatr.* 1996; 126(6): 815-820.
22. Jeon JH, Lee KH, Park JS. The Effect of Renal Scarring on Spontaneous Resolution and Breakthrough Infection in Children with Vesicoureteral Reflux. *Korean J Urol.* 2009; 50(7): 699-703.
23. Wan J, Skoog SJ, Hulbert WC, Casale AJ, Greenfield SP, Cheng EY, Craig AP and Executive Committee Section on Urology American Academy of Pediatrics. Section on Urology Response to New Guidelines for the Diagnosis and Management of UTI. *Pediatrics.* 2012: 2011-3615.
24. Zaffanello M, Tardivo S, Cataldi L, Fanos V, Biban P, Malerba G. Genetic susceptibility to renal scar formation after urinary tract infection: a systematic review and meta-analysis of candidate gene polymorphisms. *Pediatric Nephrology.* 2011; 26(7): 1017-1029.