

AOSpine—Spine Trauma Classification System: The Value of Modifiers: A Narrative Review With Commentary on Evolving Descriptive Principles

Srikanth N. Divi, MD¹, Gregory D. Schroeder, MD¹, F. Cumhur Oner, MD, PhD², Frank Kandziora, MD, PhD³, Klaus J. Schnake, MD⁴, Marcel F. Dvorak, MD⁵, Lorin M. Benneker, MD⁶, Jens R. Chapman, MD⁷, and Alexander R. Vaccaro, MD, PhD, MBA¹

Abstract

Study Design: Narrative review.

Objectives: To describe the current AOSpine Trauma Classification system for spinal trauma and highlight the value of patient-specific modifiers for facilitating communication and nuances in treatment.

Methods: The classification for spine trauma previously developed by The AOSpine Knowledge Forum is reviewed and the importance of case modifiers in this system is discussed.

Results: A successful classification system facilitates communication and agreement between physicians while also determining injury severity and provides guidance on prognosis and treatment. As each injury may be unique among different patients, the importance of considering patient-specific characteristics is highlighted in this review. In the current AOSpine Trauma Classification, the spinal column is divided into 4 regions: the upper cervical spine (C0-C2), subaxial cervical spine (C3-C7), thoracolumbar spine (T1-L5), and the sacral spine (S1-S5, including coccyx). Each region is classified according to a hierarchical system with increasing levels of injury or instability and represents the morphology of the injury, neurologic status, and clinical modifiers. Specifically, these clinical modifiers are denoted starting with M followed by a number. They describe unique conditions that may change treatment approach such as the presence of significant soft tissue damage, uncertainty about posterior tension band injury, or the presence of a critical disc herniation in a cervical bilateral facet dislocation. These characteristics are described in detail for each spinal region.

Conclusions: Patient-specific modifiers in the AOSpine Trauma Classification highlight unique clinical characteristics for each injury and facilitate communication and treatment between surgeons.

Keywords

spinal cord injury, thoracolumbar, lumbosacral, cervical, spinal injuries

Introduction

Historically, treatment of spine trauma management has been variable and is based on anecdotal rather than systems-based practices. Institutional, regional, and individual surgeon preferences often dictate treatment. One of the principal reasons is likely a lack of a universally accepted classification system. Important elements of a successful classification system facilitate communication and agreement between physicians while also determining injury severity and provide guidance on prognosis and treatment guidelines. Many classification systems

¹ Rothman Institute at Thomas Jefferson University Hospital, Philadelphia, PA, USA

² University Medical Center, Utrecht, Netherlands

³ Berufsgenossenschaftliche Unfallklinik Frankfurt, Frankfurt am Main, Germany

⁴ Schön Klinik Nürnberg Fürth, Fürth, Germany

⁵ Vancouver General Hospital, Vancouver, British Columbia, Canada

⁶ Insel Hospital, Bern University Hospital, Bern, Switzerland

⁷ Harborview Medical Center, Seattle, WA, USA

Corresponding Author:

Srikanth N. Divi, Department of Orthopaedic Surgery, Rothman Institute, Thomas Jefferson University Hospital, 925 Chestnut St, 5th Floor, Philadelphia, PA 19107, USA.

Email: srikanth.divi@rothmanortho.com



have been developed in the past for spine trauma—ranging from purely anatomic to mechanistic criteria. However, a variety of factors such as nebulous characteristics and lack of comprehensiveness as well as irrelevance toward addressing injury severity have led to absence of a single entity having been universally accepted and used. In addition, most systems have never been subjected to formal validation and are thus foundationally suspect. Hence, there has been a clear clinical need to continue to improve existing classifications and work toward a universally accepted classification system that is simple, easily reproducible, and clinically validated.

The recently introduced AOSpine Trauma classification has undertaken unprecedented efforts toward achieving this goal through a true international multispecialty consensus building approach. While the basics of this system fulfill the above-mentioned characteristics, in clinical practice, several variables have emerged as being strongly correlated to outcomes. In order to address these, the AOSpine Knowledge Forum has proposed introduction of a number of such clinical conditions in a system of “modifiers” as supplements to the basic alphanumeric system to enhance the granularity of information expressed in an efficient fashion with a simple supplemental system. The purpose of this article is to review the process of developing spine trauma classifications and why such modifiers matter and are best applied in supplemental fashion to a larger more comprehensive system.

Historical Context

Several classification systems have been proposed in the past for spine trauma. Nicoll initially described fractures and dislocations of the thoracolumbar spine in 1949 and classified stability based on their risk of increased deformity with possible cord injury with functional activity.^{1,2} Sir Holdsworth subsequently expanded on this to describe fractures of the entire spinal column, where he proposed the posterior ligamentous complex was the sole key to spinal stability.³ Kelley and Whitesides were the first to suggest a biomechanical concept of spinal stability—an anterior and posterior column composed of vertebral bodies and the neural arches.^{2,4} In 1983, Denis expanded this to include a 3-column model.⁵ Here, the addition of a hypothetical middle column consisting of the posterior longitudinal ligament, posterior annulus fibrosus, and the posterior vertebral body was identified as a key component to spinal stability.⁵ This classification became popular despite biomechanical evidence and a lack of understanding of the systems relevant details. All the aforementioned classification systems organize the injuries morphologically and thus spinal stability is inferred from radiological assessment. However, no single system fully describes the overall injury taking into account the patient’s medical and neurological status, and mechanism and severity of the injury. All of these factors are important in clinical decision making for conservative versus operative treatment.

Mechanistic classifications describe the deforming forces at the time of injury and group together similar injuries. In 1994,

Magerl et al developed a mechanistic classification for thoracolumbar fractures.⁶ Based on principles of the AO fracture classification, the authors divided injuries into 3 main patterns: compression, distraction, and axial rotation with further subdivisions representing the severity of the injury. While it was also designed to guide treatment, it never gained widespread use due to its perceived complexity of over 64 subtypes, resulting in poor interobserver agreement.^{2,7} Recognizing these drawbacks, in 2005, the Spine Trauma Study Group created a simple point-based classification system for thoracolumbar fractures to make it more clinically applicable and apply a hitherto unprecedented severity scoring system.⁸ The main criteria included injury morphology, along with 2 novel and important criteria: the integrity of the posterior ligamentous complex and the neurologic status of the patient. These criteria were integrated into the thoracolumbar classification system (Thoracolumbar Injury Classification and Severity Score [TLICS]) as well as the cervical subaxial classification system (Subaxial Cervical Spine Injury Classification and Severity Score [SLIC]).^{8,9} The inclusion of the neurologic status was made in reflection of the importance of patient neurologic injury status on outcomes and management as determined by a large international clinician expert panel. One of the shortcomings, however, is that these systems still do not consider patient-specific details such as the patient’s underlying medical condition or other spinal ailments.

Current AOSpine Trauma Classification

In 2013, the AOSpine Knowledge Forum developed a spinal trauma classification system designed to be comprehensive, yet easy to use.¹⁰ Improving on the previous AO Magerl classification and using the expertise and additional insights gained by the work of the Spine Trauma Study Group, it was designed to describe the stability of the injury while considering patient-specific variables to create a consistent set of treatment guidelines. It also allows surgeons to effectively communicate case-specific details without sacrificing simplicity. This basic system has been since then extended to the other regions of the spinal column.

The current AOSpine Trauma classification subdivides the spinal column into 4 regions: the upper cervical spine (C0-C2), subaxial cervical spine (C3-C7), thoracolumbar spine (T1-L5), and the sacral spine (S1-S5, including coccyx). Each region is classified according to a hierarchical system with increasing levels of injury or instability. If multiple injuries to the spine exist in a single patient, the worst injury is listed first to emphasize the appropriate treatment. Essentially, this system evaluates 3 different items essential to understand the severity of the injury and prognosis: (1) morphology of the injury, (2) neurologic status, and (3) clinical modifiers.

Morphologic classification is based on radiologic exams and described separately for different regions. Fractures are classified into A, B, and C types with subclassifications if necessary. The neurologic status of the patient is also an important component of this classification system and essentially the same for

Table I. Case-Specific Clinical Modifiers

	M1	M2	M3	M4
Upper cervical	Potential for instability (eg, TAL midsubstance tear)	High risk of nonunion (eg, odontoid waist fractures)	High-risk patient characteristics (age, comorbidities, bone disease, etc)	Vascular injury/abnormality
Subaxial cervical	Possible posterior capsuloligamentous complex injury	Critical disc herniation in presence of facet dislocation	Bone disease/abnormality	Vascular injury/abnormality
Thoracolumbar	Possible posterior capsuloligamentous complex injury	Bone disease/abnormality	—	—
Sacral	Soft tissue injury (degloving, hematoma, etc)	Bone disease/abnormality	Anterior pelvic ring injury	Sacroiliac joint injury

Abbreviation: TAL, transverse atlantal ligament.

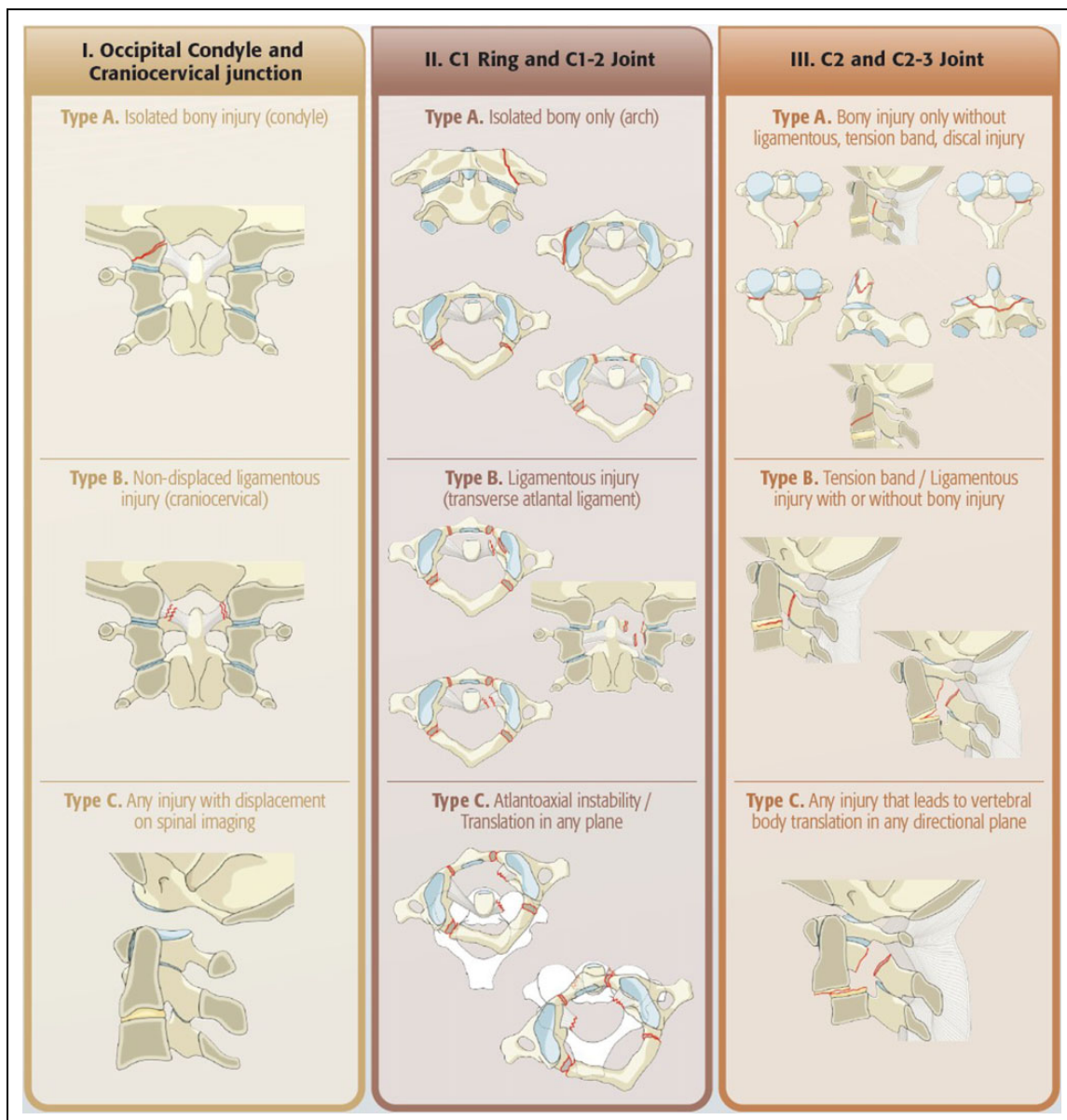


Figure I. Upper cervical spine classification. Reprinted with permission from AOSpine International. © AOSpine International, Switzerland.

all regions. Neurology is denoted starting with N and describes the neurologic status at the initial clinical examination at the emergency room. N0 indicates a neurologically intact patient, whereas N1 indicates patients that had a transient neurologic deficit that has completely recovered by the time of clinical examination. N2 denotes a nerve root injury or radiculopathy, whereas N3 denote incomplete spinal cord injury or complete or incomplete cauda equina injury. N4 means complete spinal cord injury. Nx is used when a patient is unable to be examined and the neurological status is unknown. The plus sign (+) modifier is used to signify continued spinal cord compression in a patient with a neurological injury.

Another key element to this system is the use of “clinical modifiers” to account for some of the most relevant aspects of spinal trauma patient heterogeneity (Table 1). More than one modifier can be used if needed. These modifiers are denoted starting with M followed by a number. Each number describes a different type of injury and does not correlate with increasing severity. These modifiers describe the patient-specific characteristics that are important to consider as they may affect treatment or prognosis. They are case-specific and describe unique conditions that may affect clinical decision making. Examples of this are characteristic injury patterns or uncertainties that would change treatment, such as the presence of significant soft tissue damage, uncertainty about tension band injury, or the presence of a critical disc herniation in a cervical bilateral facet dislocation. Another example may be the presence of presence of significant medical comorbidities or metabolic bone disease resulting in poor bone quality. These modifiers are intended to assist surgeons in treating patients with varying injuries, while also setting the foundation toward standardizing treatment by providing foundations for guideline development. The aim of this commentary is to review the existing AOSpine classification system for each spinal region and identify the role for case-specific clinical modifiers.

Upper Cervical Spine

Historically, upper cervical spine (UCS) fractures have been subdivided anatomically based on injuries affecting the skull base, the C1 ring, and the C2 odontoid process or C2 ring. The UCS is distinct from the subaxial spine given its unique anatomy and function. Most of cervical flexion-extension and rotation comes from the UCS and its stability relies heavily on ligamentous structures.¹¹ Several UCS fracture classifications exist based on the level involved. Anderson and Montesano were the first to classify occipital condyle fractures based on the direction of force causing the injury, and Tuli et al subsequently broadened the classification system to guide treatment.^{12,13} The Traynelis classification groups traumatic occipitocervical dislocation based on the direction of displacement, whereas the later described Harborview classification uses degree of displacement to infer instability.^{14,15} Fractures of the C1 ring can occur in the anterior arch, posterior arch, or both, and previous classification systems have tried to account for the integrity of the transverse atlantal ligament (TAL) to

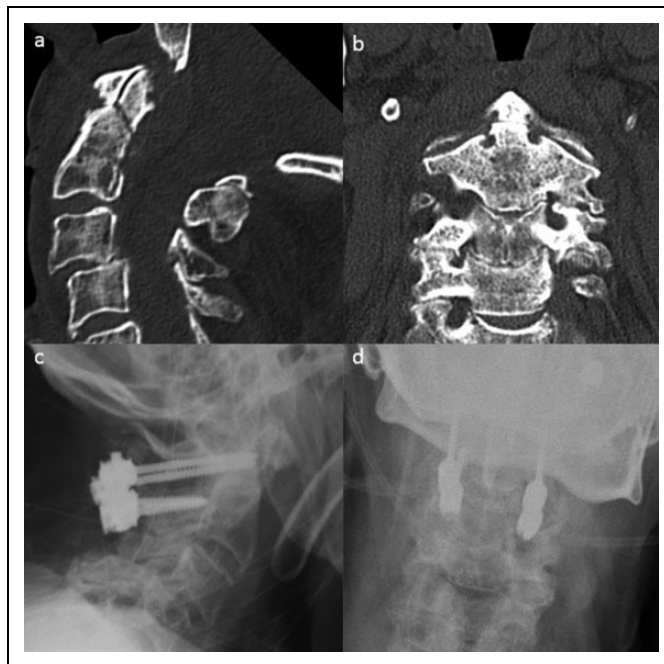

Figure 2. C2 odontoid fracture at the waist in an 80-year-old patient. There is minimal displacement in the (a) sagittal and (b) coronal planes. However, given the patient's age, this fracture is at a high risk of nonunion and thus was managed operatively with C1-C2 fixation (c and d).

determine stability and treatment. For axis fractures, the Anderson and D'Alonzo classification is the most widely used for dens fractures, whereas other classification systems exist for fractures of the C2 ring and C2 body.¹⁶⁻¹⁸ Due to the many existing classifications, there is a need for a unifying classification system that is simple to utilize and helps guide treatment. In addition, since there are a wide variety of fractures unique to the UCS, case-specific modifiers are important in identifying nuances in treatment.

The morphology component of the AOSpine UCS fracture classification simplifies the existing classification systems by combining all levels from the occiput to the C2-3 facet joint complex into 3 anatomic categories (Figure 1). Each category describes the bony element and the joint complex just caudal to it. The first category is labelled OC and involves injuries to the occipital condyle (C0) or the occipital cervical (C0-1) joint complex. The second category is labelled C1 and describes injuries to the C1 ring or the C1-2 joint complex, whereas the third category is labelled C2 and describes injuries to C2 (dens, body, or ring) or the C2-3 joint complex. Within each category, injuries are divided into 3 types based on the grade of injury: A, B, and C. Type A injuries are bony injuries alone, without any significant ligamentous, intradiscal, or tension band injuries, where conservative management is most often appropriate. Type B injuries are tension band or ligamentous injuries with or without associated bony injuries. Depending on the injury characteristics, these can be either stable or unstable and require operative management. Type C injuries include those

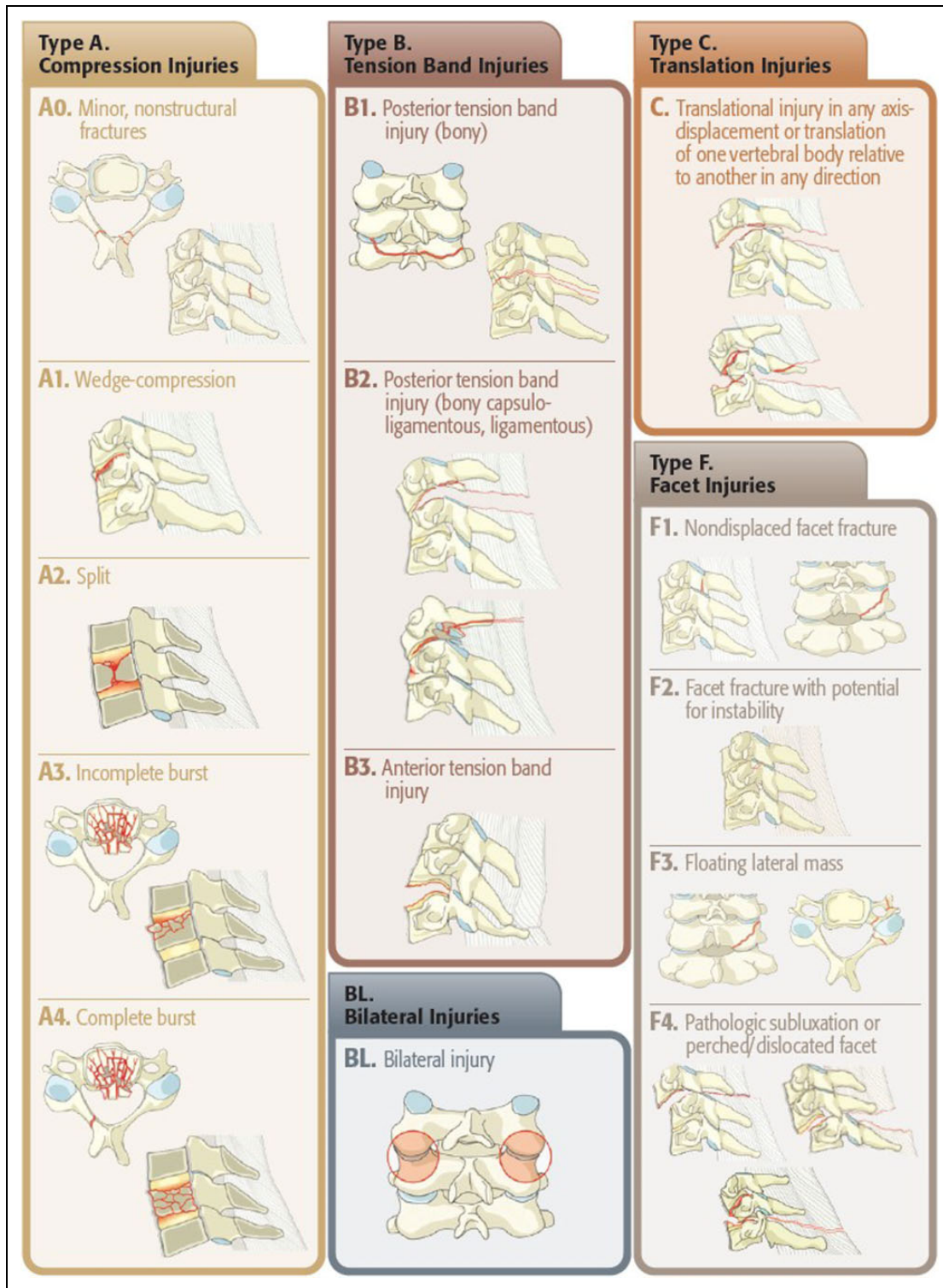


Figure 3. Subaxial cervical spine classification. Reprinted with permission from AOSpine International. © AOSpine International, Switzerland.

with significant translation of adjacent vertebrae in any direction and separation of anatomic integrity. These are inherently unstable injuries that always require operative treatment.

There are 4 case-specific modifiers (M1-M4) for the UCS classification and they are important to note for several

common injuries. An M1 modifier denotes an injury with significant potential for instability such as a nondisplaced ligamentous injury to the craniocervical junction. An example where an M1 modifier would be appropriate is in the setting of a mid-substance tear to the TAL, where if more than 6.9 mm

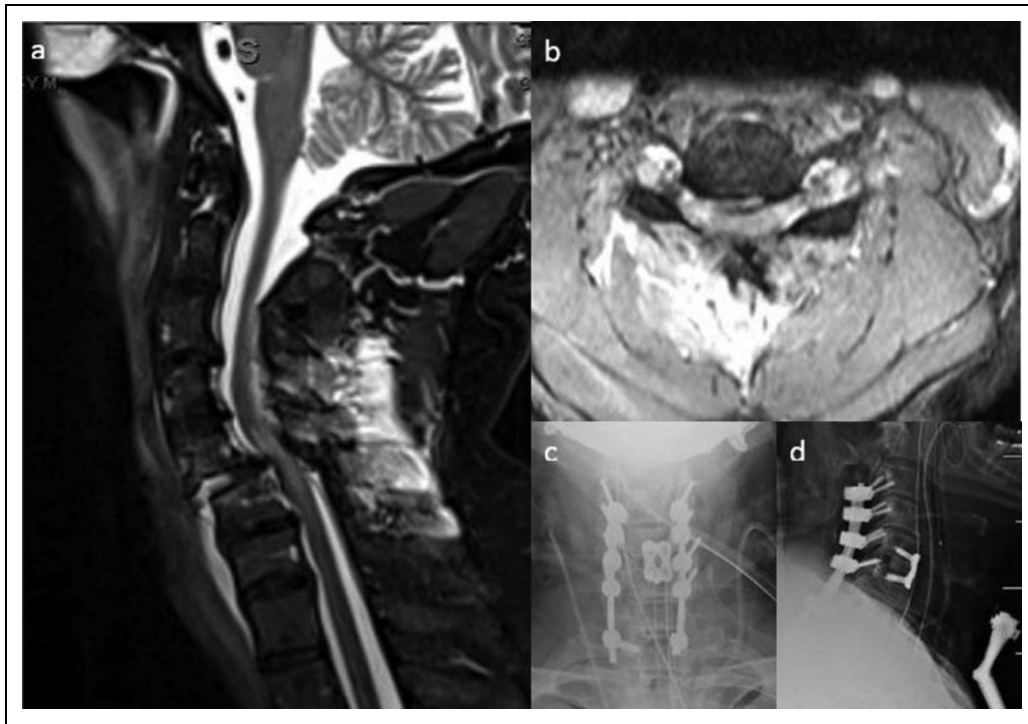


Figure 4. A 54-year-old male presenting with bilateral facet dislocation. Use of an M2 modifier designates the presence of a critical disc herniation. (a) Sagittal and (b) axial T2 MRI showing anterior translation of C5 with critical disc herniation and cord injury at C5-6. (c) AP and (d) Lateral plain films show cervical fixation with ACDF performed prior to posterior cervical fixation to address the critical disc herniation.

of displacement is identified between C1 lateral masses in the coronal plane (“rule of Spence”), then instability is present at the atlantoaxial joint, which may necessitate operative treatment. Using this modifier, the surgeon can clearly communicate the status of the injury. An M2 modifier denotes injuries that are at high risk of nonunion with nonoperative treatment. For example, C2 odontoid fractures at the waist with displacement greater than 5 mm, or displacement after a trial of conservative treatment, patient age greater than 50 years. Figure 2 shows an example of this fracture in an 80-year-old patient with this fracture. Given the patient’s age, this fracture would be at high risk for a nonunion and thus the classification would be labeled as C2 Type A, M2. Reading this modifier allows another clinician to infer that this is a bony injury; however, it is at high risk for nonunion and thus operative fixation should be considered. An M3 modifier refers to patient-specific characteristics that would affect treatment such as age, smoking status, medical comorbidities, concurrent injuries, or metabolic bone disease. An M4 modifier refers to a vascular injury or abnormality that would affect treatment. Specifically, in the upper cervical spine this refers to vertebral artery aberrant anatomy or injury.

Subaxial Cervical Spine

The first mechanistic classification for the subaxial cervical spine was developed by Allen and Ferguson in which they described cervical fractures and dislocations based on

6 mechanisms of injury.¹⁹ This system accurately and comprehensively describes all patterns of cervical trauma; however, it is difficult to apply clinically and lacks significant interobserver reliability.²⁰ Subsequently, Harris et al proposed a new mechanistic classification with 7 main categories with several subgroups; however, this too was limited in clinical use.²¹ The Spine Trauma Study Group created the Subaxial Cervical Spine Injury classification system (SLIC) in 2007 to combine previous systems and help guide treatment.⁹ The Cervical Spine Injury Severity Score (CSISS) is another point-based trauma classification system that divides the subaxial cervical spine into 4 columns: anterior, posterior, and 2 lateral pillars and summates injuries to all columns. However, unlike the SLIC it does not include neurologic status, thus limiting its applicability.²² While the latter 2 classifications have higher interobserver reliability scores than the previous Allen and Ferguson classification, no single system has gained widespread use.²³ The AOSpine classification addresses this by creating a comprehensive system based on morphological characteristics. With the incorporation of case-specific modifiers, the surgeon can accurately differentiate stable injuries that can be treated conservatively versus unstable injuries that require operative treatment.

The AOSpine classification for the subaxial cervical spine divides injuries into 3 major types: type A (compression injuries), type B (tension band injuries), and type C (translation injuries). Unique to the subaxial classification is subclassification of injuries to the facet joints, denoted as type F.²⁴ This is

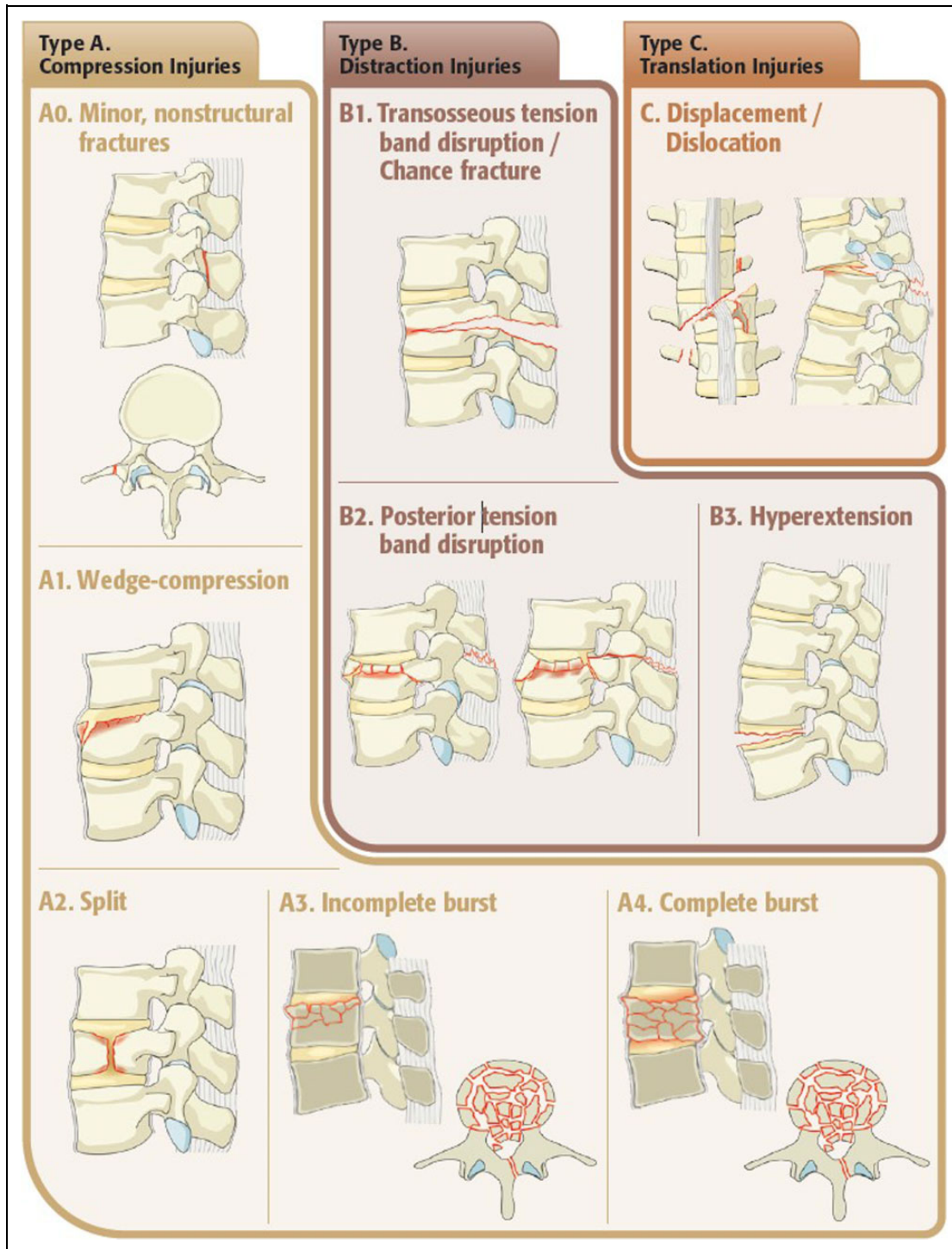


Figure 5. Thoracolumbar classification. Reprinted with permission from AOSpine International. © AOSpine International, Switzerland.

used in special circumstances, such as in an isolated facet joint fracture, bilateral facet dislocation, or a floating lateral mass. Figure 3 shows the classification system, and the specifics of the system are described in another article.²⁵ It is important to note that type F fractures are unique to this classification and are used to denote stability of isolated facet fractures or indicate subluxation/dislocation without a fracture.

Case-specific modifiers for the subaxial cervical spine are slightly different compared to the UCS classification. Here, M1 denotes possible injury to the posterior capsuloligamentous complex without complete disruption. One example where this modifier would be important to use would be in a patient that has a type A3 or A4 injury, where there are equivocal findings on radiographic studies or magnetic resonance imaging (MRI) in

the posterior soft tissue. If the surgeon cannot definitively say that there is presence of disruption of the posterior ligamentous complex, this modifier helps communicate that the patient may have a stable or an unstable injury and that they should be monitored closely. An M2 modifier indicates the presence of a critical disc herniation, an important distinction to make in the presence of a unilateral or bilateral facet dislocation that is going to be treated with closed reduction. Using this modifier communicates to the surgeon that the disc herniation present anteriorly may shift posteriorly during the reduction maneuver and further injure the spinal cord. In this case, the surgeon may decide to approach the injury anteriorly first to remove the disc herniation before applying fixation posteriorly. An example of this is shown in Figure 4, where a 54-year-old male presented with a bilateral facet dislocation with concurrent critical disc herniation with impingement on the spinal cord. In this case, the patient underwent an ACDF (anterior cervical discectomy and fusion) at C5-6, followed by posterior cervical fixation. M3 is used to emphasize bony abnormality such as stiffening or metabolic bone disease that creates a rigid lever arm and increases forces around the site of injury. Examples of this may include diffuse idiopathic skeletal hyperostosis (DISH), ankylosing spondylitis (AS), ossification of the posterior longitudinal ligament, and ossification of the ligamentum flavum. This is important to note as these patients require extra levels of fixation to prevent failure of instrumentation or fracture. Finally, M4 is the same as in the UCS classification and is used to denote vertebral artery abnormality.

The subaxial classification system was recently validated using a consensus process between experienced spine surgeons worldwide with an average interobserver reliability of 0.67 (κ) and an average intraobserver reliability of 0.75 (κ) among all subtypes and has been shown to be more reliable than the Allen and Ferguson classification.^{24,26} However, further work is needed to specifically compare the interobserver and intraobserver reliability of case-specific modifiers in subaxial spine trauma.

Thoracolumbar Spine

The previously described TLICS system is a validated thoracolumbar classification system that was developed to guide treatment.⁸ While the classification is used widely in the United States, some inconsistencies have prevented it from being adopted universally. For example, one study found that it accurately predicted treatment 99% of nonoperative cases, but it only accurately predicted treatment in 46.6% of patients in the operative treatment group.²⁷ The main drawback of this system is that it relies on interpretation of stability of the posterior ligamentous complex on MRI, which inherently varies between surgeons. The AOSpine thoracolumbar classification attempts to simplify fracture classification and guide treatment by creating hierarchical, morphologic criteria. Specifically, the use of case-specific modifiers can help decrease variability and consolidate treatment patterns.

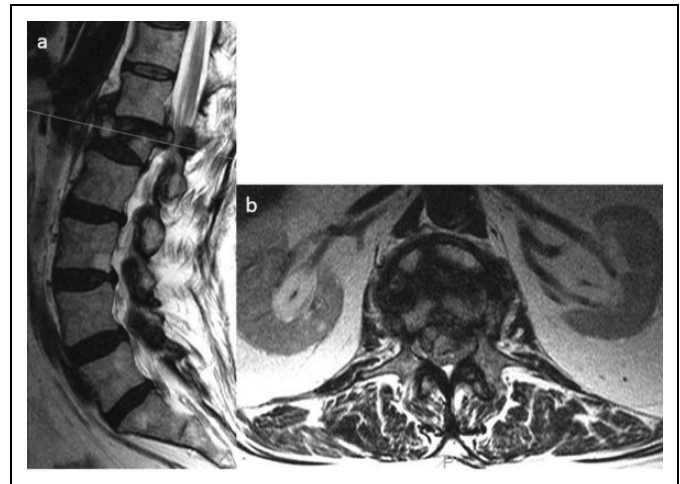


Figure 6. L1 burst fracture with indeterminate posterior soft tissue injury.

Like the previously described systems, type A injuries indicate compression, type B injuries indicate distraction, and type C injuries indicate translation.¹⁰ Figure 5 shows the thoracolumbar classification, and it is described in detail in another article.²⁵ There are only 2 patient-specific modifiers for this region, M1 and M2. Similar to the subaxial cervical spine classification, the former is used when there is an indeterminate injury to the posterior ligamentous complex on MRI. This is a critical distinction to make in the case of a burst fracture such as A3 or A4. By adding M1 to the injury description, the surgeon acknowledges that imaging findings of injury to the posterior elements are equivocal and that instability may exist. This may help surgeons decide to be more aggressive in treatment and stabilization. Figure 6 shows an example of an L1 burst fracture with indeterminate soft tissue injury. An M2 modifier is used in the presence of metabolic bone disease (eg, osteoporosis) or conditions that cause a rigid spine with a long lever arm such as DISH or AS, since this may lead to increased instability. Again, this modifier would help surgeons decide operative treatment.

Kepler et al recently looked at the reliability of the thoracolumbar classification among 100 spine surgeons and found an overall interobserver reliability (κ) of 0.56 and overall intraobserver reliability (κ) of 0.68.²⁸ This is a marked improvement from the previous AO Magerl classification system, which had lower rates of interobserver reliability (0.28 to 0.41).²⁹ While the TLICS classification also had moderate interobserver reliability (0.63) like the AO classification, the evaluation of the posterior ligamentous complex, which is an integral aspect of the classification, was much less reliable (0.11 to 0.45), thus limiting its actual use.^{30,31} The AOSpine thoracolumbar classification system circumvents the drawbacks in other systems and provides a comprehensive yet easy to use system that improves communication between surgeons. Further validation is needed for the case-specific modifiers specifically, since they add an important component to this classification system.

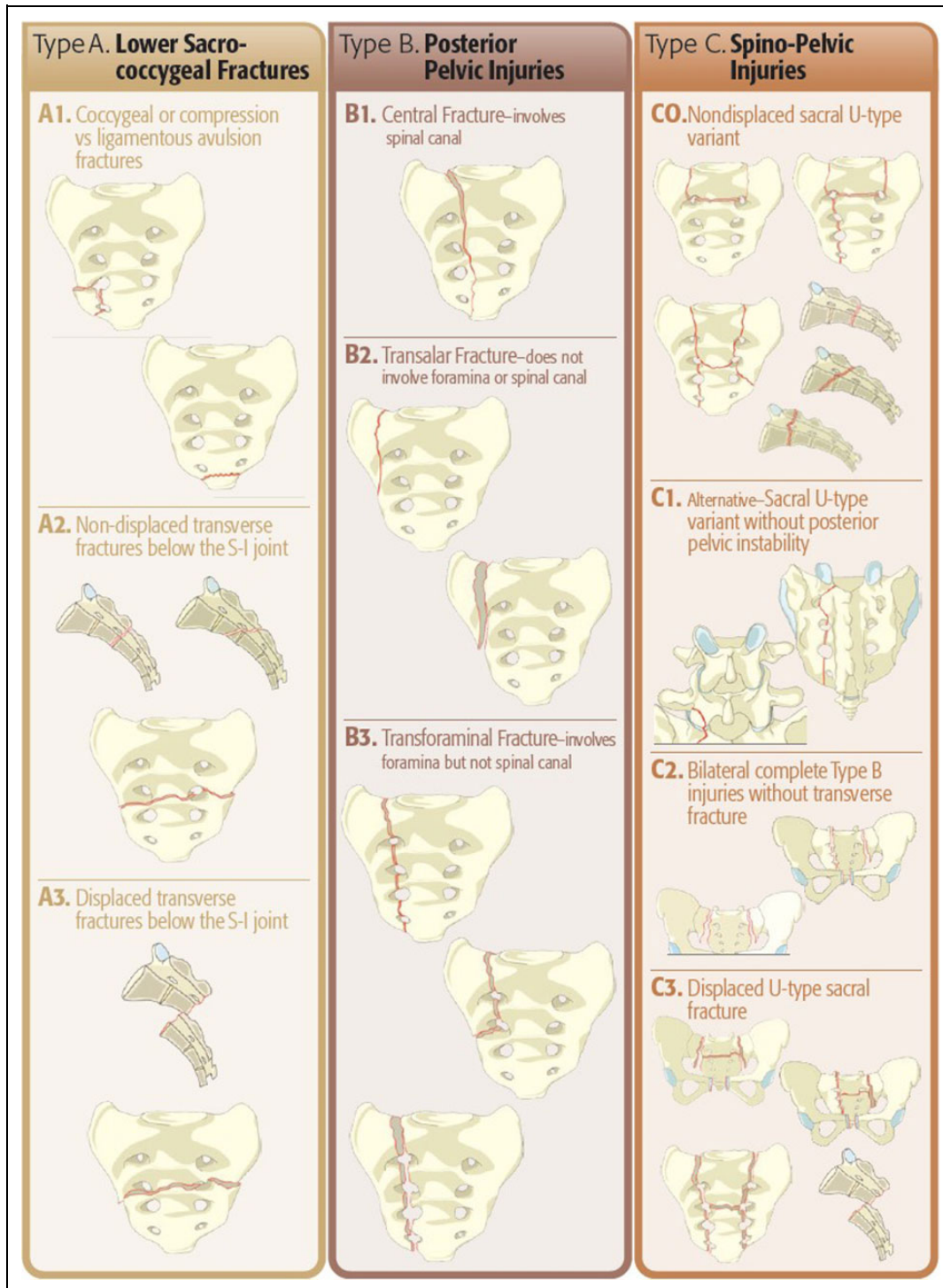


Figure 7. Sacral classification. Reprinted with permission from AOSpine International. © AOSpine International, Switzerland.

Sacral Spine

Sacral fractures typically result from a high-energy mechanism of injury with a high rate of neurologic injury.³² Due to their association with pelvic ring injuries, classifications for sacral fractures have historically fallen into general trauma classifications for pelvic ring injuries such as the Letournel or Tile

classifications.^{33,34} Isler described sacral fractures associated with pelvic ring injuries and lumbosacral instability based on the fracture pattern.³⁵ Currently, the most widely used classifications for intrinsic sacral fractures include the Denis classification for vertical fractures, the Roy-Camille classification for transverse fractures, and a descriptive classification for combined vertical and transverse fractures (H, T, U,

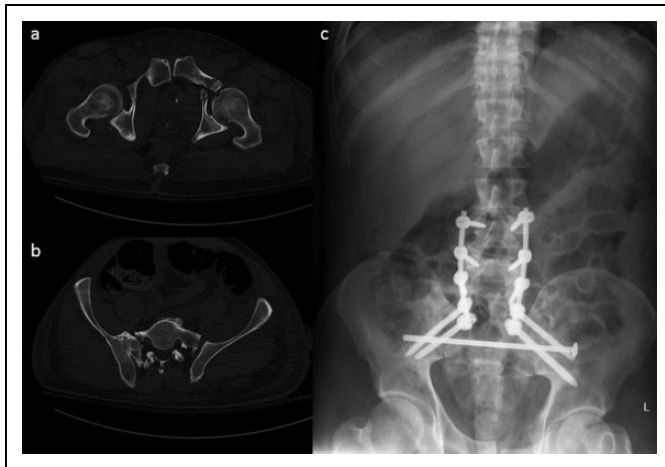


Figure 8. Sacral fracture with M3 modifier. (a) Axial CT shows anterior pelvic ring injury in the setting of (b) bilateral sacral ala fractures with left SI joint widening. (c) Plain films show lumbopelvic and sacral fixation without need (in this case) for anterior pelvic fixation.

lambda).^{36,37} Given the existence of several different classification systems and the treatment of these injuries by orthopedic traumatologists and spine surgeons alike, there is a need for a unifying classification system to facilitate communication and guide treatment.

The AOSpine sacral fracture classification system, similar to the aforementioned groups, is a hierarchical system divided into 3 main groups based on morphological criteria: A (lower sacro-coccygeal) fractures, B (posterior pelvic injuries), and C (spino-pelvic injuries). Each group is further subdivided into 3 or 4 subtypes based on the grade of injury. Figure 7 describes this classification system. Type A fractures describe more stable patterns of injury and describe injuries to the lower sacro-coccygeal spine with 3 subtypes (A1-A3). Type B fractures primarily impact posterior pelvic stability with no impact on spinopelvic stability. Type C fractures refer to higher energy injuries with spinopelvic instability and are divided into 4 subtypes. These are typically bilateral longitudinal injuries with occasional sacral U or H type variants or L5-S1 facet injuries. Due to bilateral fracture lines in the sacrum, the pelvis and lower appendicular skeleton becomes dissociated from the axial skeleton, creating spinopelvic instability.³⁸

There are 4 case-specific modifiers specific for sacral fractures (M1-M4). M1 indicates a soft tissue injury such as a degloving injury or hematoma that may complicate a surgical approach. M2 indicates metabolic bone disease such as osteoporosis that necessitates multiple points of fixation. M3 signifies a concurrent anterior pelvic ring injury. Depending on the amount of displacement in the anterior pelvic ring, this may affect that surgical approach for patients and thus this injury should be accounted for. Figure 8 shows an example of a sacral fracture with a vertical fracture line travelling through the right sacral foramen, along with a contralateral sacral ala fracture with SI joint widening. This bilateral longitudinal sacral injury signifies lumbopelvic dissociation and warrants operative

treatment. There is also a concomitant anterior pelvic ring injury; thus, this fracture would be assigned an M3 modifier. While the operative treatment of this patient involved only sacral fixation and lumbopelvic fixation without a need for anterior pelvic treatment, this modifier is important as it effectively communicates that an anterior injury exists and may alter the surgical approach. M4 indicates a concurrent SI joint injury. Classification of the neurological status is also the same as previous regions, with the distinction that there is no N4 category in case of complete neurologic injury. These are designated as N3, since in the sacrum this injury always presents as cauda equina syndrome.

This sacral classification system has been proposed and adopted after a consensus meeting among AOSpine surgeons internationally. However, to date, there have not been any validation studies. An international effort for validation of this classification system is needed.

Conclusion

Tasked with creating a new classification for spine trauma, the AOSpine Knowledge Forum Trauma group has developed a unified classification system for trauma to the entire spinal column. This includes the upper cervical spine, subaxial cervical spine, thoracolumbar spine, and the sacrum. The morphological part of the system is based on the hierarchical AO fracture classification system with 3 main categories (A, B, and C) with several subtypes based on the grade of the injury. Neurologic status at the initial admission is also classified into a simple and understandable system, which is the same for all the spine regions. In order to enhance granularity of the individual underlying patient status and also incorporate important additional clinical information, a system of supplemental modifiers was created by consensus of the largest multispecialty spine society of its kind through a series of consensus-based validation studies lead by the AOSpine Trauma Knowledge Forum. In addition to the basic alphanumeric injury description system, patient-specific modifiers consider important injury and disease characteristics that may dictate operative versus conservative treatment and influence outcomes. These are important considerations in trauma patients as the use of modifiers facilitates communication between surgeons and consolidates treatment patterns. Preliminary validation studies carried out for the subaxial cervical spine and the thoracolumbar spine indicate their interobserver and intraobserver reliability. While further validation studies need to occur, the descriptions provided in this review are an initial step in creating comprehensive, easy to use, and universally accepted classification systems for spine surgeons worldwide.

Acknowledgments

The classification system is the previous work of the AOSpine Knowledge Forum. AOSpine is a clinical division of the AO Foundation—an independent medically guided nonprofit organization. Picture representations of the classification systems can be found online at www.aospine.org.

Declaration of Conflicting Interests

The author(s) declared no potential conflicts of interest with respect to the research, authorship, and/or publication of this article.

Funding

The author(s) disclosed receipt of the following financial support for the research, authorship, and/or publication of this article: This study was organized and funded by AOSpine International through the AOSpine Knowledge Forum Tumor, a focused group of international spine oncology experts acting on behalf of AOSpine. Study support was provided directly through the AOSpine Research Department.

References

- Nicoll EA. Fractures of the dorso-lumbar spine. *J Bone Joint Surg Br.* 1949;31B:376-394.
- Mirza SK, Mirza AJ, Chapman JR, Anderson PA. Classifications of thoracic and lumbar fractures: rationale and supporting data. *J Am Acad Orthop Surg.* 2002;10:364-377.
- Holdsworth F. Fractures, dislocations, and fracture-dislocations of the spine. *J Bone Joint Surg Am.* 1970;52:1534-1551.
- Kelly RP, Whitesides TE Jr. Treatment of lumbodorsal fracture-dislocations. *Ann Surg.* 1968;167:705-717.
- Denis F. The three column spine and its significance in the classification of acute thoracolumbar spinal injuries. *Spine (Phila Pa 1976).* 1983;8:817-831.
- Magerl F, Aebi M, Gertzbein SD, Harms J, Nazarian S. A comprehensive classification of thoracic and lumbar injuries. *Eur Spine J.* 1994;3:184-201.
- Blauth M, Bastian L, Knop C, Lange U, Tusch G. Inter-observer reliability in the classification of thoraco-lumbar spinal injuries [in German]. *Orthopade.* 1999;28:662-681.
- Vaccaro AR, Lehman RA, Hurlbert RJ, et al. A new classification of thoracolumbar injuries: the importance of injury morphology, the integrity of the posterior ligamentous complex, and neurologic status. *Spine (Phila Pa 1976).* 2005;30:2325-2333.
- Vaccaro AR, Hulbert RJ, Patel AA, et al; Spine Trauma Study Group. The subaxial cervical spine injury classification system. *Spine (Phila Pa 1976).* 2007;32:2365-2374. doi:10.1097/BRS.0b013e3181557b92
- Vaccaro AR, Oner C, Kepler CK, et al. AOSpine thoracolumbar spine injury classification system. Fracture description, neurological status, and key modifiers. *Spine (Phila Pa 1976).* 2013;38:2028-2037. doi:10.1097/BRS.0b013e3182a8a381
- Joaquim AF, Ghizoni E, Tedeschi H, et al. Upper cervical injuries—a rational approach to guide surgical management. *J Spinal Cord Med.* 2014;37:139-151. doi:10.1179/2045772313Y.0000000158
- Anderson PA, Montesano PX. Morphology and treatment of occipital condyle fractures. *Spine (Phila Pa 1976).* 1988;13:731-736.
- Tuli S, Tator CH, Fehlings MG, Mackay M. Occipital condyle fractures. *Neurosurgery.* 1997;41:368-376.
- Traynelis VC, Marano GD, Dunker RO, Kaufman HH. Traumatic atlanto-occipital dislocation. Case report. *J Neurosurg.* 1986;65:863-870. doi:10.3171/jns.1986.65.6.0863
- Bellarbarba C, Mirza SK, West GA, et al. Diagnosis and treatment of craniocervical dislocation in a series of 17 consecutive survivors during an 8-year period. *J Neurosurg Spine.* 2006;4:429-440. doi:10.3171/spi.2006.4.6.429
- Anderson LD, D'Alonzo RT. Fractures of the odontoid process of the axis. *J Bone Joint Surg Am.* 1974;56:1663-1674.
- Effendi B, Roy D, Cornish B, Dussault RG, Laurin CA. Fractures of the ring of the axis. A classification based on the analysis of 131 cases. *J Bone Joint Surg Br.* 1981;63-B:319-327.
- Levine AM, Edwards CC. The management of traumatic spondylolisthesis of the axis. *J Bone Joint Surg Am.* 1985;67:217-226.
- Allen BL Jr, Ferguson RL, Lehmann TR, O'Brien RP. A mechanistic classification of closed, indirect fractures and dislocations of the lower cervical spine. *Spine (Phila Pa 1976).* 1982;7:1-27.
- Stone AT, Bransford RJ, Lee MJ, et al. Reliability of classification systems for subaxial cervical injuries. *Evid Based Spine Care J.* 2010;1:19-26. doi:10.1055/s-0030-1267064
- Harris JH, Edeiken-Monroe B, Kopaniky DR. A practical classification of acute cervical spine injuries. *Orthop Clin North Am.* 1986;17:15-30.
- Moore TA, Vaccaro AR, Anderson PA. Classification of lower cervical spine injuries. *Spine (Phila Pa 1976).* 2006;31(11 suppl):S37-S43. doi:10.1097/01.brs.0000217942.93428.f7
- Anderson PA, Moore TA, Davis KW, et al; Spinal Trauma Study Group. Cervical spine injury severity score. Assessment of reliability. *J Bone Jt Surg.* 2007;89:1057-1065. doi:10.2106/JBJS.F.00684
- Vaccaro AR, Koerner JD, Radcliff KE, et al. AOSpine subaxial cervical spine injury classification system. *Eur Spine J.* 2016;25:2173-2184. doi:10.1007/s00586-015-3831-3
- Schnake KJ, Schroeder GD, Vaccaro AR, Oner C. AOSpine classification systems (subaxial, thoracolumbar). *J Orthop Trauma.* 2017;31:S14-S23. doi:10.1097/BOT.0000000000000947
- Urrutia J, Zamora T, Campos M, et al. A comparative agreement evaluation of two subaxial cervical spine injury classification systems: the AOSpine and the Allen and Ferguson schemes. *Eur Spine J.* 2016;25:2185-2192. doi:10.1007/s00586-016-4498-0
- Joaquim AF, Rodrigues SA, Da Silva FS, et al. Is there an association with spino-pelvic relationships and clinical outcome of type A thoracic and lumbar fractures treated non-surgically? *Int J Spine Surg.* 2018;12:371-376. doi:10.14444/5043
- Kepler CK, Vaccaro AR, Koerner JD, et al. Reliability analysis of the AOSpine thoracolumbar spine injury classification system by a worldwide group of naïve spinal surgeons. *Eur Spine J.* 2016;25:1082-1086. doi:10.1007/s00586-015-3765-9
- Oner F, Ramos L, Simmermacher R, et al. Classification of thoracic and lumbar spine fractures: problems of reproducibility. A study of 53 patients using CT and MRI. *Eur Spine J.* 2002;11:235-245. doi:10.1007/s00586-001-0364-8
- Rihn JA, Yang N, Fisher C, et al. Using magnetic resonance imaging to accurately assess injury to the posterior ligamentous complex of the spine: a prospective comparison of the surgeon and radiologist. *J Neurosurg Spine.* 2010;12:391-396. doi:10.3171/2009.10.SPINE08742

31. Schroeder GD, Kepler CK, Koerner JD, et al. A worldwide analysis of the reliability and perceived importance of an injury to the posterior ligamentous complex in AO type a fractures. *Glob Spine J*. 2015;5:378-382. doi:10.1055/s-0035-1549034
32. Mehta S, Auerbach JD, Born CT, Chin KR. Sacral fractures. *J Am Acad Orthop Surg*. 2006;14:656-665.
33. Letournel E. Surgical fixation of displaced pelvic fractures and dislocations of the symphysis pubis (excluding acetabular fractures) [in French]. *Rev Chir Orthop Reparatrice Appar Mot*. 1981; 67:771-782.
34. Tile M. Pelvic ring fractures: should they be fixed? *J Bone Joint Surg Br*. 1988;70:1-12.
35. Isler B. Lumbosacral lesions associated with pelvic ring injuries. *J Orthop Trauma*. 1990;4:1-6.
36. Denis F, Davis S, Comfort T. Sacral fractures: an important problem. Retrospective analysis of 236 cases. *Clin Orthop Relat Res*. 1988;227:67-81.
37. Roy-Camille R, Saillant G, Gagna G, Mazel C. Transverse fracture of the upper sacrum. Suicidal jumper's fracture. *Spine (Phila Pa 1976)*. 1985;10:838-845.
38. Bishop JA, Dangelmajer S, Corcoran-Schwartz I, Gardner MJ, Routt MLC Jr, Castillo TN. Bilateral sacral ala fractures are strongly associated with lumbopelvic instability. *J Orthop Trauma*. 2017;31:636-639. doi:10.1097/BOT.0000000000000972