

# Corrective osteotomy with retrograde Fassier-Duval nail in an osteogenesis imperfecta patient with bilateral genu valgum

## A case report

Tsung-Yu Lin, MD, Chen-Yu Yang, MD, Shih-Chia Liu, MD\*

### Abstract

**Rationale:** The treatment of osteogenesis imperfecta (OI) requires a multidisciplinary approach to maximize function and reduce fracture incidence. The aim of this case report was to discuss an alternative surgical approach to stabilize a corrective osteotomy using the Fassier Duval (FD) system in an OI patient.

**Patient concerns:** A 20-year-old OI woman presented with left thigh pain, gait disturbance, and bilateral genu valgus deformities.

**Diagnoses:** Physical examination and standing radiographs revealed bilateral genu valgum with previous fixation implants in the femoral and the left tibia.

**Interventions:** Staged surgery was performed. A previous Ender pin was removed from the left femur, and a FD nail was inserted in a retrograde fashion. An intercondylar fracture was encountered while inserting the female rod in the distal left femur. After removal of a previous Rush pin from the right femur, several complications were also encountered during FD nailing of the right femur. The tip threads of the FD male nail could not achieve adequate anchorage in the region of the greater trochanter. To prevent male nail dropping, a horizontal stop Kirschner pin was inserted close to the distal end of the female nail.

**Outcome:** Despite perioperative problems such as rod dropping and occurrence of an intercondylar fracture of the left distal femur, bilateral retrograde nailing using the FD system was successful. An accurate entry portal is important when performing retrograde rodding. In addition, reaming the portal to a larger diameter in order to accommodate the large head of the female nail can prevent intraoperative intercondylar split, especially when combined with an osteotomy at the distal femur.

**Lessons:** Selection of the proper surgical technique is dependent on both the surgeon's experience and the condition of the patient. Although not an optimal device, a FD nail can be used as an IM nail for corrective osteotomy at the distal femur in an adult OI patient with a small femoral IM canal.

**Abbreviations:** CRIF = closed reduction and internal fixation, FD = Fassier-Duval, IM = intramedullary, OI = osteogenesis imperfecta, PMMA = polymethylmethacrylate.

**Keywords:** Fassier-Duval, osteogenesis imperfecta, osteotomy, retrograde, telescopic rod

## 1. Introduction

The treatment of osteogenesis imperfecta (OI) requires a multidisciplinary team approach to maximize patient function and comfort, and to decrease fracture incidence. Intramedullary (IM) rodding is the procedure of choice to support fragile bones, whereas plates create a stress raiser effect and should not be used.<sup>[1]</sup>

The Fassier-Duval (FD) system (Pega Medical, Autoroute Chomedey, Laval, Quebec CANADA H7W 5J8) provides a versatile method of IM stabilization through a single entry point. The aim of this case report was to discuss an alternative surgical approach to stabilize a corrective osteotomy using the FD system of retrograde nailing in an OI patient.

## 2. Case summary

A 20-year-old Taiwanese woman with a known history of OI type IVB presented with left thigh pain, gait disturbance, and bilateral genu valgus deformities. The patient had been treated with bisphosphonate therapy since October 2000. Her most recent surgical history was notable for closed reduction and internal fixation (CRIF) of a left tibial shaft fracture in 2007, scoliosis correction in 2009, left femoral shaft fracture with Ender nail fixation in 2010, and right femoral shaft fracture treated with Rush pin fixation in 2011. Since she denied any recent fractures, her left thigh pain was felt to be secondary to a delayed union of the left femoral shaft fracture (Fig. 1).

Physical examination revealed bilateral genu valgum with genu recurvatum with full passive range of motion, no tenderness of the joints, and no joint effusion. The patient was 52 inches in height and weighed 78 pounds. Both knees were moderately stable to varus, valgus, anterior, and posterior stress testing, and

Editor: Johannes Mayr.

The authors report no conflicts of interest.

Department of Orthopedics, Mackay Memorial Hospital Medical Center, New Taipei City, Taiwan, R.O.C.

\* Correspondence: Shih-Chia Liu, Department of Orthopedics, Mackay Memorial Hospital Medical Center, No. 45, Minsheng Rd, Tamsui Dist., New Taipei City 251, Taiwan, R.O.C. (e-mail: jasonscliu649@gmail.com).

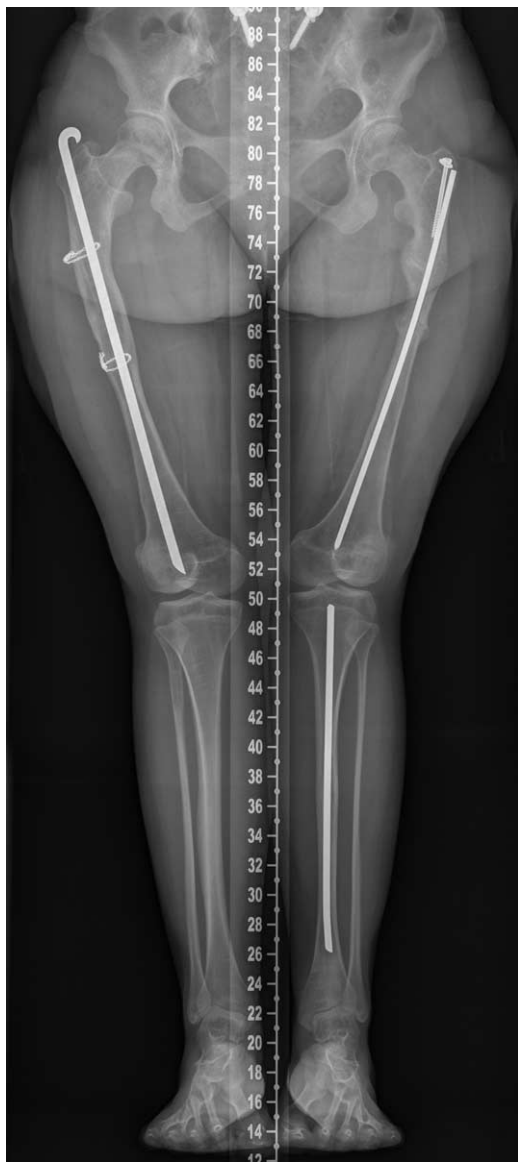Copyright © 2017 the Author(s). Published by Wolters Kluwer Health, Inc. This is an open access article distributed under the terms of the Creative Commons Attribution-Non Commercial-No Derivatives License 4.0 (CCBY-NC-ND), where it is permissible to download and share the work provided it is properly cited. The work cannot be changed in any way or used commercially without permission from the journal.

Medicine (2017) 96:47(e8459)

Received: 22 January 2017 / Received in final form: 28 September 2017 /

Accepted: 29 September 2017

<http://dx.doi.org/10.1097/MD.00000000000008459>

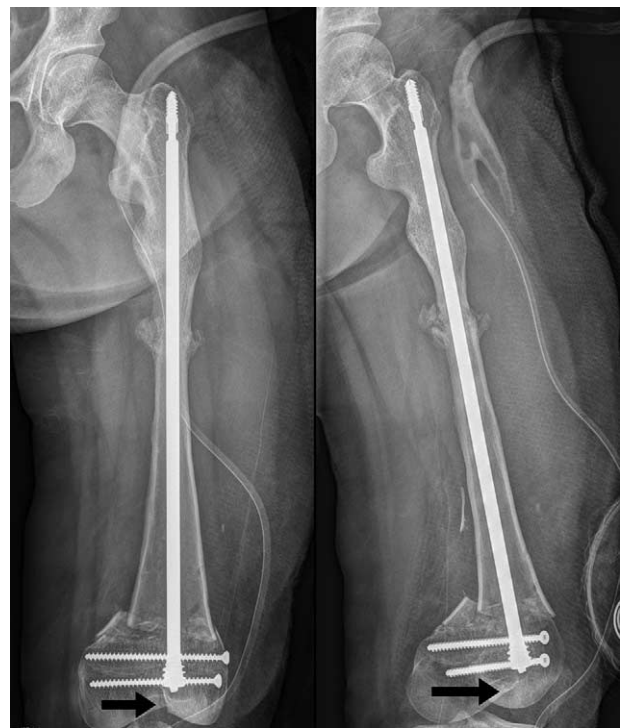

**Figure 1.** Scanography showed genu valgum and small bilateral femoral canal.

she walked with a waddling gait. The patient's bone survey revealed loss of kyphosis of the thoracic spine with left pelvic tilting, cubitus varus over the left elbow, and a neglect fatigue fracture with healing over the base of the fifth metatarsal bone of the right foot. Her neurovascular examination was normal. Significant findings other than the musculoskeletal system included blue sclera and severe heat or sweat rash over the skin of the trunk.

Standing radiographs of both legs revealed bilateral genu valgum with previous fixation implants in the femora and the left tibia. Delayed union over the shaft of left proximal femur was evident. Palpation of the left thigh at the site of the delayed union elicited pain. The narrowest diameter of medullary canal of the left femur was <7 mm (Fig. 1).

Because this report just reviewed previous data and did not involve any human trials, there is no need to conduct special ethic review, and the ethical approval is not necessary. Informed consent was provided by the patient for the publication of the case report.



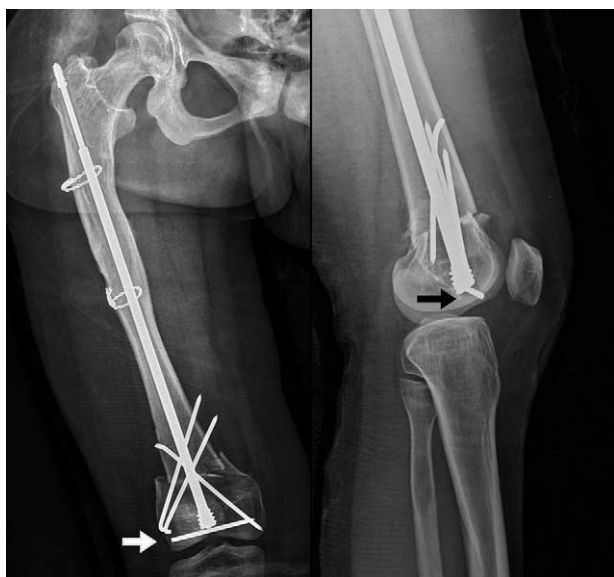**Figure 2.** Distal left femoral condylar fracture while inserting the female rod.

### 3. Surgical techniques and treatment course

Because the smallest femoral interlocking nail available at our institution was 9 mm, the FD nail became the only option for fracture stabilization in this patient with a limited medullary canal diameter.

The FD system is usually inserted in an antegrade fashion. However, to secure a corrective osteotomy for genu valgum in the distal femur of this patient, the nail was inserted in a retrograde fashion from the knee. Since she had left thigh pain, a staged operation was performed which initially focused on the left femur. The previous left femoral implant was removed through a small incision at the greater trochanter. After lateral closed wedge osteotomy, Kirschner pins were used for temporal fixation. A lateral parapatellar curvilinear incision was made to explore the knee joint and extended from the left distal femur to a few centimeters proximal to the tibial tubercle. The medullary canal was accessed by a portal at the intercondylar notch, and the insertion of the male rod was guided using the Pega Medical instructions but in a retrograde direction. A 5.6 mm male rod was pushed into the femoral canal from the intercondylar notch. However, the threads at the end of the male rod could not find adequate anchorage at the tip of the greater trochanter. A female hollow nail was then screwed into the medullary canal until the threaded portion of the female head could be driven into the femoral condyle. However, while driving the large female head into the entry hole, a split fracture of the intercondylar area of the distal femur occurred. To resolve this complication, 2 cancellous screws were used to fix the fracture (Fig. 2). Postoperatively, a posterior long-leg splint with lateral extension to the greater trochanter was applied to reinforce the osteotomy and the fractures.

With the experience learned from the left femur, 2 measures were taken during corrective surgery on the right femur 1 week

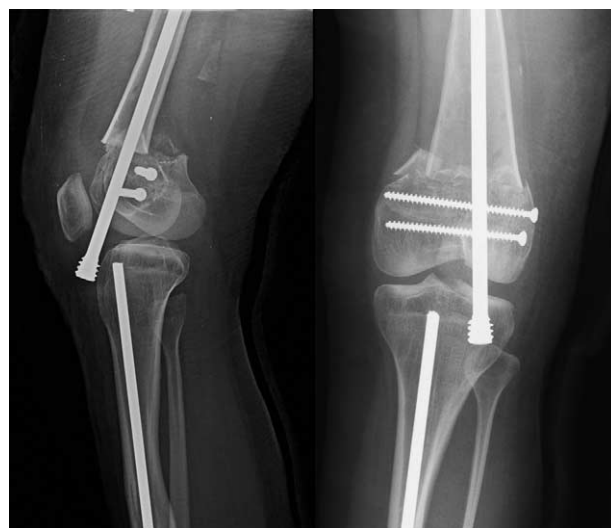

**Figure 3.** Stop K-pin used to prevent dropping of the male rod in right femur.

later. First, an optimal entry portal was created in the center of the intercondylar notch approximately 1 cm anterior to the origin of posterior cruciate ligament, because the portal at the left distal femur was too anterior. The second measure taken was to ream the entry hole to a larger diameter to accommodate the large head of the female nail to prevent a split fracture of the femoral condyles. However, due to the pre-existing canal produced by the previously inserted Rush pin, the tip threads of the FD male nail could not find adequate anchorage at the greater trochanter of the right femur. To restrain the male nail from dropping down, a horizontal stop Kirschner pin was inserted close to the distal end of the female nail. To augment the stability of the corrective osteotomy, 3 crossing Kirschner pins were inserted at the right distal femur (Fig. 3). Postoperatively, a long-leg splint was applied on the right side, and the patient was discharged from the hospital 2 days after the second operation.

Unfortunately, left knee pain was encountered 1 week after surgery. The radiograph of the left knee showed downward migration of the female nail into the left knee joint, most likely due to the split fracture at the distal femoral condyles (Fig. 4). Revision surgery was performed using a horizontal stop screw to prevent the downward protrusion of the female nail and to augment the fixation of the split fracture; 2 crossing Kirschner pins were also used to secure the position of the osteotomy. A new long-leg splint was applied.

The patient was allowed nonweight-bearing ambulation until approximately one and a half months after the operations when radiographs revealed healing callus formation at the osteotomies bilaterally. The splints at both sides were subsequently removed. Three months after surgery, follow-up radiographs revealed additional healing callus at the osteotomy sites (Fig. 5) and the patient was allowed full weight-bearing during indoor ambulation which she achieved without discomfort. The genu valgum deformities were corrected, the left thigh pain subsided, and the patient was satisfied with the procedures.



**Figure 4.** Downward protrusion of the left female nail 2 weeks after surgery.

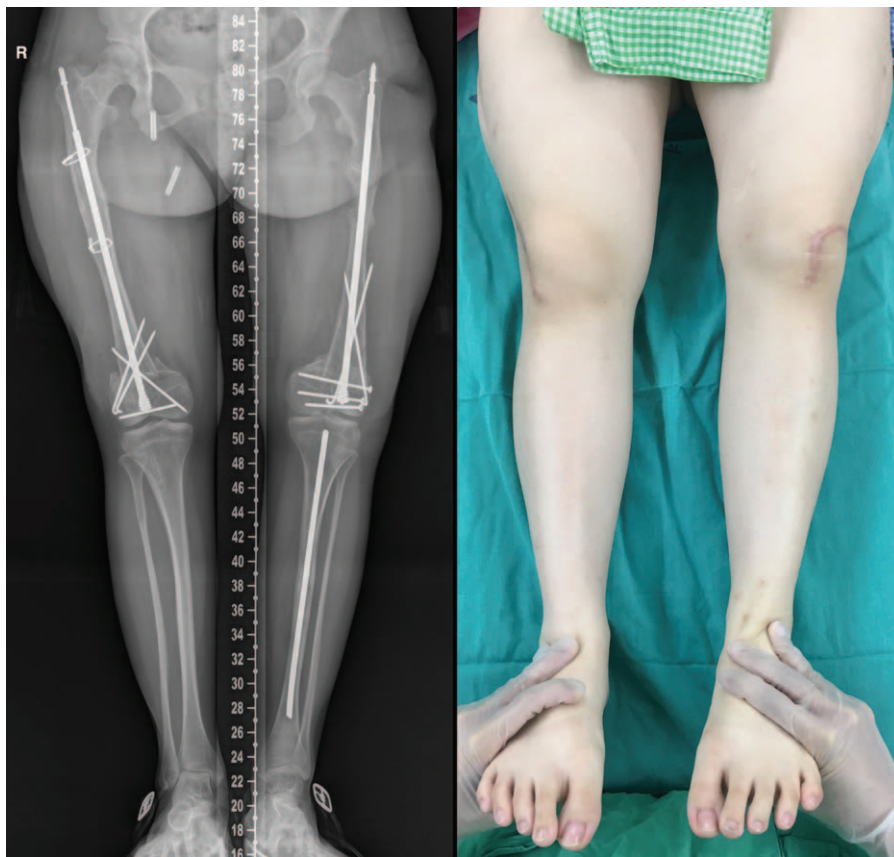
#### 4. Discussion

Patients with OI carry a significant burden of multiple fractures and bony deformities. Therefore, surgery in OI patients remains a particular challenge. The most successful surgical method of treating the deformities associated with OI is based on the work of Sofield and Millar.<sup>[2,3]</sup> They used a method comprised of multiple osteotomies, realignment of fragments, and intramedullary nail fixation for long bone fractures.<sup>[2,3]</sup>

The FD nail has several advantages including a decrease in soft tissue injury, decreased blood loss, and insertion without the need for knee arthrotomy.<sup>[4,5]</sup> Justification for the use of the FD system in our patient included lack of an alternative device such as a small rigid or interlocking IM nail. We chose nail insertion in a retrograde direction to secure proper fixation for a corrective osteotomy at the distal femur. Although several perioperative complications were encountered, included rod dropping and rod migration, an intercondylar fracture of the distal femur, and the necessity of supplementary fixations for osteoporotic bone at the osteotomy sites, the results still support the use of retrograde nailing using the FD system in select cases. Based on our experience, an accurate entry portal is important for optimal placement of the implant to produce good corrective alignment in retrograde rodding. In addition, reaming the portal to a larger diameter to accommodate the large head of the female nail can prevent intraoperative intercondylar split, especially when combined with a supracondylar osteotomy at the distal femur.

As there is no relevant article concerning retrograde nailing using an FD nail, we have shared our experience with potential complications which may arise when using the FD nail as an alternative device. Azzam et al demonstrated that revisions were required in approximately 53% of patients who received FD nail surgery. Common reasons for femoral FD nail revision included femoral fracture, bending of the rod, and proximal rod migration.<sup>[6,7]</sup>

Birke et al also noted a 13% reoperation rate for proximal rod migration when using the FD rod system.<sup>[8-10]</sup> Whether using retrograde or antegrade nailing, rod migration and distal epiphyseal disengagement still remain thorny problems. In our



**Figure 5.** Three months after surgery.

case, downward displacement of the rod was encountered both intraoperatively and postoperatively, and was successfully managed by insertion of a horizontal pin or screw.

Rod migration constitutes a frequently described problem. Cho et al<sup>[11]</sup> devised a telescopic rod system to provide effective anchorage by adding the interlocking pin at the distal epiphysis. However, proximal migration still occurred in some cases.<sup>[11]</sup> Mansour et al<sup>[12]</sup> performed a biomechanical experiment to evaluate the pullout strength of distal fixation using the telescoping rod, with and without synthetic calcium phosphate or polymethylmethacrylate (PMMA) augmentation. All augmented constructs improved pullout strength by at least 400% compared with the controls. In addition, bioabsorbable cement may be less detrimental to the physis if pullout still occurs.<sup>[12]</sup>

The IM rodding has been the mainstay of long-bone stabilization in OI. However, in some cases, IM rodding cannot provide adequate fixation due to lack of rotational control and the thin diameter of long bones. Unicortical locking plate fixation effectively supplements IM rod fixation in select cases of OI.<sup>[13,14]</sup> In OI cases similar to ours, it may provide an alternative solution to the use of the FD nail when correcting genu valgum. However, the cost of a locking plate was not included in our national health insurance; thus, Kirschner pins were chosen for fixation in our patient.

## 5. Conclusions

Recent surgical advances have improved the safety, function, and comfort when treating OI patients. The selection of a proper

surgical technique is dependent on the surgeon's experience and the individual patient's situation. Although not an optimal device, the Fassier-Duval nail can be used as an IM nail for corrective osteotomy at the distal femur in adult OI patients with small femoral canals. Accurate entry point selection is important when performing retrograde rodding. A stop screw or pin may be necessary to prevent rod dropping when using the FD nail as a fixation device during revision surgery.

## References

- [1] Sabharwal S. *Pediatric Lower Limb Deformities: Principles and techniques of management*. 1st ed. Springer International Publishing Switzerland, New York, NY:2016.
- [2] Canale ST, Beaty JH. *Campbell's Operative Orthopaedics*. 12th ed Elsevier Mosby, Philadelphia, PA:2013.
- [3] Roberts TT, Cepela DJ, Uhl RL, et al. Orthopaedic Considerations for the adult with osteogenesis imperfecta. *J Am Acad Orthop Surg* 2016;24:298–308.
- [4] Esposito P, Plotkin H. Surgical treatment of osteogenesis imperfecta: current concepts. *Curr Opin Pediatr* 2008;20:52–7.
- [5] Sterian A, Balanescu R, Barbilian A, et al. Early telescopic rod osteosynthesis for osteogenesis imperfecta patients. *J Med Life* 2015; 8:544–7.
- [6] Azzam KA, Rush ET, Burke BR, et al. Mid-term results of femoral and tibial osteotomies and Fassier-Duval nailing in children with osteogenesis imperfecta. *J Pediatr Orthop J Pediatr Orthop* 2016;[Epub ahead of print].
- [7] Lee RJ, Paloski MD, Sponseller PD, et al. Bent Telescopic rods in patients with osteogenesis imperfecta. *J Pediatr Orthop* 2016;36:656–60.
- [8] Birke O, Davies N, Latimer M, et al. Experience with the Fassier-Duval telescopic rod: first 24 consecutive cases with a minimum of 1-year follow-up. *J Pediatr Orthop* 2011;31:458–64.

- [9] Sulko J, Oberc A. Advantages and complications following Fassier-Duval intramedullary rodding in children. *Pilot Study Ortop Traumatol Rehabil* 2015;17:523–30.
- [10] Lee K, Park MS, Yoo WJ, et al. Proximal migration of femoral telescopic rod in children with osteogenesis imperfecta. *J Pediatr Orthop* 2015;35:178–84.
- [11] Cho TJ, Choi IH, Chung CY, et al. Interlocking telescopic rod for patients with osteogenesis imperfecta. *J Bone Joint Surg Am* 2007;89:1028–35.
- [12] Mansour A3rd, Barsi J, Baldini T, et al. Effect of different distal fixation augmentation methods on the pullout strength of Fassier-Duval telescoping rods. *Orthopedics* 2016;39:e328–32.
- [13] Cho TJ, Lee K, Oh CW, et al. Locking plate placement with unicortical screw fixation adjunctive to intramedullary rodding in long bones of patients with osteogenesis imperfecta. *J Bone Joint Surg Am* 2015;97:733–7.
- [14] Franzone JM, Kruse RW. Intramedullary nailing with supplemental plate and screw fixation of long bones of patients with osteogenesis imperfecta: operative technique and preliminary results. *J Pediatr Orthop B* 2016; [Epub ahead of print].