

## Possible protective effects of crocin on destructive side effects of cyclophosphamide in mice ovarian tissue: Evaluation of histomorphometrical and biochemical changes

Fahimeh Khanmohammadi, Rasoul Shahrooz\*, Abbas Ahmadi, Mazdak Razi

Department of Basic Sciences, Faculty of Veterinary Medicine, Urmia University, Urmia, Iran.

Article Info	Abstract
<b>Article history:</b> Received: 02 February 2019 Accepted: 06 July 2019 Available online: 15 June 2021	<p>One of the side effects of cyclophosphamide (CP) is low fertility. In this study, we investigated the protective role of crocin (Cr) against CP chemotherapy-induced changes in ovarian tissue. In the current study, we treated 15 female mice aged 6-8 weeks old for 21 days. The mice were distributed into three groups including control received normal saline (0.10 mL; IP), CP or sham-control group (CP once a week, 15.00 mg kg<sup>-1</sup>; IP) and experimental (CP + Cr) group received CP along with Cr (200 mg kg<sup>-1</sup> daily; IP). After completing the procedure, levels of total anti-oxidant capacity (TAC), superoxide dismutase (SOD) and sex hormones in serum as well as malondialdehyde (MDA) in the left ovarian tissue were measured. The right ovaries were used for histological and morphological tests. The obtained data were statistically analyzed by SPSS software using ANOVA and Tukey follow-up studies. Results showed that in the CP group a significant decrease was observed in ovarian follicles, the number of corpus luteum, levels of TAC, SOD and sex hormones; while, there was a significant increase in the number of atretic follicles and mast cells and level of MDA compared to control group. Administration of Cr along with CP caused a significant ameliorative effect on the studied parameters. In conclusion, the Cr could significantly decrease the side effects caused by CP chemotherapy in mice ovarian tissue.</p>
<b>Keywords:</b> Crocine Cyclophosphamide Mice Ovary	

© 2021 Urmia University. All rights reserved.

### Introduction

Chemotherapy has been utilized widely in treating cancers, autoimmune diseases and oncological disorders. Different medicines and methods are used to treat cancer; one of them is cyclophosphamide (CP), an important and effective drug to treat cancer.<sup>1</sup> Despite its role in treating cancers, it causes some disorders in ovaries.<sup>2</sup> Producing oocytes is the most important function of ovaries. In mammals, a very limited number of oocytes is produced, because in mammals including human these cells proliferate only in the fetal period and after birth; a fixed and limited number of follicles is saved in ovaries that their removal will lead to early senescence of ovaries.<sup>3</sup> It has been suggested that treating cancer with CP in female patients causes defects in ovarian functions.<sup>1</sup> Alkylating agents including CP cause genetic mutations, chromosomes fragmentations and aneuploidy in somatic cells.<sup>4</sup> Furthermore, CP damages primordial follicles due to

depletion in follicle reserve having a negative effect on genital system causing infertility and early menopause in females.<sup>5</sup>

Oxidative stress is generated when an imbalance occurs between the production of oxygen free radicals and cells defensive anti-oxidant capacity. This leads to the production of different free radicals including superoxide anion (O<sup>2-</sup>), hydroxyl radical (OH) and non-radical derivatives of oxygen like hydrogen peroxide (H<sub>2</sub>O<sub>2</sub>). These free radicals are highly unstable and react quickly with biological molecules in an unspecific pattern. This leads to the development of different cellular damages including plasma membrane peroxidation, amino acids and nucleic acids oxidation, apoptosis and necrosis.<sup>6</sup> Since chemotherapy medicines act as oxidative stress generating factors in the body and increase the production rate of free radicals, it seems that CP exerts its effects on body organs and genital system by this mechanism and causes a reduction in fertility potential.

### \*Correspondence:

Rasoul Shahrooz. DVM, DVSc  
Department of Basic Sciences, Faculty of Veterinary Medicine, Urmia University, Urmia, Iran  
E-mail: r.sharooze@urmia.ac.ir



This work is licensed under a Creative Commons Attribution-NonCommercial 4.0 International License which allows users to read, copy, distribute and make derivative works for non-commercial purposes from the material, as long as the author of the original work is cited properly.

Major active chemicals in saffron are crocetin, crocin (Cr) and safranal possessing free radicals defeating property.<sup>7</sup> These chemicals may be used to treat diseases associated with nervous degenerations and memory losses.<sup>8</sup> Saffron extract shows pharmacological activities including anti-tumors,<sup>9,10</sup> blood fat levels reduction, anti-inflammatory,<sup>11</sup> anti-convulsion<sup>12</sup> and anti-depressant effects in animals<sup>13</sup> and <sup>14</sup> antitussive and expectorant effects in human.<sup>15</sup>

Because no study has been done regarding Cr (as an anti-oxidant factor) activity to decrease CP-induced oxidative stress in ovarian tissue focusing on follicular development and atresia, we investigated the protective effect of Cr on development and atresia of ovarian follicles in mice treated with CP.

## Materials and Methods

**Animals.** Fifteen fertile female mice aged 6-8 weeks (20.00 - 25.00 g) were distributed randomly into three groups and treated for 21 days. All the ethical issues related to laboratory animals in Faculty of Veterinary Medicine, Urmia University were carefully observed (Ethic Number: AECVU-189-2019) and the animals were kept in standard conditions of temperature ( $22.00 \pm 2.00$  °C), humidity (30.00%-60.00%) and light/dark cycle (14/10) and fed freely.

**Groups and administrations.** The control group received a daily dose of normal saline (0.10 mL; IP), the sham-control (CP) group received CP (15.00 mg kg<sup>-1</sup> per week; IP, Baxter, Halle, Germany)<sup>16</sup> and experimental (CP + Cr) group received CP in a similar route as the sham-control group along with Cr (200 mg kg<sup>-1</sup> daily; IP, Sigma-Aldrich, St. Louis, USA).<sup>17</sup>

**Sampling.** After completing treatment period (21 days),<sup>2</sup> blood and tissue samples were taken. Ketamine (25.00 mg kg<sup>-1</sup>; IP, Alfasan, Utrecht, The Netherlands) was used for partial anesthesia for blood sampling through the jugular vein and animals euthanasia was performed by ketamine over-dose (75.00 mg kg<sup>-1</sup>; IP). Blood serum was separated from samples after centrifugation in 3,000 *g* for 5 min. Then, the serum was poured in sterile micro-tubes and kept in -70.00 °C until enzymatic and hormonal tests. Subsequently, the right ovaries were taken for histological investigations and kept in the 10.00% formalin buffer solution. The left ovaries were stored in -70.00 °C for biochemical tests.

**Hormonal assays.** For evaluating of LH and FSH levels, ELISA technique was utilized with specific kits including Ferigenix-LH-EASIA (Biosource, Nivelles, Belgium) and Ferigenix-FSH-EASIA (Biosource), respectively. Measurement of estrogen levels in serum was done by a radioimmunoassay technique using specific kit (Biogenesis, Poole, UK). The results were reported as picogram (pg).

**Histological studies.** For histomorphometrical studies, the samples were fixed in 10.00% formalin buffer solution for 48 hr and undertaken tissue passage and molding; then, they were serially sectioned. Finally, tissue sections were stained by Hematoxylin and Eosin<sup>18</sup> and evaluated for ovarian follicular development. A histological study was fulfilled by follicles appearance and mast cells distribution (by toluidine blue staining) analyses. Morphometrical studies of ovaries were done by counting normal and atretic follicles in different growth stages as well as corpus luteum.

**Biochemical analyses.** Serum samples stored at -70.00 °C were used for total anti-oxidant capacity (TAC) and superoxide dismutase (SOD) measurements. Staining technique of Randox Laboratories Ltd. (Crumlin, UK) using Ransod kit was applied for evaluating SOD levels. In addition, Benzie method was applied for measuring TAC.<sup>19</sup> Lipid peroxidation level was measured by the amount of malondialdehyde (MDA) produced in ovarian tissue through reaction of thiobarbituric acid.<sup>20</sup> The MDA was calculated as nanomole per mg proteins in samples.<sup>21</sup> The proteins were evaluated based on Lowry's method as mg mL<sup>-1</sup>.<sup>22</sup>

**Statistical analysis.** The SPSS (version 18.0; IBM Corp., Armonk, USA) was applied for data analysis and one-way ANOVA and Tukey post hoc test were used. All data were stated as mean  $\pm$  SEM and the  $p < 0.05$  was considered as significant value.

## Results

**Crocins led to ovarian follicular development enhancement in CP-treated mice.** Results of the current study suggested that ovarian follicular reserve of CP-treated mice underwent a significant decrease compared to control group; while, Cr could retain the primary follicles population; so, the average number of the follicles showed a significant difference compared to sham-control group ( $p < 0.05$ ). Development of primary, secondary, tertiary and Graafian follicles as well as the number of corpus luteum in CP group (sham-control) showed a significant decrease. However, in the experimental group, Cr treatment led to all these parameters elevation versus sham-control group ( $p < 0.05$ ), (Table 1 and Fig. 1).

**Crocins prevented CP-induced follicular atresia.** Morphometrical findings regarding atretic follicles suggested that administration of CP in sham-control group leads to a significant increase in the number of reserved atretic (primary) follicles in comparison with the control group; but, Cr supplementation in test group prevented atresia in reserved primary follicles population ( $p < 0.05$ ). Furthermore, administration of Cr caused a significant reduction in the average number of growing pre-antral atretic follicles compared to sham-control group ( $p < 0.05$ ). The average number of atretic antral follicles showed

a significant increase following CP administration compared to the sham-control group; while, administration of Cr caused atretic follicles reduction compared to the sham-control group; but, this reduction was not significant (Table 1 and Fig. 1).

**Crocin increased serum levels of estrogen, LH and FSH.** Test results of serum hormones analyses showed that CP reduced sex hormones (estrogen, FSH and LH) levels compared to control group; but, Cr could rise these parameters significantly compared to sham-control group ( $p < 0.05$ ), (Fig. 2). The Cr administration led to an increase in TAC and SOD levels; while, it caused a decrease in MDA levels. Results of TAC and SOD measurements suggested a significant decrease in sham-control group compared to control group. Giving Cr caused TAC and SOD levels increase up to the level of control group or even higher than that; so, the difference with the sham group was significant ( $p < 0.05$ ). Ovarian tissue level of MDA showed a significant increase in the CP group versus control group and Cr as an anti-oxidant agent could lower it compared to CP group ( $p < 0.05$ ), (Fig. 2).

**Crocin reduced the mast cells distribution in ovarian medulla connective tissue.** The findings about ovarian mast cells distribution in CP group revealed a significant increase compared to the control group; however, administration of Cr led to a significant drop in mast cells distribution compared to sham group ( $p < 0.05$ ), (Table 1 and Fig. 3).

## Discussion

This study was performed to modify side effects of oxidative stress exerted by CP in the process of ovarian follicular development using Cr, an effective ingredients in the saffron extract. In this work, by generating oxidative stress in female genital system through CP administration, it has been observed a significant reduction in ovarian follicles, corpus luteum and sex hormones, TAC and SOD of serum as well as a significant increase in atretic follicles, mast cells and MDA levels in ovarian tissue of sham-control group compared to control group.

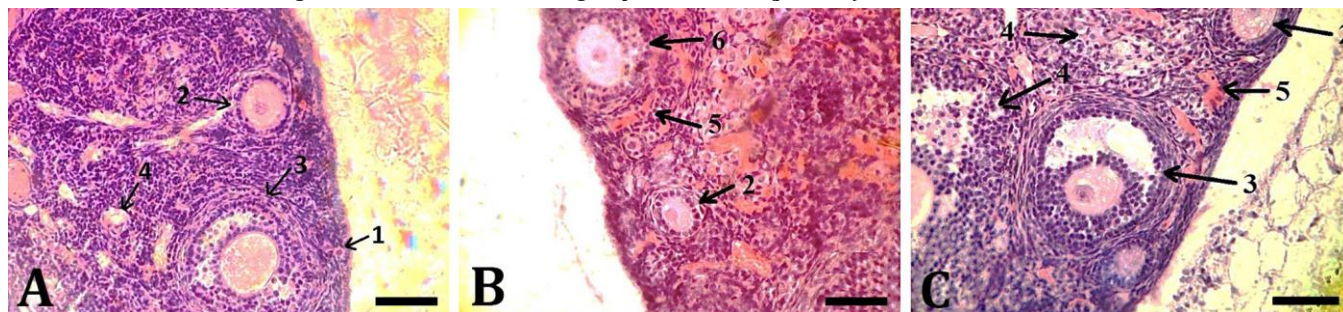
Alkylating agents including CP lead to genetic mutations, chromosomal fragmentations and aneuploidy in somatic cells.<sup>4</sup> In addition, CP causes destructions in primordial follicles due to a reduction in follicular stocks negatively influencing on the genital system leading to infertility and early menopause in females and cellular cycle disruption affecting resting oocytes.<sup>23</sup> Histological studies suggested that following CP administration, a follicular atresia increased in the animals. However, Cr supplementation led to a significant decrease in follicular atresia of the experimental group.

Earlier studies have suggested that CP by interrupting pituitary-gonadal axis may interfere with the procedure of gonadotrophic and gonadal hormones production.<sup>24</sup> Considering the reduction of LH and FSH hormones levels in CP-treated mice, it can be concluded that in addition

**Table 1.** Average number of right ovarian normal and atretic follicles, corpus luteum and mast cells in studied groups (mean  $\pm$  SEM).

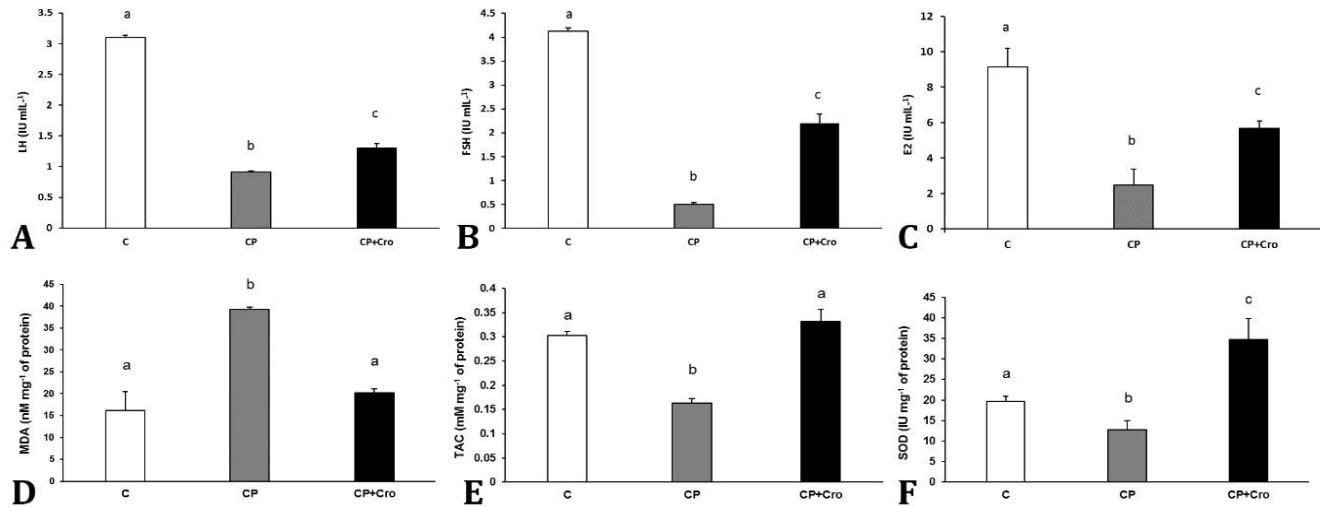
Parameters		Control	Cyclophosphamide	Cyclophosphamide+Crocin
Primordial follicles	Normal	270.60 $\pm$ 3.41 <sup>a</sup>	229.60 $\pm$ 3.33 <sup>b</sup>	246.00 $\pm$ 2.12 <sup>c</sup>
	Atretic	197.20 $\pm$ 3.87 <sup>a</sup>	327.60 $\pm$ 3.18 <sup>b</sup>	187.00 $\pm$ 2.09 <sup>c</sup>
Primary follicles	Normal	18.20 $\pm$ 0.58 <sup>a</sup>	6.20 $\pm$ 0.58 <sup>b</sup>	10.80 $\pm$ 0.86 <sup>c</sup>
	Atretic	29.80 $\pm$ 0.66 <sup>a</sup>	45.40 $\pm$ 1.43 <sup>b</sup>	19.00 $\pm$ 0.54 <sup>c</sup>
Secondary follicles	Normal	14.40 $\pm$ 0.74 <sup>a</sup>	2.20 $\pm$ 0.37 <sup>b</sup>	11.60 $\pm$ 0.50 <sup>c</sup>
	Atretic	78.80 $\pm$ 1.35 <sup>a</sup>	84.80 $\pm$ 1.85 <sup>b</sup>	64.40 $\pm$ 1.28 <sup>c</sup>
Tertiary follicles	Normal	7.00 $\pm$ 0.44 <sup>a</sup>	2.20 $\pm$ 0.20 <sup>b</sup>	6.60 $\pm$ 1.28 <sup>c</sup>
	Atretic	25.20 $\pm$ 1.39 <sup>a</sup>	45.00 $\pm$ 1.30 <sup>b</sup>	44.60 $\pm$ 0.92 <sup>b</sup>
Graffian follicles	Normal	8.60 $\pm$ 0.60 <sup>a</sup>	4.60 $\pm$ 0.60 <sup>b</sup>	6.00 $\pm$ 0.50 <sup>c</sup>
	Atretic	0.60 $\pm$ 0.24 <sup>a</sup>	1.80 $\pm$ 0.37 <sup>b</sup>	1.60 $\pm$ 0.24 <sup>b</sup>
Corpus luteum		16.00 $\pm$ 1.00 <sup>a</sup>	4.00 $\pm$ 0.57 <sup>b</sup>	6.66 $\pm$ 0.88 <sup>c</sup>
Mast cells		3.80 $\pm$ 0.61 <sup>a</sup>	9.70 $\pm$ 0.42 <sup>b</sup>	2.40 $\pm$ 0.17 <sup>a</sup>

<sup>abc</sup> Different letters indicate significant difference between groups in each row ( $p < 0.05$ ).

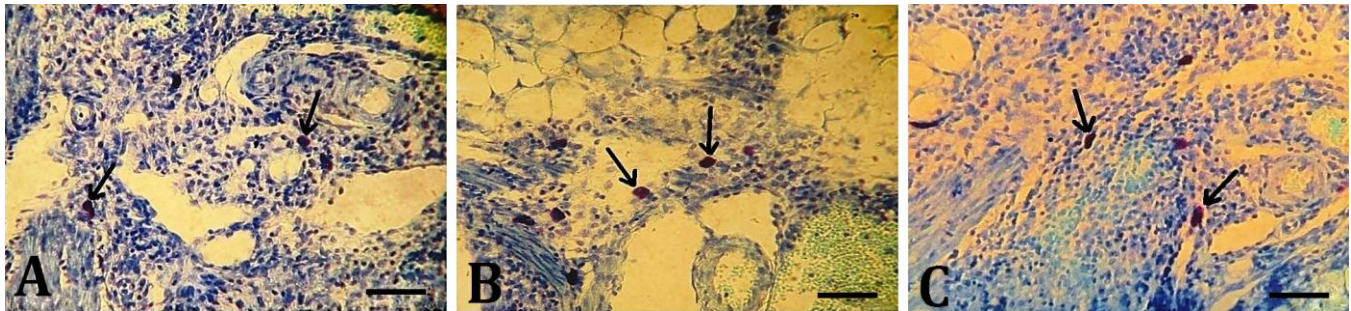


**Fig. 1.** Histological view of ovary in the A) Control, B) Cyclophosphamide and C) cyclophosphamide and crocin treated groups. Note the hyperemia of ovarian tissue in CP group. 1: Primordial follicle; 2: Primary follicle; 3: Tertiary follicle; 4: Atretic follicle; 5: Blood vessel; 6: Secondary follicle, (H & E, Scale bars = 80.00  $\mu$ m).





**Fig. 2.** Mean levels of sex hormones including **A) LH**, **B) FSH** and **C) Estrogen (E2)**, and oxidative and anti-oxidant factors including **D) Malondialdehyde (MDA)**, **E) Total anti-oxidant capacity (TAC)** and **F) Superoxide dismutase (SOD)** in studied groups. Different letters indicate significant difference between groups ( $p < 0.05$ ). C: Control; CP: Cyclophosphamide; Cro: Crocin.



**Fig. 3.** Mast cells distribution (arrows) in the ovary of **A) Control**, **B) Cyclophosphamide** and **C) Cyclophosphamide and crocin** treated groups, (Toluidine blue staining, Scale bars = 80.00  $\mu\text{m}$ ).

to cytotoxic effects of CP imposed to ovarian tissue, it is able to interfere with endocrine system and damage follicular growth procedure.

Oxidative stress occurs due to increase of free radicals levels in the body; so that, it exceeds the anti-oxidative defense capacity of the body.<sup>25</sup> Observations indicated that the toxic effects of CP on female genital system activity are through generating oxidative stress. Concurrent administration of Cr as an anti-oxidant made toxic effects of CP alleviated. It also led to increase in the number of normal follicles and levels of sex hormones, TAC and SOD in serum as well as decrease in atretic pre-antral follicles, mast cells and MDA levels in ovarian tissue compared to sham-control group. Considering hypothalamus-pituitary-gonadal axis and since antral follicles<sup>24</sup> growth is affected by this axis hormones,<sup>4</sup> in this study Cr ameliorative effect on hormonal status of treated animals was not sufficient to diminish CP's reductive effects on atretic antral follicles; so, there was not a significant difference in the number of these follicles compared to CP group. However, pre-antral follicular development is independent from hypothalamus- pituitary-gonadal axis<sup>26</sup> and in this study the protective effect of Cr on pre-antral

follicles was more evident and Cr could significantly protect these follicles against atresia. It has been shown that the sweet fennel's essence can protect ovarian follicles against atresia imposed by busulfan chemotherapy and even enhance growth process of embryos obtained by *in vitro* fertility.<sup>27</sup> In addition, Das *et al.* have studied the protective role of ascorbic acid as an anti-oxidant agent against CP toxic effects on androgenic and gametogenic disorders in rats ovaries and suggested that CP prevents the activities of peroxidase and catalase and increases MDA level. All these changes were reversed by simultaneous usage of ascorbic acid.<sup>28</sup> In the current study, Cr as a protective factor against side effects of CP could lower the MDA level down to control group and protect the female genital system against damages caused by free radicals. The defending role of vitamin E against oxidative stress regarding CP administration in mice has been proved formerly. This action of vitamin E is caused by destroying free radicals as well as pituitary anterior lobe gonadotropins release stimulation.<sup>29</sup> In addition, the hydroalcoholic extract of ginger has been able to inhibit pharmacological side effects of CP on hypothalamus-pituitary-gonadal axis.<sup>24</sup> Considering that, follicular cells

are resources of estradiol in ovarian tissue and any severe disorder or damage will cause a significant reduction in serum estradiol levels.<sup>30</sup> In our study, oxidative stress caused by CP administration led to a severe drop in estradiol level compared to control group; while, in the group receiving concurrent CP and Cr, this effect of CP was canceled. Pituitary gonadotropins control the growth and maturation of ovarian follicles and estrogen secretion.<sup>26</sup> Receptors residing on granulosa cells interfere with FSH and activate enzymatic aromatase system resulting in androgens to estrogen conversion. Just before ovulation, a vast amount of LH reacts with its receptors on the surface of granulosa cells and causes ovulation. The LH hormone secreted from pituitary gland leads to luteinizing of follicular cells; then, causes the formation of active corpus luteum.<sup>31</sup> In the current study, it has been shown that levels of FSH and LH hormones and the average count of corpus luteum underwent a significant decrease in the CP group compared to control group; but, administration of Cr along with CP caused inhibition of CP side effects. Subsequently, the level of hormones and number of corpus luteum increased significantly compared to CP group. Considering that, CP increases the follicular atresia significantly; obviously due to damages in granulosa cells and estradiol production reduction. Cyclophosphamide also has a role in apoptosis of somatic COV434 granulosa cells through the removal of glutathione from these cells.<sup>32</sup> Generally, the tissues react against free radicals in two anti-oxidative mechanisms including enzymatic and non-enzymatic pathways. In the enzymatic system, glutathione, SOD and catalase play the most important role and the sum of two defensive systems (enzymatic and non-enzymatic) will form the ovarian anti-oxidative capacity.<sup>33</sup> We tried in this study to evaluate serum levels of SOD as one of the most important enzymes involved in anti-oxidative capacity. Observations suggested that in mice treated with CP alone, the levels of SOD and TAC in serum reduced significantly. In the meantime, treatment of mice by Cr increased above-noted parameters. Therefore, Cr was able to increase the SOD level as well as TAC level up to the control group through increasing the other anti-oxidant enzymes.

In animals, mast cells are sensitive to hormone levels.<sup>34</sup> Distribution of mast cells in rat ovary is dependent on some physiological changes during sex cycle.<sup>35</sup> Secretions of histamine and chemotactic factors in response to acute physical and chemical stresses caused by degranulated mast cells lead to the increase in blood vessels permeability and immune cells recall.<sup>36</sup> On the other hand, it has been shown that increased number of mast cells is related to infertility.<sup>37</sup> As a result, mast cells number increase in the CP group and a significant reduction of mast cells distribution in Cr receiving group can reveal the anti-oxidative role of Cr in decreasing vessel reactions and tissue inflammations. In addition, the average number of

these cells in association with hormonal changes resulted from CP may increase.

Overall, considering all results obtained, this study supports the idea that genital toxicity resulted from CP administration occurs due to oxidative stress and a potent anti-oxidant like Cr can protect the female genital system against damages often leading to infertility. However, in the current study, Cr could increase the quality of ovarian follicles, enhance the anti-oxidative capacity of serum and reduce mean number of mast cells and follicular atresia as well as MDA levels in ovarian tissue.

### Acknowledgments

This manuscript is a part of MSc thesis (No: 2-591) supported by Department of Basic Sciences, Faculty of Veterinary Medicine, Urmia University (Urmia, Iran) and authors wish to thank Urmia University for the financial supports.

### Conflict of interest

The authors have no conflicts of interest to declare.

### References

1. Himelstein-Braw R, Peters H, Faber M. Morphological study of the ovaries of leukaemic children. *Br J Cancer* 1978; 38 (1): 82-87.
2. Khan Mohammadi Ghane F, Ahmadi A, Shahrooz R, et al. Evaluation of protective effects of ethyl pyruvate on embryo developing process in in vitro fertilization (IVF) in cyclophosphamide treated mice. *Urmia Med J* 2014;25(8):760-768.
3. Vaskivuo T. Regulation of apoptosis in the female reproductive system. Thesis, University of Oulu. Oulu, Finland: 2002.
4. Ben-Yehuda D, Krichevsky S, Caspi O, et al. Microsatellite instability and p53 mutations in therapy-related leukemia suggest mutator phenotype. *Blood* 1996;88(11):4296-4303.
5. Apperley JF, Reddy N. Mechanism and management of treatment-related gonadal failure in recipients of high dose chemoradiotherapy. *Blood Rev* 1995; 9 (2):93-116.
6. Abdoon AS, Kandil OM, Otoi T, et al. Influence of oocyte quality, culture media and gonadotropins on cleavage rate and development of in vitro fertilized buffalo embryos. *Ani Reprod Sci* 2001;65(3-4):215-223.
7. Kianbakht S, Mozaffari K. Effects of saffron and its active constituents, crocin and safranal, on prevention of indomethacin induced gastric ulcers in diabetic and nondiabetic rats. *J Med Plants* 2009;8(Suppl 5):30-38.
8. Abe K, Saito H. Effects of saffron extract and its constituent crocin on learning behavior and long-term

- potentiation. *Phytother Res* 2000; 14(3):149-152.
9. Zarei Jaliani H, Riazi GH, Ghaffari SM, et al. The effect of the crocus sativus L. carotenoid, crocin, on the polymerization of microtubules, *in vitro*. *IJBMS* 2013;16(1):101-107.
  10. Alizadeh F, Bolhassani A. In vitro cytotoxicity of Iranian saffron and two main components as a potential anti-cancer drug. *SM J Pharmac Ther* 2015;1(1):1001.
  11. Hosseinzadeh H, Younesi H. Petal and stigma extracts of *Crocus sativus* L. have antinociceptive and anti-inflammatory effects in mice. *BMC Pharmacol* 2002; 2:1-8.
  12. Hosseinzadeh H, Khosravan V. Anticonvulsant effects of aqueous and ethanolic extracts of *Crocus sativus* L. stigmas in mice. *Arch Irn Med* 2002; 5(1):44-47.
  13. Hosseinzadeh H, Karimi G, Niapoor M. Antidepressant effect of *Crocus sativus* L. stigma extracts and their constituents, crocin and safranal, in mice. *Acta Horti*. 2004;650:435-445;
  14. Esalatmanesh S, Biuseh M, Noorbala AA, et al. Comparison of saffron and fluvoxamine in the treatment of mild to moderate obsessive-compulsive disorder: a double blind randomized clinical trial. *Iran J Psychiatry* 2017; 12(3):154-162.
  15. Zargari A. Medicinal plants [Persian]. Tehran, Iran: Tehran University Press 1990; 574.
  16. Selvakumar E, Prahalathan C, Sudharsan PT, et al. Protective effect of lipoic acid on cyclophosphamide-induced testicular toxicity. *Clinia Chimica Acta* 2006; 367(1-2): 114-119.
  17. Hesari AK, Shahrooz R, Ahmadi A, et al. Crocin prevention of anemia-induced changes in structural and functional parameters of mice testes. *J Appl Biomed* 2015;13(3):213-223
  18. Humson GL. Animal tissue techniques. 4<sup>th</sup> ed. San Francisco, USA: W. H. Freeman, Macmillan Publishers 1979; 137-138.
  19. Benzie IF, Strain JJ. Ferric reducing/antioxidant power assay: direct measure of total antioxidant activity of biological fluids and modified version for simultaneous measurement of total antioxidant power and ascorbic acid concentration. *Methods Enzymol* 1999;299:15-27.
  20. Garcia YJ, Rodríguez-Malaver AJ, Peñaloza N. Lipid peroxidation measurement by thiobarbituric acid assay in rat cerebellar slices. *J Neurosci Methods* 2005; 144(1):127-135.
  21. Niehaus Jr WG, Samuelsson B. Formation of malondialdehyde from phospholipid arachidonate during microsomal lipid peroxidation. *Eur J Biochem* 1968; 6(1):126-130.
  22. Lowry OH, Rosebrough NJ, Farr AL, et al. Protein measurement with the Folin phenol reagent. *J Biol Chem* 1951; 193(1):265-275.
  23. Hassanpour A, Yousefian S, Askaripour M, et al. Ovarian protection in cyclophosphamide-treated mice by fennel. *Toxicol Rep* 2017;4: 160-164.
  24. Johari H. Mahmoudinejad F, Amjad G. Evaluate the effect of ginger extract on the axis hypothalamus - pituitary - gonadal axis in adult female rats treated with cyclophosphamide [Persian]. *J Pzhvda* 2011; 6 (20): 62-70.
  25. Agarwal A, Saleh RA, Bedaiwy MA. Role of reactive oxygen species in the pathophysiology of human reproduction. *Fertil Steril* 2003; 79(4):829-843.
  26. Eurell JA, Frappier BL. Dellmann's textbook of veterinary histology. 6<sup>th</sup> ed. New Jersey, USA: John Wiley & Sons 2006; 256-278.
  27. Ahmadi A, Chafjiri SB, Sadrkhanlou RA. Effect of satureja khuzestanica essential oil against fertility disorders induced by busulfan in female mice. *Vet Res Forum* 2017; 8(4): 281-286.
  28. Das UB, Mallick M, Debnath JM, et al. Protective effect of ascorbic acid on cyclophosphamide-induced testicular gametogenic and androgenic disorders in male rats. *Asian J Androl* 2002; 4(3):201-207.
  29. Li D-J, Xu Z-S, Zhang Z-H, et al. Antagonistic effects of vitamin E on the testicular injury by cyclophosphamide in mice [Chinese]. *Zhonghua Nan Ke Xue* 2006; 12(4):318-322.
  30. Douglas DC, Nakhuda GS, Sauer MV, et al. Angiogenesis and ovarian function. *J Fertil Reprod* 2005; 13(4): 7-15.
  31. Mescher AL. Junqueira's basic histology: text and atlas. 13<sup>th</sup> ed. California, USA: McGraw-Hill, 2013; 449-477.
  32. Tsai-Turton M, Luong BT, Tan Y, et al. Cyclophosphamide-induced apoptosis in COV434 human granulosa cells involves oxidative stress and glutathione depletion. *Toxicol Sci* 2007; 98(1):216-230.
  33. Chaudière J, Ferrari-Iliou R. Intracellular antioxidants: from chemical to biochemical mechanisms. *Food Chem Toxicol* 1999; 37(9-10):949-962.
  34. Krishna A, Terranova PF. Alterations in mast cell degranulation and ovarian histamine in the proestrous hamster. *Biol Reprod* 1985; 32(5):1211-1217.
  35. Karaca T, Yörük M, Uslu S. Distribution and quantitative patterns of mast cells in ovary and uterus of rat. *Arch Med Vet* 2007; 39(2):135-139.
  36. Prussin C, Metcalfe DD. 4. IgE, mast cells, basophils, and eosinophils. *J Allergy Clin Immunol* 2003; 111(S2): S486-S494.
  37. Roaiah MMF, Khatib H, Mostafa T. Mast cells in testicular biopsies of azoospermic men. *Andrologia* 2007; 39(5):185-189.