

 **Review Article** 

Thoracic Endovascular Aortic Repair for Acute Aortic Dissection

Tetsuro Uchida, MD, PhD and Mitsuaki Sadahiro, MD, PhD

Thoracic endovascular aortic repair (TEVAR) for thoracic aortic disease constitutes a paradigm shift in the treatment strategy of aortic dissection, as well as thoracic aortic aneurysms. Conventionally, most patients with Stanford type B acute aortic dissection are treated using conservative medical treatment during the acute phase. However, in patients with complicated type B aortic dissection who present with life-threatening complications, TEVAR has been introduced as a novel and less-invasive alternative and has shown better early results than those observed with conventional therapy. Recently, TEVAR was reported to be effective in not only promoting thrombosis of the false lumen but also in preventing aortic enlargement observed at long-term follow-up. TEVAR has been established as first-line therapy for complicated type B aortic dissection. In contrast, a considerable number of patients who received acute phase medical treatment required surgical intervention for chronic dissecting aortic aneurysms. With the increasing popularity of TEVAR for the treatment of complicated type B aortic dissection, prophylactic and pre-emptive TEVAR has been considered in patients with uncomplicated type B aortic dissection. However, supportive evidence for this strategy is limited, and reassessment is mandatory because it is continuously evolving. Although acute type A aortic dissection is a life-threatening condition, the results of open surgery continue to improve in the modern surgical era. Open surgical treatment is well established and recognized as a gold standard even in the endovascular era. Presently, the application of TEVAR for ascending aortic dissection has undergone a change, and TEVAR is considered a viable rescue option for patients

with type A aortic dissection who are not eligible for open surgical repair. However, TEVAR for the descending aorta is well-established treatment for retrograde type A dissection. Several conceptual and technical issues remain unresolved, and technological advances would lead to the development of innovative disease-specific devices and solutions in the future for endovascular treatment of acute aortic dissection. (This is a translation of *Jpn J Vasc Surg* 2018; 27: 337–345.)

Keywords: acute aortic dissection, thoracic endovascular aortic repair

Introduction

Thoracic endovascular aortic repair (TEVAR) has achieved a major paradigm shift in the treatment of both atherosclerotic thoracic aortic aneurysm and chronic aortic dissection. Traditionally, resting antihypertensive treatment has been the standard treatment for acute type B aortic dissection, but aggressive acute phase surgical intervention by TEVAR has now become widespread for complicated type B aortic dissection. In addition, it is now covered by medical insurance in Japan, and quite favorable results have been reported. In recent years, the indication has expanded to include uncomplicated type B aortic dissection with the intention of preventing future aortic events. In addition to discussing the current status of TEVAR for acute type B aortic dissection, this paper mentions the possibility of its use in the treatment for acute type A aortic dissection.

TEVAR for Acute Type B Aortic Dissection

Prior to the popularization of TEVAR for acute type B aortic dissection in Japan, the INSTEAD-XL study was published in 2013¹⁾ and the European Society of Cardiology (ESC) Guidelines were revised in 2014²⁾ (Table 1). TEVAR for complicated type B aortic dissection, such as organ ischemia, was listed as class IIa in the 2001 ESC guidelines³⁾ but was changed to class I in the revised version. Furthermore, TEVAR was also listed as class IIa for the first time for uncomplicated type B aortic dissection. Since then, the concept and selection of preventive TEVAR has been added as a surgical option in the treatment for

Second Department of Surgery, Yamagata University Faculty of Medicine, Yamagata, Japan

Received: October 18, 2018; Accepted: October 22, 2018
Corresponding author: Tetsuro Uchida, MD, PhD. Second Department of Surgery, Yamagata University Faculty of Medicine, 2-2-2 Iida-Nishi, Yamagata 990-9585, Japan
Tel: +81-23-628-5342, Fax: +81-23-628-5345
E-mail: t-uchida@med.id.yamagata-u.ac.jp
This is a translation of *Jpn J Vasc Surg* 2018; 27: 337–345.


 ©2018 The Editorial Committee of Annals of Vascular Diseases. This article is distributed under the terms of the Creative Commons Attribution License, which permits use, distribution, and reproduction in any medium, provided the credit of the original work, a link to the license, and indication of any change are properly given, and the original work is not used for commercial purposes. Remixed or transformed contributions must be distributed under the same license as the original.

Table 1 2014 European Society of Cardiology (ESC) Guidelines on the diagnosis and treatment of aortic diseases

Recommendations	Class ^a	Level ^b	Ref. ^c
In all patients with AD, medical therapy including pain relief and blood pressure control is recommended.	I	C	
In patients with Type A AD, urgent surgery is recommended.	I	B	1,2
In patients with acute Type A AD and organ malperfusion, a hybrid approach (i.e. ascending aorta and/or arch replacement associated with any percutaneous aortic or branch artery procedure) should be considered.	IIa	B	2,118, 202–204, 227
In uncomplicated Type B AD, medical therapy should always be recommended.	I	C	
In uncomplicated Type B AD, TEVAR should be considered.	IIa	B	218,219
In complicated Type B AD, TEVAR is recommended.	I	C	
In complicated Type B AD, surgery may be considered.	IIb	C	

ESC: European Society of Cardiology
Reprinted from Reference 2 by permission of Oxford University Press.

acute type B aortic dissection.

TEVAR procedure for acute type B aortic dissection

The principle of surgical treatment in acute aortic dissection is aortic resection including the intimal tear (entry) and closure of the false lumen by reapproximating the dissected aortic wall. The concept is the same in TEVAR, with the aim of reducing the pressure inside the false lumen and thrombosis by covering the intimal tear with a stent graft (Fig. 1). For entry closure in the vicinity of the left subclavian artery, covering and debranching of the origin of the left subclavian artery are considered to be appropriate for securing an adequate landing zone on the proximal side. It is important to place the stent graft after ensuring that the true lumen has been visualized by intravascular ultrasound (Fig. 1). It has also been suggested with regard to the optimal size of the stent graft that a device with the same diameter as the true lumen diameter, or with a 10% increase beyond this diameter, should be selected; however, because there is a high degree of bias in the measurement of the true lumen diameter, the difference in radial force between each device, etc., no consensus on this topic has been reached. Recently, in addition to entry closure by a covered stent, provisional extension to induce complete attachment (the PETTICOAT technique)^{4–6} has been performed by the bare stent placement to facilitate true lumen expansion (Fig. 2). The residual blood flow into the false lumen via the peripheral reentry after TEVAR is a major factor related to the enlargement of a dissecting aortic aneurysm in the chronic phase and remains an important problem.

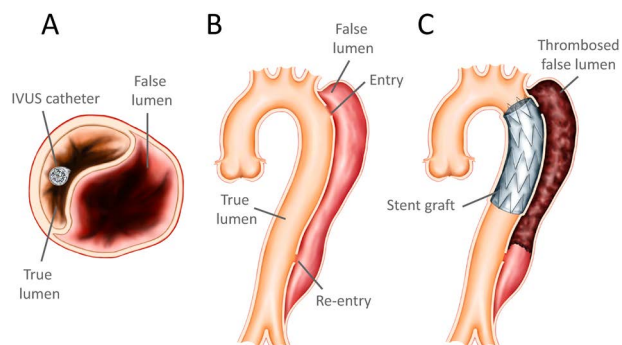


Fig. 1 Schematic drawings of TEVAR procedure of type B aortic dissection.

A: Confirmation of IVUS catheter being inside the true lumen. **B:** Primary intimal tear located at the descending aorta. **C:** Stent graft coverage of the primary intimal tear. TEVAR: thoracic endovascular aortic repair; IVUS: intravascular ultrasound

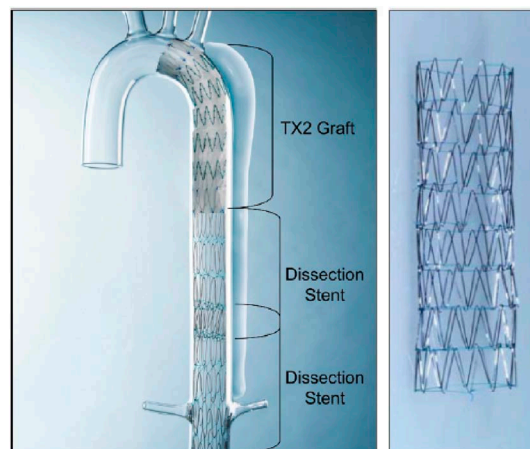


Fig. 2 Zenith Dissection Endovascular System.

In type B aortic dissection, the PETTICOAT technique, which entails stent graft coverage of the primary intimal tear followed by bare metal stent placement distally, may improve true lumen caliber and promote false lumen thrombosis. PETTICOAT: provisional extension to induce complete attachment

nique)^{4–6} has been performed by the bare stent placement to facilitate true lumen expansion (Fig. 2). The residual blood flow into the false lumen via the peripheral reentry after TEVAR is a major factor related to the enlargement of a dissecting aortic aneurysm in the chronic phase and remains an important problem.

Complicated type B

Because many patients who underwent emergency surgery for acute complicated type B aortic dissection prior to the introduction of TEVAR had complications due to rupture and severe organ malperfusion, treatment results were extremely poor. Aortic replacement surgery via lateral

Table 2 Endovascular treatment for aortic dissection

Class I
1. Chronic follow-up after endovascular treatment (including imaging diagnosis) (Level C)
2. Support from a surgical team (Level C)
3. Entry closure with stent grafting for acute complicated type B aortic dissection (Level C)
Class IIa
1. Stent placement for ischemic branch vessels resulting from compression of the true lumen due to aortic dissection (Level B)
*Early treatment after the onset of dissection is important in acute cases.
2. Transcatheter fenestration soon after the onset of acute type B aortic dissection with blocked true lumen (Level B)
3. Entry closure with stent grafting for chronic type B aortic dissection where surgery is indicated (Level B)
4. Entry closure with stent grafting for acute type A aortic dissection caused by retrograde dissection (Level B)
Class IIb
1. Entry closure with stent grafting for patients with chronic type B aortic dissection having high surgical risk (Level B)
2. Stenting for a narrowed segment of the true lumen in acute aortic dissection (Level C)
3. Entry closure with stent grafting for acute type B aortic dissection to prevent the formation of future aneurysms (Level C)
Class III
1. Use in patients who do not meet anatomical criteria (Level B)
2. Entry closure with stent grafting for acute type B aortic dissection where branch vessels are obviously ischemic due to static compression (Level C)
3. Entry closure with stent grafting for chronic type B aortic dissection where the main branch vessels are perfused from the false lumen (Level C)
*When transcatheter fenestration is simultaneously performed with or prior to stent grafting, Class IIb and Level of Evidence: C.

It is a prerequisite that the above procedures are conducted in hospitals skilled in endovascular treatment.

Adopted from Reference 11.

thoracotomy, extra-anatomical bypass surgery, fenestration of intimal flap via laparotomy or using a catheter, etc., were performed in response to various pathological conditions, but the in-hospital mortality rates regarding operative treatment for type B aortic dissection in the acute phase were very high (32.1%).⁷⁾ Fortunately, the recent introduction of TEVAR has greatly contributed to the improvement of the treatment outcomes of this patient group. Although patient background issues such as their preoperative conditions and the timing of surgical intervention were not always the same, the short-term outcome of TEVAR for acute complicated type B aortic dissection has been favorable, as reported in the literature.⁴⁻⁶⁾ According to Szeto et al.,⁸⁾ the 30-day postoperative mortality rate of 35 patients who underwent TEVAR for acute complicated type B aortic dissection was only 2.8% and the 1-year survival rate was 93.4%. Hanna et al.⁹⁾ also reported that no cases of mortality were noted in 30 days following TEVAR, and postoperative results were favorable; however, in the chronic phase, >25% of the patients required additional treatment.⁹⁾ The series of Bavaria et al.¹⁰⁾ reported that although the mortality rates at 30 days and 1 year postoperatively were favorable (8% and 15%, respectively), the incidence of paraplegia was 6%, and some sort of aorta-related complications occurred within 1 year in approximately 50% of the patients.¹⁰⁾

In the current Guidelines for Diagnosis and Treatment of Aortic Aneurysm and Aortic Dissection of the Japanese Circulation Society (Table 2), TEVAR for acute compli-

cated type B aortic dissection is listed as class I.¹¹⁾ Recent findings have reported that TEVAR is effective for aortic remodeling to promote the thrombosis of the false lumen in the long term and to prevent the enlargement of the thoracic aorta.¹²⁾ In addition, TEVAR for acute complicated type B aortic dissection has been established as the first choice for acute treatment.^{13,14)} Although attention has been paid to the favorable short-term results of TEVAR, how to prevent the aortic events in the long term remains an important issue.

Uncomplicated type B

The purpose of initial treatment of acute uncomplicated type B aortic dissection is the prevention of aortic events in the acute phase in many institutions at present. However, after undergoing conservative treatment in the acute phase, numerous patients have presented with the formation of a dissecting aortic aneurysm during follow-up, and these require surgical treatment in the chronic phase. TEVAR for acute uncomplicated type B aortic dissection is performed from the viewpoint of preventing aortic events such as aneurysmal formation and rupture during the chronic phase. In the Japanese guidelines, the use of TEVAR for the purpose of preventing the chronic aneurysmal formation in acute uncomplicated type B aortic dissection is listed as class IIb. However, the accumulation of evidence including the prognosis in the long term is insufficient, and at present, TEVAR has not yet been established as the primary treatment method in Japan, where it is not

covered by medical insurance, like Western countries.^{11,15)}

Results of TEVAR for acute type B aortic dissection

According to the International Registry of Acute Aortic Dissection,¹⁴⁾ the 3-year survival rate of patients who underwent conservative treatment for acute type B aortic dissection is 75%–80%.¹⁴⁾ In Japanese reports, the overall survival rates of conservative treatment for type B dissection 5 years after onset in cases of patent false lumen and thrombosed false lumen were 64%–79% and 74%–97%, respectively.^{16–18)} All these reports concern commercially available TEVAR devices, but there is no significant change in mortality and morbidity rates with conservative treatment for type B aortic dissection after the introduction of TEVAR. The aortic event-free survival rate in the 10 years after the onset of type B aortic dissection among our cases was 77% for the group in which aortic enlargement was observed in the chronic phase and 79% in the group in which it was not observed.¹⁹⁾

The short-term survival rate of patients with acute type B aortic dissection in which strict resting blood pressure management is performed is generally favorable,²⁰⁾ but there has been a significantly large groups of patients requiring surgical intervention in the chronic phase, and it was indicated that their survival rate was poor compared with the group that underwent TEVAR in the acute phase.^{21–23)}

According to one study,⁹⁾ the surgical results of TEVAR for acute complicated type B aortic dissection were favorable, with no cases of in-hospital mortality being noted, and the incidence of cerebrospinal disorder was low (2%). However, as of the mean observation period of 34 months, the fact that 26% of cases required re-intervention for various reasons is clearly a problem. Still, according to the database of the ADSORB trial, which is a prospective randomized study of acute type B aortic dissection,²⁴⁾ mortality within 30 days was not noted in either the conservative treatment group or the TEVAR group for acute uncomplicated type B aortic dissection, and short-term outcomes were favorable. However, although observation after 1 year revealed true lumen expansion and false lumen constriction in the TEVAR group, the true lumen diameter did not change in the conservative treatment group; instead, the data showed that the false lumen had expanded.

Complications following TEVAR for aortic dissection include stent graft-induced new entry (SINE)^{25,26)} (Fig. 3), retrograde type A aortic dissection (RTAD)^{27,28)} (Fig. 4), and enlargement of the residual false lumen,²⁹⁾ all of which can cause severe or lethal pathological conditions. It has been reported that the onset of SINE is more frequent in TEVAR in the chronic phase than in the acute phase,²⁶⁾ and stent graft oversizing has been reported as a

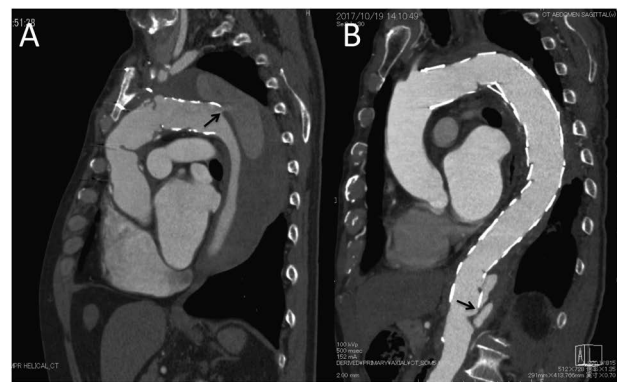

Fig. 3 A, B: SINE was observed at the distal end of the endograft (black arrow). SINE: stent graft-induced new entry

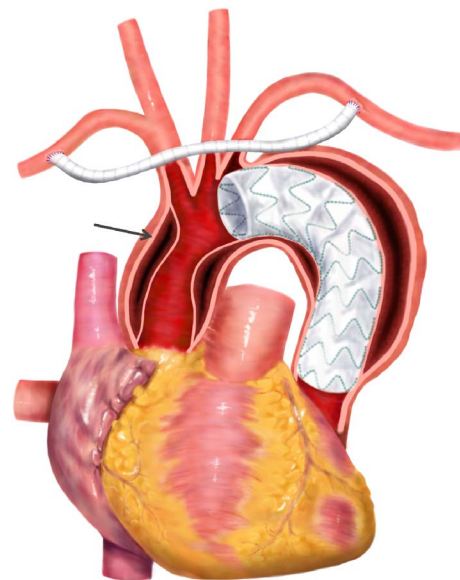


Fig. 4 RTAD occurring after TEVAR for type B aortic dissection. Retrograde ascending aortic dissection was indicated (black arrow). RTAD: retrograde type A dissection; TEVAR: thoracic endovascular aortic repair

common risk factor for both SINE and RTAD,²⁶⁾ but there is no definitive consensus for the procedure as a preventive measure for postoperative complications related to stent grafting. If a surgical procedure-related problem occurs after a prophylactic TEVAR for acute uncomplicated type B aortic dissection, invasive treatment that was not originally necessary to be performed more than once may become necessary depending on the situation.

Problems noted regarding current acute type B aortic dissection include (i) characteristics of cases of future aneurysm formation and (ii) the optimal timing of TEVAR. In particular, there are many reports on what kinds of cases cause enlargement of aneurysm size and formation of dissecting aortic aneurysm, and it turns out to be largely

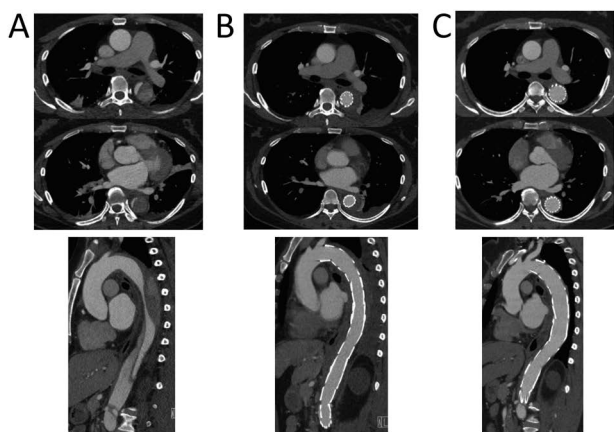


Fig. 5 CT images of 44 year-old female diagnosed with acute complicated type B aortic dissection.

A: Preoperative CT demonstrated narrow true lumen. **B:** The PETTICOAT technique, which consisted of stent graft coverage of the primary entry followed by bare metal stent placement to the downstream aorta. CT image soon after TEVAR showed the true lumen increased dramatically and thrombosis of the false lumen was induced. **C:** CT image 1 year after TEVAR showed complete remodeling of the descending aorta with complete disappearance of the false lumen. CT: computed tomography; PETTICOAT: provisional extension to induce complete attachment; TEVAR: thoracic endovascular aortic repair

related to the determination of TEVAR indication criteria for acute uncomplicated type B aortic dissection. It is necessary to carefully plan TEVAR for acute uncomplicated type B aortic dissection, taking into consideration that it is a prophylactic treatment. Therefore, for these patients, it is important to precisely identify and intervene in acute phase cases only when treatment is actually necessary, that is, cases in which the risk of onset of aortic events in the chronic phase is significant.

Risk factors for poor prognosis of acute type B aortic dissection, that is, the onset of aortic events include being male,³⁰⁾ partial thrombosis of the false lumen,³¹⁾ having an aortic diameter exceeding 40 mm,^{19,32,33)} early aortic diameter expansion,³⁴⁾ onset at young age,^{33,35)} false lumen located on the small curvature side,³⁰⁾ and the diameter of the intimal tear exceeding 10 mm.^{29,36)} Examinations from various viewpoints have been reported in cases wherein branches originated in the false lumen and the aortic diameter tended to expand,³⁷⁾ and it was found that the greater the number of intercostal arteries, the higher the tendency for the aneurysmal change.³⁸⁾

Favorable results have also been reported using the PETTICOAT technique to expand the true lumen. Regarding the treatment results of TEVAR combined with PETTICOAT together for type B aortic dissection with acute to subacute complications, the 30-day mortality rate was 0%–5.0%, and false lumen regression was noted in 31%–

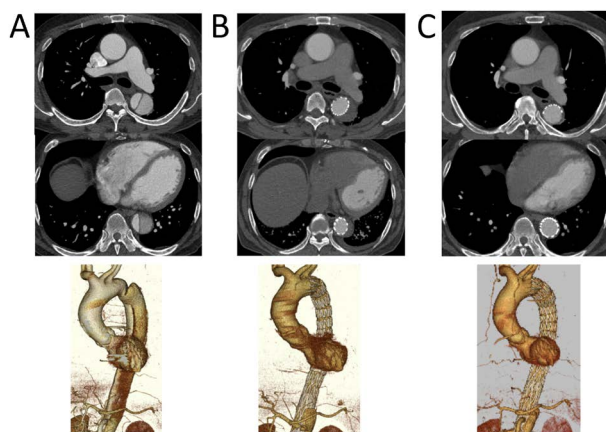


Fig. 6 CT images of 51 year-old male diagnosed with subacute uncomplicated type B aortic dissection.

A: Preoperative CT image demonstrating narrow true lumen. **B:** Endovascular treatment with the PETTICOAT technique was performed 2 months after the onset. CT image soon after TEVAR showed enlarged true lumen and thrombosis of the false lumen was promoted. **C:** One year follow-up CT demonstrated favorable remodeling of the dissected descending aorta. No sign of dissection is seen at the descending aorta. CT: computed tomography; PETTICOAT: provisional extension to induce complete attachment; TEVAR: thoracic endovascular aortic repair

80% of patients. However, there was a difference between institutions during the 1-year observation period.^{4–6)} Here, we present a case study using TEVAR with the PETTICOAT technique for acute complicated type B aortic dissection (Figs. 5 and 6). Computed tomography (CT) performed 1 year after TEVAR revealed favorable true lumen expansion and disappearance of the false lumen.

Endovascular stent graft placement for acute type B aortic dissection is currently a worldwide topic in aortic surgery, and it is a field that is constantly debated at academic conferences. At present, there are many choices for the optimal timing of TEVAR intervention, as well as for various novel surgical procedures and techniques. It is essential to perform appropriate treatment with a view toward the long-term prognosis of patients rather than with a focus on novel procedures.

TEVAR for Acute Type A Aortic Dissection

Despite disease severity, the results of open surgery for acute type A aortic dissection are relatively favorable, and in the 2014 annual report of the Japanese Association for Thoracic Surgery, the surgical mortality rate in Japan was 10.6%.³⁹⁾ With this background, the standard of treatment for acute type A aortic dissection in Japan as well as worldwide is open surgery. However, due to problems such as general status and complications, the mortality rate of patients not indicated for open surgery is very high

(approximately 60%),⁴⁰⁾ and TEVAR has drawn attention as a minimally invasive alternative treatment method. However, at present, TEVAR of the ascending aorta for treating acute type A aortic dissection is employed in only high-risk cases, in which open surgery is difficult to perform.⁴¹⁾ TEVAR for acute type A aortic dissection in Japan is not yet widely used. In the guidelines, “Entry closure with stent grafting for acute type A aortic dissection caused by retrograde dissection” is listed as class IIa¹¹⁾

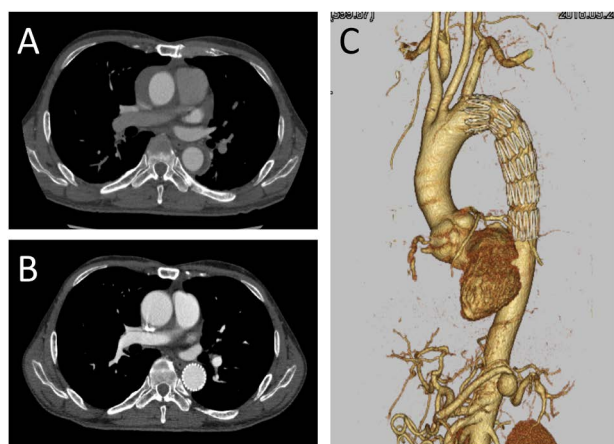


Fig. 7 CT images of 44 year-old male with retrograde acute type A aortic dissection.

A: Preoperative CT demonstrated ascending and descending aortic dissection with thrombosed false lumen. No pericardial effusion was noted. **B:** Stent graft coverage of the primary entry at descending aorta was performed. CT at 1-month follow-up showed remodeling from the ascending to the descending aorta with complete disappearance of the false lumen. **C:** Three-dimensional reconstruction CT demonstrated thoracic descending endograft. No sign of dissection was noted. A 20 mm of splenic arterial aneurysm was also showed. CT: computed tomography

(Table 2), and there are a few reports of entry closure by TEVAR of the descending aorta in clinical practice.^{42,43)} Here we present a case in which TEVAR was performed on the descending aorta for retrograde acute type A aortic dissection (Fig. 7). As the thrombosed false lumen of the ascending aorta expanded, an ulcer-like projection of the descending aorta was noted on CT; we therefore attempted TEVAR for the entry closure of the descending aorta. The false lumen of the ascending aorta completely disappeared 1 month after TEVAR.

TEVAR procedure for acute type A aortic dissection

The surgical procedure for TEVAR of the descending aorta for retrograde acute type A aortic dissection is almost the same as that for acute type B aortic dissection. In contrast, TEVAR of the ascending aorta requires determination of anatomical indication and a surgical technique that significantly differs from TEVAR for acute type B aortic dissection. Entry is present in the ascending aorta for two-thirds of aortic dissection cases,⁴⁴⁾ and it is therefore important to ensure adequate landing zone when performing entry closure of the ascending aorta by TEVAR; however, attention should also be paid to potential interference with the coronary artery, aortic valve, and brachiocephalic artery by the stent graft. It has been reported that when the landing zone on the peripheral side is insufficient, debanching of the brachiocephalic artery may be considered, but 32% of patients with acute type A aortic dissection present with anatomical conditions suitable for TEVAR of the ascending aorta.⁴⁵⁾ There is a retrograde approach from the femoral artery and an antegrade approach from the apex (Fig. 8), but the detail of the procedures such as delivery of the stent graft and rapid pacing are largely due to the technological progress of transcatheter aortic valve

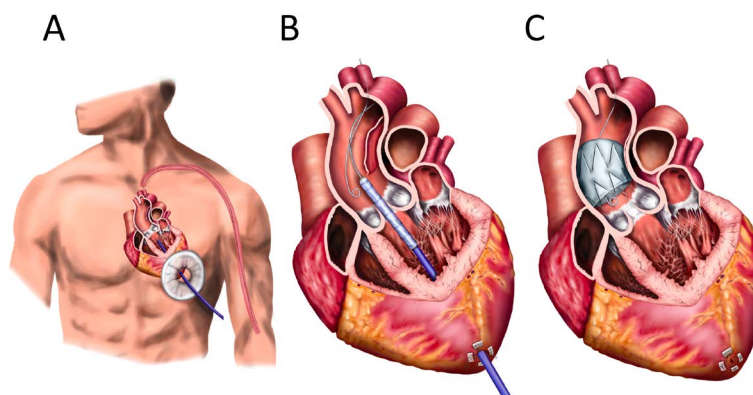


Fig. 8 Schematic drawings of transapical TEVAR procedure of type A aortic dissection.

A: Through small left intercostal thoracotomy, a transapical sheath advanced through the aortic valve into the descending aorta. **B:** Stent graft delivery system being advanced into the aortic root in preparation for deployment. **C:** Transapical ascending stent graft deployment was completed. TEVAR: thoracic endovascular aortic repair

replacement.

Results of TEVAR for acute type A aortic dissection

This situation appears to be due to the strict selection of indicated cases, but the success rates of TEVAR and the surgical mortality rates are favorable (97%–100% and 0%–6.7%, respectively).^{46–48)} The most serious postoperative complication of concern is cerebral infarction. The incidence of brain complications among all TEVAR cases is 3.5%–5.0%^{49,50)}; however, in TEVAR for acute type A aortic dissection, because it is necessary to perform a surgical procedure in the ascending aorta with the lesion, it may be a higher-risk procedure.

In addition, attention should be paid to the onset of endoleak, aortic rupture, dissection progression, coronary artery occlusion, and aortic valve dysfunction. Currently, TEVAR for acute type A aortic dissection does not exceed open surgery and is merely regarded as a rescue procedure for high-risk cases. We hope that improved TEVAR devices and technological innovation in the future will lead to further improvement in treatment results of acute type A aortic dissection.

Conclusion

There has definitely been a change from the traditional approach of performing conservative treatment for acute type B aortic dissection and emergency open surgery for acute type A aortic dissection. It is important that surgeons involved in the treatment of modern aortic diseases accurately evaluate new information as it develops and appropriately select treatments based on accumulated evidence.

Disclosure Statement

The author and co-author have no conflicts of interest to declare.

Additional Note

An abstract of the present paper was presented at the 27th Study Seminar of the Japanese Society for Vascular Surgery (2018, Yamagata).

Additional Remarks

This review article was primarily published in the Japanese Journal of Vascular Surgery Vol. 27 (2018) No. 4; however, an error was detected after the publication. The erratum was published in Vol. 27 (2018) No. 5 of the same journal. This translation reflects the correction.

References

- 1) Nienaber CA, Kische S, Rousseau H, et al. Endovascular repair of type B aortic dissection: long-term results of the randomized investigation of stent grafts in aortic dissection trial. *Circ Cardiovasc Interv* 2013; **6**: 407-16.
- 2) Erbel R, Aboyans V, Boileau C, et al. 2014 ESC Guidelines on the diagnosis and treatment of aortic disease: document covering acute and chronic aortic diseases of the thoracic and abdominal aorta of the adult. The task force for the diagnosis and treatment of aortic diseases of the European Society of Cardiology (ESC). *Eur Heart J* 2014; **35**: 2873-926.
- 3) Erbel R, Alfonso F, Boileau C, et al. Diagnosis and management of aortic dissection. *Eur Heart J* 2001; **22**: 1642-81.
- 4) Lombardi JV, Cambria RP, Nienaber CA, et al. Prospective multicenter clinical trial (STABLE) on the endovascular treatment of complicated type B aortic dissection using a composite device design. *J Vasc Surg* 2012; **55**: 629-40.e2.
- 5) Alsac JM, Girault A, El Batti S, et al. Experience of the Zenith Dissection Endovascular System in the emergency setting of malperfusion in acute type B dissections. *J Vasc Surg* 2014; **59**: 645-50.
- 6) Lombardi JV, Cambria RP, Nienaber CA, et al. Aortic remodeling after endovascular treatment of complicated type B aortic dissection with the use of a composite device design. *J Vasc Surg* 2014; **59**: 1544-54.
- 7) Suzuki T, Mehta RH, Ince H, et al. Clinical profiles and outcomes of acute type B aortic dissection in the current era: lessons from the international registry of aortic dissection (IRAD). *Circulation* 2003; **108 Suppl 1**: I1312-7.
- 8) Szeto WY, McGarvey M, Pochettino A, et al. Results of a new surgical paradigm: endovascular repair for acute complicated type B aortic dissection. *Ann Thorac Surg* 2008; **86**: 87-93; discussion, 93-4.
- 9) Hanna JM, Andersen ND, Ganapathi AM, et al. Five-year results for endovascular repair of acute complicated type B aortic dissection. *J Vasc Surg* 2014; **59**: 96-106.
- 10) Bavaria JE, Brinkman WT, Hughes GC, et al. Outcomes of thoracic endovascular aortic repair in acute type B aortic dissection: results from the Valiant United States investigational device exemption study. *Ann Thorac Surg* 2015; **100**: 802-8; discussion, 808-9.
- 11) Takamoto S, Ishimaru S, Ueda Y, et al. Guidelines for Diagnosis and Treatment of Aortic Aneurysm and Aortic Dissection (JCS 2011). http://www.j-circ.or.jp/guideline/pdf/JCS2011_takamoto_h.pdf (Reference: March 2018).
- 12) Leshnower BG, Duwayri YM, Chen EP, et al. Aortic remodeling after endovascular repair of complicated acute type B aortic dissection. *Ann Thorac Surg* 2017; **103**: 1878-85.
- 13) Zeeshan A, Woo EY, Bavaria JE, et al. Thoracic endovascular aortic repair for acute complicated type B aortic dissection: superiority relative to conventional open surgical and medical therapy. *J Thorac Cardiovasc Surg* 2010; **140 Suppl**: S109-15; discussion, S142-6.
- 14) Tsai TT, Fattori R, Trimarchi S, et al. International Registry of Acute Aortic Dissection. Long-term survival in patients presenting with type B acute aortic dissection: insights from the International Registry of Acute Aortic Dissection. *Circulation* 2006; **114**: 2226-31.

- 15) Hiratzka LF, Bakris GL, Beckman JA, et al. 2010 ACCF/AHA/AATS/ACR/ASA/SCA/SCAI/SIR/STS/SVM guidelines for the diagnosis and management of patients with thoracic aortic disease: a report of the American College of Cardiology Foundation/American Heart Association Task Force on Practice Guidelines, American Association for Thoracic Surgery, American College of Radiology, American Stroke Association, Society of Cardiovascular Anesthesiologists, Society for Cardiovascular Angiography and Interventions, Society of Interventional Radiology, Society of Thoracic Surgeons, and Society for Vascular Medicine. *Circulation* 2010; **121**: e266-369.
- 16) Kaji S, Akasaka T, Katayama M, et al. Prognosis of retrograde dissection from the descending to the ascending aorta. *Circulation* 2003; **108 Suppl 1**: II300-6.
- 17) Marui A, Mochizuki T, Mitsui N, et al. Toward the best treatment for uncomplicated patients with type B acute aortic dissection: a consideration for sound surgical indication. *Circulation* 1999; **100 suppl**: II275-80.
- 18) Akutsu K, Nejima J, Kiuchi K, et al. Effects of the patent false lumen on the long-term outcome of type B acute aortic dissection. *Eur J Cardiothorac Surg* 2004; **26**: 359-66.
- 19) Nakamura K, Uchida K, Sho R, et al. Risk factor analysis for the aortic enlargement in patients with chronic type B aortic dissection. *Japanese Journal of Vascular Surgery* 2018; **27**: 55-60.
- 20) Niino T, Hata M, Sezai A, et al. Optimal clinical pathway for the patient with type B acute aortic dissection. *Circ J* 2009; **73**: 264-8.
- 21) Durham CA, Cambria RP, Wang LJ, et al. The natural history of medically managed acute type B aortic dissection. *J Vasc Surg* 2015; **61**: 1192-9.
- 22) Lou X, Chen EP, Duwayri YM, et al. The impact of thoracic endovascular aortic repair on long-term survival in type B aortic dissection. *Ann Thorac Surg* 2018; **105**: 31-8.
- 23) Fattori R, Montgomery D, Lovato L, et al. Survival after endovascular therapy in patients with type B aortic dissection: a report from the International Registry of Acute Aortic Dissection (IRAD). *JACC Cardiovasc Interv* 2013; **6**: 876-82.
- 24) Brunkwall J, Kasprzak O, Verhoeven E, et al. Endovascular repair of acute uncomplicated aortic type B dissection promotes aortic remodeling: 1 year results of the ADSORB trial. *Eur J Vasc Endovasc Surg* 2014; **48**: 285-91.
- 25) Dong Z, Fu W, Wang Y, et al. Stent graft-induced new entry after endovascular repair for Stanford type B aortic dissection. *J Vasc Surg* 2010; **52**: 1450-7.
- 26) Pantaleo A, Jafrancesco G, Buia F, et al. Distal stent graft-induced new entry: an emerging complication of endovascular treatment in aortic dissection. *Ann Thorac Surg* 2016; **102**: 527-32.
- 27) Ray HM, Durham CA, Ocazionez D, et al. Predictors of intervention and mortality in patients with uncomplicated acute type B aortic dissection. *J Vasc Surg* 2016; **64**: 1560-8.
- 28) Nauta FJ, Tolenaar JL, Patel HJ, et al. Impact of retrograde arch extension in acute type B aortic dissection on management and outcomes. *Ann Thorac Surg* 2016; **102**: 2036-43.
- 29) Cambria RP, Conrad MF. Thoracic endovascular aneurysm repair for uncomplicated type B dissection. *J Vasc Surg* 2016; **64**: 1558-9.
- 30) Tolenaar JL, van Keulen JW, Jonker FH, et al. Morphologic predictors of aortic dilatation in type B aortic dissection. *J Vasc Surg* 2013; **58**: 1220-5.
- 31) Tsai TT, Evangelista A, Nienaber CA, et al. Partial thrombosis of the false lumen in patients with acute type B aortic dissection. *N Engl J Med* 2007; **357**: 349-59.
- 32) Onitsuka S, Akashi H, Tayama K, et al. Long-term outcome and prognostic predictors of medically treated acute type B aortic dissections. *Ann Thorac Surg* 2004; **78**: 1268-73.
- 33) van Bogerijen GH, Tolenaar JL, Rampoldi V, et al. Predictors of aortic growth in uncomplicated type B aortic dissection. *J Vasc Surg* 2014; **59**: 1134-43.
- 34) Sailer AM, Nelemans PJ, Hastie TJ, et al. Prognostic significance of early aortic remodeling in acute uncomplicated type B aortic dissection and intramural hematoma. *J Thorac Cardiovasc Surg* 2017; **154**: 1192-200.
- 35) Luebke T, Brunkwall J. Type B aortic dissection: a review of prognostic factors and meta-analysis of treatment options. *Aorta (Stamford)* 2014; **2**: 265-78.
- 36) Schwartz SI, Durham C, Clouse WD, et al. Predictors of late aortic intervention in patients with medically treated type B aortic dissection. *J Vasc Surg* 2018; **67**: 78-84.
- 37) Kamman AV, Brunkwall J, Verhoeven EL, et al. Predictors of aortic growth in uncomplicated type B aortic dissection from the Acute Dissection Stent Grafting or Best Medical Treatment (ADSORB) database. *J Vasc Surg* 2017; **65**: 964-71.e3.
- 38) Sailer AM, van Kuijk SM, Nelemans PJ, et al. Computed tomography imaging features in acute uncomplicated Stanford type-B aortic dissection predict late adverse events. *Circ Cardiovasc Imaging* 2017; **10**: e005709.
- 39) Masuda M, Okumura M, Doki Y, et al. Thoracic and cardiovascular surgery in Japan during 2014: annual report by the Japanese Association for Thoracic Surgery. *Gen Thorac Cardiovasc Surg* 2016; **64**: 665-97.
- 40) Pape LA, Awais M, Woznicki EM, et al. Presentation, diagnosis, and outcomes of acute aortic dissection: 17-year trends from the International Registry of Acute Aortic Dissection. *J Am Coll Cardiol* 2015; **66**: 350-8.
- 41) Shah A, Khoynzhad A. Thoracic endovascular repair for acute type A aortic dissection: operative technique. *Ann Cardiothorac Surg* 2016; **5**: 389-96.
- 42) Ozawa M, Uchida N, Shibamura H, et al. Strategy for acute type IIb aortic dissection associated with abdominal-organ malperfusion. *Japanese Journal of Vascular Surgery* 2006; **15**: 551-8.
- 43) Furuta A, Koide M, Kunii Y, et al. Clinical results of thoracic endovascular aortic repair for acute aortic dissection. *Japanese Journal of Vascular Surgery* 2015; **24**: 945-51.
- 44) Hirst AE Jr, Johns VJ Jr, Kime SW Jr. Dissecting aneurysm of the aorta: a review of 505 cases. *Medicine (Baltimore)* 1958; **37**: 217-79.
- 45) Moon MC, Greenberg RK, Morales JP, et al. Computed tomography-based anatomic characterization of proximal aortic dissection with consideration for endovascular candidacy. *J Vasc Surg* 2011; **53**: 942-9.
- 46) Ronchey S, Serrao E, Alberti V, et al. Endovascular stenting of the ascending aorta for type A aortic dissections in patients at high risk for open surgery. *Eur J Vasc Endovasc Surg* 2013; **45**: 475-80.

- 47) Ye C, Chang G, Li S, et al. Endovascular stent-graft treatment for Stanford type A aortic dissection. *Eur J Vasc Endovasc Surg* 2011; **42**: 787-94.
- 48) Lu Q, Feng J, Zhou J, et al. Endovascular repair of ascending aortic dissection: a novel treatment option for patients judged unfit for direct surgical repair. *J Am Coll Cardiol* 2013; **61**: 1917-24.
- 49) Khojnehzad A, Donayre CE, Bui H, et al. Risk factors of neurologic deficit after thoracic aortic endografting. *Ann Thorac Surg* 2007; **83**: S882-9; discussion, S890-2.
- 50) Ehlert BA, Durham CA, Parker FM, et al. Impact of operative indication and surgical complexity on outcomes after thoracic endovascular aortic repair at National Surgical Quality Improvement Program Centers. *J Vasc Surg* 2011; **54**: 1629-36.