




ELSEVIER

Contents lists available at ScienceDirect

Arthroplasty Today

journal homepage: <http://www.orthroplastytoday.org/>

Original research

Proximal tibial resorption in a modern total knee prosthesis

Justin T. Deen, MD^{*}, Terry B. Clay, MD, Dane A. Iams, MD, MaryBeth Horodyski, EdD, Hari K. Parvataneni, MD

Department of Orthopaedics and Rehabilitation, University of Florida College of Medicine, Gainesville, FL, USA

ARTICLE INFO

Article history:

Received 18 September 2017

Received in revised form

20 October 2017

Accepted 23 October 2017

Available online 6 December 2017

Keywords:

Total knee arthroplasty

Resorption

Classification

Incidence

ABSTRACT

Background: In an effort to minimize backside polyethylene wear and osteolysis associated with titanium tibial baseplates, many manufacturers have transitioned to cobalt chromium alloys. Recent literature has implicated thicker cobalt chromium designs as a potential source of increased stress shielding and resorption. We report the incidence of proximal tibial bone resorption in a large consecutive series of patients undergoing total knee arthroplasty, with a modern total knee design.

Methods: Four hundred thirty-two consecutive primary total knee arthroplasties, performed by 2 fellowship-trained arthroplasty surgeons were identified over a 24-month period. In addition to review of the medical records, analysis of preoperative and postoperative radiographs was performed. Utilizing a novel classification system, the severity of resorption was quantified and correlated with patient and implant characteristics.

Results: After exclusions, 339 knees were evaluated in 292 patients. Mean follow-up was 13.2 months (range 6–41). Resorption was present in 119 knees (35.1%). Average time to diagnosis of bone loss was 6.9 months (range 2–32) postoperatively. There was a statistically significant difference between resorption and nonresorption groups with regards to gender and preoperative alignment. Most cases were classified as Grade 1. During the study period, 2 patients required revision for aseptic tibial loosening.

Conclusions: Our findings suggest that proximal tibial resorption is common with this particular implant, particularly in men and patients with preoperative varus deformity. Although this typically occurs relatively early in postoperative period and in most cases appears to remodel and stabilize, its ultimate clinical significance and effect on implant survivorship remains unclear.

© 2017 The Authors. Published by Elsevier Inc. on behalf of The American Association of Hip and Knee Surgeons. This is an open access article under the CC BY-NC-ND license (<http://creativecommons.org/licenses/by-nc-nd/4.0/>).

Introduction

Total knee arthroplasty (TKA) is a historically successful operation with excellent outcomes [1–3]. However, despite advances in modern implant manufacturing and design, issues with polyethylene (PE) wear still plague long-term survivorship [4,5]. Long-term PE particles can be associated with osteolysis, implant

loosening, and fracture. In addition to the primary bearing surface, the articulation between the tibial baseplate and PE liner, or so-called “backside wear,” has also been cited as a source of wear particles that induce osteolysis [6–8].

In an effort to address issues with backside wear in total knee implants, many manufacturers have transitioned from titanium baseplates to more scratch-resistant, highly polished cobalt chromium (CoCr) designs. However, with different metallurgy comes different mechanical properties. CoCr designs are inherently more rigid and are often thicker than their titanium counterparts. Stress shielding is a well-recognized phenomenon following TKA, with most previous studies using computed tomography or dual X-ray absorptiometry data to describe more subtle preferential loss of cancellous bone [9–11]. However, 2 recent studies have implicated these designs in more dramatic proximal tibial bone loss [12,13].

One or more of the authors of this paper have disclosed potential or pertinent conflicts of interest, which may include receipt of payment, either direct or indirect, institutional support, or association with an entity in the biomedical field which may be perceived to have potential conflict of interest with this work. For full disclosure statements refer to <https://doi.org/10.1016/j.artd.2017.10.005>.

^{*} Corresponding author. PO Box 112727, Gainesville, FL 32611, USA. Tel.: +1 352 273 7001.

E-mail address: deenjt@ortho.ufl.edu

<https://doi.org/10.1016/j.artd.2017.10.005>

2352-3441/© 2017 The Authors. Published by Elsevier Inc. on behalf of The American Association of Hip and Knee Surgeons. This is an open access article under the CC BY-NC-ND license (<http://creativecommons.org/licenses/by-nc-nd/4.0/>).

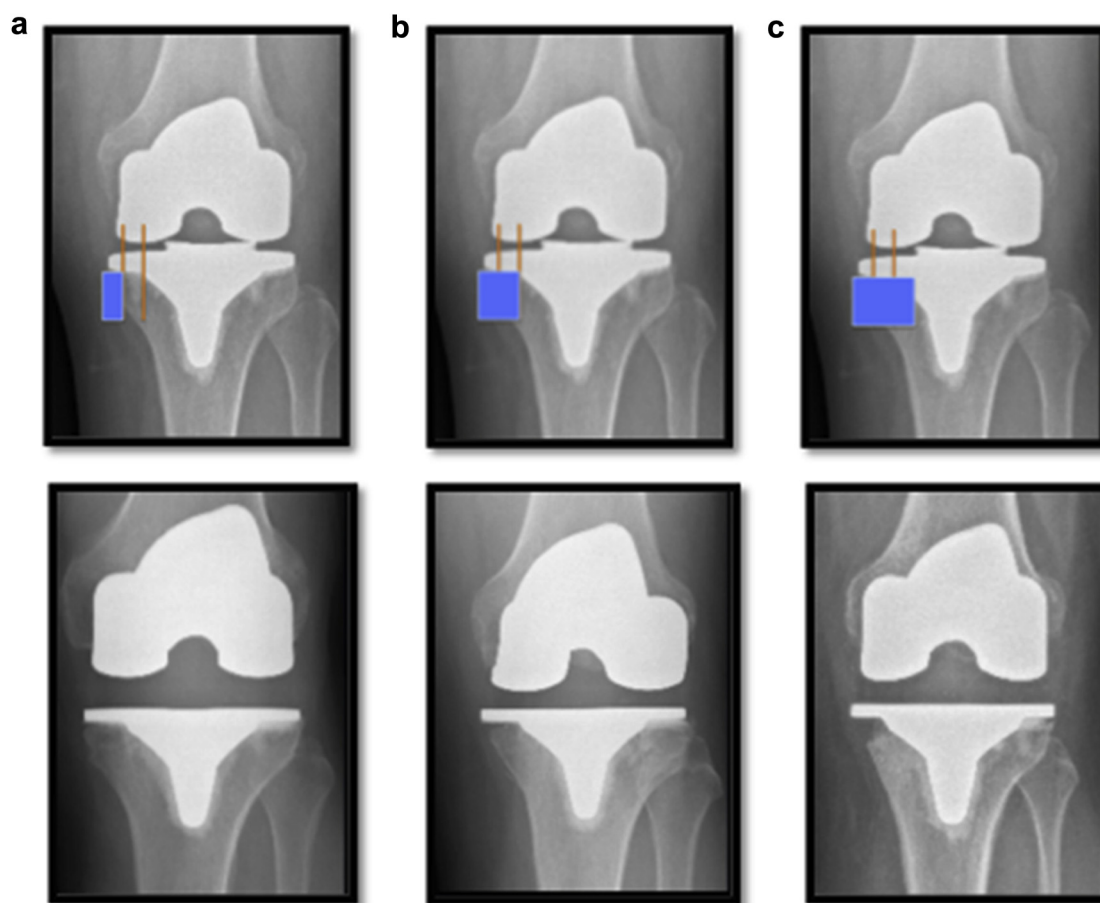


Figure 1. Classification system. (a) Grade 1: Resorption to the level of the baseplate (including any prior uncovered bone) up to 50% of the width of the tray. (b) Grade 2: Resorption beyond 50% but not to the keel. (c) Grade 3: Resorption to/beyond the level of the keel.

With anecdotal concerns from the senior authors, and recent questions about the effect of CoCr designs on proximal tibial bone loss, we sought to evaluate our institutional experience with a single modern total knee implant that utilizes CoCr tibial baseplate. Our primary goal is to calculate an overall incidence of proximal tibial bone loss, classify such bone loss in a way that could be easily reproducible, and identify any patient or implant characteristics that are associated with its occurrence. To our knowledge, this is the first large radiographic study to investigate the incidence of proximal tibial bone loss in a specific implant, and the first to attempt to classify its severity.

Material and methods

Following Institutional Review Board approval, the surgical cases of 2 experienced, fellowship-trained arthroplasty surgeons were reviewed from October 2013 to October 2015. Four hundred thirty-two consecutive primary TKAs were identified. Patients were then limited to those receiving a cemented DePuy Attune (Warsaw, IN) total knee prosthesis. This system utilizes a 4-mm thick cobalt-chromium-molybdenum alloy tibial baseplate with a rounded stem design. Those patients with fewer than 6 months of radiographic follow-up were excluded. Other exclusions included prior surgery altering the patient's lower extremity alignment (ie, high tibial osteotomy, open reduction internal fixation, etc.) and those with postoperative infection. Operative reports and clinical notes were then reviewed to obtain patient demographic data and body mass index (BMI), as

well as implant sizes, bearing platform, complications, and/or reoperations.

Formal radiographic analysis was then performed. Per our institutional protocol, standing anteroposterior and lateral radiographs of the knee were obtained at the patients' preoperative visit, as well as their 6-week, 6-month, and 12-month postoperative visits. If there was additional follow-up, these radiographs were reviewed as well. All radiographs were identified and reviewed by a single observer independent of the surgeons. Quality of the anteroposterior image was considered acceptable if the posterior femoral condyles were not visible and there was approximately 45%–55% overlap between the lateral tibia and fibular head.

For each radiograph, lower extremity alignment was calculated by measuring the angle formed by the anatomic axes of the femur and tibia. Patients were then stratified into 3 groups: varus (any degree of varus alignment), neutral (0° – 7° of valgus), and valgus ($>7^{\circ}$ of valgus). In addition, the anatomic lateral distal femoral angles and medial proximal tibial angles were calculated for each patient.

If present, proximal tibial bone loss was identified and quantified/classified based on a novel system as shown in Figure 1. Grade 1 resorption was defined as bone loss to the level of the baseplate (including any uncovered bone) up to 50% of the width of the tray. Grade 2 was defined as bone loss beyond 50% of the width of the tray, but not to the level of the keel. Grade 3 involved bone loss to/beyond the level of the keel. The point in time at which the bone loss was first identified was recorded, and if later

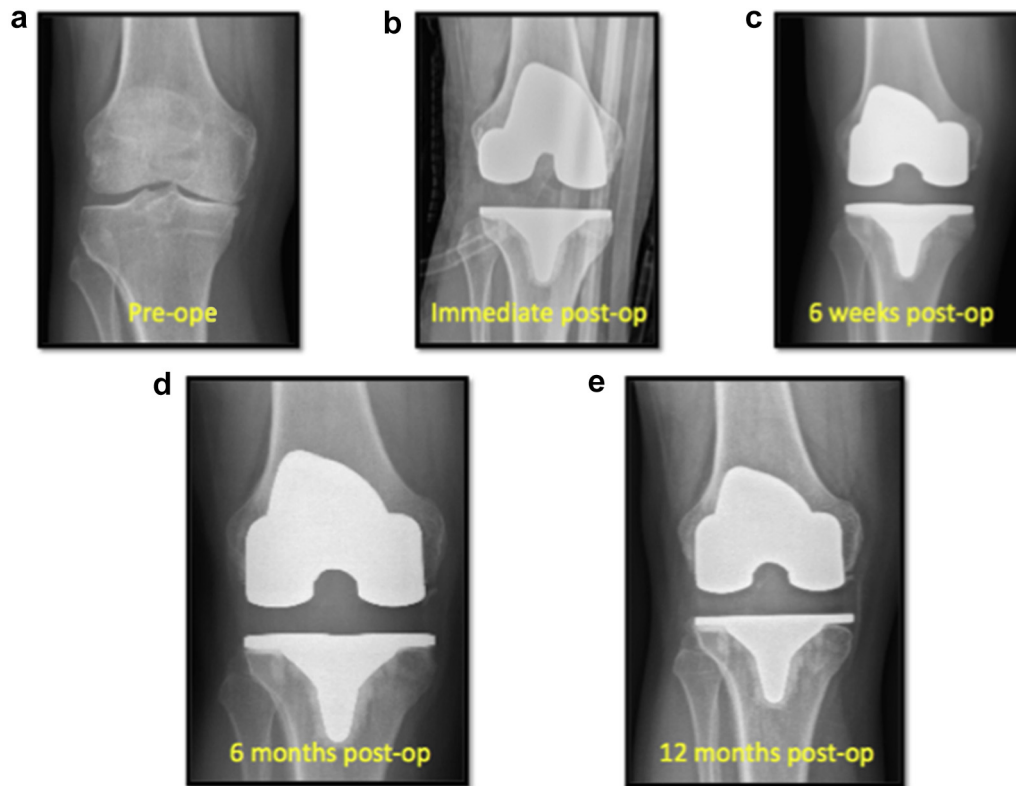


Figure 2. Case Example 1. Patient is a 50-year-old male who underwent a right primary total knee arthroplasty. Preoperative and immediate postoperative images are shown revealing correction of his previous varus deformity (a,b). Radiographs from his 6-week (c), 6-month (d), and 12-month postoperative visits (e) show development of Grade 1 resorption at 6 months, with progression to Grade 2 at 12 months.

follow-up was available these radiographs were critically evaluated to assess for any evidence of progression or change in implant position.

Statistical analysis was performed utilizing SPSS v24 (Chicago, IL). Analysis of variance was used to identify differences in continuous data, and chi-squared for differences in categorical data. Differences were considered to be statistically significant if the *P*-value was $<.05$.

Results

After review of surgical cases, 432 knees were identified. Eighty-four knees were excluded due to inadequate follow-up, 7 due to previous open surgery, and 2 due to inadequate radiographs. After exclusions, 339 knees (in 292 patients) were included in the study. One surgeon performed 277 TKAs, and the other performed 62. The average age of the patients was 66.6 years (range 36–95), and average BMI was 31.7 (range 19.1–49.9). Mean follow-up was 13.2 months (range 6–41).

There were 192 (56.6%) knees in the varus group, with a mean preoperative alignment of 4.1° . There were 93 (27.4%) knees in the valgus group, with a mean preoperative alignment of 12.5° . An additional 54 (15.9%) knees were classified as neutral, with an average preoperative alignment of 2.8° of valgus.

Two hundred seventy-seven (81.7%) implants were a fixed bearing design, and 62 (18.3%) were a rotating platform mobile bearing design.

At most recent follow-up, 119 of 339 knees showed some degree of proximal tibial resorption, for an incidence of 35.1%. The incidence for each surgeon was 36.1% and 30.6%, respectively. The average time to radiographic diagnosis was 6.9 months (range 2–

32) postoperatively. Serial clinical radiographs from an example patient are shown in Figure 2. The distribution of bone loss by grade is shown in Figure 3. Grade 1 occurred in 65 patients (54.6%), Grade 2 in 44 patients (37.0%), and Grade 3 in 10 patients (8.4%). It should be noted that these are grades at initial diagnosis. Preoperative varus alignment was present in 38 of 44 (86%) patients with Grade 2 resorption, and all those with Grade 3 resorption (see Fig. 4).

Comparative analysis between the resorption and nonresorption groups is shown in Table 1. There was no statistically significant difference between the resorption and nonresorption groups with regards to age or BMI. However, there was a significant difference between groups for preoperative alignment and gender. One hundred

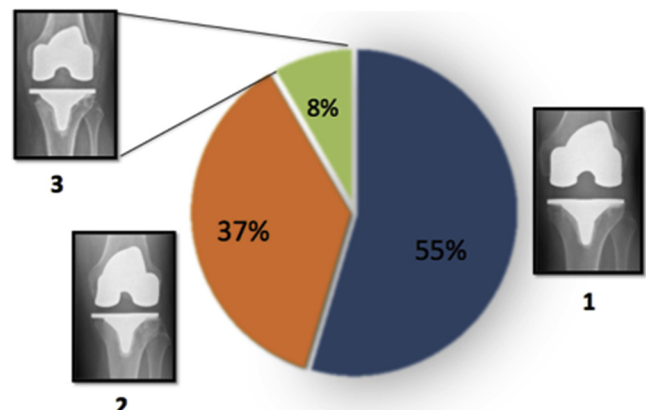


Figure 3. Resorption by grade.

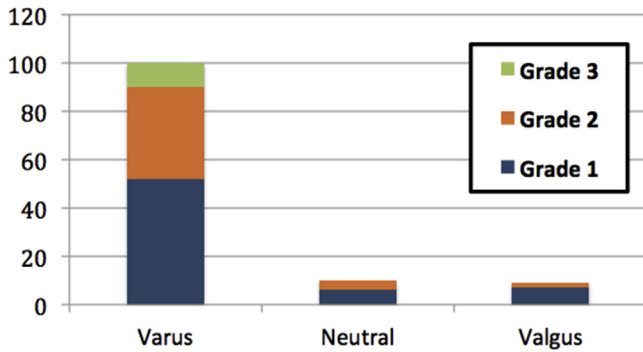


Figure 4. Resorption by alignment.

of the 119 patients (84%) who developed resorption had a preoperative varus alignment ($P \leq .001$). This represented 52.1% of the varus cohort. In addition, while overall there were more female patients with resorption, there were a larger proportion of men than women ($P = 0.01$). With regards to bearing platform, while there was a higher incidence in the rotating platform group, this did not reach statistical significance ($P = 0.08$).

There were 73 patients in the resorption cohort with radiographic follow-up beyond their initial diagnosis, 24 (32.8%) of which showed progression in resorption grade. Of these, 20 (83.3%) had a preoperative varus alignment. Reoperations as well as indications are listed in Table 2. Two patients in the resorption group required revision for aseptic loosening and subsidence of the tibia. Of note, both patients were male with preoperative varus alignment. Serial radiographs from another example patient are shown in Figure 5.

Discussion

Although stress shielding is a common phenomenon following TKA, very few studies have evaluated proximal tibial bone loss in relationship to preoperative alignment, and none have provided a method of classifying it when it occurs. We report the incidence of bone resorption in the first radiographic study evaluating a large consecutive series of patients undergoing TKA utilizing a modern CoCr tibial baseplate design. In addition, we illustrate a novel, simple system for quantifying/classifying bone loss.

At an average follow-up of 13 months, our incidence of resorption was 35.1%. Despite similar age and BMI, there was a significantly higher percentage of cases in male patients and those with preoperative varus alignment. In fact, 84.0% of the cases occurred in those with preoperative varus. In a previous report comparing a Titanium, All-polyethylene, and CoCr tibial design, Martin et al [12] reported that 28 of 50 (56.0%) patients in the CoCr

Table 2
Revisions.

Indication for revision	Resorption present (n = 119)	Resorption absent (n = 220)
Aseptic tibial loosening	2	0
Infection	1	4
Patellar clunk	2	3
Stiffness	1	3
Instability	1	0

cohort showed some form of bone loss. All the patients in their study had a preoperative varus alignment. This is similar to our findings, in which 52.1% of the patients in the varus cohort showed radiographic bone loss.

In conjunction with previous studies [10-13], we believe that the medial tibial bone loss in this cohort is likely multifactorial. First, correcting alignment in patients with preoperative varus offloads the previous stresses on the medial side of the proximal tibia. Additionally, balancing varus knees typically involves substantial proximal medial tibial subperiosteal stripping. This could potentially result in a variable degree of boney devascularization not otherwise seen in nonvarus aligned knees. Finally, CoCr baseplates are more rigid, and this increased modulus mismatch further shields the native bone.

In addition, tray thickness can further contribute to stress shielding. In another study by Martin et al [13] comparing 2 CoCr baseplates of differing thicknesses, they found that patients with a thick tray had a 7 times higher increased risk of proximal tibial bone loss. Interestingly, the implant evaluated in our study was the same implant in the “thick tray” group.

Finally, while bone loss has been seen in other CoCr trays, we cannot exclude that this phenomenon is due to implant design. At least 1 additional study has reported early reductions in proximal tibial bone density with this particular baseplate. Munro et al [10] reported a randomized study of CT data evaluating bone density in patients at 1 and 2 years following TKA utilizing 2 different tibial designs, 1 of which was used in our study. They found reductions in bone density in both implants, but did not evaluate preoperative alignment. In addition, Au et al [11] described how altered bone or implant condylar surface geometry and load pattern created by implants are at least as important or, in some cases, more important factors in observed stress shielding immediately after operation. This would require additional investigation.

Previous studies have attempted to quantify bone loss in millimeters based on plain radiographic measurements. However, this is highly dependent on rotation, magnification, and calibration. Our method, while similar but distinct from the roentgenographic scoring system proposed by Ewald [14], is based on relationship to the implant itself and can theoretically be used for all designs, regardless of variations in image quality.

Our study is not without limitations. First, the average follow-up was relatively short. However, even at just over 1 year we still identified a significant percentage of patients with bone loss. Although in most cases the resorption remodeled and stabilized, approximately one-third of cases showed some form of progression in severity, nearly all of which were varus knees. Although 2 patients required revision for aseptic loosening, we cannot comment on effects on long-term survivorship. Second, while we did investigate incidence of revision, no functional or reported outcomes were obtained. Finally, this purely radiographic observation is based on standard knee views, which are chronologically spaced out according to our institutional protocols. Although each was evaluated for quality, radiographic measurements were based on anatomic axis as opposed to mechanical axis measurements from

Table 1
Comparative analysis.

Mean (SD)	Resorption present (n = 119)	Resorption absent (n = 220)	P-value
Mean age (y)	65.9 (9.2)	67.1 (8.8)	.23
Mean BMI	31.6 (5.7)	31.7 (6.3)	.87
Gender	Male: 77 Female: 62	Male: 58 Female: 142	.02
Preoperative alignment	Varus: 100 Neutral: 10 Valgus: 9	Varus: 92 Neutral: 44 Valgus: 84	<.001
Bearing platform	Fixed: 91 Rotating: 27	Fixed: 186 Rotating: 35	.08

SD, standard deviation.

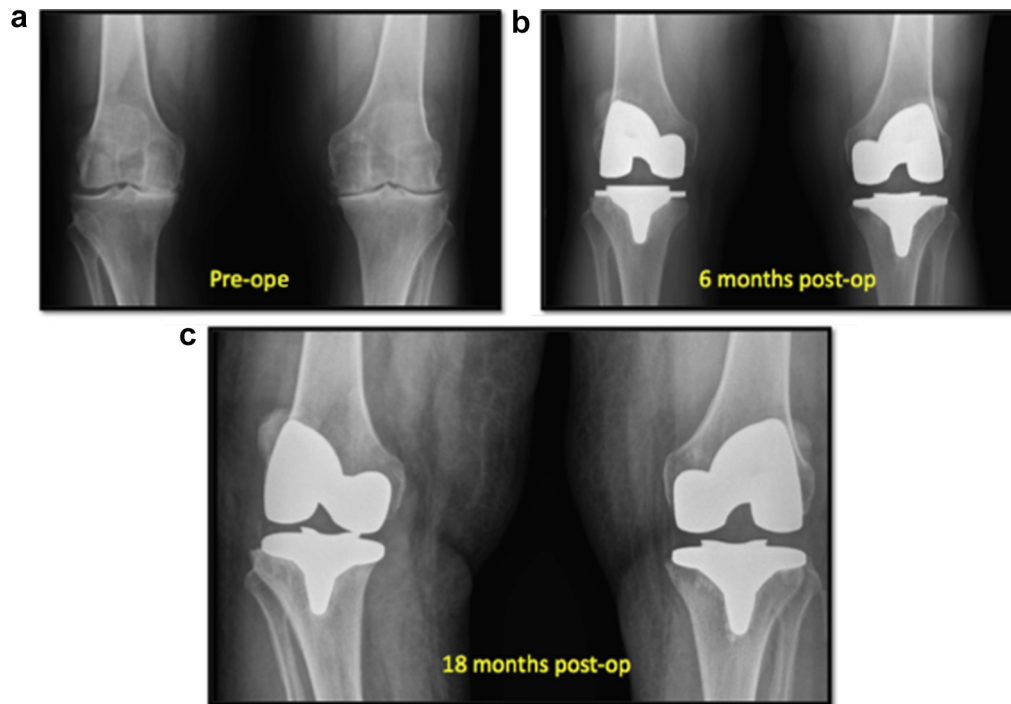


Figure 5. Case Example 2. Patient is a 62-year-old male who underwent staged, bilateral primary total knee arthroplasties separated by approximately 6 weeks (left then right) (a). At his second postoperative visit, Grade 2 resorption was noted on the right (b). He presented 1 year later with loosening and varus collapse (c).

formal hip-knee-ankle radiographs. However, the use of anatomic axis on limited radiographs has been validated as an estimate of full-length films [15]. In addition, while the average time to diagnosis was approximately 6 months, it is difficult to identify more specifically when this process first occurs based on the standard timing of the radiographs.

Conclusions

Our findings suggest that proximal tibial resorption is common in this particular implant, especially in men and patients with preoperative varus alignment. Although this typically occurs relatively early in postoperative period and in most cases appear to remodel and stabilize, its ultimate clinical significance and effect on implant survivorship remains unclear.

References

- [1] Fitzgerald JF, Heck DA, Kennedy JM, et al. Tricompartmental knee replacement. A comparison of orthopaedic surgeons' self reported performance rates with surgical indications, contraindications, and expected outcomes. Knee replacement patient outcomes research team. *Clin Orthop Relat Res* 1994;(305):209.
- [2] Drake BG, Heck DA, Dittus RS. Patient outcomes following tricompartmental total knee replacement. A meta-analysis. *JAMA* 1994;271:1349.
- [3] Joshi AB. Long-term results of cemented, posterior cruciate ligament-retaining total knee arthroplasty in osteoarthritis. *Am J Knee Surg* 2001;14:209.
- [4] Schroer WC, Berend KR, Lombardi AV, et al. Why are total knees failing today? Etiology of total knee revision in 2010 and 2011. *J Arthroplasty* 2013;28(8 Suppl):116.
- [5] Sharkey PF, Lichstein PM, Shen C, Tokarski AT, Parvizi J. Why are total knee arthroplasties failing today—has anything changed after 10 years? *J Arthroplasty* 2014;29(9):1774.
- [6] Wasielewski RC, Parks N, Williams I, et al. Tibial insert undersurface as a contributing source of polyethylene wear debris. *Clin Orthop Relat Res* 1997;(345):53.
- [7] Parks NL, Engh GA, Topoleski LD, Emperado J. The Coventry Award. Modular tibial insert micromotion. A concern with contemporary knee implants. *Clin Orthop Relat Res* 1998;(356):10.
- [8] Engh GA, Ammeen DJ. Epidemiology of osteolysis. Backside implant wear. *Instr Course Lect* 2004;53:243.
- [9] Innocenti B, Truyens E, Labey L, et al. Can medio-lateral baseplate position and load sharing induce asymptomatic local bone resorption of the proximal tibia? A finite element study. *J Orthop Surg Res* 2009;4:26.
- [10] Munro JT, Pandit S, Walker CG, Clatworthy M, Pitto RP. Loss of tibial bone density in patients with rotating- or fixed-platform TKA. *Clin Orthop Relat Res* 2010;468:775.
- [11] Au AG, James Raso V, Liggins AB, Amirfazli A. Contribution of loading conditions and material properties to stress shielding near the tibial component of total knee replacements. *J Biomech* 2007;40:1410.
- [12] Martin JR, Watts CD, Levy DL, Kim RH. Medial tibial stress shielding: a limitation of cobalt chromium tibial baseplates. *J Arthroplasty* 2017;32(2):558.
- [13] Martin JR, Watts CD, Levy DL, et al. Tibial tray thickness significantly increases medial tibial bone resorption in cobalt–chromium total knee arthroplasty implants. *J Arthroplasty* 2017;32(1):79.
- [14] Ewald FC. The Knee Society total knee arthroplasty roentgenographic evaluation and scoring system. *Clin Orthop Relat Res* 1989;248:9.
- [15] Tipton SC, Sutherland J, Schwarzkopf R. Using the anatomical axis as an alternative to the mechanical axis to assess knee alignment. *Orthopedics* 2015;38(12):e1115.