

ARTICLE

Radionuclides in the management of thyroid cancer

J.R. Buscombe

Nuclear Medicine, Royal Free Hospital, London, NW3 2QG, UK

*Corresponding address: Dr John Buscombe, Nuclear Medicine, Royal Free Hospital, Pond Street, London, NW3 2QG, UK.
Email: j.buscombe@medsch.ucl.ac.uk*

Date accepted for publication 17 October 2007

Abstract

Nuclear medicine imaging was born over 60 years ago with imaging of thyroid conditions. Most of our present imaging devices were developed for imaging of the thyroid and thyroid cancer. Millions of patients in over 100 countries have been diagnosed and treated for thyroid cancer using nuclear medicine techniques. It remains, however, one of the most dynamic areas of development in nuclear medicine with new roles for positron emission tomography and receptor based imaging. In addition to this is research into combinations of genetic therapy and radioisotopes and receptor based therapy using beta emitting analogues of somatostatin. Despite the use of ultrasound computed tomography and magnetic resonance, nuclear medicine techniques remain central to both imaging and therapy in thyroid disease and the field has recently become one of the most dynamic within the specialty.

Keywords: *Thyroid disease; ^{131}I ; somatostatin receptor imaging and therapy; PET.*

Introduction

Differentiated thyroid cancer (DTC), though not the commonest of cancers, remains one of the cancers that we are keen to identify, stage and treat as even in its most advanced state cures though unlikely are possible. A range of radiopharmaceuticals have been used in the management of thyroid cancer over the past 60 years (Table 1) and in this review their present usage is assessed.

The initial diagnosis of thyroid cancer can be made by a combination of clinical history, palpation and ultrasound; fine needle aspiration nuclear imaging may be used but under present guidelines thyroid scintigraphy is not indicated as a primary investigation of suspected thyroid cancer^[1]. However, most large centres performing isotopic thyroid studies will find 1–2 incidental thyroid cancers a year on the pre-treatment scan performed on patients with hyperthyroidism using ^{123}I or $^{99\text{m}}\text{Tc}$ pertechnetate. These cancers will appear as a cold nodule but this appearance is very non-specific (Fig. 1). A cold nodule on a functional thyroid scan is normally benign with reported rates of malignancy varying from 5 to 20%^[2–4]. So whilst it requires further investigation often ultrasound will suffice as these cold nodules are normally cysts.

The next major role of nuclear medicine has been after surgery with whole body imaging and post surgery ablation of thyroid tissue with ^{131}I . This often seems a paradox. How is it that thyroid cancer is negative on a diagnostic thyroid cell but positive on a whole body ^{131}I scan? The reason is that the whole body ^{131}I images are performed 48–72 h after administration of the radiotracer allowing cells with poor uptake, e.g. cancer cells enough time to accumulate the radioiodine. When performing local imaging, the non-cancerous normal thyroid cells take up the radioiodine or pertechnetate at a much higher rate so the cancer appears as a defect.

^{131}I whole body imaging

The standard methods for imaging patients with differentiated thyroid cancer is to perform whole body imaging with ^{131}I . This has normally been done with a small ‘tracer dose’ of about 150–185 MBq of ^{131}I given orally and then imaged 48–72 h later. To ensure good uptake of the ^{131}I the patient should be prepared by withdrawal of thyroid replacement therapy (4 weeks is required for thyroxine) and the patient is often asked to take a low iodine diet avoiding fish and other sea foods. The count rates obtained from ^{131}I imaging are

Table 1 Radiopharmaceuticals used in thyroid cancer

Radiopharmaceutical	Radiation emission	Clinical utility
^{131}I	Gamma, beta	Imaging thyroid nodules ^a Whole body imaging to stage DTC Post operative ablation of thyroid remnant Treating metastatic DTC
^{123}I	Gamma	Imaging thyroid nodules Whole body imaging to stage DTC
$^{99\text{m}}\text{Tc}$]pertechnetate	Gamma	Imaging thyroid nodules Imaging local metastases ^b
$^{99\text{m}}\text{Tc}$]MDP	Gamma	Identify bone metastases
^{124}I	Positron	Whole body imaging to stage DTC ^b
^{111}In]pentetreotide	Gamma	Somatostatin receptor imaging in DTC and MCT
^{123}I]mIBG	Gamma	Amine uptake imaging in MCT
$^{99\text{m}}\text{Tc}$]DMSA(V)	Gamma	Staging of MCT
^{18}F]FDG	Positron	Staging of DTC and MCT ^b
^{201}Tl	Gamma	Characterisation of thyroid nodule ^a
$^{99\text{m}}\text{Tc}$]sestamibi	Gamma	Characterisation of thyroid nodule ^a Staging of DTC
^{131}I]mIBG	Gamma, beta	Staging of MCT ^a Treating mIBG positive metastatic MCT
^{90}Y]octreotide/tate	Beta	Treating ^{111}In]pentetreotide positive MCT ^b Treating ^{111}In]pentetreotide positive, ^{131}I negative DTC

DTC, differentiated thyroid cancer; MDP, methyl di-phosphosphate; MCT, medullary cell cancer of the thyroid; DMSA, dimercaptosuccinic acid; FDG, fluorodeoxyglucose; mIBG, *meta*-iodobenzyl guanidine.

^aNo longer used routinely.

^bExperimental.

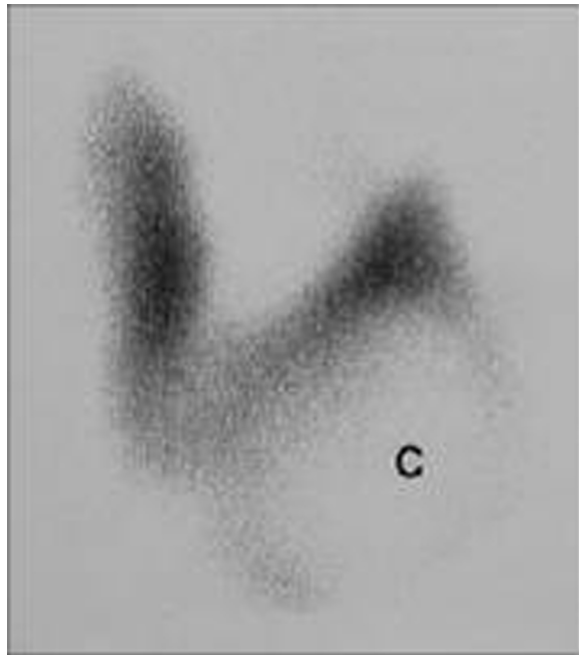


Figure 1 Large 'cold nodule' marked 'c' replacing and displacing the lower pole of the left lobe of the thyroid in a 55-year-old woman. Subsequent ultrasound and fine needle aspiration confirmed a simple colloid cyst.

often poor and images less than ideal quality. This is partly due to the fact that ^{131}I gives off a variety of different gamma rays with different energies resulting in scatter but the high energy gamma photons up to 580 keV need a high energy collimator which blocks

about 95% of the counts coming from the patient. In such circumstance the administered activity of the radiopharmaceutical would be increased however, it is normal practice when there is any evidence of residual thyroid tissue or cancer to give a therapeutic dose of ^{131}I within 2–3 days. This is done so that the patient does not need to withdraw from thyroid replacement again. There is now clear evidence that administration of too high an activity of ^{131}I given for imaging damages the thyroid cancer cells in such a way that they have reduced uptake of the therapeutic dose of ^{131}I in up to 80% of cases; a process known as stunning^[5,6]. There is some evidence that stunning may occur with activities of ^{131}I as low as 74 MBq at which point image quality is very poor^[7].

An alternative approach has been to assume that all patients post thyroidectomy will need ^{131}I ablation and plan to give a 3 GBq ablative activity 6 weeks after surgery (Figs. 2 and 3) withdrawing lio-thyronine 2 weeks before therapy. If there is no uptake on the post therapy scan no more ^{131}I is given; however, if there is activity then treatment with 5 GBq of ^{131}I is given until the post therapy scan is clear^[8]. Whilst there is some concern that the patient may receive an unnecessary radiation dose, it has also been suggested that a dose of ^{131}I given when the subsequent scan is negative may be treating sub-1 cm tumours not visible on the scan^[9]. Once the patient is ablated they can be followed by plasma levels of thyroglobulin.

Other imaging modalities that can be used include chest X-ray, and computed tomography (CT) of neck,

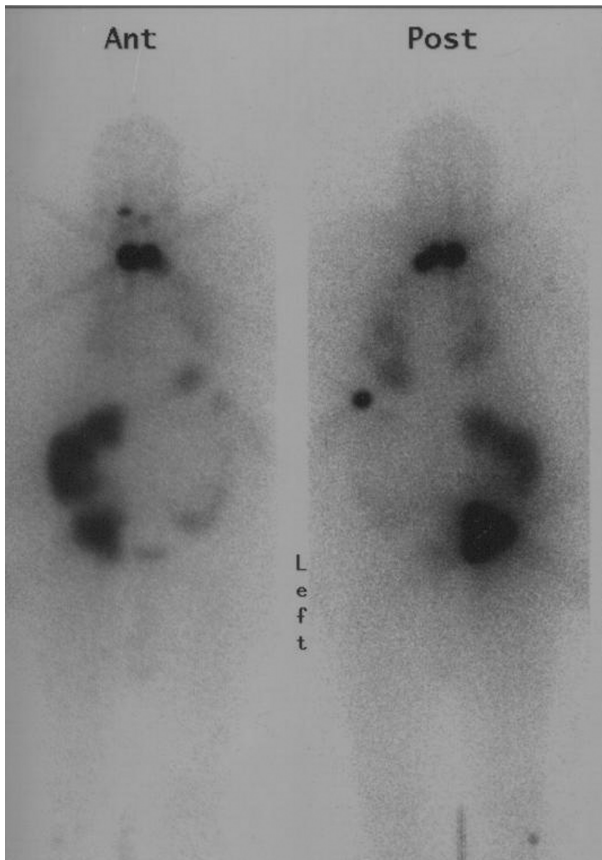


Figure 2 Anterior and posterior whole body images performed 48 h after administration of 5 GBq of ^{131}I therapy. Note some stomach and colonic activity is seen but all other sites are metastatic papillary thyroid cancer.

chest and abdomen which must be performed without contrast so is of limited use. There is at present no consensus on when and how newer contrast agents with faster clearance can be used. In addition, magnetic resonance imaging (MRI) of neck, spin and liver and ultrasound of liver and neck and bone scintigraphy are often performed. These other techniques tend to be used when there is evidence of disease not seen on the ^{131}I scan or confirm the site of abnormality seen on the ^{131}I scan.

Ablative therapy

The aim of ablative therapy is to remove all thyroidal tissue both benign and malignant so that the patient can be followed by serial plasma thyroglobulin levels. Data from over 40 years show that in all but stage 1 tumours there is a progression and overall survival benefit from ablation but this is only apparent 10–25 years after surgery^[10]. There is, however, some discussion on the activity of ^{131}I needed for ablation with some observers stating that this could be achieved with activities much lower than the standard 3 GBq^[11]. To attempt to answer this question, the British National Cancer Research Network (NCRN) Head and Neck group have facilitated a national prospective randomized controlled trial comparing high and low activity ablative doses of ^{131}I . It is hoped that this study called the 'HiLo' study will report in 2009–2010.

Recombinant TSH/transgenic changes

To ensure adequate uptake of ^{131}I into tumour cells that often have reduced iodine trapping it is necessary to remove any competition for the cell membrane sodium

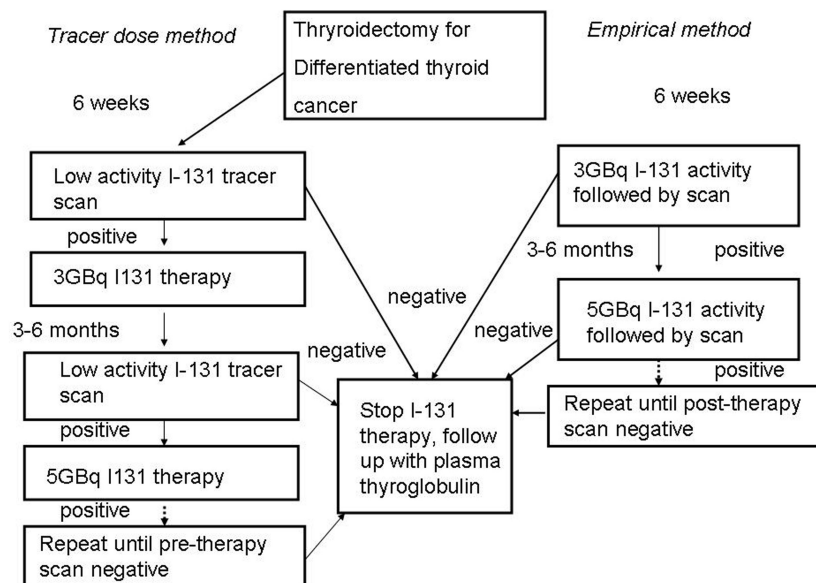


Figure 3 Two approaches to ablation and treatment of thyroid remnant and metastases.

iodide symporter (NIS). Some variants such as Hurtle cell tumour have poor uptake of radioiodine in almost all cases. Therefore excess iodine (the most common source being CT contrast) should be avoided for at least 6 months. In addition the cells need to be stimulated by high levels of thyroid stimulating hormone (TSH) The normal method to do this and obviously the cheapest is withdrawal of thyroid replacement therapy started after thyroidectomy for at least 4 weeks. Though it may be possible to cover the first 2 weeks of this withdrawal with lio-thyronine, the aim of the exercise is to make the patient profoundly hypothyroid. This can be very unpleasant and for the more elderly patient with cardiac disease it can lead to a significant cardiac event^[12]. Uptake of ¹³¹I can also be assisted by administration of thyrotrophin releasing hormone (TRH) which induces additional TSH release from the pituitary 30–60 min before giving the ¹³¹I^[13].

More recently recombinant human TSH (rhTSH) has become available and pre-administration 48 and 24 h before giving the radiotracer can result in similar uptake of ¹³¹I into the tumour tissues as 4 weeks of thyroxine withdrawal^[14,15]. There are clear advantages that the patient does not have to have the symptoms of hypothyroidism or the cardiac risks. The only significant drawback is that the treatment costs about £1000 (€1500).

In some patients there may be very poor or little uptake of radioiodine. This could be because the cells no longer express the NIS gene. This is probably a defensive mechanism for cells exposed to non-lethal levels of radioiodine and those that survive may be those that do not take up the radioactive tracer^[16]. There is some evidence, however, that the NIS gene expression can be stimulated by pre-medication with lithium or retinoids^[13,17,18] but so far there remains no clear consensus on their use and they have not entered general usage. In addition to this, there is some interesting pre-clinical work looking at viral vectors to try and re-transfect these cells with the NIS gene^[19]. Whether or not any of this technology will find a clinical role remains unclear. In addition, the use of NIS gene transfection may in itself increase tumour retention of ¹³¹I and this requires organification which is controlled by a different gene.

123I

As the main role for whole body imaging is to determine if there is sufficient thyroid tissue to need further ablation by ¹³¹I, it may be possible to use an isotope of iodine without beta emission and therefore reduce the risk of blunting. ¹²³I, a cyclotron produced isotope of iodine with a 13-h half life and a pure gamma emission photon of 167 keV has been used for thyroid imaging for over 25 years. However, recently it has also been introduced for whole body imaging^[20]. As there are no beta or high energy gamma emissions, there is improved dosimetry, which means that sufficient ¹²³I (about 100 MBq) can

be administered to ensure a good count rate at 24 h. This can improve image quality as well as prevent stunning. As most gamma cameras are optimized for lower energy isotopes, such as ^{99m}Tc, single photon emission-computed tomography (SPECT) is often easier with ¹²³I than ¹³¹I as a higher count rate can be achieved and SPECT is very count dependent. This should improve the accuracy of the imaging further. The advantages of ¹²³I are such that in our practice we no longer perform ¹³¹I whole body images pre-¹³¹I therapy. Like ¹³¹I, imaging with ¹²³I can be enhanced by pre-administration of rhTSH^[21]. The disadvantage is cost as ¹²³I is up to 5 times greater in price than ¹³¹I.

Positron emission tomography (PET)

Despite the advances in imaging that are obtained with use of ¹²³I, there will be a cohort of patients in whom there is biochemical evidence of residual thyroid cancer by a raised and rising thyroglobulin level but no active disease can be found by ¹³¹I whole body imaging. If CT and MR are unhelpful then [¹⁸F]fluorodeoxyglucose positron emission tomography ([¹⁸F]FDG PET) has been used. One advantage of [¹⁸F]FDG PET is that as it reflects tumour metabolism and not iodine uptake, thyroid replacement hormones do not need to be stopped though recent evidence suggests that enhanced uptake of [¹⁸F]FDG can occur as the TSH is elevated^[22]. The use of rhTSH pre [¹⁸F]FDG PET is being investigated^[23].

Using PET-CT it is possible to not only identify any abnormal sites of activity suggestive of metastatic disease but to localize the site of any abnormality which will aid biopsy, surgery or radiotherapy and these tumours tend to be chemo-resistant and only local treatments are effective. Though few studies have been performed, the accuracy of [¹⁸F]FDG in thyroid cancer is as high as 95% and in particular for those tumours that have de-differentiated and are therefore ¹²³I/¹³¹I negative^[24–28]. Incidentally, [¹⁸F]FDG PET-CT can also be used in anaplastic thyroid cancer but its clinical utility is doubtful in view of the dismal prognosis of the anaplastic variant.

It may also be possible to use ¹²⁴I, a positron emitter, but there is as yet little evidence that this is not just a more expensive way to image with radioiodine and no clear clinical advantage has been shown^[29].

A footnote to the [¹⁸F]FDG PET story in thyroid cancer is that both benign and malignant growths can be very glucose avid. As a consequence as more patients undergo [¹⁸F]FDG imaging for other disease, serendipitous uptake in the thyroid may be seen (Fig. 4). These should be investigated. It is difficult to know how many such nodules are seen on PET but last year we found 2 previously unknown thyroid cancers in the 500 patients we sent for [¹⁸F]FDG PET imaging so a big centre performing 2500 PET scans a year can expect to find approximately 10 previously unknown thyroid cancers. In addition to this will be the occasional cancer

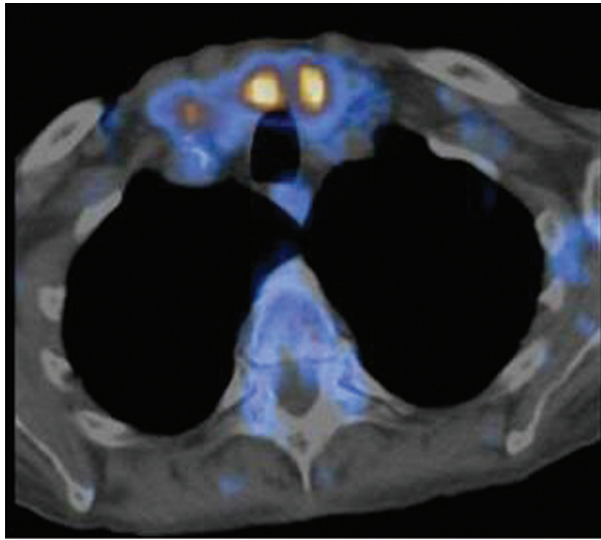


Figure 4 Fused [^{18}F]FDG PET-CT images in a patient with renal cancer showing two areas of uptake of tracer in the right and left lobes of the thyroid; subsequent investigation showed these to be nodules in a multi-nodular goitre.

metastases in the thyroid and thyroid lymphoma. All this means that all sites of unexpected thyroid uptake of [^{18}F]FDG must be fully investigated.

Metabolic imaging single photon

Though PET imaging provides probably the best functional imaging modality to assess cancer patients, there are still significant issues related to access and cost of these techniques. Therefore other simple single photons techniques have been developed and used historically in assessment of thyroid cancers. As thyroid cancers tend to have a higher metabolic turnover than normal tissues tracers such as [^{201}Tl]- and [$^{99\text{m}}\text{Tc}$]sestamibi have been used in two scenarios. First, scintigraphic assessment of the cold nodule. If a thyroid cold nodule has uptake of [^{201}Tl]- or [$^{99\text{m}}\text{Tc}$]sestamibi, the chance of malignancy rises from 5% to 60%^[30–32]. Also it was used in finding tumours in the scenario of raised thyroglobulin and negative ^{131}I scan but has really been superseded by PET techniques.

There may still, however, be a role for ^{67}Ga citrate in identification of thyroid lymphoma where diffuse uptake throughout the gland is diagnostic, though this is more likely to be a finding in a patient imaged for another reason such as fever of unknown cause.

Somatostatin imaging

Somatostatin analogues such as octreotide have been used to treat the symptoms of neuroendocrine tumours for 15 years and a radiolabelled form, [^{111}In]pentetreotide has been used for imaging of neuroendocrine tumours such as carcinoid^[33]. However, it was found that there

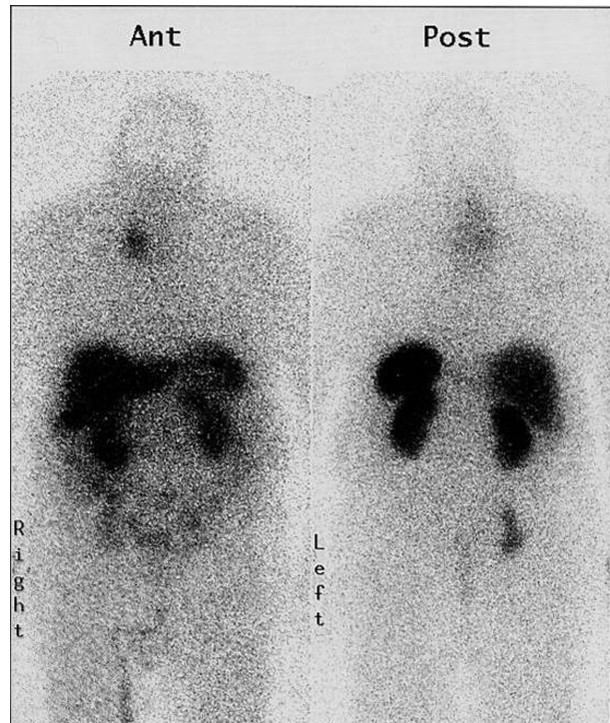


Figure 5 Whole body [^{111}In]pentetreotide imaging showing a large metastasis in the upper inner right lung not seen on ^{131}I imaging but demonstrating somatostatin receptor positivity.

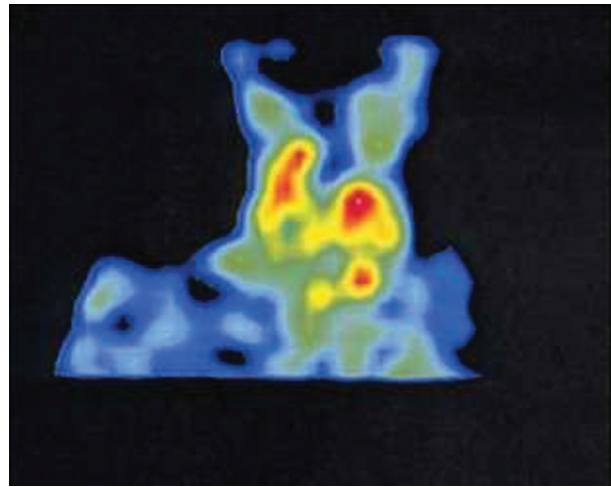


Figure 6 Coronal SPECT [^{111}In]pentetreotide image showing extensive somatostatin positive uptake in lymph nodes invaded by medullary cell cancer of the thyroid (the red areas are the cancer). These were treated by surgery and radiotherapy.

was uptake in a range of other cancers which had expression of the sub-type-2 receptor for which pentetreotide has a very high affinity. A series of studies have been performed showing that 74% of differentiated thyroid cancers have uptake of [^{111}In]pentetreotide including some negative on [^{18}F]FDG (Fig. 5)^[34,35].

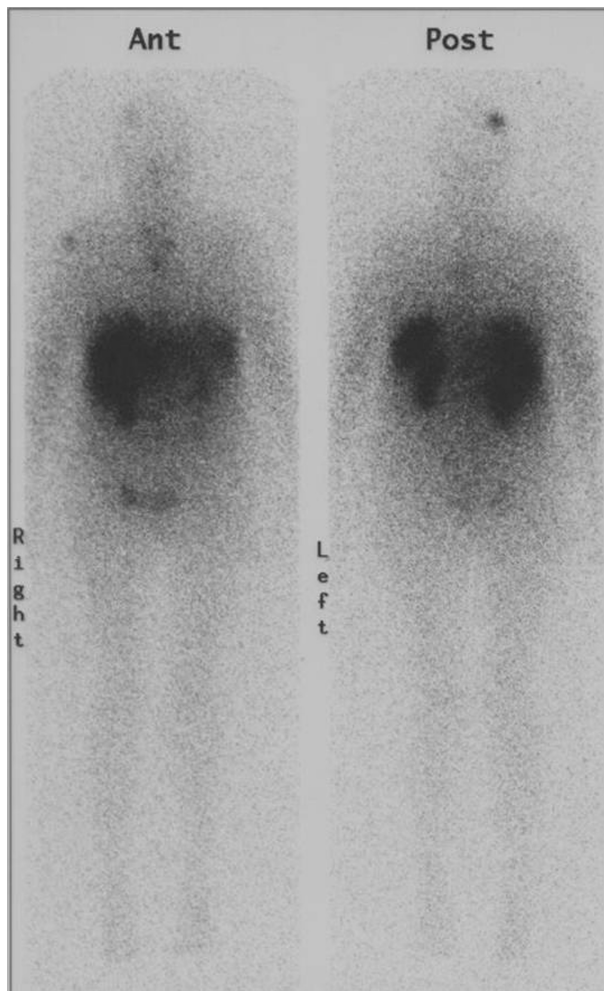


Figure 7 Images performed 24 h after administration of [^{90}Y]octreotate therapy in a patient with metastatic medullary cell cancer of the thyroid. Liver, kidney and splenic uptake in normal other sites represent metastatic disease. Note abnormal uptake in skull, shoulder, sternum and pelvis. This patient had a good response to this therapy sustained over 12 months later.

This was found to be true for those tumours with and without uptake of ^{131}I so could be used as an alternative to [^{18}F]FDG PET imaging. There are, however, disadvantages in using somatostatin imaging in that uptake depends on receptor expression; the resolution is not as good as PET and the cost can be higher.

In patients in whom there is known to be tumour and in whom there is no evidence for uptake of ^{131}I , a positive [^{111}In]pentetreotide scan may mean the possibility of treatment with ^{90}Y - or ^{177}Lu -labelled somatostatin analogues. These products are not commercially available but have been used in a variety of European centres where it can be manufactured on site. Some early work in thyroid cancer has produced encouraging results^[36,37].

MCT

Medullary cell cancer of the thyroid (MCT) is a cancer of the calcitonin producing cells in the thyroid. These cells do not have an iodine uptake mechanism and therefore imaging with radioiodine or pertechnetate and treatment with ^{131}I will not work. However, the tumour is a neuroendocrine tumour. Imaging can be performed with [^{111}In]pentetreotide with good results (Fig. 5)^[38]. Also it is possible to use the amine uptake mechanism used by *meta*-iodobenzyl guanidine (mIBG). This seems to have uptake in about 60% of patients with MCT and, like [^{111}In]pentetreotide, can be used for staging local disease and metastases^[39]. Whole body imaging with SPECT of the neck is used with both of these agents, with additional SPECT as required. An added advantage of ^{123}I mIBG imaging is that in patients with multiple endocrine neoplasia type 2 (MEN2), any co-incidental pheochromocytoma may be found.

The prime role of these agents, however, is not just staging but to determine if therapy can be undertaken with beta labelled versions of these agents, either ^{90}Y -labelled somatostatin analogues (Fig. 7) or ^{131}I -labelled mIBG^[40,41].

Imaging alone has been shown to be effective with [$^{99\text{m}}\text{Tc}$]pentaivalent dimercapto succinic acid (DMSA(V))^[42]. The advantage is that there is a high sensitivity of greater than 90% especially for nodal disease. Also unlike somatostatin receptor and mIBG imaging, it can be positive in tumours that do not display the correct receptors. A therapeutic version of (DMSA(V)) using ^{186}Re or ^{188}Re is under development^[43]. [^{18}F]FDG PET-CT has been used increasingly in metastatic MCT but at present there is insufficient data to state if it will be used instead of the established nuclear medicine techniques.

Conclusions

For the past 60 years nuclear medicine has been at the heart of diagnosis and treatment of patients with thyroid cancers. Methods of imaging have been refined as have optimal protocols for therapy. Newer techniques such as PET and receptor based imaging and therapy has meant that this oldest branch of nuclear medicine has also become one of its fastest moving.

References

- [1] AACE/AME Task Force on Thyroid Nodules American Association of Clinical Endocrinologists and Associazione Medici Endocrinologi. Medical guidelines for clinical practice for the diagnosis and management of thyroid nodules. *Endocr Pract* 2006; 12: 63–102.
- [2] Brooks JR, Starnes HF, Brooks DC, Pelkey JN. Surgical therapy for thyroid carcinoma: a review of 1249 solitary thyroid nodules. *Surgery* 1988; 104: 940–6.
- [3] Belfiore A, Giuffrida D, La Rosa GL, *et al.* High frequency of cancer in cold thyroid nodules occurring at young age. *Acta Endocrinol (Copenh)* 1989; 121: 197–202.

- [4] Belfiore A, La Rosa GL, La Porta GA, *et al.* Cancer risk in patients with cold thyroid nodules: relevance of iodine intake, sex, age, and multinodularity. *Am J Med* 1992; 93: 363–9.
- [5] Yagcoglu H, Ozalp E, Ibis E, Aras G. Partial stunning in thyroid remnant after administration of scanning dose followed by 100 mCi I-131 therapy. *Clin Nucl Med* 1996; 21: 340.
- [6] Kao CH, Yen TC. Stunning effects after a diagnostic dose of iodine-131. *Nuklearmedizin* 1998; 37: 30–2.
- [7] Muratet JP, Daver A, Minier JF, Larra F. Influence of scanning doses of iodine-131 on subsequent first ablative treatment outcome in patients operated on for differentiated thyroid carcinoma. *J Nucl Med* 1998; 39: 1546–50.
- [8] Kamel N, Corapcioglu D, Sahin M, Gürsoy A, Küçük O, Aras G. I-131 therapy for thyroglobulin positive patients without anatomical evidence of persistent disease. *J Endocrinol Invest* 2004; 27: 949–53.
- [9] Dworkin HJ, Meier DA, Kaplan M. Advances in the management of patients with thyroid disease. *Semin. Nucl. Med.* 1995; 25: 205–20.
- [10] Mazzaferrri EL. Thyroid remnant ¹³¹I ablation for papillary and follicular thyroid carcinoma. *Thyroid* 1997; 7: 265–71.
- [11] Siddiqui AR, Edmondson J, Wellman HN, *et al.* Feasibility of low doses of I-131 for thyroid ablation in postsurgical patients with thyroid carcinoma. *Clin Nucl Med* 1981; 6: 158–61.
- [12] Tang YD, Kuzman JA, Said S, Anderson BE, Wang X, Gerdes AM. Low thyroid function leads to cardiac atrophy with chamber dilatation, impaired myocardial blood flow, loss of arterioles, and severe systolic dysfunction. *Circulation* 2005; 112: 3122–30.
- [13] Ang ES, Teh HS, Sundram FX, Lee KO. Effect of lithium and oral thyrotrophin-releasing hormone (TRH) on serum thyrotrophin (TSH) and radioiodine uptake in patients with well differentiated thyroid carcinoma. *Singapore Med J* 1995; 36: 606–8.
- [14] Meier CA, Braverman LE, Ebner SA, *et al.* Diagnostic use of recombinant human thyrotropin in patients with thyroid carcinoma (phase I/II study). *J Clin Endocrinol Metab* 1994; 78: 188–96.
- [15] Mazzaferrri EL, Kloos RT. Is diagnostic iodine-131 scanning with recombinant human TSH useful in the follow-up of differentiated thyroid cancer after thyroid ablation? *J Clin Endocrinol Metab* 2002; 87: 1490–8.
- [16] Nordén MM, Larsson F, Tedelind S, *et al.* Down-regulation of the sodium/iodide symporter explains ¹³¹I-induced thyroid stunning. *Cancer Res* 2007; 67: 7512–7.
- [17] Pons F, Carrió I, Estorch M, Ginjaume M, Pons J, Milian R. Lithium as an adjuvant of iodine-131 uptake when treating patients with well-differentiated thyroid carcinoma. *Clin Nucl Med* 1987; 12: 644–7.
- [18] Liu YY, Stokkel MP, Pereira AM, *et al.* Bexarotene increases uptake of radioiodide in metastases of differentiated thyroid carcinoma. *Eur J Endocrinol* 2006; 154: 525–31.
- [19] Haberkorn U, Beuter P, Kübler W, *et al.* Iodide kinetics and dosimetry in vivo after transfer of the human sodium iodide symporter gene in rat thyroid carcinoma cells. *J Nucl Med* 2004; 45: 827–33.
- [20] Siddiqi A, Foley RR, Britton KE, *et al.* The role of ¹²³I-diagnostic imaging in the follow-up of patients with differentiated thyroid carcinoma as compared to ¹³¹I-scanning: avoidance of negative therapeutic uptake due to stunning. *Clin Endocrinol* 2001; 55: 515–21.
- [21] Anderson GS, Fish S, Nakhoda K, Zhuang H, Alavi A, Mandel SJ. Comparison of I-123 and I-131 for whole-body imaging after stimulation by recombinant human thyrotropin: a preliminary report. *Clin Nucl Med* 2003; 28: 93–6.
- [22] Saab G, Driedger AA, Pavlosky W, *et al.* Thyroid-stimulating hormone-stimulated fused positron emission tomography/computed tomography in the evaluation of recurrence in ¹³¹I-negative papillary thyroid carcinoma. *Thyroid* 2006; 16: 267–72.
- [23] Petrich T, Börner AR, Weckesser E, *et al.* Follow-up of differentiated thyroid cancer patients using rhTSH – preliminary results. *Nuklearmedizin* 2001; 40: 7–14.
- [24] Chung JK, So Y, Lee JS, *et al.* Value of FDG PET in papillary thyroid carcinoma with negative ¹³¹I whole-body scan. *J Nucl Med* 1999; 40: 986–92.
- [25] Schlüter B, Bohuslavizki KH, Beyer W, Plotkin M, Buchert R, Clausen M. Impact of FDG PET on patients with differentiated thyroid cancer who present with elevated thyroglobulin and negative ¹³¹I scan. *J Nucl Med* 2001; 42: 71–6.
- [26] Lind P, Kresnik E, Kumnick G, *et al.* ¹⁸F-FDG-PET in the follow-up of thyroid cancer. *Acta Med Austriaca* 2003; 30: 17–21.
- [27] Ruiz Franco-Baux JV, Borrego Dorado I, Gómez Camarero P, *et al.* F-18-fluorodeoxyglucose positron emission tomography on patients with differentiated thyroid cancer who present elevated human serum thyroglobulin levels and negative I-131 whole body scan. *Rev Esp Med Nucl* 2005; 24: 5–13.
- [28] Shammass A, Degirmenci B, Mountz JM, *et al.* ¹⁸F-FDG PET/CT in patients with suspected recurrent or metastatic well-differentiated thyroid cancer. *J Nucl Med* 2007; 48: 221–6.
- [29] Erdi YE, Macapinlac H, Larson SM, *et al.* Radiation dose assessment for I-131 therapy of thyroid cancer using I-124 PET imaging. *Clin Positron Imaging* 1999; 2: 41–6.
- [30] el-Desouki M. Tl-201 thyroid imaging in differentiating benign from malignant thyroid nodules. *Clin Nucl Med* 1991; 16: 425–30.
- [31] Nakahara H, Noguchi S, Murakami N, *et al.* Technetium-99m-sestamibi scintigraphy compared with thallium-201 in evaluation of thyroid tumors. *J Nucl Med* 1996; 37: 901–4.
- [32] Sharma R, Mondal A, Shankar LR, *et al.* Differentiation of malignant and benign solitary thyroid nodules using 30- and 120-minute Tc-99m MIBI scans. *Clin Nucl Med* 2004; 29: 534–7.
- [33] Krenning EP, Kwekkeboom DJ, Bakker WH, *et al.* Somatostatin receptor scintigraphy with [¹¹¹In-DTPA-D-Phe1]- and [¹²³I-Tyr3]-octreotide: the Rotterdam experience with more than 1000 patients. *Eur J Nucl Med* 1993; 20: 716–31.
- [34] Görges R, Kahaly G, Müller-Brand J, Mäcke H, Roser HW, Bockisch A. Radionuclide-labeled somatostatin analogues for diagnostic and therapeutic purposes in nonmedullary thyroid cancer. *Thyroid* 2001; 11: 647–59.
- [35] Sarlis NJ, Gourgiotis L, Guthrie LC, *et al.* In-111 DTPA-octreotide scintigraphy for disease detection in metastatic thyroid cancer: comparison with F-18 FDG positron emission tomography and extensive conventional radiographic imaging. *Clin Nucl Med* 2003; 28: 208–17.
- [36] Virgolini I, Traub T, Novotny C, *et al.* Experience with indium-111 and yttrium-90-labeled somatostatin analogs. *Curr Pharm Des* 2002; 8: 1781–807.
- [37] Virgolini I, Britton K, Buscombe J, Moncayo R, Paganelli G, Riva P. In- and Y-DOTA-¹¹¹In-octreotide: results and implications of the MAURITIUS trial. *Semin Nucl Med* 2002; 32: 148–55.
- [38] Bernà L, Chico A, Matías-Guiu X, *et al.* Use of somatostatin analogue scintigraphy in the localization of recurrent medullary thyroid carcinoma. *Eur J Nucl Med* 1998; 25: 1482–8.
- [39] Kaltsas G, Korbonits M, Heintz E, *et al.* Comparison of somatostatin analog and meta-iodobenzylguanidine radionuclides in the diagnosis and localization of advanced neuroendocrine tumors. *J Clin Endocrinol Metab* 2001; 86: 895–902.
- [40] Waldherr C, Schumacher T, Pless M, *et al.* Radiopeptide transmitted internal irradiation of non-iodophil thyroid cancer and conventionally untreatable medullary thyroid cancer using radiopeptides. *Nucl Med Commun* 2001; 22: 673–8.
- [41] Bodei L, Handkiewicz-Junak D, Grana C, *et al.* Receptor radionuclide therapy with ⁹⁰Y-DOTATOC in patients with medullary

- thyroid carcinomas. *Cancer Biother Radiopharm* 2004; 19: 65–71.
- [42] Clarke S, Lazarus C, Maisey M. Experience in imaging medullary thyroid carcinoma using ^{99m}Tc (V) dimercaptosuccinic acid (DMSA). *Henry Ford Hosp Med J* 1989; 37: 167–8.
- [43] Blower PJ, Lam AS, O'Doherty MJ, Kettle AG, Coakley AJ, Knapp Jr FF. Pentavalent rhenium-188 dimercaptosuccinic acid for targeted radiotherapy: synthesis and preliminary animal and human studies. *Eur J Nucl Med* 1998; 25: 613–21.