

# Early experience with surgical strategies aimed at preserving the pulmonary valve and annulus during repair of tetralogy of Fallot

Anil Kumar Dharmapuram<sup>1</sup>, Nagarajan Ramadoss<sup>2</sup>, Vejendla Goutami<sup>3</sup>, Sudeep Verma<sup>3</sup>, Shantanu Pande<sup>4</sup>, Sindhura Devalaraja<sup>5</sup>

<sup>1</sup>Paediatric Cardiac Surgery, <sup>2</sup>Paediatric Cardiac Anaesthesiology, <sup>3</sup>Paediatric Cardiology, Division of Paediatric Cardiac Sciences, Krishna Institute of Medical Sciences (KIMS Hospitals), Secunderabad, Telangana, India, <sup>4</sup>Cardiovascular and Thoracic Surgery, Sanjay Gandhi Postgraduate Institute of Medical Sciences, Lucknow, Uttar Pradesh, India, <sup>5</sup>Department of Anthropology, Overseas Observer Pre-Med student from University of Massachusetts, Massachusetts, USA

## ABSTRACT

- Background** : During repair of tetralogy of fallot (TOF) we modified surgical strategies to preserve the valve and annulus if the pulmonary valve leaflets are pliable and not significantly dysplastic.
- Methods** : Initially, the repair was done from the main pulmonary artery (Group-1, 215 patients) and later through an additional incision in the infundibulum of the right ventricle (Group-2, 73 patients). Recently, we changed the approach to commissurotomy of the fused leaflets by releasing the supra valvar tethering and delamination of the cuspal apparatus till the base to improve the mobility of the cusps and do a controlled commissurotomy (Group-3, 14 patients). With delamination, we could extend the limit of the repair to a z-score of -3.5.
- Results** : There was no hospital mortality; two patients died at home after discharge. A mean follow-up of 42.01 months  $\pm$  19.25 is available for 198 patients (92%) for group 1, 16.03  $\pm$  7.45 for group 2, and 4.07  $\pm$  2.09 for group 3. The re-intervention-free survival is 94.4% in group 1. The z value improved from -3 (-3--2) to -1.2 (-3 - 0),  $P = 0.001$  in Group 1, from -2.8 (-3--2.4) to -1 (-1.1--0.7),  $P = 0.001$  in Group 2 and from -3 (-4--3) to -1,  $P = 0.001$  in Group 3. In all the groups, there was trivial or mild pulmonary regurgitation.
- Conclusions** : During repair of TOF, adequate valve/annulus sparing is possible if the repair is done from both the main pulmonary artery and infundibular incisions using the delamination technique.
- Keywords** : Avoiding trans annular incision in tetralogy of fallot repair, delamination, valve-sparing repair, annulus sparing repair

Access this article online	
<b>Quick Response Code:</b> 	<b>Website:</b> <a href="http://www.annalspc.com">www.annalspc.com</a>
	<b>DOI:</b> <a href="https://doi.org/10.4103/apc.APC_166_20">10.4103/apc.APC_166_20</a>

This is an open access journal, and articles are distributed under the terms of the Creative Commons Attribution-NonCommercial-ShareAlike 4.0 License, which allows others to remix, tweak, and build upon the work non-commercially, as long as appropriate credit is given and the new creations are licensed under the identical terms.

**For reprints contact:** WKHLRPMedknow\_reprints@wolterskluwer.com

**How to cite this article:** Dharmapuram AK, Ramadoss N, Goutami V, Verma S, Pande S, Devalaraja S. Early experience with surgical strategies aimed at preserving the pulmonary valve and annulus during repair of tetralogy of Fallot. *Ann Pediatr Card* 2021;14:315-22.

**Address for correspondence:** Dr. Anil Kumar Dharmapuram, Pediatric Cardiac Surgery, Division of Paediatric Cardiac Sciences, Krishna Institute of Medical Sciences (KIMS Hospitals), Minister Road, Secunderabad - 500 003, Telangana, India.

E-mail: dharmapuram22@yahoo.com

Submitted: 18-Jul-2020    Revised: 17-Sep-2020    Accepted: 27-May-2021    Published: 11-Aug-2021

## INTRODUCTION

In recent years there has been a trend towards repair of tetralogy of fallot (TOF) during early infancy with good outcomes.<sup>[1-7]</sup> Majority of the surgeons do the repair with a transannular patch (TAP) in the right ventricular outflow tract (RVOT).<sup>[1,2]</sup> When a TAP is done, the structural integrity of the valve and the annulus is lost and this leads to pulmonary regurgitation and the long-term consequence of progressive right ventricular dilatation.<sup>[8-10]</sup> To avoid pulmonary regurgitation, there has been an increasing trend to preserve the native pulmonary valve (PV) and avoid incising the annulus and preserve its integrity.<sup>[11-16]</sup> Intraoperative balloon dilatation of the annulus/valve ring has been concomitantly employed as part of the repair technique to preserve the annulus.<sup>[11,12,17,18]</sup> More recently, delamination plasty of the PV cusps has been introduced as part of the valve-sparing strategy.<sup>[11,12,19]</sup>

In this manuscript, we present our early experience with valve and annulus sparing repair of TOF. Since we started this approach we have evolved surgical strategies of valve-sparing over the last few years that can handle smaller annuli and mildly dysplastic valves while avoiding a TAP.

## METHODS

Between March 2013 and February 2020, 403 patients underwent complete intracardiac repair of TOF. Among them, 302 patients underwent repair with a valve/annulus sparing approach. This was based purely on the morphology of the PV cusps and the repair was done only if the cusps were pliable and supple and did not show significant dysplasia.

The patient profile and variables are described in Table 1. Eight patients in the whole group underwent a

right modified Blalock Taussig shunt (BT shunt) as part of the palliative strategy before complete correction either because of hypoplastic pulmonary arteries or cyanotic spells in a small weight baby. In the earlier years, the repair was done from the right atrium (RA) and the main pulmonary artery (MPA) (group-1:215 patients); the resection was done from both sides in addition to an aggressive commissurotomy of the fused cusps. Later on, we modified the approach and started making a small and separate incision in the infundibulum of the right ventricle (RV) below the annulus for better access of the sub-valvular resectable tissue (group-2:73 patients). In the recent past, we changed the approach of handling the cusps by doing a delamination type of repair (group-3:14 patients).

94 patients (among the total number of 403) required a TAP during repair in view of a small annulus and dysplastic PV. This includes 7 patients in whom a valve/annulus sparing repair was converted to a TAP in view of high intraoperative RV pressures.

### Surgical techniques

In all patients, the repair was accomplished from midline sternotomy on cardiopulmonary bypass with moderate hypothermia. After the cardioplegic arrest of the heart, the RA was incised and the anatomy inspected. The fibromuscular infundibular obstruction was resected from the RA as completely as possible leaving adequate margin for the VSD suturing. Many times, the PV could not be visualized from the RA. After this, a linear incision was made in the MPA and the PV was inspected from above. In the majority of patients, the PV was noted to be bicuspid. The commissures were carefully divided with a sharp blade to make an aggressive commissurotomy. Following this, the leaflets were retracted carefully and the sub-valvar infundibular obstruction was further resected from above without damaging the leaflets during

**Table 1: Patient profile/outcomes**

Parameters	Median (minimum-maximum)		
	MPA patch	MPA + infundibular patch	MPA + infundibular + delamination
Total numbers (n)	215	73	14
Age (month)	20 (3-264)	12 (3-168)	10.5 (8-120)
Weight (kg)	8.6 (4-58)	7.6 (4.5-34)	8.6 (5-13)
BSA	0.42 (0.2-1.8)	0.4 (0.28-1.2)	0.39 (0.29-0.78)
Valve morphology (n)			
Bicuspid	200	70	12
Tricuspid	14	4	2
CPB time (min)	120 (70-221)	135 (90-230)	145 (120-180)
Cross clamp time (min)	84 (40-160)	97 (75-220)	100 (80-123)
Chest open (n) (24 h)	1	7	Nil
JET (n)	6	4	Nil
Ventilation (h)	12 (6-72)	10 (8-48)	8 (8-24)
Re-operation	PBPV (2) Redo ICR (6) Waiting for Redo ICR (3)	No re-intervention	No re-intervention
Mortality (n)	1	1	Nil

BSA: Body surface area, CPB: Cardiopulmonary bypass, JET: Junctional ectopic tachycardia, PBPV: Percutaneous balloon pulmonary valvuloplasty, ICR: Intra cardiac repair, MPA: Main pulmonary artery

retraction. This was the technique followed earlier by us (Group-1).

*Technique of valve-sparing repair of right ventricular outflow tract*

In our early experience, we noticed that some patients in group-1 came back with recurrent obstruction in the RVOT requiring re-intervention [Table 1]. We modified the surgical approach and started doing a small incision in the infundibulum of the RV just below the annulus [Group-2, Figure 1].

With this incision, the sub-valvar obstruction could be resected more aggressively to open up the RVOT better. This is in addition to the aggressive commissurotomy of the fused cusps. After this, the appropriately sized Hegar dilator is negotiated carefully across the annulus without damaging the leaflets to assess the adequacy of

the outflow tract. After the VSD repair, both the incisions in the infundibulum and the MPA were augmented with 0.6% glutaraldehyde treated pericardial patches.

**Change of surgical approach to delamination**

After seeing some aggressive surgical strategies described recently<sup>[11,12]</sup> we started a similar surgical approach to handle the cuspal apparatus of the PV in the recent past (group-3). The fused commissural apparatus of the leaflets [Figure 2] was carefully and completely detached from the PA wall with No. 15 sharp blade. After this, the cusps were gently delaminated and released from the bases to reach as much as possible to the infundibulum [Figures 3 and 4]. Following this, a controlled and adequate commissurotomy was done with a No. 11 sharp blade till the level of the cusp

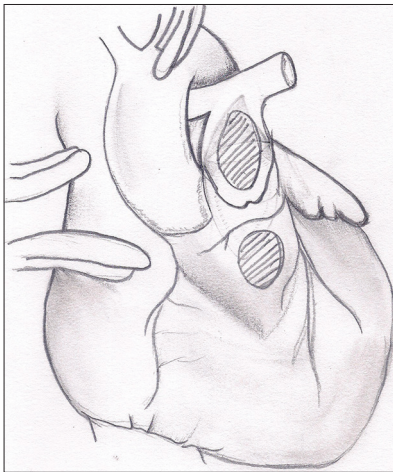


Figure 1: Schematic diagram of the heart showing the two patch technique of Group-2 and Group-3 patients. Note the incisions in the main pulmonary artery and infundibulum. Both have been augmented with pericardial patches

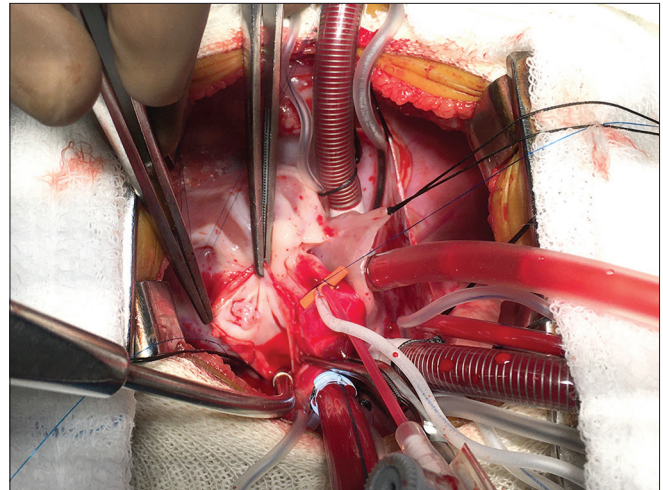


Figure 2: Intraoperative photograph of the pulmonary valve in a borderline sized annulus after opening the main pulmonary artery. The tight stenosis of the bicuspid valve is seen; however the cusps are pliable and not dysplastic with adequate bases

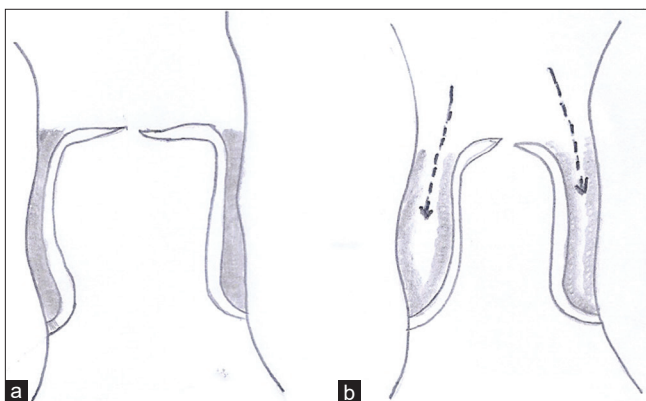


Figure 3: (a) Schematic illustration showing the fused cuspal apparatus to the pulmonary artery wall in longitudinal section. (b) Technique of delamination and release of the fused cuspal apparatus from the pulmonary artery wall. The arrows indicate the line of release of the fused apparatus and proceeding to the delamination of the bases

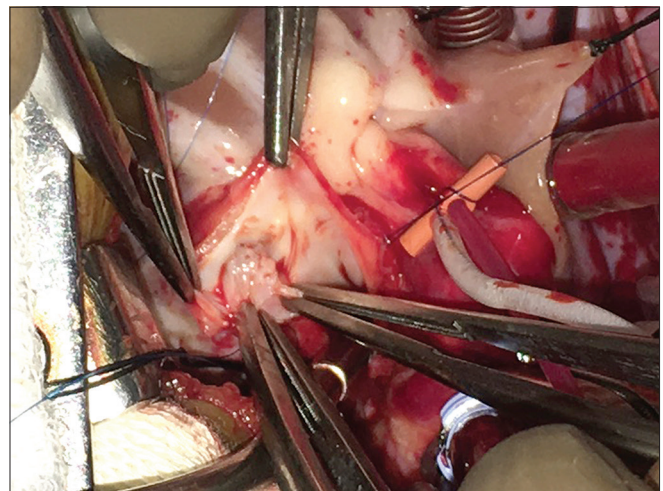


Figure 4: Intraoperative photograph of completion of delamination at one side of the fused cuspal apparatus with mobilization of the base of the cusp

bases and taking care to maintain leaflet coaptation [Figures 5 and 6]. This delamination increased the mobility and the free surface area. This is in addition to the small infundibular incision and aggressive resection of the sub-valvar tissue.

*Calculation of the z-score*

The z-score of the PV annulus was calculated in the preoperative echocardiography and also during follow-up based on guidelines published.<sup>[20]</sup> The decision for sparing the annulus was based postoperatively on P RV and LV percentage achieved immediately at the end of surgery. A percentage higher than 80 was considered unacceptable and a transannular patch was added. Thus it was completely free of the preoperative z value of the pulmonary annulus.

**Statistical analysis**

The data are presented in median and range from minimum to maximum. The analysis of data in three groups was performed using one-way ANOVA to observe any significant difference between them. The homogeneity of variance was established and then the Brown-Forsythe method was used to establish equality of means. If equality was achieved, then Bonferroni method was used to do the *post hoc* analysis to study the inter-group difference. In case equality was not achieved, then the Games-Howell method was used to achieve intergroup *post hoc* analysis. The bivariate correlation between relevant variables was achieved using Pearson’s Test. Kaplan–Meier analysis was done to perform the survival analysis based on outcome variables. Student’s *t*-test was used to identify the difference when comparing a variable in the same group after the operation. In group 3, since the number of cases is 14, Wilcoxon signed-rank test is used to observe the

statistical difference in the variable before and after the operation. A  $P < 0.05$  was considered significant. SPSS version 17 for windows (SPSS, Inc. Chicago, IL, USA) was used for statistical analysis.

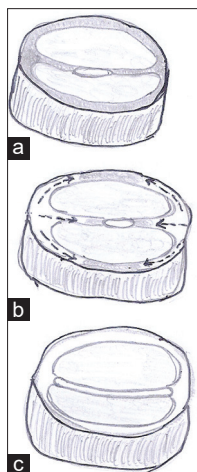
**RESULTS**

The peri-operative and the immediate postoperative outcomes are described in Table 1. The need for keeping the chest open overnight in 8 patients was due to lung-related issues despite good hemodynamics. All these patients were below 6.0 kg weight. In all patients, dobutamine was used for inotropic support in the peri-operative period at a dose of 5 µg/kg/min; if required adrenaline was added at the discretion of the intensivist. No patient developed complete heart block.

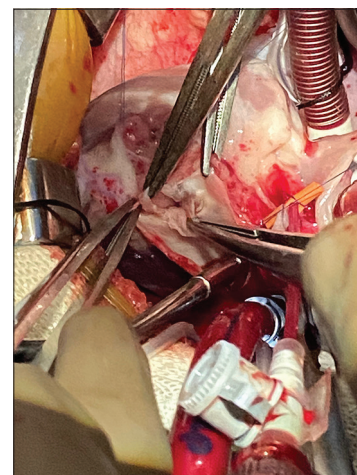Six patients required re-intubation because of desaturation and respiratory distress; two patients among them had to be taken to the cath lab to rule out MAPCAS based on clinical, radiological and two dimensional echocardiography suspicion. However, none of them required any intervention and they did well eventually.

The mean age at operation in the whole study group was 3 years (3 months–22 years). There were 195 males and 107 females distributed into three groups. The distribution of age and body surface area (BSA) in three groups is displayed in Figures 7 and 8. There was a statistically significant difference in age and BSA between Group-1 and Group-2.

A mean follow-up of 42.01 months ± 19.25 was available for 198 patients (92%) for group 1, 16.03 ± 7.45 for group 2, and 4.07 ± 2.09 for Group-3. The follow-up in Group 2 and 3 is 100% complete. There was no hospital mortality. Two patients died at home 2 months



**Figure 5: Schematic illustration showing the steps of delamination. (a) Shows the tight stenosis in the middle of the bicuspid valve with severe fusion. (b) Shows the release of cuspal apparatus and delamination indicated by the arrows in all directions. (c) Shows the fully opened up valve with mobile cusps**



**Figure 6: Intraoperative photograph of completion of the pulmonary valve repair after delamination and controlled commissurotomy till the level of the cuspal bases. Note that the coaptation of the leaflets is intact. The leaflets look thin and pliable and fully mobile**

after discharge (one mortality each in Group 1 and 2). Mortality-free survival was 99.3%.

There were 11 re-interventions (either done or planned for future) in Group 1 and none in Group 2 and 3. The re-intervention-free survival was 94.4% in group 1 and is presented in Figure 9.

With improvement of technique, there was a tendency to accept smaller z value of pulmonary annulus for valve-sparing repair. There was statistically significant improvement in the postoperative left and right ventricular pressure, z value of pulmonary annulus in follow-up and RVOT gradients during follow-up. The improvements in these values were evident with the advancement of the technique of valve preservation. These values are presented in Table 2. There was a strong negative correlation between follow-up z value and follow-up RVOT gradient and the need for

re-intervention ( $r = -0.916$ ,  $P = 0.000$  and  $r = -0.816$ ,  $P = 0.000$ , respectively).

**Assessment of pulmonary regurgitation**

There was no concern of PR in Group-1 and 2 patients when the valve-sparing repair was done. However, in Group-3 where the aggressive repair was attempted with delamination of the cuspal apparatus, we evaluated the PR more carefully in the follow-up. Among the 14 patients, the PR was absent in two, trivial in two, mild in eight, and moderate in two patients. An example of an intra-operative TEE echo in a case of delamination repair shows the absence of PR [Video 1].

*Comparison between the valve/annulus sparing and trans annular incision*

Table 3 shows the comparative numbers of the valve/annulus sparing and TAP in our experience. Before

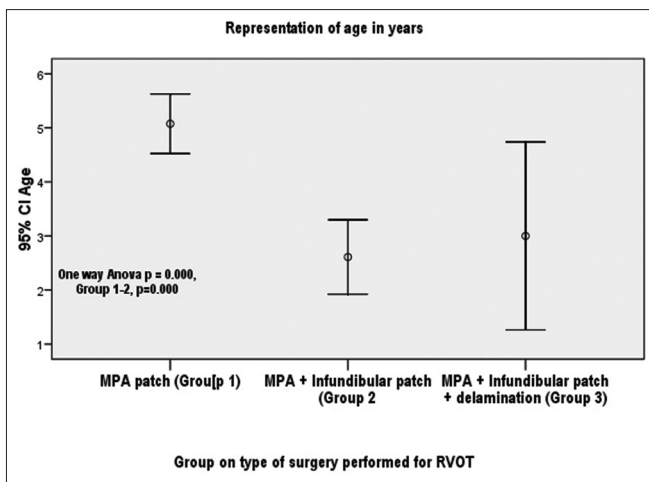


Figure 7: The representation of age in three groups using error bars with inter group significance

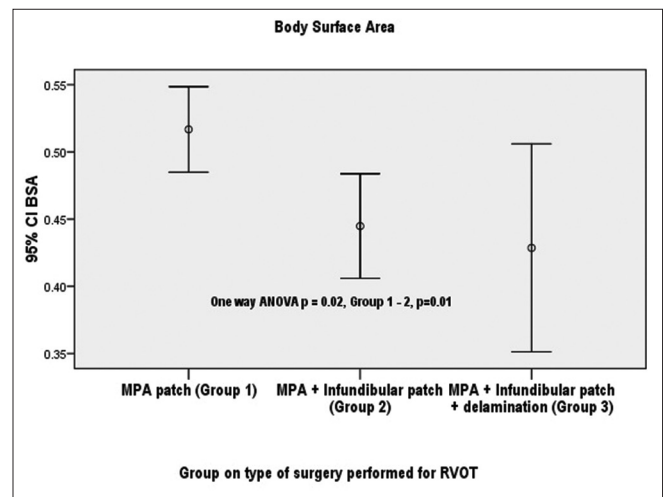


Figure 8: Representation of Body Surface area in three group and its statistical significance between them

**Table 2: One-way ANOVA analysis of three groups for various variables**

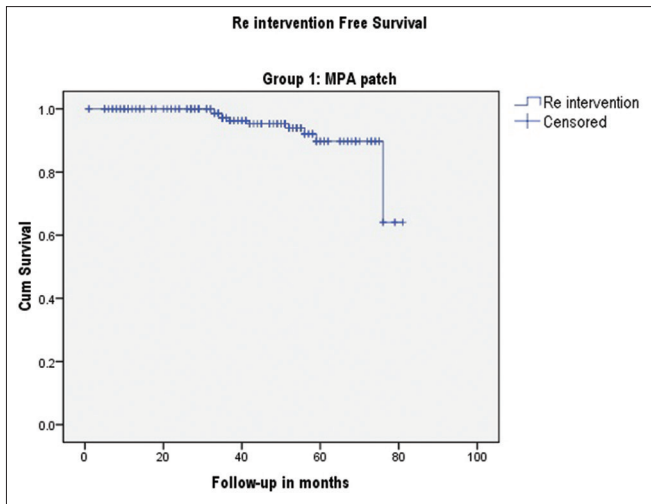
Variable	Median (minimum-maximum)			P	P of inter-group difference
	Group 1 (n=215)	Group 2 (n=73)	Group 3 (n=14)		
Preoperative Z value	-3 (-3--2)	-2.8 (-3--2.4)	-3 (-4--3)	0.001	1-2*, 1-3*
Follow-up Z value	-1.2 (-3-0)	-1 (-1.1--0.7)	-1	0.001	1-2*, 2-3*, 1-3*
RVOT gradient (mm Hg) at last follow-up	35 (30-105)	25 (20-30)	24 (20-24)	0.001	1-2*, 2-3*, 1-3*
RV/LV pressure (%)	65 (65-75)	60 (50-70)	50 (50-60)	0.001	1-2*, 2-3*, 1-3*

\*P=0.001. RVOT: Right ventricular outflow tract, RV/LV pressure %: Immediate postoperative percentage of right ventricular pressure as compared to left ventricular pressure, RV: Right ventricle, LV: Left ventricular

**Table 3: Comparative numbers of tetralogy of fallot repair with valve/annulus sparing versus trans annular patch**

Duration	Total number (n)	Valve/annulus sparing	TAP, n (%)
March 2013 to August 2019	379	Total number (n) (288) MPA patch (215) MPA + infundibular patch (73)	91 (24.04)
September 2019 to March 2020	24	Total number (n) (21) MPA + infundibular patch (7) Delamination (14)	3 (12.5)

TAP: Transannular patch, MPA: Main pulmonary artery



**Figure 9: Kaplan-Meier curve for re intervention free survival in Group 1**

the delamination approach, the TAP was used in 23.21% of the total number and after the delamination, the percentage of TAP decreased to 12.5%.

## DISCUSSION

Since March 2013 our valve/annulus sparing strategy in the repair of TOF is based purely on the morphology of the PV leaflets. We noticed that many times the PV leaflets look pliable and salvageable despite a borderline/smallish size of the annulus. It is important for surgeons to realize this finding and try to save the annulus and adopt to a valve-sparing strategy. This is especially appropriate in a situation like our country with limited resources and improper follow-up. The primary concern is the prevention of long-term RV dilatation that would require redo operations and PV replacement which is a financially difficult option.

The upper limit of the z score value that would dictate the decision to incise the annulus has been a subject of variability in the decision-making among many units. As surgeons, we need to understand that z score does not actually indicate the true PV pathology and narrowing.<sup>[13]</sup> Some groups have a cut-off limit-2.45,<sup>[17]</sup> while others have been more aggressive.<sup>[11,12,16,21,22]</sup>

We disagree with the philosophy of relying only on z scores for a decision to preserve the annulus and strongly contend that intra-operative inspection of the valve is more important. In our experience with the Group-1 patients, the early re-interventions prompted us to introspect our surgical strategy. We modified the strategy and started doing a separate additional small incision in the infundibulum. With this approach, we could see the immediate early outcomes with better RVOT gradients and with no significant obstruction. Recently, when we evolved the delamination strategy

involving aggressive mobilization of the cusps and doing a controlled commissurotomy, we could achieve a larger volume of the base of the cusps to function with better co-aptation.

In a unit that would adopt to the annulus sparing strategy of repair, the use of TAP could come down to 30% with a low risk of re-operation and significantly reduced long-term RV dilatation.<sup>[14]</sup> In our own experience, by adopting an aggressive valve/annulus sparing approach we could reduce the incidence of TAP in our series from 23.21% in Group-1 and 2% to 12.5% in Group-3 [Table 3]. Our early experience shows that the residual PS that has occurred in Group 1 was in 11 of 215 patients with a 94.4% re-intervention-free survival. We understand that this is a significant number of patients that required re-intervention. However, we were very careful to introspect this outcome and quickly change the surgical strategy to achieve better results with lesser RVOT gradients in the follow-up and no re-interventions. Moderate gradients postoperatively need close follow-up. They were advised yearly echocardiography and reporting to the hospital in case symptoms appear. Exercise testing is planned if the gradients rise even without symptoms.

PV regurgitation after valve-sparing repair in TOF has been a matter of concern in some reports<sup>[16,17]</sup>. At the same time, others claimed very low incidence of this problem.<sup>[11,12,14]</sup> In our experience, PV regurgitation has never been a concern, especially in Group-1 and 2 where only aggressive commissurotomy was done and the cuspal apparatus was never mobilized. However, in Group-3 where we adopted to aggressive delamination of the cuspal apparatus and mobilization of the cusps till the infundibulum, the PR was more carefully evaluated during follow-up. As mentioned earlier it was not significant and only moderate in two patients. We feel that careful handling of the valve cusps and controlled commissurotomy without destroying the commissure and holding the integrity of the co-apting surface of the leaflets has helped in the prevention of any significant valve leak. Furthermore, in this technique, the original commissure of the cusps will be moved down to a different level away from the pulmonary artery wall. This itself will provide more room for the outflow. By evolving this technique we could stretch the limit of the z score from -3 in Group 2 to -3.5 in Group 3.

## CONCLUSIONS

We strongly recommend that congenital heart surgeons should not neglect the PV anatomy and should base the repair of TOF completely on the morphology of the leaflets even in borderline-sized annuli. When an annulus saving strategy is chosen, using an additional small incision in the infundibulum would help in aggressive resection of the sub-valvar apparatus and contribute to

achieving a bigger infundibular chamber. Detachment of the fused cuspal apparatus from the true commissure and delamination of the bases of the cusps till the infundibulum will increase the volume of the cusps and provide better coaptation of the leaflets. This strategy would help to handle smaller annuli in the valve-sparing repair. Careful handling of the cuspal apparatus during repair would not cause pulmonary insufficiency. Early experience with this technique of delamination shows encouraging results; however long-term follow-up is required to demonstrate the efficacy of this strategy.

#### Description of supplementary files

Video shows an example of an intra-operative TEE in a case of delamination repair with no PR and with adequate RVOT.

#### Acknowledgments

We are thankful to the following team members in our unit for helping us in the preparation of manuscript.

1. Mr. Goutham Nellutla, Clinical Data Co-ordinator
2. Mr. Narsimulu Mantri and Mr Jagadeesh Chandu (Surgical Physician Assistants)
3. Mr. Suresh Siliveri and Mr. P. Naresh Kumar (Perfusionists).

#### Financial support and sponsorship

Nil.

#### Conflicts of interest

There are no conflicts of interest.

## REFERENCES

1. Al Habib HF, Jacobs JP, Mavroudis C, Tchervenkov CI, O'Brien SM, Mohammadi S, et al. Contemporary patterns of management of tetralogy of Fallot: Data from the Society of Thoracic Surgeons Database. *Ann Thorac Surg* 2010;90:813-9.
2. Sarris GE, Comas JV, Tobota Z, Maruszewski B. Results of reparative surgery for tetralogy of Fallot: Data from the European Association for Cardio-Thoracic Surgery Congenital Database. *Eur J Cardiothorac Surg* 2012;42:766-74.
3. Jonas RA. Early primary repair of tetralogy of Fallot. *Semin Thorac Cardiovasc Surg Pediatr Card Surg Annu* 2009;2:39-47.
4. Bové T, François K, Van De Kerckhove K, Panzer J, De Groote K, De Wolf D, et al. Assessment of a right-ventricular infundibulum-sparing approach in transatrial-transpulmonary repair of tetralogy of Fallot. *Eur J Cardiothorac Surg* 2012;41:126-33.
5. Barron DJ. Tetralogy of Fallot: Controversies in early management. *World J Pediatr Congenit Heart Surg* 2013;4:186-91.
6. Bacha EA, Scheule AM, Zurakowski D, Erickson LC, Hung J, Lang P, et al. Long-term results after early primary repair of tetralogy of Fallot. *J Thorac Cardiovasc Surg* 2001;122:154-61.
7. Parry AJ, McElhinney DB, Kung GC, Reddy VM, Brook MM, Hanley FL. Elective primary repair of acyanotic tetralogy of Fallot in early infancy: Overall outcome and impact on the pulmonary valve. *J Am Coll Cardiol* 2000;36:2279-83.
8. Geva T. Indications and timing of pulmonary valve replacement after tetralogy of Fallot repair. *Semin Thorac Cardiovasc Surg Pediatr Card Surg Annu* 2006;9:11-22.
9. Geva T, Sandweiss BM, Gauvreau K, Lock JE, Powell AJ. Factors associated with impaired clinical status in long-term survivors of tetralogy of Fallot repair evaluated by magnetic resonance imaging. *J Am Coll Cardiol* 2004;43:1068-74.
10. Murphy JG, Gersh BJ, Mair DD, Fuster V, McGoon MD, Ilstrup DM, et al. Long-term outcome in patients undergoing surgical repair of tetralogy of Fallot. *N Engl J Med* 1993;329:593-9.
11. Vida VL, Guariento A, Castaldi B, Sambugaro M, Padalino MA, Milanese O, et al. Evolving strategies for preserving the pulmonary valve during early repair of tetralogy of Fallot: Mid-term results. *J Thorac Cardiovasc Surg* 2014;147:687-94.
12. Vida VL, Angelini A, Guariento A, Frescura C, Fedrigo M, Padalino M, et al. Preserving the pulmonary valve during early repair of tetralogy of Fallot: Anatomic substrates and surgical strategies. *J Thorac Cardiovasc Surg* 2015;149:1358-63.e1.
13. Bacha E. Valve-sparing options in tetralogy of Fallot surgery. *Semin Thorac Cardiovasc Surg Pediatr Card Surg Annu* 2012;15:24-6.
14. Hickey E, Pham-Hung E, Halvorsen F, Gritti M, Duong A, Wilder T, et al. Annulus-sparing tetralogy of fallot repair: Low risk and benefits to right ventricular geometry. *Ann Thorac Surg* 2018;106:822-9.
15. Hua Z, Li S, Wang L, Hu S, Wang D. A new pulmonary valve cusp plasty technique markedly decreases transannular patch rate and improves midterm outcomes of tetralogy of Fallot repair. *Eur J Cardiothorac Surg* 2011;40:1221-6.
16. Stewart RD, Backer CL, Young L, Mavroudis C. Tetralogy of Fallot: Results of a pulmonary valve-sparing strategy. *Ann Thorac Surg* 2005;80:1431-8.
17. Hofferberth SC, Nathan M, Marx GR, Lu M, Sleeper LA, Marshall AC, et al. Valve-sparing repair with intraoperative balloon dilation in tetralogy of Fallot: Midterm results and therapeutic implications. *J Thorac Cardiovasc Surg* 2018;155:1163-73.e4.
18. Bautista-Hernandez V, Cardenas I, Martinez-Bendayan I, Loyola H, Rueda F, Portela F. Valve-sparing tetralogy of Fallot repair with intraoperative dilation of the pulmonary valve. *Pediatr Cardiol* 2013;34:918-23.
19. Vida VL, Zucchetta F, Stellin G. Pulmonary valve-sparing techniques during repair of tetralogy of Fallot: The delamination plasty. *J Thorac Cardiovasc Surg* 2016;151:1757-8.
20. Pettersen MD, Du W, Skeens ME, Humes RA. Regression equations for calculation of z scores of cardiac structures

- in a large cohort of healthy infants, children, and adolescents: An echocardiographic study. *J Am Soc Echocardiogr* 2008;21:922-34.
21. Rao V, Kadletz M, Hornberger LK, Freedom RM, Black MD. Preservation of the pulmonary valve complex in tetralogy of fallot: How small is too small? *Ann Thorac Surg* 2000;69:176-80.
22. Boni L, Garcia E, Galletti L, Perez A, Herrera D, Ramos V, *et al.* Current strategies in tetralogy of fallot repair: Pulmonary valve sparing and evolution of right ventricle/left ventricle pressure ratio. *Eur J Cardiothorac Surg* 2009;35:885-90.