

Feeding tube replacement: not always that simple!

Mateus Quitembo Soares da Silva^{a,b}, Alex Lederman^a,
Ricardo Frank Coelho da Rocha^a, Rodrigo Montenegro Lourenção^a

Silva MQS, Lederman A, Rocha RFC, Lourenção RM. Feeding tube replacement: not always that simple! Autopsy Case Rep [Internet]. 2015; 5(1):49-52. <http://dx.doi.org/10.4322/acr.2014.050>

ABSTRACT

Although surgical gastrostomy is not a technically troublesome surgery, the procedure may be accompanied by unfavorable outcomes. Most complications occur early in the post-operative period and include feeding tube dislodgment, stomal infection, peritonitis, and pneumonia. The authors report the case of an 83-year-old man who underwent a surgical gastrostomy because of a swallowing disorder after an ischemic stroke. Nine months after the procedure, the feeding tube dislodged and a new tube was inserted with a certain delay and with some difficulty, causing a false path and consequently an intrabdominal abscess after diet infusion. The outcome was fatal. The authors call attention for meticulous care with the insertion of feeding tubes and advise the performance of imaging control to assure its precise positioning.

Keywords

Gastrostomy; Peritonitis; Shock Septic.

INTRODUCTION

Gastrostomy was one of the first abdominal surgeries ever undertaken. In 1837, Egeberg, a Norwegian surgeon, initially conceived the procedure.^{1,2} In 1849, Sèdilot performed the first gastrostomy, but the patient died due to peritonitis. In the very beginning, this procedure was associated with 100% mortality.³ In 1875, the first successful attempt was attributed to Jones,⁴ but in 1876, another publication attributed it to Verneuil.^{1,2} However, the gastrostomy techniques changed over time and the outcomes improved. In 1894, Stamm⁵ proposed a new technique, which is still being used today. Up until 1979, all gastrostomies were

surgically performed. In 1979, Gauderer and Ponsky⁶ accomplished the first procedure through endoscopy, and in 1981, Preshaw⁷ performed a percutaneous procedure with fluoroscopic guidance.

Although, apparently, the surgical gastrostomy technique seems to be simple, its complications are fairly common. When they occur within the first 15 days of the procedure, re-operation is always mandatory, since the stomach has not yet adhered to the abdominal wall and the tube path has not yet formed. Therefore, when necessary, feeding tube replacement should be postponed for 1 month after the procedure. Prudent

^a Surgery Division - Hospital Universitário - Universidade de São Paulo, São Paulo/SP - Brazil.

^b Surgery Department - Clínica Girassol, Luanda - Angola.



surgeons do not recommend replacement of the tube before 3 months to prevent complications.⁸

CASE REPORT

An 83-year-old man was brought to the emergency facility because of the dislodgment of his gastrostomy feeding tube the day before. He had undergone the gastrostomy 9 months before (Stamm's technique) because of a swallowing disorder acquired after an acute ischemic stroke. As the stoma was stenotic, it was dilated and a new tube was inserted through the original orifice. The patient was discharged afterwards. He experienced abdominal pain and vomiting soon after the diet administration through the replaced tube. He returned to the hospital within 36 hours. Physical examination showed an ill-looking patient, dehydrated, with hypotension, and tachycardia. The abdomen was distended and diffusely tender, predominantly in the left hypochondrium and flank, close to the stoma. The abdominal computed tomography (CT), after the infusion of 40 mL of iodine contrast medium through the gastrostomy tube, showed a cavity formed by peritoneal blockade filled by gas and fluid (Figure 1).

Therefore, the patient was submitted to an exploratory laparotomy. Surgical findings included a significant amount of a lumpy liquid in the peritoneal cavity, and peritoneal adhesions between the loops and

the abdominal wall. At the site of the gastrostomy, a false path was found linking the abdominal orifice with a blockade purulent collection, adjacent to the stomach. Another gastrostomy was performed and the stomach was sutured to the abdominal wall. A thorough lavage of the peritoneal cavity with saline was undertaken and the abdomen was drained. The patient was referred to the intensive care unit, but the outcome was accompanied with evisceration requiring re-operation. Multiple organ failure ensued and he died 43 days later.

DISCUSSION

Regardless of the technique used to carry out a gastrostomy, complications occur. At first glance it could be supposed that surgical gastrostomy would always be associated with successful tube placement, but in a meta-analysis this procedure was significantly associated with higher procedure-related mortality and major complications.^{1,9} In the literature, a 30-day mortality rate after surgical gastrostomy was higher than percutaneous endoscopic gastrostomy, ranging between 21% and 41%. These high percentages are probably due to the severe disability of the patients in the different series.⁹⁻¹¹ However, other studies did not find such a difference between the techniques.¹¹⁻¹⁴ Complications after a gastrostomy are divided into minor and major categories. The former include: peristomal

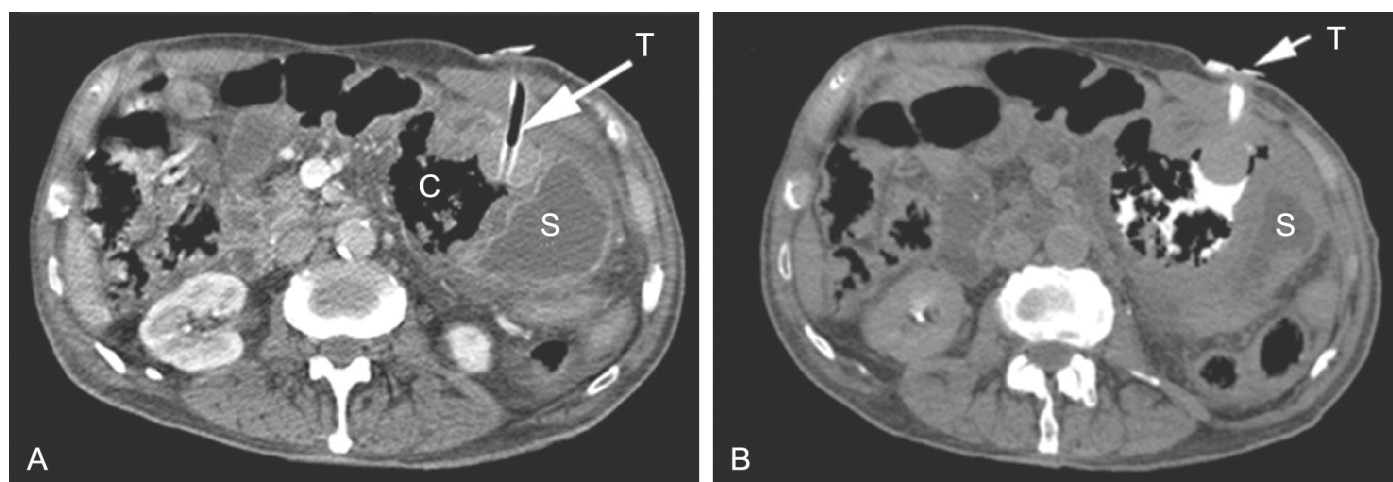


Figure 1. Abdominal CT. **A** – The extremity of the feeding tube (T) inserted within the abdominal collection (C), which displaced the stomach (S) to the left; **B** – Contrast medium filling the abdominal collection after the injection through the feeding tube.

infection, stomal leakage, and tube dislodgment. Major complications are represented by severe wound infection, septicemia, dehiscence, aspiration, peritonitis, and gastrointestinal perforation or bleeding. The overall rate of complications after surgical gastrostomy varies between 35% and 60%.^{12,15-18} In the study by Consentini et al.,¹² the rate of major and minor complications were higher among those submitted to the surgical procedure.

Long-term complications of gastrostomy are usually minor and include skin ulceration, dislodgment of the feeding tube, and superficial abscesses. Severe long-term complications are rare. Govednnik, Cover and Regner¹⁹ reported a severe case of retrograde jejunoduodenogastric intussusception. In the case reported herein, a minor long-term complication occurred represented by the dislodgment of the feeding tube, followed by a major complication, which was the false path during the replacement of a new tube. No imaging control was held before refeeding the patient, and the diet infusion into the peritoneal cavity resulted in peritonitis, septicemia, and death.

We would like to emphasize the care during the replacement of a new feeding tube, because this maneuver is not always that simple. In these cases, a long time after the gastrostomy, one could expect that the stomach should be strongly adhered to the abdominal wall. However, as reinforced with this case report, this impression is seriously in doubt.

We conclude and advise that every feeding tube replacement should be accompanied by an imaging study control.

REFERENCES

1. Wollman B, D'Agostino HB, Walus-Wigle JR, Easter DW, Beale A. Radiologic, endoscopic, and surgical gastrostomy: an institutional evaluation and meta-analysis of the literature. *Radiology*. 1995;197(3):699-704. <http://dx.doi.org/10.1148/radiology.197.3.7480742>. PMID:7480742
2. Walker LG Jr. L. L. Staton, M.D., and the first successful gastrostomy in America. *Surg Gynecol Obstet*. 1984;158(4):387-8. PMID:6369586.
3. Minard G. The history of surgically placed feeding tubes. *Nutr Clin Pract*. 2006;21(6):626-33. <http://dx.doi.org/10.1177/0115426506021006626>. PMID:17119170
4. Baehr FH, Frehling S. The spivack gastrostomy. *N Engl J Med*. 1938;219(9):305-9. <http://dx.doi.org/10.1056/NEJM193809012190904>.
5. Stamm M. Gastrostomy by a new method. *Med News*. 1894;65:324-6.
6. Gauderer MWL, Ponsky JL, Izant RJ Jr. Gastrostomy without laparotomy: a percutaneous endoscopic technique. *J Pediatr Surg*. 1980;15(6):872-5. [http://dx.doi.org/10.1016/S0022-3468\(80\)80296-X](http://dx.doi.org/10.1016/S0022-3468(80)80296-X). PMID:6780678
7. Preshaw RM. A percutaneous method for inserting a feeding gastrostomy tube. *Surg Gynecol Obstet*. 1981;152(5):658-60. PMID:6784260.
8. Beres A, Bratu I, Laberge JM. Attention to small details: big deal for gastrostomies. *Semin Pediatr Surg*. 2009;18(2):87-92. <http://dx.doi.org/10.1053/j.sempedsurg.2009.02.005>. PMID:19348997
9. Ljungdahl M, Sundbom M. Complication rate lower after percutaneous endoscopic gastrostomy than after surgical gastrostomy: a prospective, randomized trial. *Surg Endosc*. 2006;20(8):1248-51. <http://dx.doi.org/10.1007/s00464-005-0757-6>. PMID:16865614
10. Oyogoa S, Schein M, Gardezi S, Wise L. Surgical feeding gastrostomy: are we overdoing it? *J Gastrointest Surg*. 1999;3(2):152-5. [http://dx.doi.org/10.1016/S1091-255X\(99\)80025-0](http://dx.doi.org/10.1016/S1091-255X(99)80025-0). PMID:10457338
11. Moller P, Lindberg CG, Zilling T. Gastrostomy by various techniques: evaluation of indications, outcome, and complications. *Scan J Gastroenterol*. 1999;34:1050-4.
12. Cosentini EP, Sautner T, Gnant M, Winkelbauer F, Teleky B, Jakesz R. Outcomes of surgical, percutaneous endoscopic, and percutaneous radiologic gastrostomies. *Arch Surg*. 1998;133(10):1076-83. <http://dx.doi.org/10.1001/archsurg.133.10.1076>. PMID:9790204
13. Stiegmann GV, Goff JS, Silas D, Pearlman N, Sun J, Norton L. Endoscopic versus operative gastrostomy: final results of a prospective randomized trial. *Gastrointest Endosc*. 1990;36(1):1-5. [http://dx.doi.org/10.1016/S0016-5107\(90\)70911-X](http://dx.doi.org/10.1016/S0016-5107(90)70911-X). PMID:2107116
14. Rustom IK, Jebreel A, Tayyab M, England RJ, Stafford ND. Percutaneous endoscopic, radiological and surgical gastrostomy tubes: a comparison study in head and neck cancer patients. *J Laryngol Otol*. 2006;120(6):463-6. <http://dx.doi.org/10.1017/S0022215106000661>. PMID:16772054
15. Akkersdijk WL, van Bergeijk JD, van Egmond T, et al. Percutaneous endoscopic gastrostomy (PEG): comparison of push and pull methods and evaluation of antibiotic prophylaxis. *Endoscopy*. 1995;27(4):313-6. <http://dx.doi.org/10.1055/s-2007-1005699>. PMID:7555937
16. Jarnagin WR, Duh QY, Mulvihill SJ, Ridge JA, Schrock TR, Way LW. The efficacy and limitations of percutaneous endoscopic gastrostomy. *Arch*

- Surg. 1992;127(3):261-4. <http://dx.doi.org/10.1001/archsurg.1992.01420030023003>. PMID:1550470
17. Meguid MM, Williams LF. The use of gastrostomy to correct malnutrition. *Surg Gynecol Obstet.* 1979;149(1):27-32. PMID:451824.
18. Mamel JJ. Percutaneous endoscopic gastrostomy. *Am J Gastroenterol.* 1989;84(7):703-10. PMID:2500845.
19. Govednik C, Cover J, Regner JL. Preventing retrograde jejunoduodenogastric intussusception as a complication of a long-term indwelling gastrostomy tube. *Proc (Bayl Univ Med Cent).* 2015;28(1):34-7. PMID:25552793

Conflict of interest: None

Submitted on: January 13, 2015

Accepted on: February 20, 2015

Correspondence

Mateus Quitembo Soares da Silva

Hospital Universitário USP

Avenida Professor Lineu Prestes, 2565 – Cidade Universitária – São Paulo/SP – Brazil

CEP: 05508-000

E-mail: mquitembo@gmail.com