

# Clear cell odontogenic carcinoma in maxilla: A rare case report

Swapna Amod Patankar<sup>1</sup>, Pratik Raut<sup>2</sup>, Amod Pramod Patankar<sup>3</sup>, Rajesh Ashok Kshirsagar<sup>3</sup>

Departments of <sup>1</sup>Oral and Maxillofacial Pathology and Oral Microbiology and <sup>3</sup>Oral and Maxillofacial Surgery, Bharati Vidyapeeth Dental College and Hospital, <sup>2</sup>Consultant Maxillofacial Surgeon in Pune, Pune, Maharashtra, India

## Abstract

A rare and aggressive form of tumor with a female predilection and more seen with mandible is the clear cell odontogenic carcinoma (CCOC). The World Health Organization categorized it as a malignant neoplasm in 2005. This type of tumor is characterized by local recurrences as well as distant metastasis apart from being highly aggressive in nature. Due to the presence of clear cells, it is a diagnostic challenge to the pathologist. Only about 84 cases of maxillary variant have been reported in the literature. Here, we present a case report of a 31-year-old male with CCOC in the maxilla from the pathological and diagnostic point of view.

**Keywords:** Clear cell odontogenic tumor, clear cells, male, maxilla, rare

**Address for correspondence:** Dr. Swapna Amod Patankar, "Shree" 35/1 Padma Darshan Housing Society Survey Number 62B, Parvati, Pune - 411 009, Maharashtra, India.

E-mail: swapna.patankar@gmail.com

**Submitted:** 16-Jul-2020, **Received:** 05-Oct-2020, **Accepted:** 08-Oct-2020, **Published:** 09-Jan-2021

## INTRODUCTION

A rare and aggressive form of tumor with a female predilection and more seen with mandible is the clear cell odontogenic carcinoma (CCOC).<sup>[1]</sup> The World Health Organization categorized it as a malignant neoplasm in 2005. This type of tumor is characterized by local recurrences as well as distant metastasis apart from being highly aggressive in nature.<sup>[2]</sup> Due to the presence of clear cells, it is a diagnostic challenge to the pathologist. About 84 cases of maxillary variant have been reported so far, and because of its rarity, the diagnosis can be missed easily.

## CASE HISTORY

A 31-year-old male reported with the chief complaint of swelling on the upper left anterolateral region of the mouth. The swelling grew gradually in size over a span of 6 months.

It was initially painless but later become painful. The pain was more on the outer aspect of the upper left part of the cheek. Eventually, when the patient had reported to our department, he was having unbearable pain in the nose and surrounding left eye region [Figure 1].

External examination of the swelling showed a solitary swelling measuring 3 cm × 4 cm in size that extended from the upper left of part of the cheek, extending in nasal area, the zygomatic arch and lower border of the left eye. It had an irregular surface, well-demarcated border and covered by intact skin. It was firm consistency and was nontender without any signs of bleeding or pus discharge. There was no local rise of temperature over the skin covering the swelling. No abnormality was noted with the temporomandibular joint. The eyesight was not compromised, though the area around the eye was painful.

### Access this article online

#### Quick Response Code:



#### Website:

www.jomfp.in

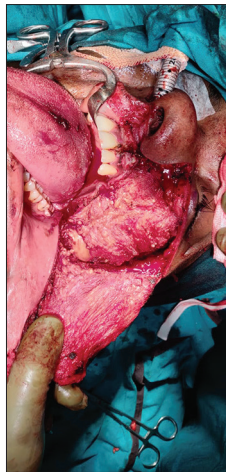#### DOI:

10.4103/jomfp.JOMFP\_298\_20

This is an open access journal, and articles are distributed under the terms of the Creative Commons Attribution-NonCommercial-ShareAlike 4.0 License, which allows others to remix, tweak, and build upon the work non-commercially, as long as appropriate credit is given and the new creations are licensed under the identical terms.

**For reprints contact:** WKHLRPMedknow\_reprints@wolterskluwer.com

**How to cite this article:** Patankar SA, Raut P, Patankar AP, Kshirsagar RA. Clear cell odontogenic carcinoma in maxilla: A rare case report. J Oral Maxillofac Pathol 2020;24:590.



**Figure 1:** Surgical site photograph of the patient

Left submental and submandibular lymph nodes along with cervical lymphadenopathy (of level 1, 2, 3 and 4) were observed in the patient. There was no relevant medical or dental history in the recent years associated with the patient.

Intraoral features of the swelling: the swelling extended from right maxillary first premolar to the first molar. The swelling was characterized by a normal mucosal covering, nonmovable/fixed, nontender, no pus or blood discharge, no ulceration of the overlying mucosa. The swelling had an irregular surface texture and well-defined borders.

### Investigations

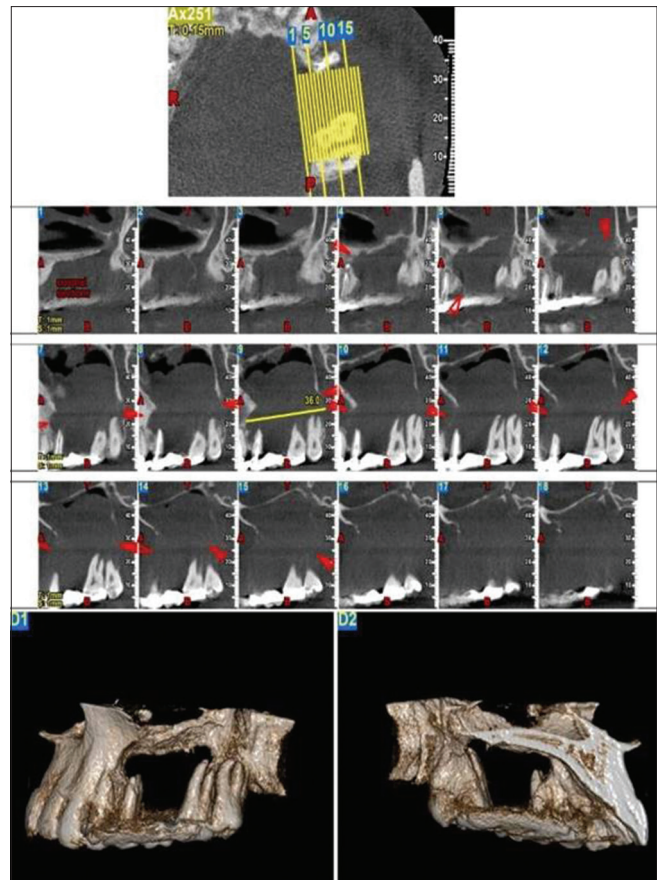
The following investigations were carried out. These include radiographs (cone-beam computer tomography), complete hemogram, incisional biopsy and abdominal ultrasonography (USG). Abdominal USG was carried out to rule out any primary or secondary tumor. USG reports were normal ruling out any metastasis to or from any other soft-tissue tumor.

### Radiographic features

It showed both buccal as well as a lingual cortical plate expansion. A well-defined, corticated, unilocular radiolucent lesion with irregular borders was visible; extending from 24 to 26 regions on the orthopantomogram. General physical findings such as ultrasonography of the abdomen and chest were noncontributory. Based on the clinical and radiographic features, a provisional diagnosis of odontogenic cyst was made. The lesion was then surgically enucleated and sent for histopathological diagnosis [Figure 2].

### Histopathological features

The hematoxylin and eosin staining showed that the epithelium was odontogenic in nature. They demonstrated a biphasic cellular pattern (typical of CCOC). Small islands



**Figure 2:** Cone-beam computer tomography of the patient

of hyperchromatic, polygonal cells with eosinophilic cytoplasm were seen. These cells are seen surrounding the periphery of the tumor islands. Larger clear cells were separated by a clear delicate fibrous connective tissue stroma. Individual tumor cells had distinct cellular outline, round nuclei, prominent nucleoli and abundant clear cytoplasm. The cells exhibited a significant variable degree of nuclear and cytoplasmic pleomorphism. High mitotic activity was seen in the clear cells. At certain places, neural cells invaded the tissue [Figures 3 and 4].

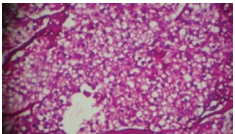
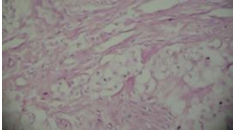
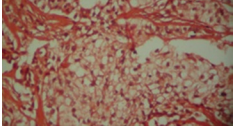
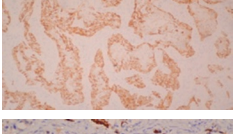
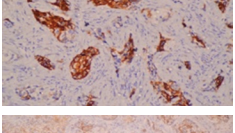
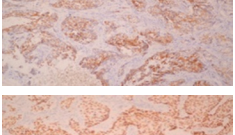
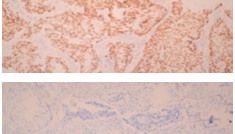
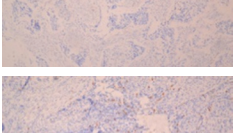
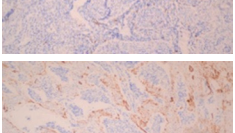

Table 1 shows the different stains that we used and the outcome of the same.

Different stains for histopathological diagnosis and the outcomes with these histopathological features and immunohistochemical profile, the diagnosis of CCOC were established.

### DISCUSSION

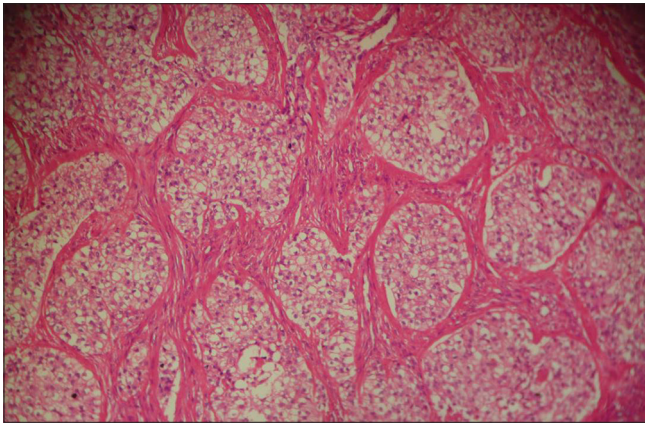
Hansen in 1985 coined the term “clear cell odontogenic tumor.” 1992 WHO classifications did not include this. However, later on the subsequent reporting and documentation led to its inclusion. Hence, the term tumor

**Table 1: Different Stains used and their outcome**

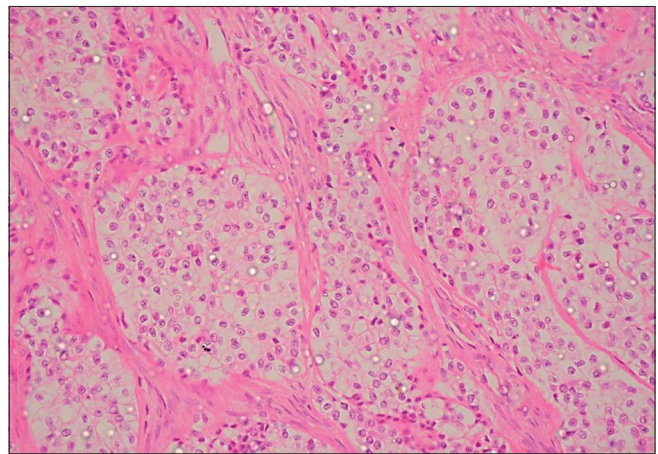
Stain	Finding	Figures
Per Iodic Acid Schiff Stain (PAS)	Tumour cells are showing abundant diastase degradable PAS-positive granules, but they are negative for mucin	
Mucicarmin Stain	Negative for mucin	
Congo red stain	Negative for amyloid deposit	
CK5/6	Tumor cells showed diffuse positivity	
CK- 7	Tumor cells showed and strong positivity	
CK- 19	Tumor cells showed weak positivity	
p63	Diffuse and strong nuclear positivity of the nuclear cells	
Calretinin	Negative in all tumour cells	
S-100 protein	Negative in all tumour cells	
SMA	Negative in tumour cells. Staining was noted in smooth muscle cells and blood vessels in the stroma	

**Table 2: The different considerations for the clear cell variety of tumors**

Is it odontogenic?	Is it salivary gland origin?	Is it metastatic?
Clear cell ameloblastoma: Odontogenic follicles exhibit VickersGorlin criteria	Acinic cell carcinoma: Acinar differentiation is evident	Uncommon to jaws Metastasis from kidney, prostate, liver and thyroid considered
Clear cell CEOT: polyhedral epithelial cells with prominent intercellular bridges and presence of amyloid and calcifications	Mucoepidermoid carcinoma: triphasic pattern (epidermoid, mucous and intermediate cells) with microcyst and macrocyst formation Hyalinizing clear cell carcinoma: less common in bone and there is presence of hyalinizing stroma	Renal clear cell carcinoma exhibits rich dilated prominent sinusoidal vascular network



**Figure 3:** Under  $\times 10$ : hematoxylin and eosin staining showing large clear cells separated by a delicate fibrous connective tissue stroma



**Figure 4:** Under  $\times 40$ : hematoxylin and eosin staining showing individual tumor cells have distinct cellular outline, round nuclei, prominent nucleoli and abundant clear cytoplasm

was replaced with carcinoma (CCOC).<sup>[1]</sup> CCOC has a female predilection with the male/female ratio of 1:1.8, and the majority of cases have been diagnosed in patients older than 40 years (81.0%). The mean age is 54.2 years, with 58.2 years for women and 41.8 years for men. Mandible is involved in 77.0% and maxilla in only 23% of cases.<sup>[3,4,5]</sup> Of the reported cases, 6.8% of cases have shown a radiopaque finding. Hence, lesion may be either radiolucent or radiopaque or mixed in nature.<sup>[6,7]</sup> CCOC may exhibit biphasic, monophasic and ameloblastomatous patterns. Monophasic patterns have all clear cells throughout the lesion. Most of the tumors report a biphasic pattern, having clear nest cells and islands of polygonal cells. These polygonal cells surround the tumor periphery. In case, it resembles the pattern like that of ameloblastoma; there are clear cells within the network of follicular cells.<sup>[8]</sup> The extent to which pleomorphism or hyperchromatism can occur varies from case to case and is not always a consistent parameter.<sup>[4]</sup> The differential diagnosis of clear cell carcinoma of the jaws has a long list such as odontogenic tumors, tumors of the salivary glands and metastatic renal carcinoma.<sup>[9]</sup>

Table 2 shows the different considerations for the clear cell variety of tumors.<sup>[10]</sup>

Based on the present case findings, we were able to rule out the salivary gland as S-100 protein test was negative and renal carcinomas since intratumoral hemorrhage was clinically not present. This could have been a case of ameloblastoma, but since the site and presentation were not conventional,<sup>[11]</sup> we ruled that out too. However, palisading was seen in the present case, which actually made us consider ameloblastoma as a differential diagnosis. The absence of amyloid as well as Liesegang's ring calcification ruled out CCCEOT also.<sup>[12]</sup> Mucoepidermoid carcinomas are distinguished by a triphasic architecture consisting of

mucin-positive mucous cells, squamoid cells, along with intermediate cells.<sup>[13]</sup> CK19 showed weak positivity, hence cannot be always definitive diagnosis.<sup>[1,2]</sup> Histopathological and immunological overlaps result in difficulty for differentiating CCOC from the clear cell carcinoma of the salivary gland in the maxilla. This type of tumor is reported to have a recurrence rate of 38.25%. Hence, long-term follow-up is necessary.

Three main mechanisms explain the clear cell change in cells:<sup>[12]</sup>

1. Sparsity/loss of cell organelles
  - Rough endoplasmic reticulum is reduced, its cisternae show vacuolization
  - Secretory granules are decreased
  - The predominance of immature granules with limited optical density
  - Mitochondria are swollen, show the vacuolar transformation.
2. Accumulation of intracytoplasmic substances (glycogen, mucin, lipids, tonofilaments and zymogen granules)
3. Artifacts due to fixation and histologic techniques.

### Treatment

Surgical control of CCOC was carried out with an en bloc resection of bone and soft-tissue involvement keeping 1 cm safe margins, to decrease the risk of recurrence. Adjuvant radiation therapy was given to this patient as there were extensive soft tissue and perineural invasion, positive nodes and/or extracapsular spread. Because of the potential for locoregional recurrence and/or late metastatic spread, the patient is kept under observation.<sup>[14]</sup>

### Recurrence

A recurrence of the same lesion at the same site was

observed after 1 year, which was treated with the radical surgical approach followed by radiation.

## CONCLUSION

CCOC is a rare tumor. It has variations in its histological appearance. Hence, considering a holistic view of the tumor is essential. Differential diagnosis is important to prepare the treatment plan for a long-term follow-up of the patients. More robust reporting is needed to understand the biological nature of such tumors.

## Declaration of patient consent

The authors certify that they have obtained all appropriate patient consent forms. In the form, the patient has given his consent for images and other clinical information to be reported in the journal. The patient understands that his name and initials will not be published and due efforts will be made to conceal identity.

## Financial support and sponsorship

Nil.

## Conflicts of interest

There are no conflicts of interest.

## REFERENCES

1. Elbeshir EI, Harris M, Barrett AW. Clear cell odontogenic carcinoma of the maxilla: Clinical, histological and immunohistochemical features of a case. *Oral Oncol Extra* 2004;40:91-4.
2. Tie-Jun L, Shi-Feng Y, Yan G, En-Bo W. Clear cell odontogenic carcinoma. *APLM* 2001;125:1566-71.
3. Gadiwan M, Paremala K, Soumya M, Hosthor SS. Histomorphological array in odontogenic keratocyst. *J Oral Maxillofac Pathol* 2013;17:143-5.
4. Swain N, Dhariwal R, Ray JG. Clear cell odontogenic carcinoma of maxilla: A case report and mini review. *J Oral Maxillofac Pathol* 2013;17:89-94.
5. Siraj F, Kaur M, Agrawal U. Clear cell odontogenic carcinoma of maxilla: A diagnostic challenge. *Clin Cancer Investig J* 2016;5:256-8.
6. Chaîne A, Pitak-Arnop P, Dhanuthai K, Bertrand JC, Bertolus C. An asymptomatic radiolucent lesion of the maxilla. Clear cell odontogenic carcinoma. *Oral Surg Oral Med Oral Pathol Oral Radiol Endod* 2009;107:452-7.
7. Nair MK, Burkes EJ, Chai-U-Dom O. Radiographic manifestation of clear cell odontogenic tumor. *Oral Surg Oral Med Oral Pathol Oral Radiol Endod* 2000;89:250-4.
8. Eversole LR, Duffey DC, Powell NB. Clear cell odontogenic carcinoma. A clinicopathologic analysis. *Arch Otolaryngol Head Neck Surg* 1995;121:685-9.
9. August M, Faquin W, Troulis M, Kaban L. Clear cell odontogenic carcinoma: Evaluation of reported cases. *J Oral Maxillofac Surg* 2003;61:580-6.
10. Priya NS, Annaji AG, Keerthi R, Umadevi HS. Clear cell odontogenic carcinoma of mandible: An unclarified entity. *J Oral Maxillofac Pathol* 2018;22:392-5.
11. Ellis GL. Clear cell neoplasms in salivary glands: Clearly a diagnostic challenge. *Ann Diagn Pathol* 1998;2:61-78.
12. Premalatha BR, Rao RS, Patil S, Neethi H. Clear cell tumours of the head and neck: An overview. *World J Dent* 2012;3:344-9.
13. Datar UV, Kamat MS, Kanitkar SS, Byakodi SS. Clear cell odontogenic carcinoma: A rare case report with emphasis on differential diagnosis. *J Cancer Res Ther* 2017;13:374-7.
14. Krishnamurthy A, Ramshankar V, Majhi U. Clear cell odontogenic carcinoma of the mandible and temporomandibular joint with cervical lymph nodal metastasis. *Natl J Maxillofac Surg* 2014;5:221-3.