

# Effective management of bone fractures with the IlluminOss® photodynamic bone stabilization system: initial clinical experience from the European Union registry

Thomas Gausepohl,<sup>1</sup> Dietmar Pennig,<sup>2</sup>  
Steffen Heck,<sup>2</sup> Sascha Gick,<sup>2</sup>  
Paul A. Vegt,<sup>3</sup> Jon E. Block<sup>4</sup>

<sup>1</sup>Lahn-Dill Kliniken, Wetzlar;

<sup>2</sup>St. Vinzenz Hospital GmbH, Cologne, Germany; <sup>3</sup>Department of Surgery, Albert Schweitzer Hospital, Dordrecht, The Netherlands;

<sup>4</sup>Independent consultant, San Francisco, CA, USA

## Abstract

The IlluminOss® system (IS) uses a light-curable polymer contained within an inflatable balloon catheter, forming a patient customized intramedullary implant. A registry was established in Germany and The Netherlands to prospectively collect technical and clinical outcomes in patients treated with IS for fractures of the phalange, metacarpal, radius, ulna, distal radius, fibula, clavicle and/or olecranon. Humeral, femoral, tibial and pelvic fractures were included under compassionate use. Procedural success included successful placement of the device at the target fracture site and achievement of fracture stabilization. Clinical and radiographic assessments were made postoperatively through 12 months. One hundred thirty two patients (149 fractures) were enrolled with most fractures (85%) resulting from low-energy trauma. Simple fractures predominated (47%) followed by complex (23%) and wedge (16%) fractures. Procedural success was achieved in all patients and no implants required removal or revision. Normal range of motion was realized in 87% of fractures. Radiographically, there was substantial cortical bridging, total dissolution of the fracture line, and complete fracture healing. Across a variety of fracture types, the IS provides a safe and effective approach for rapid healing and functional recovery.

## Introduction

The available treatment options for the management of fractures include simple immobilization, percutaneous wire place-

ment, intramedullary nail fixation, and open surgical stabilization with or without the use of plates, screws and bone graft. The choice of treatment is based, in large part, on the severity of fracture, the degree of comminution and loss of bone stock. However, several principles of internal fixation for fracture management are well established: sufficient anatomical reduction of the fracture fragments; stable internal fixation of the bone; preservation of blood supply; and, the ability to facilitate early, active, pain free motion of the associated muscles and joints.<sup>1</sup>

While traditional orthopedic devices provide the requisite amount of stabilization to achieve fracture repair in healthy bone, none of the current modalities are designed or appropriate for treating fragility fractures resulting from compromised osteoporotic bone. In this setting, the traditional treatment approaches are inadequate as the bone is functionally impaired and has reduced ability to hold screws or support implants. The IlluminOss® system (IS) provides a new treatment paradigm in the repair and stabilization of osteoporotic, pathologic or other compromised bone. In cases where internal fixation is indicated, the IS involves a minimally invasive surgical technique that allows clinicians to stabilize bone fractures using a light-curable polymer contained within an inflatable balloon catheter.

The IS received European regulatory approval (CE mark) in 2009 and is indicated for use in the reduction and alignment of fractures of non- to low-load bearing bones. In an effort to track the effectiveness and clinical utility of this fracture management approach in a real world setting, a medical device registry was established in Germany and The Netherlands in 2010. Herein, we provide the first reported characterization of patients enrolled in the registry with clinical and radiographic follow-up data.

## Materials and Methods

This is a multi-center European medical device registry, initiated at clinical sites in Germany and The Netherlands, to evaluate the ongoing utilization of the IlluminOss® photodynamic bone stabilization system (IlluminOss Medical, Inc., East Providence, RI, USA) in the management of fractures of non- to low-load bearing bones. The primary aim of the registry is to prospectively collect a consistent set of technical and clinical outcomes among patients treated with this novel fracture management system. The registry functions in accordance with the Declaration of Helsinki and with the

Correspondence: Jon E. Block, Independent consultant, San Francisco, CA, USA  
Tel: +1.415.775.7947 - Fax: +1.415.928.0765.  
E-mail: jb@drjonblock.com

Key words: Appendicular; Fractures; Long bone; Minimally-invasive; Photodynamic.

Contributions: all authors were involved in the study design and development of this manuscript. All authors read and approved the final manuscript.

Conflict of interest: JEB received financial support from IlluminOss® Medical for assistance with manuscript development. The authors declare no other conflict of interest in this work.

Acknowledgments: the authors thank Peter Shabe for radiographic data management support and Terry Meredith for assistance with manuscript preparation.

Received for publication: 22 November 2016.  
Revision received: 1 February 2017.  
Accepted for publication: 1 February 2017.

This work is licensed under a Creative Commons Attribution NonCommercial 4.0 License (CC BY-NC 4.0).

©Copyright T. Gausepohl et al., 2017  
Licensee PAGEPress, Italy  
Orthopedic Reviews 2017;9:6988  
doi:10.4081/or.2017.6988

Medical Research Involving Human Subjects and Good Clinical Practice guidelines. Following ethics approval at each clinical site, all patient supplied informed consent to participate in the registry.

Characterization and description of the device system, indications for use, procedural details and surgical technique have been published previously.<sup>2</sup> Briefly, the system is designed for use in bones that are not subjected to significant weight bearing forces, promotes fracture alignment, and provides appropriate stabilization via a minimally invasive percutaneous delivery system (Figure 1).

Under fluoroscopic guidance, an inflatable, thin-walled PET (Dacron®) balloon catheter is delivered through a small pathway into the intramedullary canal spanning the fracture site. The balloon is inserted via a small (~5 mm) pathway to the intramedullary canal, and filled with a light curable monomer expanding the balloon. A small diameter pathway allows for the creation of an implant many times larger than the original balloon shape and size. The expansion of the balloon within the canal creates an implant that fills the intramedullary space and contacts the bone

in a circumferential radial fashion (Figure 2). The implant is longitudinally strong and provides rotational stability without the need for locking screws. The resultant device is a patient-customized implant that is conformant to the shape, size and curvature of the patient's canal. More importantly, the implant provides a structural component analogous to that of normal bone strength over the entire contact span of the implant. The complete cortical contact area of the implant and resultant load dispersion provide a support pattern unlike any other implant and negates single point loading, a potential cause of implant failure and screw pull out. Unlike bone cement where the curing process cannot be controlled once the components are mixed, the IS polymer cures on demand and only upon the application of light emitted from a specialized source. This allows the surgeon the freedom and time to attain proper reduction and alignment of the fracture prior to initiating the hardening of the polymer. Using a standard syringe, a light activated, biocompatible monomer is infused into the balloon, causing it to expand, fill and conform to the size and shape of the patients' intramedullary canal. When the light system is activated it triggers the photo initiator in the monomer to rapidly polymerize and harden *in situ*. The cured implant provides both longitudinal strength and rotational stability to allow for fracture repair and sta-

bilization. Should ancillary fixation devices be needed they can be placed anywhere along the implant.

Patients are eligible to participate in the registry if they have been previously implanted with the device (retrospective) or have one or more of qualifying fractures and are scheduled for fracture treatment using the photodynamic system (prospective). Fractures of the phalange, metacarpal, radius, ulna, distal radius, fibula, clavicle and/or olecranon are included. Additionally, fractures of the humerus, femur, tibia and pelvis were also treated under compassionate use guidelines.

The primary outcome of the registry is the achievement of procedural success, as evidenced by the successful placement of the device at the target fracture site and the stabilization of the fracture. Specifically, procedural success involves introduction of the catheter into the medullary canal, infusion of the monomer into the balloon, curing of the monomer, separation from the delivery catheter and a stabilized fracture. Secondary outcomes, when available, include a longitudinal assessment of significant adverse events, the occurrence of ancillary interventions (*e.g.*, reoperations, revisions, removal, supplemental fixation, *etc.*), evidence of clinical healing (*i.e.*, return to pre-fracture mobility with no pain on palpation), range of motion, as well as disability and return to work status.

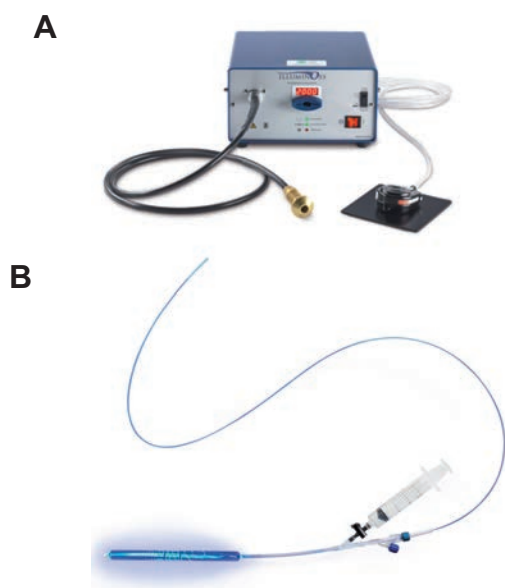
Optionally, the healing status of the fracture is evaluated serially using standard anteroposterior, lateral and oblique radiographs.

## Results

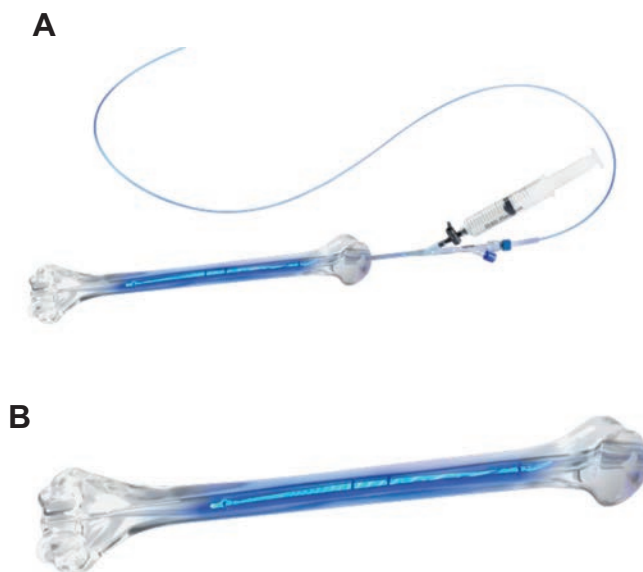
This report represents the initial assessment of this medical device registry. One hundred thirty-two (132) patients with 149 fractures have been enrolled in the registry and treated with the photodynamic bone stabilization system. Table 1 provides background characteristics for this population. Most patients (>80%) were older females who suffered a traumatic appendicular fracture, with smokers accounting for approximately 20% of the registry cases.

Table 2 provides a description of the fracture characteristics. There was a broad anatomical distribution with regard to fracture location. The average age of patients for most fracture types was greater than 75 years with the exception of metacarpal fractures that had an average age of 31 years. Almost 84% (125 of 149) were closed fractures with 107 (72%) fractures having prior treatment with cast immobilization; plates and screws were used previously in 16 (11%) fractures.

The average duration of the fracture reduction procedure was 116.4±59 minutes. Twenty different device sizes were used



**Figure 1.** The IlluminOss® photodynamic curing system (A) and *ex vivo* illustration of monomer infusion and complete containment within the balloon catheter (B).



**Figure 2.** Balloon expansion within the intramedullary canal with anatomical conformation (A) and on demand monomer curing with application of visible light (B).

ranging from 5x40 mm to 13x260 mm with 13x220 mm being the most common (20 of 149, 13%). Concomitant use of screws (35 of 149, 23%) and plate with screws (34 of 149, 23%) were employed somewhat commonly.

In 120 patients that required hospitalization following surgery, the average hospital stay duration was 8.3±9 days, but it varied widely based on fracture type. For example, the average hospital stay for metacarpal and distal radius fractures was 1.7±2 and 1.8±3 days, respectively, whereas patients with ulnar fractures averaged 8.4±10 days. Procedural success, the primary outcome, was achieved in all treated patients and range of motion was within normal limits in 87% (40 of 46) of patients reporting up to 3 months of follow-up, post-operatively.

A total of 5 adverse events were reported in 3 patients. None of the adverse events were considered related to the use of the device, although 2 of the events resulted in subsequent breakage of the implant. In the first case, the IS device was used to replace a failed plate/screw system. This implant subsequently failed and was supplemented with a new plate, which also failed. The second case involved an existing pseudoarthrosis where the attempt to resolve the matter using the IS implant was attempted but unsuccessful, resulting in removal of the implant. The third case had delayed bone healing. This patient was a treatment failure using a previously implanted traditional nail and was treated as a compassionate use patient.

Sixty-two patients (70 fractures) had at least one postoperative radiographic evaluation through 12 months of follow-up. For example, 53 patients (59 fractures) had radiographs taken during the immediate postoperative period, whereas 26 patients (30 fractures) and 23 patients (25 fractures) had 3 and 12 months of radiographic follow-up, respectively. At final follow-up, 67% (47 of 70) of fractures were adequately reduced without residual deformity with 84% (21 of 25) of fractures demonstrating adequate reduction in patients with 12 months of follow-up. Limb shortening was absent or < 5 mm in 86% (60 of 70) of fractures at final follow-up and 88% (22 of 25) of fractures at 12 months. Recurvatum/procurvatum deformity was absent in 73% (51 of 70) of fractures at final follow-up and 80% (20 of 25) of fractures at 12 months. There was no radiographic evidence of implant migration. Table 3 provides three separate radiographic assessments of fracture healing status. Healing outcomes were excellent with substantial cortical bridging, total dissolution (100%) of the fracture line, at the 3-month

**Table 1. Patients' demographic and baseline characteristics.**

Characteristics	Value (n=132)
Age, mean±SD (years)	72.1±17.9
Female, n (%)	106 (80.3)
Smokers, n (%)	25 (19.1)
Mechanism of injury, n (%)	
Traumatic	112 (84.8)
Non-traumatic	16 (12.1)
Not reported	4 (3.0)

SD, standard deviation.

**Table 2. Fracture characteristics.**

Variable	Value (n=149)
Fracture location, n (%)	
Radius	25 (16.8)
Ulna	24 (16.1)
Fibula	24 (16.1)
Metacarpal	14 (9.4)
Humerus	44 (29.5)
Femur	9 (6.0)
Sternum	1 (0.7)
Pelvis	4 (2.7)
Tibia	4 (2.7)
Fracture type, n (%)	
Simple	70 (47.0)
Complex	34 (22.8)
Wedge	24 (16.1)
Unspecified	21 (14.1)

**Table 3. Radiographic fracture healing status.**

Variable	12 months (n=25)	Last observation* (n=70)
Bridging cortices, n (%)		
0	1 (4)	6 (8.6)
1	0 (0)	1 (1.4)
2	0 (0)	2 (2.9)
3	0 (0)	3 (4.3)
4	24 (96)	43 (61.4)
NR	0 (0)	15 (21.4)
Fracture line dissolution, n (%)		
None	1 (4)	7 (10)
<25%	0 (0)	3 (4.3)
25%≤50%	1 (4)	2 (2.9)
50%≤75%	0 (0)	5 (7.1)
75%≤100%	3 (12)	8 (11.4)
100%	20 (80)	30 (42.9)
NR	0 (0)	15 (21.4)
Fracture healing, n (%)		
No healing	1 (4)	6 (8.6)
Partial healing	0 (0)	4 (5.7)
Progressive healing	4 (16)	20 (28.6)
Complete healing	20 (80)	25 (35.7)
NR	0 (0)	15 (21.4)

NR, not reported. \*Last observation represents final available radiographic follow-up from 1 month to 12 months, post-operatively.

follow-up time and complete healing, particularly among patients with 12 months of follow-up.

## Discussion

The genesis of the photodynamic bone stabilization system involves technology derivatives from a series of independent surgical technologies; catheters and balloons from interventional cardiology and interventional radiology, fiber optics from endoscopy, and monomers and polymers from dental cements. Unlike other deliveries of intramedullary cements and fillers, the IS material cures on demand, through the application of visible light.

This method offers percutaneous, customized, intramedullary stabilization of bone fractures that combines the longitudinal stability of intramedullary nailing, as well as rotational stability, without the need or requirement of ancillary hardware, with the versatility of the balloon kyphosis technique. However, unlike vertebral kyphoplasty, the IS maintains the hardened monomer within the confines of the delivery balloon, eliminating the risk of extravasation at the fracture site. The success of this procedural technique has been demonstrated and validated in a sheep tibial osteotomy model.<sup>3</sup>

The IS offers significant advantages to

surgeons for treating a variety of fractures. The procedure utilizes a minimally invasive catheter-based approach where the monomer-infused balloon can conform completely to canal geometry. *In situ* polymerization of the monomer to form a stable bone pin occurs at the surgeons' discretion through the application of visible light. Once hardened, the implant provides immediate stabilization and mechanical strength at the fracture site. Supplementary hardware can be employed anywhere along the length of the implant to provide additional stabilization, as necessary. From an imaging standpoint, the implant is radiolucent, providing improved visibility of the cortex to evaluate the healing process. The lack of opacity is also of value in the treatment of the pathologic patient population, as there is no scatter, and a review of the secondary metastasis is enhanced owing to improved imaging. Radiopaque spiral markings provide a 3-dimensional profile of the implant.

This medical device registry was initiated to provide real world, pragmatic experience with this novel system across a broad range of fracture types. It expands and complements other ongoing studies in specific fracture indications.<sup>4</sup>

## Conclusions

In this initial report of a European med-

ical device registry, patients treated with the photodynamic fracture management system experienced rapid healing and functional recovery post-operatively. This treatment approach offers a minimally invasive alternative to standard methods of fracture management.

## References

1. Matter P. History of the AO and its global effect on operative fracture treatment. *Clin Orthop Relat Res* 1998;347:11-8.
2. Vegt P, Muir JM, Block JE. The photodynamic bone stabilization system: a minimally invasive, percutaneous intramedullary polymeric osteosynthesis for simple and complex long bone fractures. *Med Devices (Auckl)* 2014;7:453-61.
3. Zani BG, Baird R, Stanley JR, et al. Evaluation of an intramedullary bone stabilization system using a light-curable monomer in sheep. *J Biomed Mater Res B* 2016;104:291-9.
4. Hagenars T, Van Oijen GW, Roerdink WH, et al. Functional recovery after treatment of extra-articular distal radius fractures in the elderly using the IlluminOss(R) System (IO-Wrist); a multicenter prospective observational study. *BMC Musculoskelet Dis* 2016;17:235.