

Intratesticular varicocele and extratesticular varicocele in a patient with nephrotic syndrome complicated by left renal vein thrombosis

Poovathumkadavil Mammunji Abduljaleel,* Fathima Al-Mulhim,* Asif Nouman,† Ahmed Kharouby,* Subhash Chandra Das †

Intratesticular varicocele is a rare condition, with a reported incidence of less than 2%.¹ Its clinical significance is not well established. The condition is characterized by dilatation of the intratesticular veins in and around the mediastinum testis. Color Doppler ultrasound can confirm the diagnosis. We present a case of a young man with nephrotic syndrome complicated by left renal vein thrombosis and left-sided extratesticular and intratesticular varicocele. To our knowledge, no case of intratesticular and extratesticular varicocele in a patient with nephrotic syndrome and a complicated left renal vein thrombosis has been reported concomitantly in the same patient.

Case

A 24 year-old man was diagnosed clinically with nephrotic syndrome and renal biopsy-proved membranous nephropathy and the patient was put on steroid and anti-diuretic therapy. Two weeks prior to admission he developed progressive abdominal distension and continuous, non-radiating dull aching pain in the left flank. Two days later he developed pain and swelling in the left side of the scrotum, which enlarged progressively. Abdominal ultrasound was done and the findings showed enlarged kidneys and increased echotexture with accentuation of cortico-medullary differentiation of both kidneys. The left kidney was more enlarged with a globular contour. The sinus echo was ill defined. The left renal vein was distended and the lumen showed echogenic thrombi. There was no appreciable flow on color Doppler imaging (Figure 1). The right renal vein and inferior vena cava were normal. A radiological diagnosis of bilateral renal parenchymal disease with left renal vein thrombosis was made. Scrotal ultrasound revealed

*From the *Department of Radiology; †Department of Internal Medicine, King Fahd Hospital of the University, Al Khobar, Saudi Arabia*

Correspondence and reprint requests:

Poovathumkadavil M. Abduljaleel, MD

P.O. Box 40044

*Department of Radiology
King Fahd Hospital of the
University*

Al Khobar

Saudi Arabia

dajaleel@rediffmail.com

Ann Saudi Med 2006;26(3):228-230

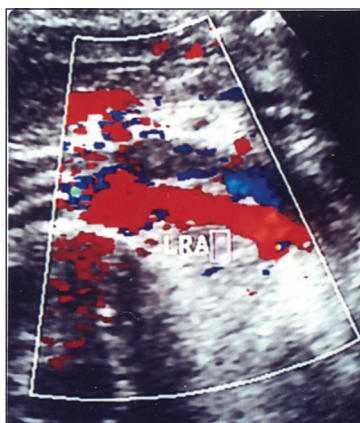


Figure 1. 24 year-old man with nephrotic syndrome and left vein thrombosis. Color Doppler ultrasound image revealed echogenic thrombus in the left renal vein and absence of flow. Normal left artery seen below the thrombosed vein.

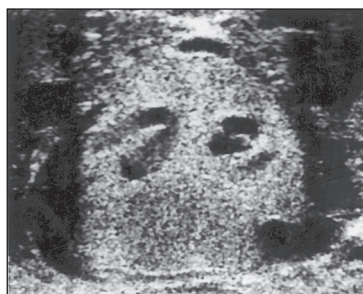

Figure 2a and 2b. Same patient shows intratesticular varicocele and extratesticular varicocele as hypoechoic structures on gray scale (a) and venous flow in color Doppler sonography (b).

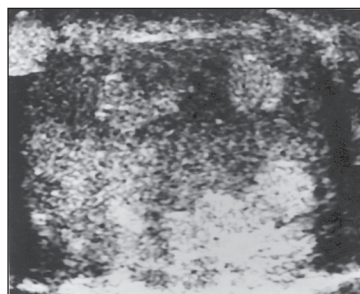



Figure 3. Follow-up gray scale ultrasound of the same patient one week after shows the venous channels are all became hyperechoic simulating focal mass lesions.

grossly dilated and tortuous hypoechoic veins in the left side of the scrotum. There were a few dilated hypoechoic venous channels seen in the mediastinum testis and in the testicular parenchyma. Color Doppler sonography confirmed the finding (Figure 2a and 2b). There was no appreciable change in size of the veins on Valsalva's maneuver, but the intensity of the color was increased. A dilated left testicular vein was traced up to its junction with a thrombosed left renal vein. Follow-up ultrasound after one week showed minimal peri-thrombal flow in the left renal vein. The venous channels in the left scrotal sac became more echogenic and intratesticular lesions became hyperechoic (Figure 3), but color Doppler sonography with Valsalva's maneuver showed flow within the hyperechoic veins, which suggested the veins were not thrombosed.

Discussion

The incidence of symptomatic or asymptomatic renal vein thrombosis is 16% to 42% in patients with nephrotic syndrome.²⁻⁴ The left testicular vein drains into the left renal vein. Thrombosis of the left renal vein as a cause of left-sided extratesticular varicocele is well known, but to our knowledge, its exact incidence is unknown.

Extratesticular varicocele is a common clinical condition, seen in approximately 8% to 20% of the normal adult male population,⁵⁻⁷ but intratesticular varicocele is a rare entity, with a reported incidence of 1.7% in symptomatic patients and 16% in patients

with infertility.¹ However, whether there is any relationship between male infertility and intratesticular varicocele is not known. Thirty-nine percent of patients with intratesticular varicocele had bilateral pathology and a significant number of these patients presented with infertility. Right-sided lesions were reported in 50%. Only 44% of patients with intratesticular varicocele have any associated extratesticular varicocele.¹ The occurrence of intratesticular varicocele in patients with cryptorchidism and orchiopexy was reported by various authors.^{9,20} The clinical implications and pathogenesis of intratesticular varicocele are not clear, but are believed to be similar to extratesticular varicocele, because of similar flow characteristics.⁸

Testicular pain is the commonest complaint and is attributed to stretching of the tunica albuginea from dilatation of the vein and venous congestion. Our patient also had testicular pain as a chief complaint. Other reported presenting features are infertility, orchitis, tenderness and scrotal mass.^{1,9,10} Recently, Nambirajan et al reported a case of intratesticular varicocele presenting with acute scrotum.¹⁸

Sonographically, the lesion appears as tubular structures in and around the mediastinum testis. Occasionally, oval-shaped lesions have been seen.¹ A finding of venous flow and reflux during Valsalva's maneuver on color Doppler and power Doppler sonography is diagnostic of intratesticular varicocele. No further study is required for confirmation.^{1,11,12} However, some authors have suggested that the venous structures need to be 2 mm or greater in diameter to establish a diagnosis.¹³ In our patient, on follow-up ultrasound, the lesion became hyperechoic to the testis, which could be due to stagnation of blood from long-standing obstruction. The lesion can easily be misdiagnosed as other hyperechoic lesions on gray-scale sonography, but color Doppler helps to identify the vascular structures. The intratesticular varicocele in this patient was a secondary type

caused by left renal vein thrombosis, hence there was no appreciable change in the size of the veins on Valsalva's maneuver. It is to be emphasized that Valsalva's maneuver, however, has little role in the diagnosis of secondary varicocele.

The differential diagnosis of hypoechoic lesions in the testes includes intratesticular cysts, tubular ectasia of rete testis, haematoma, focal infection and (rarely) cystic intratesticular neoplasm. These lesions will not show venous flow

on color Doppler ultrasound and a negative response to Valsalva's maneuver helps in differentiation from intratesticular varicocele.^{1,14,15}

Sclerotherapy and percutaneous embolisation are treatments reported for intratesticular varicocele.^{16,17} Das et al reported complete disappearance of the intratesticular varicocele after varicoectomy.¹ Diamond et al showed complete resolution of intratesticular varicocele following spermatic vein ligation in three youngsters.¹

References

1. Das KM, Prasad K, Szmigielski W, Noorani N. Intratesticular varicocele; evaluation using conventional and Doppler sonography. *AJR* 1999; 173: 1079-83
2. Cameron JS: The nephrotic syndrome and its complications. *Am J Kidney Dis* 1987; 10(3): 157-71
3. Llach F, Papper S, Massry SG: The Clinical spectrum of renal vein thrombosis: acute and chronic. *Am J Med* 1980; 69(6): 819-27
4. Velasquez Forero F, Garcia Prugue N, Ruiz Morales N: idiopathic nephrotic syndrome of the adult with asymptomatic thrombosis of the renal vein. *Am J Nephrol* 1988; 8(6): 457-62
5. Rifkin MD, Foy PM, Kurtz AB, Pasto ME, Goldberg BB. The role of diagnostic ultrasonography in varicocele evaluation. *J Ultrasound Med* 1983;2: 271-5
6. Wolverson MK, Houttuin E, Heiberg E, Sundaram M, Gregoroy J. High-resolution real time sonography of scrotal varicocele. *AJR* 1983; 141: 775-9
7. Petros JA, Andriole GL, Middleton WD, Picus DD. Correlation of testicular color Doppler ultrasonography, physical examination and venography in the detection of left varicocele in men with infertility. *J. Urol.* 1991; 145:785-8
8. Weis AJ, Kellman GM, Middleton WD, Kirkemo A. Intratesticular varicocele- sonographic finding in two patients: *AJR* 1992; 158: 1061-3
9. O'Donnell PG, Dewbury KC. Ultrasound appearance of intratesticular varicocele. *Br J. Radiol.* 1998; 71: 324-325
10. Belker AM. The varicocele and male infertility. *Urol Clin North Am* 1981;8: 41-44
11. Atasoy C, Fitoz M. Gray scale and color Doppler sonographic findings in intratesticular varicocele. *J. Clin. Ultrasound* 2001; 29: 369-73
12. Simon Strauss, Dan Leibovici. Intratesticular varicocele diagnosed by power Doppler sonography with valsalva's maneuver. *IMAJ* 2002;4:147-148
13. Gersovich EO., High resolution ultrasonography in the diagnosis of scrotal pathology. 1. Normal scrotum and benign disease. *J. Clin. Ultrasound* 1993;21: 355-73
14. Hamm B, Fobbe F, Loy V. Testicular cysts: Differentiation with US and clinical findings. *Radiology* 1998; 168: 19-23
15. Brown DL, Benson CB, Doherty FJ, et al. Cystic testicular mass caused by dilated rete testis: sonographic findings in 31 cases. *AJR* 1992; 158: 1257-59
16. Morvay Z, Nagy E. The diagnosis and treatment of intratesticular varicocele. *Cardiovasc. Intervent. Radiol.* 1998; 21:76-8
17. Demirba N, Ellergezen A, Bilen CY, Bayvat F. Intratesticular varicocele treated with percutaneous embolization. *Urology* 2001; 58: 1058
18. Thiagarajan Nambirajan , Siobhan Woolsey , Latha Manavalan , et al. Intra-testicular varicocele presenting as acute scrotum. *Scandinavian Journal of Urology and Nephrology* 2004; 38:179-181
19. Diamond DA, Roth JA, Cilento BG, Barnewolt CE. Intratesticular varicocele in adolescents: a reversible anechoic lesion of the testis. *J Urol.* 2004 Jan; 171(1): 381-3
20. Nuri Erdogan, Oguz Ekmekcoglu, Murat Baykara. Bilateral intra testicular varicocele in a patient with history of bilateral cryptorchidism. *Turk J Med Sci.* 2003; 33: 117-119