

# Right ventricle remodeling in chronic thromboembolic pulmonary hypertension

Jixiang Liu<sup>1,2,3,4,5</sup>, Peiran Yang<sup>6</sup>, Han Tian<sup>1,2,3,4,5</sup>, Kaiyuan Zhen<sup>1,2,3,4,7</sup>, Colm McCabe<sup>8</sup>, Lan Zhao<sup>8</sup>, Zhenguo Zhai<sup>1,2,3,4</sup>

<sup>1</sup>Department of Pulmonary and Critical Care Medicine, Center of Respiratory Medicine, China-Japan Friendship Hospital, Beijing 100029, China;

<sup>2</sup>National Center for Respiratory Medicine, Beijing 100029, China;

<sup>3</sup>National Clinical Research Center for Respiratory Disease, Beijing 100029, China;

<sup>4</sup>Institute of Respiratory Medicine, Chinese Academy of Medical Sciences, Peking Union Medical College, Beijing 100029, China;

<sup>5</sup>Graduate School of Peking Union Medical College, Chinese Academy of Medical Sciences and Peking Union Medical College, Beijing 100029, China;

<sup>6</sup>Department of Physiology, State Key Laboratory of Medical Molecular Biology, Institute of Basic Medical Sciences, Chinese Academy of Medical Sciences, School of Basic Medicine Peking Union Medical College, Beijing 100730, China;

<sup>7</sup>Peking University China–Japan Friendship School of Clinical Medicine, Beijing 100029, China;

<sup>8</sup>National Heart and Lung Institute (NHLI), Imperial College London, London SW72AZ, UK

## ABSTRACT

Chronic thromboembolic pulmonary hypertension (CTEPH) is an underdiagnosed, but potentially curable pulmonary vascular disease. The increased pulmonary vascular resistance in CTEPH is caused by unresolved proximal thrombus and secondary microvasculopathy in the pulmonary vasculature, leading to adaptive and maladaptive remodeling of the right ventricle (RV), eventual right heart failure, and death. Knowledge on the RV remodeling process in CTEPH is limited. The progression to RV failure in CTEPH is a markedly slower process. A detailed understanding of the pathophysiology and underlying mechanisms of RV remodeling may facilitate early diagnosis and the development of targeted therapy. While ultrasound, magnetic resonance imaging, right heart catheterization, and serum biomarkers have been used to assess cardiac function, the current treatment strategies reduce the afterload of the right heart, but are less effective in improving the maladaptive remodeling of the right heart. This review systematically summarizes the current knowledge on adaptive and maladaptive remodeling of the right heart in CTEPH from molecular mechanisms to clinical practice.

**Key words:** chronic thromboembolic pulmonary hypertension, right ventricular failure, maladaptive remodeling, pathophysiology, targeted medicine

## INTRODUCTION

Chronic thromboembolic pulmonary hypertension (CTEPH) belongs to Group 4 of “pulmonary hypertension (PH) due to pulmonary artery obstruction” in the clinical classification.<sup>[1]</sup> CTEPH is diagnosed after at least 3 months of effective anticoagulation, with evidence of chronic thrombi and precapillary PH.<sup>[2]</sup> It is caused by single or recurrent pulmonary embolism (PE), followed by thromboembolic organization, pulmonary vascular obstruction, and remodeling. The

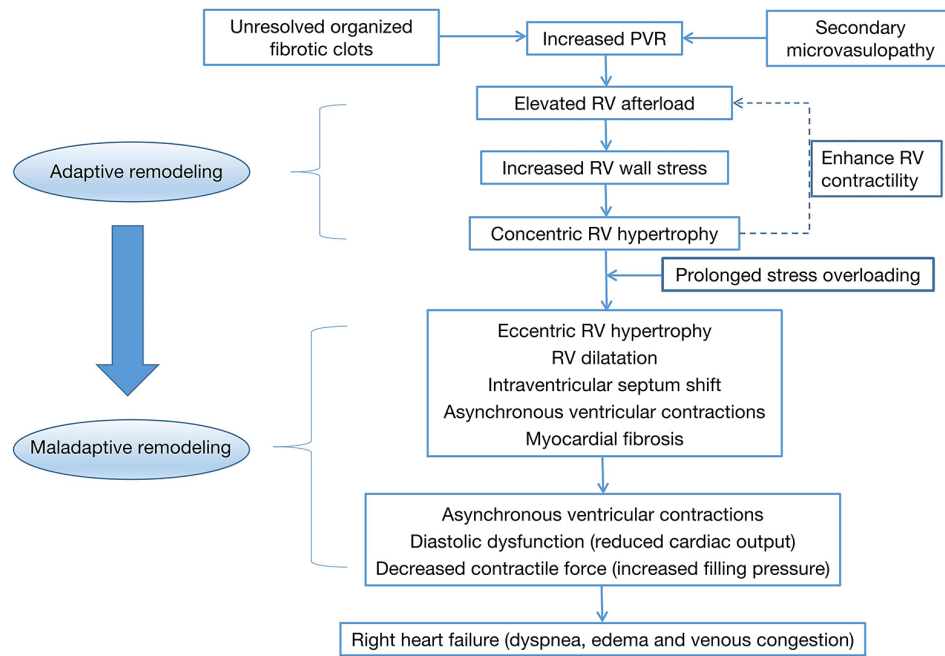
obstruction of the pulmonary artery (PA) by unresolved organized fibrotic clots and the secondary microvasculopathy are the two distinctive pathological characteristics of CTEPH, leading to increased pulmonary artery pressure (PAP) and progressive right ventricular (RV) failure.<sup>[3]</sup> Available therapies, such as pulmonary endarterectomy (PEA) and balloon pulmonary angioplasty (BPA), have been shown to reverse RV remodeling partially.<sup>[4]</sup> However, RV dysfunction remains difficult to normalize in most CTEPH cases and greatly impacts the quality of life of patients.<sup>[5]</sup> It is necessary and important to rectify the impaired RV function in the

**Address for Correspondence:**  
Prof. Zhenguo Zhai, Department of Pulmonary and Critical Care Medicine, Center of Respiratory Medicine, China–Japan Friendship Hospital, No. 2 East Yinghua Road, Chaoyang District, Beijing 100029, China.  
E-mail: zhaizhenguo2011@126.com

### Access this article online

**Website:**  
www.intern-med.com

**DOI:**  
10.2478/jtim-2022-0027



**Figure 1: The pathophysiology of chronic right heart failure in chronic thromboembolic pulmonary hypertension. PVR: pulmonary vascular resistance; RV: right ventricle; LV: left ventricle.**

treatment of CTEPH. Here, we review the characteristics of RV dysfunction, the underlying pathophysiological mechanisms, and potential interventions targeting right heart remodeling in CTEPH.

## CHARACTERISTICS OF THE RV IN THE NATURAL COURSE OF CTEPH

In acute PE and chronic thromboembolic pulmonary disease (CTEPD), RV dysfunction has a strong impact on the prognosis of patients. In CTEPH, the RV ejection fraction (EF) and interventricular septal wall thickness significantly decreased, while the end-systolic volume (ESV) and the end-diastolic volume (EDV) were increased compared to healthy controls.<sup>[6]</sup> In contrast, acute thrombotic obstruction secondary to PE causes an abrupt increase in RV afterload, leading to RV dysfunction or even death.<sup>[7]</sup> The main feature distinguishing CTEPH from PE is the gradual increase of RV afterload due to secondary remodeling of small arteries and the adaptive or maladaptive remodeling of the myocardium. In addition, RV dysfunction may not be limited to CTEPH as it also occurs in patients with CTEPD characterized by a mean PAP <25 mmHg who demonstrate slower RV relaxation.<sup>[8]</sup>

The heterogeneity in RV adaptation may be more prominent in CTEPH patients in comparison to pulmonary arterial hypertension (PAH) patients. Compared to PAH patients with similar pulmonary vascular resistance (PVR), CTEPH patients have lower PAP, which possibly signifies a

relative lack of RV adaptation.<sup>[9]</sup> It has been shown that the correlation coefficient of RV diastolic stiffness to afterload in CTEPH is significantly higher than that of idiopathic PAH.<sup>[10]</sup> The time constant of pulmonary circulation, representing the exponential pressure decay in the PA during diastole, was shown to be significantly shorter in CTEPH than that in idiopathic PAH. In addition, the time constant of proximal CTEPH was significantly lower than that of patients with distal disease.<sup>[11]</sup> Importantly, this change is mainly due to the early wave reflection in proximal CTEPH, which also contributes to RV dysfunction.<sup>[12]</sup> Impaired RV adaptability in CTEPH could be further affected due to the later onset of the condition, prolonged duration of RV dysfunction, and disease-specific changes in the pulmonary circulation.<sup>[13]</sup> CTEPH patients share similar microvascular pathology to that of patients with PAH, such as plexiform lesions from regions close to the pleura that are not obstructed and increased vascular resistance in the distal lung.<sup>[14,15]</sup> These studies provided evidences of certain similarities and differences in the RV remodeling between CTEPH and other diseases; nevertheless, more studies are needed for a detailed comparison.

## PATHOPHYSIOLOGY AND PROGRESSION OF RV REMODELING

In CTEPH, unresolved thrombus mechanically obstructs the PA and when combined with pulmonary microvasculopathy, it leads to increased PVR, resulting in a gradual increase in RV afterload. Initially, the RV increases the force of

contraction to maintain cardiac output, adapting to the increased afterload. Long-term pressure overload leads to RV dysfunction and failure. The pathophysiology of RV failure in CTEPH is shown in Figure 1.

Early drivers of the change in RV function in CTEPH include a long-term increase in RV afterload and ventricular wall stress. Ventricular pressure overload causes increased wall stress initially, leading to RV hypertrophy, which is characterized by increased RV wall thickness and cell size.<sup>[4]</sup> The increase in sarcomeres composed of contractile and cytoskeletal proteins results in myocardial cell enlargement unloading single muscle fibers, thereby improving the RV contractile efficiency.<sup>[6]</sup> This process is similar to left ventricular (LV) adaptive remodeling.<sup>[7]</sup>

Chronic pressure overload inevitably leads to subsequent maladaptive remodeling of the RV. The chronic obstruction of proximal vasculature and *in situ* thrombosis contributes to the continuous pressure overload, and the secondary microvasculopathy further aggravates the increase of afterload.<sup>[4]</sup> RV diastolic dysfunction, including increased ventricular stiffness, impaired filling, and prolonged isovolumic relaxation, may arise from diffuse myocardial fibrosis and may occur at a relatively early stage of the disease, as patients with PH show defective diastolic function and relatively preserved systolic function.<sup>[4]</sup> Increased myocardial oxygen consumption, resulting from the increase in ventricular wall stress, and decreased RV perfusion, predispose to diastolic dysfunction, decreased contractility, and myocardial fibrosis. Meanwhile, later-stage changes reduce RV stroke volume, causing insufficient filling of the left heart due to interventricular septal shift, which aggravates the severity of heart failure symptoms.<sup>[8]</sup> The level of tolerance of patients to RV pressure overload is heterogeneous, mainly due to variations in the response to high PA pressure, load, and myocardial and neurohumoral regulation.<sup>[4]</sup>

Decompensated RV failure is regulated by the heart itself and by various compensatory mechanisms and sympathetic nerve overstimulation. A thorough understanding of the pathophysiological progression of RV remodeling may help determine the state of the right heart in patients and better direct the clinical practice. Moreover, the identification of key mechanisms and targeted intervention toward RV remodeling are essential to improve or ultimately reverse maladaptive remodeling of RV.

## MOLECULAR MECHANISMS OF MALADAPTIVE RV REMODELING

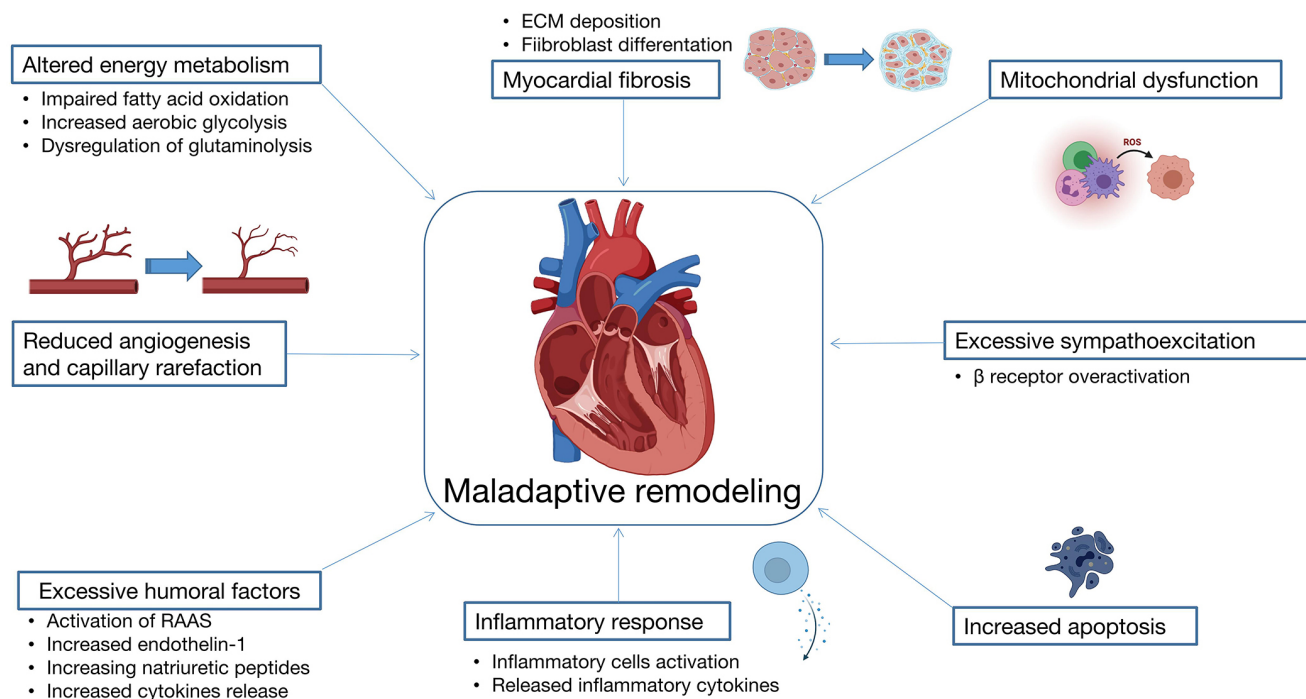
Few studies have investigated and elucidated the mechanisms of right heart changes in CTEPH. The

principal limitations are the lack of stable animal models and the scarcity of human myocardial tissue. Importantly, severe right heart structural changes appear in the late stage of CTEPH, whereas the early functional changes may be mild and easily overlooked.

Myocardial fibrosis, as a hallmark pathological process of maladaptive ventricular hypertrophy, involves the participation of a variety of molecules in the differentiation and scar formation.<sup>[19]</sup> A study of RV histopathology in CTEPH autopsy cases found apparent interstitial fibrosis in the right heart, where the area of RV collagen deposition was 15.7%.<sup>[20]</sup> Transforming growth factor- $\beta$  (TGF- $\beta$ ), a known key molecule in fibrosis, is involved in extracellular matrix (ECM) deposition by upregulating the expression of ECM and tissue inhibitors of matrix metalloproteinase genes and downregulating the expression of matrix metalloproteinase genes.<sup>[19,21]</sup> The oxidative stress response may also amplify the ECM remodeling mediated by TGF- $\beta$ , inducing myofibroblast differentiation through nicotinamide adenine dinucleotide phosphate hydrogen (NADPH) oxidase and aggravation of myocardial fibrosis.<sup>[19]</sup> In experimental models of CTEPH, there is a faster RV fibrosis progression with an enlargement of cardiomyocytes, compared with the sham-operated animals.<sup>[22,23]</sup> Inhibition of myocardial fibrosis is the key to the improvement of maladaptive remodeling of RV.

Another pathological process involved in the RV remodeling process is phenotypic shift in energy metabolism. When hypoxia or cardiac insufficiency occurs, the energy supply mode switches from fatty acid oxidation (FAO) to glycolysis and the local tissue lactic acid accumulation damages the myocardium. RV glucose uptake in patients with PH is increased, as shown by measuring myocardial 18F-FDG.<sup>[24,25]</sup> In the hypertrophic RV of PAH, the shifting of energy metabolism to aerobic glycolysis (*i.e.*, Warburg effect) leads to lactate accumulation and reduced energy production.<sup>[26,27]</sup> This glycolytic transition of adaptively remodeled RV tissue has been associated with increased angiogenesis, mainly mediated by hypoxia-inducible factor.<sup>[26]</sup> Additionally, increased fatty acid accumulation in the RV in CTEPH is significantly correlated with mean PAP, which is reversible after PEA as a result of decreased RV mass and altered metabolism.<sup>[28]</sup>

Hypertrophic RV tissue also shows decreased angiogenesis and capillary rarefaction.<sup>[29,30]</sup> Capillary rarefaction results from disturbed angiogenesis and injury to microvascular endothelial cells. Infusion of autologous intracoronary endothelial progenitor cells (EPCs) may improve the RV function and capillary density.<sup>[31]</sup> Insulin-like growth factor may mediate a protective role of EPCs in the left ventricle



**Figure 2: The proposed molecular mechanisms of RV remodeling. ECM: extracellular matrix; RAAS: renin-angiotensin-aldosterone system; RV: right ventricular.**

following myocardial infarction,<sup>[32]</sup> but the role of EPCs in the RV in CTEPH is still unclear. The expression of vascular endothelial growth factor (VEGF), acting as the main determinant of capillary growth and maintenance, is significantly reduced, and this correlates with decreased RV capillary density in maladaptive remodeling in contrast to preserved capillary density in adaptive remodeling.<sup>[26]</sup> Studies have found that cardiomyocyte-specific knockout of VEGF-B induced reprogramming of the cardiomyocyte metabolism, including increased glucose uptake and decreased FAO-related gene expression.<sup>[33]</sup> In addition, RV remodeling is associated with other potential mechanisms, as reflected by the increased expression of genes associated with inflammation, oxidative stress, and apoptosis.<sup>[30]</sup>

Based on the abovementioned evidences from CTEPH and PAH studies, we have proposed several potential pathological processes involved in the maladaptive remodeling of the right heart (Figure 2), including myocardial fibrosis, capillary rarefaction, metabolic conversion to glycolysis, mitochondrial dysfunction, inflammation, increased apoptosis, and overstimulation of neurohumoral factors. These pathophysiological changes of RV and the corresponding molecular mechanisms are potentially helpful for the early diagnosis and intervention of RV dysfunction in CTEPH.

## ASSESSMENT OF THE RV AFTERLOAD AND FUNCTION IN CTEPH

Echocardiography is a noninvasive screening examination method for measurement of PA pressure and cardiac function, while it is an indirect measure of RV hemodynamics. More detailed functional assessment of RV afterload can be performed by right heart catheterization, which may be further complemented by generation of RV pressure-volume loops. End-systolic ventricular elastance ( $E_{es}$ ) and arterial elastance ( $E_a$ ) reflect the contractility and afterload of the RV, respectively. While  $E_{es}/E_a$  ratio is correlated with the RV-PA coupling,<sup>[34]</sup> invasive assessment methods to obtain  $E_{es}/E_a$  using cardiac catheterization remain challenging. Importantly, the RV and PA should be studied together in the evaluation of CTEPH.<sup>[68]</sup> Gallium-labeled fibroblast activation protein inhibitor imaging has also been a promising indicator of activated fibroblasts in CTEPH patients.<sup>[35]</sup> Cardiac magnetic resonance imaging (CMR) is a noninvasive clinical assessment, which may be more suitable for the accurate and consistent evaluation of RV-PA coupling in CTEPH patients.<sup>[36]</sup> Although well suited for the follow-up of CTEPH, CMR is not yet fully integrated into routine clinical practice due to its limited accessibility.



**Table 1: Evaluation of right ventricular function in CTEPH patients after pulmonary endarterectomy by cardiac magnetic resonance imaging**

Reference	Number of patients (post-PEA)	Follow-up period	RV				
			Mass	EDV(I)	ESV(I)	SV(I)	EF
Kreitner <i>et al.</i> <sup>[39]</sup>	34	14 ± 8 days	NA	NA	NA	NA	↑
Surie <i>et al.</i> <sup>[40]</sup>	18 (17)	NA	↓	↓	↓	NSS*	↑
Waziri <i>et al.</i> <sup>[41]</sup>	19	12 months	↓	↓	↓	NSS	↑
Schoenfeld <i>et al.</i> <sup>[42]</sup>	19	12 days (average)	↓	↓	↓	↑	↑
Maschke <i>et al.</i> <sup>[43]</sup>	22	12 days (average)	↓	↓	↓	NSS	↑
Czerner <i>et al.</i> <sup>[44]</sup>	31	12 days (average)	↓	↓	↓	NA	↑
Ruigrok <i>et al.</i> <sup>[45]</sup>	68	6 months	NA	↓	↓	NA	↑
Mauritz <i>et al.</i> <sup>[46]</sup>	13	6 months	↓	↓	↓	NSS	↑
Claessen <i>et al.</i> <sup>[47]</sup>	15 (7)	NA	NA	NSS	↓	NSS	↑
Reesink <i>et al.</i> <sup>[48]</sup>	17	At least 4 months	↓	↓	↓	↑	↑
Armini <i>et al.</i> <sup>[49]</sup>	37 (35)	Discharge	NSS	↓	↓	NA	NSS
Rolf <i>et al.</i> <sup>[50]</sup>	65	NA	↓	↓	↓	↑	↑
Hardziyenka <i>et al.</i> <sup>[51]</sup>	No RVF 4	8 months (average)	↓	↓	NA	NSS	NSS
	RVF 16		↓	↓	NA	↑	↑
Berman <i>et al.</i> <sup>[52]</sup>	72	3 months	↓	↓	↓	↑	↑
Iino <i>et al.</i> <sup>[53]</sup>	22 (20)	1 month	NA	↓	↓	NA	↑

CTEPH: chronic thromboembolic pulmonary hypertension; PEA: pulmonary endarterectomy; RV: right ventricle; EDV(I): end-diastolic volume index; ESV(I): end-systolic volume index; SV(I): stroke volume index; EF: ejection fraction; RVF: right ventricular failure; NSS: not statistically significant; NA: not available. The arrows indicate statistically significant changes.

\*SVI increased significantly after 3 min of exercise in the post-PEA group compared to the pre-PEA group.

## TREATMENT STRATEGIES OF CTEPH AND THEIR EFFECTS ON THE RV

Current treatments of CTEPH include multiple strategies or their combinations. While these treatments improve the RV function, advanced CMR assessments have found that it is difficult for the RV to recover to normal performance after treatment.

### Partial reversal of rv remodeling after pea

PEA removes the proximal thrombus and apart of the thickened neointima, as well as segmental arteries, thus reducing the afterload of RV. PEA has been shown to relieve interventricular asynchrony and RV systolic wall stress, but it cannot recover the RV to its original healthy state, as shown by patients who, following PEA, exhibit abnormal exercise responses.<sup>[37,38]</sup> Findings from previous studies assessing the RV after PEA by CMR are shown in Table 1.<sup>[39–53]</sup>

The mass and function of the RV normalized by body surface area may improve 2 weeks after PEA.<sup>[42–44]</sup> In addition, tricuspid annular plane systolic excursion (TAPSE), an index of the RV systolic function, initially showed a downward trend after PEA and partially recovered after a 1-year follow-up. In this study, the short-term reduction in TAPSE postoperatively was mainly due to the temporary decline in overall cardiac function. The reason for the incomplete recovery after PEA may be that chronic elevation in afterload leads to a decrease in RV functional reserve. The increase in afterload is related to a decrease in PA compliance, rather than a slightly

elevated PVR.<sup>[54]</sup> Therefore, PEA partially reverses RV remodeling, but it infrequently returns to baseline levels, and so, a range of additional strategies are needed for further improvement.

### Improvement in the cardiac function after bpa

Inoperable CTEPH patients and patients with a low risk-benefit ratio for surgery often undergo BPA.<sup>[55,56]</sup> A meta-analysis of five echocardiographic studies shows that BPA can significantly reduce the RV basal diameter and increase the RV fractional area change, but the beneficial effects on TAPSE and tricuspid lateral annular systolic velocity ( $S^2$ ) are not significant.<sup>[57]</sup> CMR is also useful for evaluating the RV function in CTEPH patients after BPA. BPA significantly reduces the EDV and ESV of the RV, while improving RVEF.<sup>[58–61]</sup> In addition, BPA also improves the LV function to an extent.<sup>[58,59]</sup> However, it is proposed that a single BPA makes changes in pulmonary blood flow without improving cardiac function significantly.<sup>[62]</sup> It is interesting to note that the plasma concentration of soluble ST2 is increased in CTEPH patients and its levels decline significantly after several BPA intervention.<sup>[63]</sup> sST2 represents a potential prognostic biomarker of CTEPH.

The degree of improvement of RV function in patients with BPA varies, mainly due to the heterogeneity of patients treated, as there is no standardized indication for BPA.<sup>[64]</sup> As a complementary approach in the treatment of CTEPH, BPA further improves the cardiac function, but the degree of improvement is still limited.

### Medical therapies to *rv* remodeling of cteph

Pharmacological therapies, riociguat and treprostinil, are approved for the treatment of CTEPH.<sup>[3]</sup> In general, these improve RV function by reducing RV afterload; however, still, there is a lack of therapies directly targeting RV remodeling.

Studies have confirmed that RV remodeling may be alleviated by riociguat.<sup>[65–68]</sup> Moreover, sildenafil can directly mitigate myocardial interstitial fibrosis caused by RV dysfunction, as myocardial endothelin signaling is upregulated in the RV of PAH.<sup>[69,70]</sup> Recently, it has been found that the cardiac function improved after long-term subcutaneous administration of treprostinil in severe inoperable CTEPH.<sup>[71]</sup> Meanwhile, inhalation of iloprost significantly improved TAPSE and exercise capacity and partially reversed RV fibrosis in experimental model of PAH.<sup>[72]</sup> The mechanism of action of iloprost may involve reduced collagen synthesis and increased collagen turnover by cardiac fibroblasts.

RV remodeling-targeted drugs of the right heart are being developed in recent years. Beta-blockers are important in the treatment of heart failure and in the mitigation of ventricular remodeling.<sup>[73]</sup> Carvedilol, a selective  $\alpha 1/\beta 1/\beta 2$ -adrenergic receptor blocker, is effective in reversing RV remodeling in PAH.<sup>[74–76]</sup> In addition, partial fatty acid antioxidants could enhance the function of RV by reducing fatty acids and normalizing the oxidative phosphorylation of glucose.<sup>[77]</sup> Moreover, inhibiting myocardial mitochondrial FAO may protect the myocardium by reducing the production of reactive oxygen species.<sup>[78]</sup> Aldosterone has been reported to increase oxidative stress and promote inflammation and fibrosis of the heart.<sup>[79]</sup> A recent randomized controlled trial has found that spironolactone, an aldosterone antagonist, could relieve heart failure with preserved EF (HfpEF), reducing the markers of fibrosis in circulation.<sup>[80]</sup> Angiotensin-converting enzyme inhibitors or angiotensin receptor blockers are also known to reduce myocardial remodeling, but further research is needed to investigate their effects on the maladaptive overload-induced remodeling of the right heart.

### PROGNOSIS OF CTEPH BY RV DYSFUNCTION

RV dysfunction, caused by maladaptive remodeling, is widely recognized as the major determinant of long-term prognosis in CTEPH, including survival rate and quality of life.<sup>[1,2,81]</sup> CTEPH patients with surgical indication have significantly higher upstream resistance due to proximal fibrotic clots than those with inoperable CTEPH. The higher preoperative downstream resistance, indicating the existence of distal microvascular disease that resembles PAH, appears to be correlated to increased risk for

persistent PH and poor prognosis after PEA.<sup>[82]</sup> New York Heart Association (NYHA) functional class and right atrial pressure (RAP) are associated with mortality in CTEPH patients over a prolonged period of time. NYHA class IV was the most important predictor of death in both operated and non-operated CTEPH patients in comparison with NYHA class I and II patients, while RAP was correlated with mortality in non-operated patients.<sup>[83]</sup> However, it has also been controversial that the major cause of deaths in CTEPH after the perioperative period was attributed to RV failure.<sup>[84]</sup> The positive role of rehabilitation has been demonstrated in the improvement of the cardiac index at rest and during exercise among inoperable CTEPH patients, indicating that exercise training may improve RV function.<sup>[85,86]</sup> Furthermore, home-based rehabilitation might also be an efficient and practical option.

### FUTURE PROSPECTS

In CTEPH, the increase in PVR and afterload caused by unresolved thrombi and microvascular disease leads to right heart failure, resulting in a high mortality rate. A variety of mechanisms are involved in maladaptive remodeling of the RV. The use of CMR is important for assessing the improvement in RV function after treatment and may be more widely adopted and further optimized. In future research, it will be useful to combine laboratory blood-based testing with the parameters derived from CMR or echocardiography for a comprehensive analysis of the RV phenotypes in individual patients and for monitoring their disease progression.

Current treatment strategies are unable to completely reverse the maladaptive remodeling of the RV. Research on the RV in CTEPH is hindered by the limited availability of human tissue and robust animal models. Mechanistic studies comparing compensated hypertrophy and maladaptive remodeling may facilitate the discovery of novel targets to prevent decompensated remodeling while preserving more beneficial adaptation. Given the importance of RV function in the severity and prognosis of CTEPH patients, further investigation is desperately needed to develop interventions and therapies specifically targeting RV.

### Conflict of Interest

The authors declare that there is no conflict of interest.

### Source of Funding

This work was supported by the CAMS Innovation Fund for Medical Sciences (CIFMS) (No.2018-I2M-1-003); the National Key Research and Development Program

of China (No. 2016YFC0905600, 2016YFC0901104, 2018YFC1315100); National Natural Science Foundation of China (No. 81570049, 81970058); and Beijing Natural Science Foundation (No. 7152062).

## REFERENCES

- Galiè N, Humbert M, Vachiery JL, Gibbs S, Lang I, Torbicki A, *et al.* 2015 ESC/ERS Guidelines for the diagnosis and treatment of pulmonary hypertension. *Eur Heart J* 2016;37:67–119.
- Lang IM, Campean IA, Sadushi-Kolici R, Badr-Eslam R, Gerges C, Skoro-Sajer N. Chronic Thromboembolic Disease and Chronic Thromboembolic Pulmonary Hypertension. *Clin Chest Med* 2021;42:81–90.
- Delcroix M, Torbicki A, Gopalan D, Sitbon O, Klok FA, Lang I, *et al.* ERS statement on chronic thromboembolic pulmonary hypertension. *Eur Respir J* 2021;57:2002828.
- Simonneau G, Torbicki A, Dorfmüller P, Kim N. The pathophysiology of chronic thromboembolic pulmonary hypertension. *Eur Respir Rev* 2017;26:1–14.
- Van De Veerdonk MC, Marcus JT, Westerhof N, De Man FS, Boonstra A, Heymans MW, *et al.* Signs of right ventricular deterioration in clinically stable patients with pulmonary arterial hypertension. *Chest* 2015;147:1063–71.
- Roller FC, Wiedenroth C, Breithecker A, Liebetau C, Mayer E, Schneider C, *et al.* Native T1 mapping and extracellular volume fraction measurement for assessment of right ventricular insertion point and septal fibrosis in chronic thromboembolic pulmonary hypertension. *Eur Radiol* 2017;27:1980–91.
- Lang IM, Dorfmüller P, Noordegraaf AV. The pathobiology of chronic thromboembolic pulmonary hypertension. *Ann Am Thorac Soc* 2016;13:S215–21.
- McCabe C, White PA, Hoole SP, Axell RG, Priest AN, Gopalan D, *et al.* Right ventricular dysfunction in chronic thromboembolic obstruction of the pulmonary artery: A pressure-volume study using the conductance catheter. *J Appl Physiol* 2014;116:355–63.
- Quarck R, Nawrot T, Meyns B, Delcroix M. C-Reactive Protein. A New Predictor of Adverse Outcome in Pulmonary Arterial Hypertension. *J Am Coll Cardiol* 2009;53:1211–8.
- Braams NJ, van Leeuwen JW, Vonk Noordegraaf A, Nossent EJ, Ruigrok D, Marcus JT, *et al.* Right ventricular adaptation to pressure-overload: Differences between chronic thromboembolic pulmonary hypertension and idiopathic pulmonary arterial hypertension. *J Hear Lung Transplant* 2021;40:458–66.
- MacKenzie Ross R V., Toshner MR, Soon E, Naeije R, Pepke-Zaba J. Decreased time constant of the pulmonary circulation in chronic thromboembolic pulmonary hypertension. *Am J Physiol Hear Circ Physiol* 2013;305:H259–64.
- Fukumitsu M, Westerhof BE, Ruigrok D, Braams NJ, Groeneveldt JA, Bayoumy AA, *et al.* Early return of reflected waves increases right ventricular wall stress in chronic thromboembolic pulmonary hypertension. *Am J Physiol Hear Circ Physiol* 2020;319:1438–50.
- Lang IM, Simonneau G, Pepke-Zaba JW, Mayer E, Ambrož D, Blanco I, *et al.* Factors associated with diagnosis and operability of chronic thromboembolic pulmonary hypertension a case-control study. *Thromb Haemost* 2013;110:83–91.
- Gerges C, Gerges M, Friewald R, Fesler P, Dorfmüller P, Sharma S, *et al.* Microvascular Disease in Chronic Thromboembolic Pulmonary Hypertension: Hemodynamic Phenotyping and Histomorphometric Assessment. *Circulation* 2020;376–86.
- Moser KM, Bloor CM. Pulmonary vascular lesions occurring in patients with chronic major vessel thromboembolic pulmonary hypertension. *Chest* 1993;103:685–92.
- Veerdonk MC, Bogaard HJ, Voelkel NF. The right ventricle and pulmonary hypertension. *Heart Fail Rev* 2016;21:259–71.
- McCabe C, White PA, Hoole SP, Axell RG, Priest AN, Gopalan D, *et al.* Right ventricular dysfunction in chronic thromboembolic obstruction of the pulmonary artery: A pressure-volume study using the conductance catheter. *J Appl Physiol* 2014;116:355–63.
- Delcroix M, Noordegraaf AV, Fadel E, Lang I, Simonneau G, Naeije R. Vascular and right ventricular remodelling in chronic thromboembolic pulmonary hypertension. *Eur Respir J* 2013;41:224–32.
- Leask A. Getting to the heart of the matter: New insights into cardiac fibrosis. *Circ Res* 2015;116:1269–76.
- Asano R, Ogo T, Ohta-Ogo K, Fukui S, Tsuji A, Ueda J, *et al.* Prolonged QRS duration as a predictor of right ventricular dysfunction after balloon pulmonary angioplasty. *Int J Cardiol* 2019;280:176–81.
- López B, Ravassa S, Moreno MU, José GS, Beaumont J, González A, *et al.* Diffuse myocardial fibrosis: mechanisms, diagnosis and therapeutic approaches. *Nat Rev Cardiol* 2021;18:479–98.
- Noly PE, Guihaire J, Coblenz M, Dorfmüller P, Fadel E, Mercier O. Chronic thromboembolic pulmonary hypertension and assessment of right ventricular function in the piglet. *J Vis Exp* 2015:e53133.
- Arias-Loza PA, Jung P, Abeßer M, Umbenhauer S, Williams T, Frantz S, *et al.* Development and characterization of an inducible rat model of chronic thromboembolic pulmonary hypertension. *Hypertension* 2016;67:1000–5.
- Fang W, Zhao L, Xiong CM, Ni XH, He ZX, He JG, *et al.* Comparison of 18F-FDG uptake by right ventricular myocardium in idiopathic pulmonary arterial hypertension and pulmonary arterial hypertension associated with congenital heart disease. *Pulm Circ* 2012;2:365–72.
- Yang T, Wang L, Xiong CM, He JG, Zhang Y, Gu Q, *et al.* The ratio of 18F-FDG activity uptake between the right and left ventricle in patients with pulmonary hypertension correlates with the right ventricular function. *Clin Nucl Med* 2014;39:426–30.
- Sutendra G, Dromparis P, Paulin R, Zervopoulos S, Haromy A, Nagendran J, *et al.* A metabolic remodeling in right ventricular hypertrophy is associated with decreased angiogenesis and a transition from a compensated to a decompensated state in pulmonary hypertension. *J Mol Med* 2013;91:1315–27.
- Ryan JJ, Huston J, Kutty S, Hatton ND, Bowman L, Tian L, *et al.* Right ventricular adaptation and failure in pulmonary arterial hypertension. *Can J Cardiol* 2015;31:391–406.
- Sakao S, Miyachi H, Voelkel NF, Sugiura T, Tanabe N, Kobayashi Y, *et al.* Increased right ventricular fatty acid accumulation in chronic thromboembolic pulmonary hypertension. *Ann Am Thorac Soc* 2015;12:1465–72.
- Klinke A, Schubert T, Müller M, Legchenko E, Zelt JGE, Shimauchi T, *et al.* Emerging therapies for right ventricular dysfunction and failure. *Cardiovasc Diagn Ther* 2020;10:1735–67.
- Stam K, Cai Z, van der Velde N, van Duin R, Lam E, van der Velden J, *et al.* Cardiac remodelling in a swine model of chronic thromboembolic pulmonary hypertension: comparison of right vs. left ventricle. *J Physiol* 2019;597:4465–80.
- Loisel F, Provost B, Guihaire J, Boulate D, Arouche N, Amsellem M, *et al.* Autologous endothelial progenitor cell therapy improves right ventricular function in a model of chronic thromboembolic pulmonary hypertension. *J Thorac Cardiovasc Surg* 2019;157:655–66.
- Hynes B, Kumar AHS, O'Sullivan J, Klein Buneker C, Leblond AL, Weiss S, *et al.* Potent endothelial progenitor cell-conditioned media-related anti-apoptotic, cardioprotective, and pro-angiogenic effects post-myocardial infarction are mediated by insulin-like growth factor-1. *Eur Heart J* 2013;34:782–9.
- Kivelä R, Bry M, Robciuc MR, Räsänen M, Taavitsainen M, Silvola JM, *et al.* VEGF-B-induced vascular growth leads to metabolic reprogramming and ischemia resistance in the heart. *EMBO Mol Med* 2014;6:307–21.
- Schmeißer A, Rauwolf T, Groscheck T, Fischbach K, Kropf S, Luani B, *et al.* Predictors and prognosis of right ventricular function in pulmonary hypertension due to heart failure with reduced ejection fraction. *ESC*



- Hear Fail 2021;8:2968–81.
35. Chen BX, Xing HQ, Gong JN, Guo XJ, Xi XY, Yang YH, *et al.* Eur J Nucl Med Mol Imaging 2022;49:1211–22.
  36. Swift AJ, Wild JM, Nagle SK, Roldán-Alzate A, François CJ, Fain S, *et al.* Quantitative magnetic resonance imaging of pulmonary hypertension: A practical approach to the current state of the art. J Thorac Imaging 2014;29:68–79.
  37. Claeyss M, Claessen G, La Gerche A, Petit T, Belge C, Meyns B, *et al.* Impaired Cardiac Reserve and Abnormal Vascular Load Limit Exercise Capacity in Chronic Thromboembolic Disease. Imaging of cardiac fibroblast activation in patients with chronic thromboembolic pulmonary hypertension. JACC Cardiovasc Imaging 2019;12:1444–56.
  38. Klok FA, van Kralingen KW, van Dijk APJ, Heyning FH, Vliegen HW, Huisman M V. Prospective cardiopulmonary screening program to detect chronic thromboembolic pulmonary hypertension in patients after acute pulmonary embolism. Haematologica 2010;95:970–5.
  39. Kreitner KFJ, Ley S, Kauczor HU, Mayer E, Kramm T, Pitton MB, *et al.* Chronic thromboembolic pulmonary hypertension: Pre- and postoperative assessment with breath-hold MR imaging techniques. Radiology 2004;232:535–43.
  40. Surie S, Van Der Plas MN, Marcus JT, Kind T, Kloek JJ, Vonk-Noordegraaf A, *et al.* Effect of pulmonary endarterectomy for chronic thromboembolic pulmonary hypertension on stroke volume response to exercise. Am J Cardiol 2014;114:136–40.
  41. Waziri F, Ringgaard S, Mellekjær S, Bøgh N, Kim WY, Clemmensen TS, *et al.* Long-term changes of right ventricular myocardial deformation and remodeling studied by cardiac magnetic resonance imaging in patients with chronic thromboembolic pulmonary hypertension following pulmonary thromboendarterectomy. Int J Cardiol 2020;300:282–8.
  42. Schoenfeld C, Cebotari S, Hinrichs J, Renne J, Kaireit T, Olsson KM, *et al.* MR imaging-derived regional pulmonary parenchymal perfusion and cardiac function for monitoring patients with chronic thromboembolic pulmonary hypertension before and after pulmonary endarterectomy. Radiology 2016;279:925–34.
  43. Maschke SK, Schoenfeld CO, Kaireit TF, Cebotari S, Olsson K, Hoepfer M, *et al.* MRI-derived Regional Biventricular Function in Patients with Chronic Thromboembolic Pulmonary Hypertension Before and After Pulmonary Endarterectomy. Acad Radiol 2018;25:1540–7.
  44. Czermer CP, Schoenfeld C, Cebotari S, Renne J, Kaireit TF, Winther HB, *et al.* Perioperative CTEPH patient monitoring with 2D phase-contrast MRI reflects clinical, cardiac and pulmonary perfusion changes after pulmonary endarterectomy. PLoS One 2020;15:1–11.
  45. Ruijgrok D, Meijboom LJ, Nossent EJ, Boonstra A, Braams NJ, van Wezenbeek J, *et al.* Persistent exercise intolerance after pulmonary endarterectomy for chronic thromboembolic pulmonary hypertension. Eur Respir J 2020;55.
  46. Mauritz GJ, Vonk-Noordegraaf A, Kind T, Surie S, Kloek JJ, Bresser P, *et al.* Pulmonary endarterectomy normalizes interventricular dyssynchrony and right ventricular systolic wall stress. J Cardiovasc Magn Reson 2012;14:1–9.
  47. Claessen G, La Gerche A, Dymarkowski S, Claus P, Delcroix M, Heidebuchel H. Pulmonary vascular and right ventricular reserve in patients with normalized resting hemodynamics after pulmonary endarterectomy. J Am Heart Assoc 2015;4:e001602.
  48. D'Armini AM, Zanotti G, Ghio S, Magrini G, Pozzi M, Scelsi L, *et al.* Reverse right ventricular remodeling after pulmonary endarterectomy. J Thorac Cardiovasc Surg 2007;133:162–8.
  49. Reesink HJ, Marcus JT, Tulevski II, Jamieson S, Kloek JJ, Noordegraaf AV, *et al.* Reverse right ventricular remodeling after pulmonary endarterectomy in patients with chronic thromboembolic pulmonary hypertension: Utility of magnetic resonance imaging to demonstrate restoration of the right ventricle. J Thorac Cardiovasc Surg 2007;133:58–64.
  50. Rolf A, Rixe J, Kim WK, Börgel J, Möllmann H, Nef HM, *et al.* Right ventricular adaptation to pulmonary pressure load in patients with chronic thromboembolic pulmonary hypertension before and after successful pulmonary endarterectomy--a cardiovascular magnetic resonance study. J Cardiovasc Magn Reson 2014;16:96.
  51. Hardziyenka M, Campian ME, Reesink HJ, Surie S, Bouma BJ, Groenink M, *et al.* Right ventricular failure following chronic pressure overload is associated with reduction in left ventricular mass: Evidence for atrophic remodeling. J Am Coll Cardiol 2011;57:921–8.
  52. Berman M, Gopalan D, Sharples L, Screaton N, Maccan C, Sheares K, *et al.* Right ventricular reverse remodeling after pulmonary endarterectomy: Magnetic resonance imaging and clinical and right heart catheterization assessment. Pulm Circ 2014;4:36–44.
  53. Iino M, Dymarkowski S, Chaotawee L, Delcroix M, Bogaert J. Time course of reversed cardiac remodeling after pulmonary endarterectomy in patients with chronic pulmonary thromboembolism. Eur Radiol 2008;18:792–9.
  54. Ghio S, Crimi G, Guida S, Valentini A, Celentano A, Pin M, *et al.* Magnetic resonance imaging of pulmonary arterial compliance after pulmonary endarterectomy. Eur Respir J 2020;55.
  55. Kataoka M, Inami T, Kawakami T, Fukuda K, Satoh T. Balloon Pulmonary Angioplasty (Percutaneous Transluminal Pulmonary Angioplasty) for Chronic Thromboembolic Pulmonary Hypertension: A Japanese Perspective. JACC Cardiovasc Interv 2019;12:1382–8.
  56. De Perrot M, Thenganatt J, McRae K, Moric J, Mercier O, Pierre A, *et al.* Pulmonary endarterectomy in severe chronic thromboembolic pulmonary hypertension. J Hear Lung Transplant 2015;34:369–75.
  57. Li W, Yang T, Quan RL, Chen XX, An J, Zhao ZH, *et al.* Balloon pulmonary angioplasty reverse right ventricular remodelling and dysfunction in patients with inoperable chronic thromboembolic pulmonary hypertension: a systematic review and meta-analysis. Eur Radiol 2021;31:3898–908.
  58. Yamasaki Y, Nagao M, Abe K, Hosokawa K, Kawanami S, Kamitani T, *et al.* Balloon pulmonary angioplasty improves interventricular dyssynchrony in patients with inoperable chronic thromboembolic pulmonary hypertension: a cardiac MR imaging study. Int J Cardiovasc Imaging 2017;33:229–39.
  59. Sato H, Ota H, Sugimura K, Aoki T, Tatebe S, Miura M, *et al.* Balloon pulmonary angioplasty improves biventricular functions and pulmonary flow in chronic thromboembolic pulmonary hypertension. Circ J 2016;80:1470–7.
  60. Fukui S, Ogo T, Morita Y, Tsuji A, Tateishi E, Ozaki K, *et al.* Right ventricular reverse remodelling after balloon pulmonary angioplasty. Eur Respir J 2014;43:1394–402.
  61. Asano R, Ogo T, Ohta-Ogo K, Fukui S, Tsuji A, Ueda J, *et al.* Prolonged QRS duration as a predictor of right ventricular dysfunction after balloon pulmonary angioplasty. Int J Cardiol 2019;280:176–81.
  62. Schoenfeld C, Hinrichs JB, Olsson KM, Kuettner MA, Renne J, Kaireit T, *et al.* Cardio-pulmonary MRI for detection of treatment response after a single BPA treatment session in CTEPH patients. Eur Radiol 2019;29:1693–702.
  63. Banaszkiwicz M, Pietrasik A, Florczyk M, Kędziński P, Piłka M, Mańczak R, *et al.* Soluble ST2 as a Biomarker for Early Complications in Patients with Chronic Thromboembolic Pulmonary Hypertension Treated with Balloon Pulmonary Angioplasty. Diagnostics 2021;11:133.
  64. Darocha S, Araszkiwicz A, Kurzyńska M, Banaszkiwicz M, Jankiewicz S, Dobosiewicz A, *et al.* Balloon pulmonary angioplasty in technically operable and technically inoperable chronic thromboembolic pulmonary hypertension. J Clin Med 2021;10:1–13.
  65. Marra AM, Egenlauf B, Ehlken N, Fischer C, Eichstaedt C, Nagel C, *et al.* Change of right heart size and function by long-term therapy with riociguat in patients with pulmonary arterial hypertension and chronic thromboembolic pulmonary hypertension. Int J Cardiol 2015;195:19–26.
  66. Ahmadi A, Thornhill RE, Pena E, Renaud JM, Promislow S, Chandy G, *et al.* Effects of Riociguat on Right Ventricular Remodelling in Chronic Thromboembolic Pulmonary Hypertension Patients: A Prospective Study. Can J Cardiol 2018;34:1137–44.



67. Marra AM, Halank M, Benjamin N, Bossone E, Cittadini A, Eichstaedt CA, *et al.* Right ventricular size and function under riociguat in pulmonary arterial hypertension and chronic thromboembolic pulmonary hypertension (the RIVER study). *Respir Res* 2018;19:258.
68. Murata M, Kawakami T, Kataoka M, Moriyama H, Hiraide T, Kimura M, *et al.* Clinical Significance of Guanylate Cyclase Stimulator, Riociguat, on Right Ventricular Functional Improvement in Patients with Pulmonary Hypertension. *Cardiol* 2021;146:130–6.
69. Borgdorff MA, Bartelds B, Dickinson MG, van Wiechen MPH, Steendijk P, de Vroomen M, *et al.* Sildenafil treatment in established right ventricular dysfunction improves diastolic function and attenuates interstitial fibrosis independent from afterload. *Am J Physiol Hear Circ Physiol.* 2014;307: H361-9.
70. Nagendran J, Sutendra G, Paterson I, Champion HC, Webster L, Chiu B, *et al.* Endothelin axis is upregulated in human and rat right ventricular hypertrophy. *Circ Res* 2013;112:347–54.
71. Sadushi-Kolici R, Jansa P, Kopec G, Torbicki A, Skoro-Sajer N, Campean IA, *et al.* Subcutaneous treprostinil for the treatment of severe non-operable chronic thromboembolic pulmonary hypertension (CTREPH): a double-blind, phase 3, randomised controlled trial. *Lancet Respir Med* 2019;7:239–48.
72. Gomez-Arroyo J, Sakagami M, Syed AA, Farkas L, Van Tassell B, Kraskauskas D, *et al.* Iloprost reverses established fibrosis in experimental right ventricular failure. *Eur Respir J* 2015;45:449–62.
73. Yancy CW, Jessup M, Bozkurt B, Butler J, Casey DE, Colvin MM, *et al.* 2017 ACC/AHA/HFSA Focused Update of the 2013 ACCF/AHA Guideline for the Management of Heart Failure: A Report of the American College of Cardiology/American Heart Association Task Force on Clinical Practice Guidelines and the Heart Failure Society of America. *Circulation* 2017;136:e137–61.
74. Okumura K, Kato H, Honjo O, Breitling S, Kuebler WM, Sun M, *et al.* Carvedilol improves biventricular fibrosis and function in experimental pulmonary hypertension. *J Mol Med* 2015;93:663–74.
75. Bogaard HJ, Natarajan R, Mizuno S, Abbate A, Chang PJ, Chau VQ, *et al.* Adrenergic receptor blockade reverses right heart remodeling and dysfunction in pulmonary hypertensive rats. *Am J Respir Crit Care Med* 2010;182:652–60.
76. Grinnan D, Bogaard HJ, Grizzard J, Van Tassell B, Abbate A, DeWilde C, *et al.* Treatment of group I pulmonary arterial hypertension with carvedilol is safe *Am J Respir Crit Care Med* 2014;189:1562–4.
77. Fang YH, Piao L, Hong Z, Toth PT, Marsboom G, Bache-Wiig P, *et al.* Therapeutic inhibition of fatty acid oxidation in right ventricular hypertrophy: Exploiting Randle's cycle. *J Mol Med* 2012;90:31–43.
78. Wang P, Zhang F, Pan L, Tan Y, Song F, Ge Q, *et al.* Inhibiting Cardiac Mitochondrial Fatty Acid Oxidation Attenuates Myocardial Injury in a Rat Model of Cardiac Arrest. *Oxid Med Cell Longev* 2021:6622232.
79. Guitart-Mampel M, Urquiza P, Borges JJ, Lymperopoulos A, Solesio ME. Impact of Aldosterone on the Failing Myocardium: Insights from Mitochondria and Adrenergic Receptors Signaling and Function. *Cells* 2021;10:1552.
80. McDiarmid AK, Swoboda PP, Erhayiem B, Bounford KA, Bijsterveld P, Tyndall K, *et al.* Myocardial Effects of Aldosterone Antagonism in Heart Failure With Preserved Ejection Fraction. *J Am Heart Assoc* 2020;9:e011521.
81. Bonderman D, Skoro-Sajer N, Jakowitsch J, Adlbrecht C, Dunkler D, Taghavi S, *et al.* Predictors of outcome in chronic thromboembolic pulmonary hypertension. *Circulation* 2007;115:2153–8.
82. Kim NHS, Fesler P, Channick RN, Knowlton KU, Ben-Yehuda O, Lee SH, *et al.* Preoperative Partitioning of Pulmonary Vascular Resistance Correlates with Early Outcome after Thromboendarterectomy for Chronic Thromboembolic Pulmonary Hypertension. *Circulation* 2004;109:18–22.
83. Delcroix M, Lang I, Pepke-Zaba J, Jansa P, D'Armini AM, Snijder R, *et al.* Long-Term Outcome of Patients with Chronic Thromboembolic Pulmonary Hypertension : Results from an International Prospective Registry. *Circulation* 2016;133:859–71.
84. Cannon JE, Su L, Kiely DG, Page K, Toshner M, Swietlik E, *et al.* Dynamic risk stratification of patient long-term outcome after pulmonary Endarterectomy: Results from the United Kingdom national cohort. *Circulation* 2016;133:1761–71.
85. Ehlken N, Lichtblau M, Klose H, Weidenhammer J, Fischer C, Nechwatal R, *et al.* Exercise training improves peak oxygen consumption and haemodynamics in patients with severe pulmonary arterial hypertension and inoperable chronic thrombo-embolic pulmonary hypertension: A prospective, randomized, controlled trial. *Eur Heart J* 2016;37:35–44.
86. Mereles D, Ehlken N, Kreuzer S, Ghofrani S, Hoepfer MM, Halank M, *et al.* Exercise and respiratory training improve exercise capacity and quality of life in patients with severe chronic pulmonary hypertension. *Circulation* 2006;114:1482–9.

**How to cite this article:** Liu J, Yang P, Tian H, Zhen K, McCabe C, Zhao L, Zhai Z. Right ventricle remodeling in chronic thromboembolic pulmonary hypertension. *J Transl Intern Med* 2022; 10: 125-133.