



# Graft choice in combined anterior cruciate ligament and medial collateral ligament reconstruction

Francisco Figueroa<sup>1,2</sup>

David Figueroa<sup>1</sup>

Rafael Calvo<sup>1</sup>

Alex Vaisman<sup>2,3</sup>

João Espregueira-Mendes<sup>4,5,6,7,8</sup>

- There is a concern regarding which grafts should be used in combined anterior cruciate ligament (ACL) and medial collateral ligament (MCL) reconstructions, with a paucity of recommendations focused on this specific topic.
- Expert opinions suggest the use of allograft-only reconstructions to limit donor-site morbidity or using at least one allograft and one autograft.
- When a hamstring tendon autograft is harvested, techniques that maintain both the integrity of the sartorius fascia and the gracilis are recommended because of the role that the ST-G-S (semitendinosus-gracilis-sartorius) complex plays in valgus stability in the setting of an MCL-deficient knee.

**Keywords:** ACL; anterior cruciate ligament; combined; MCL; medial collateral ligament; MKI

Cite this article: *EFORT Open Rev* 2020;5:221-225.

DOI: 10.1302/2058-5241.5.190049

## Introduction

The medial collateral ligament (MCL) is the most commonly injured knee ligament, and an anterior cruciate ligament (ACL) rupture is the most frequently associated injury after an MCL lesion.<sup>1-4</sup> Successful outcomes after non-surgical treatment of isolated MCL injuries<sup>5</sup> have led many surgeons to advocate non-surgical treatment for the MCL in combined ACL and MCL injuries, with early (and therefore protected) or delayed ACL reconstruction (after the MCL has healed). However, MCL deficiency, even partial, has been reported to increase the forces on the ACL graft, and surgical intervention to re-establish the stabilizing properties of the MCL may benefit the healing of both the ACL graft and the MCL and overall knee stability.<sup>6</sup>

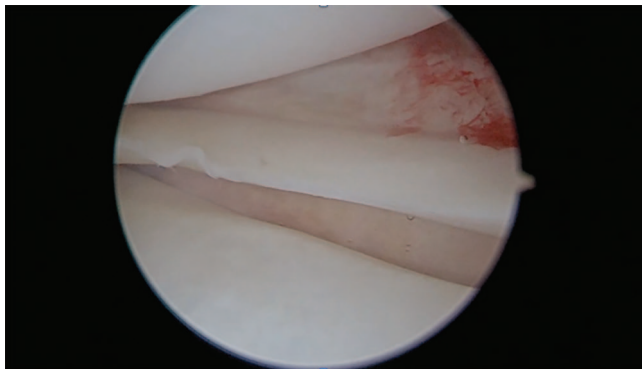
A recent study on 19,457 patients from the Swedish National Knee Ligament Registry<sup>7</sup> suggested that the presence of a concomitant MCL and ACL injury (regardless of the treatment performed on the MCL) was significantly associated with an increased risk of undergoing ACL revision compared with an isolated ACL injury. The risk of ACL revision was significantly increased for patients undergoing ACL reconstruction and non-surgical treatment of the concomitant MCL injury, while patients treated with either MCL suture repair or reconstruction did not display an increased risk of ACL revision compared with isolated ACL reconstruction.

Accordingly to this new evidence, we advocate surgical treatment of the MCL in combined ACL and MCL injuries in patients with grade III valgus instability in the initial setting, injuries with a low healing capacity (distal MCL lesions, Stener-like lesions and combined MCL and posterior oblique ligament [POL] lesions)<sup>8</sup> and persistent valgus instability after non-surgical treatment (especially grade II lesions with drive through sign or tibial lift-off sign during the diagnostic arthroscopy: Fig. 1). The decision to repair/augment or reconstruct the MCL depends on the chronicity of the injury, three weeks is our cut-off for repairing or reconstructing according to the viability of the soft tissues.

When reconstruction is the elected treatment, there is a concern regarding which grafts should be used in these combined injuries. As there is a paucity of recommendations focused on this specific topic, we decided to perform a review of the literature available and provide the reader with an algorithm specially made to deal with this clinical setting.

## Approach to the problem

As there are no publications regarding the election of the graft in this specific setting (combined ACL and MCL



**Fig. 1** Meniscus tibial lift-off sign in the medial compartment during a diagnostic arthroscopy.

reconstruction), the review of the literature was made by dividing the clinical scenario into three different questions, the first two being relatively uncommon questions in the scientific literature while the third question is one of the most important and published topics in knee surgery: (1) Which is the best graft in a setting of multiligamentary knee injuries (MKI)? (2) Which is the best graft in MCL injuries? (3) Which is the best graft in ACL injuries?

### Best graft in a setting of MKI

Few studies address graft choice in MKI as a study question. Alentorn-Geli et al<sup>9</sup> in a recent study focusing on factors that predict a poor outcome in surgical repair of MKI, demonstrated that patients treated with allograft had worse International Knee Documentation Committee (IKDC) score, range of motion (ROM), and percentage of normality compared to those not requiring the use of an allograft. This finding should be taken cautiously, because this study includes all kinds of MKI, including combined complete and partial lesions (for example complete ACL and partial MCL) and concomitant ACL and posterior cruciate ligament injuries. From a rational point of view, more complex knee injuries, involving more ligaments, and with a poorer prognosis, will require the use of an allograft, meaning that allograft use cannot be blamed as the responsible of a poor outcome.

Strauss et al<sup>10</sup> after a thorough review of the literature available concluded that allograft use is appealing in MKI because of the need for multiple grafts, the possibly poor condition of the autograft tissues and the attempt to limit further damage to the patient by harvesting autografts. They suggest that such practical issues may in fact outweigh clinical evidence.

Tisherman et al,<sup>11</sup> in another review of the literature, concluded that MKI represent a unique clinical challenge, and reconstruction of several injured tendons with autograft may not be in the best interests of the patient

due to donor-site morbidity and increased surgical time associated with autograft harvesting. Overall, multiple small studies<sup>12–14</sup> have shown that allograft is a viable graft choice in patients with MKI and results in a high rate of return to sport, good-to-excellent patient-reported outcomes, and restoration of knee stability.

#### *Conclusions on graft choice for MKI*

Without the existence of high-level evidence, and from a rational point of view, allograft tissue should be used in the context of MKI to limit the morbidity to the knee and the already damaged soft tissues. In the scenario of a combined ACL and MCL reconstruction, at least one ligament should be reconstructed using an allograft to limit donor-site morbidity.

### Best graft in MCL injuries

Again, there are scarce reports in the literature assessing graft choice as a study question in the context of MCL reconstruction. However, in recent years, Herbort et al<sup>15</sup> and Kremen et al<sup>16</sup> published cadaveric studies addressing the importance of the semitendinosus-gracilis-sartorius (ST-G-S) complex in knee stability in the setting of a MCL-deficient knee<sup>15</sup> and in the context of concurrent ACL and MCL injuries<sup>16</sup> respectively. Both studies conclude that the ST-G-S complex is of high importance for valgus stability in the MCL-deficient knee, in both cases of isolated MCL or combined ACL and MCL injury. Notably, Kremen et al<sup>16</sup> demonstrated that preserving the S fascia during ST-G harvesting achieves an almost normal valgus stability in the context of a reconstructed ACL with a partially deficient MCL.

#### *Conclusions on graft choice for MCL injuries*

Both Herbort et al's<sup>15</sup> and Kremen et al's<sup>16</sup> results have important clinical applications regarding graft choice recommendations or the surgical technique used for graft harvest. Given the importance of the ST-G-S complex in the concurrence of an MCL injury, if possible, ST-G harvesting should be avoided. But in cases where this is not possible, repairing or not disrupting the S fascia may help bolster medial knee stability in this setting. Techniques involving isolated ST autograft harvest, which maintain both the integrity of the S fascia and the G, would likely further decrease the potential risk of increased valgus stress on an ACL graft in the setting of concurrent MCL injuries.

### Best graft in ACL injuries

Graft choice in ACL surgery is one of the most studied topics in the scientific literature. The four most common options are: (1) hamstring (HT) autograft, (2) bone-tendon-bone (BTB) autograft, (3) quadriceps tendon (QT) autograft, and

(4) several types of allografts. Various authors have reported that equivalent clinical outcomes can be achieved when comparing autograft and non-irradiated allograft ACL reconstructions.<sup>17</sup> However, it is important to note that inferior outcomes with allografts have been reported in young (< 25 years), highly active patients.

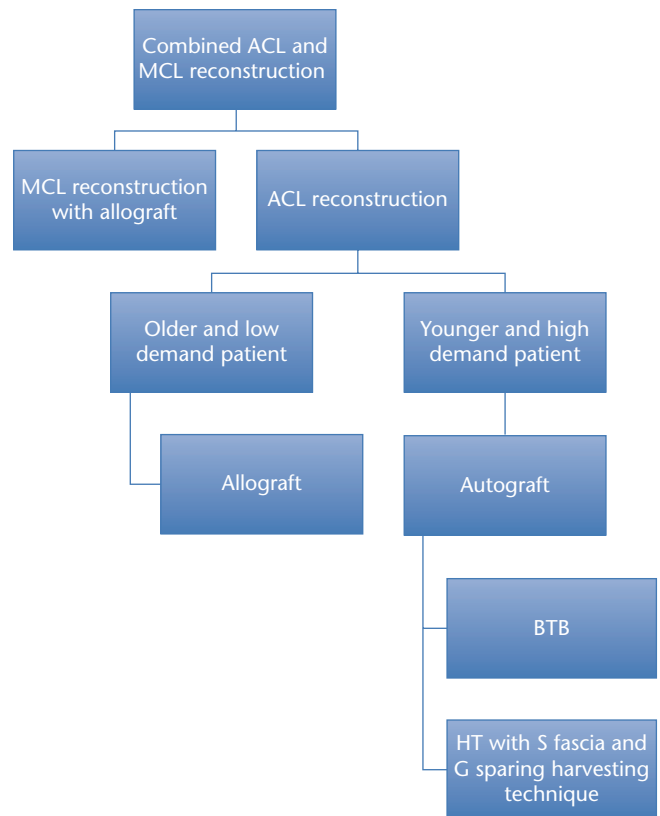
Regarding the different types of autografts, Schuette et al<sup>18</sup> in a systematic review of overlapping meta-analyses concluded that ACL reconstruction with a BTB autograft provides superior static knee stability and less risk of graft failure, but with an increased postoperative complication rate when compared with an HT autograft. There is also concern regarding anterior knee pain, with a risk ratio for anterior knee pain of 1.71 in favour of HT autografts and a risk ratio for kneeling pain of 2.05 in favour of HT autografts. QT autograft has also been described as a suitable graft alternative for primary ACL reconstruction,<sup>19</sup> as it achieves good clinical outcomes with a low incidence of anterior knee pain. However, given the limited quality of the studies regarding this graft, there is a need for a well-designed multicentre randomized control trial comparing QT autograft with other primary ACL autografts to confirm this assumption. Furthermore, new evidence from the Danish Ligament Reconstruction Registry<sup>20</sup> has shown that in spite of the fact that QT achieves excellent improvements in knee laxity and subjective outcome similar to BTB and HT grafts, there is a concern about the high revision rate within two years (more than two times that of the other autografts) and more knee laxity.

### Conclusions on graft choice for ACL injuries

Graft choice in ACL surgery has been widely studied. The decision about which graft to use remains controversial and is probably based more on the surgeon's personal preferences rather than on evidence from clinical studies. There are some controversies with the use of allografts in younger patients and with the use of a QT autograft, with recent evidence suggesting a higher rate of failure. On the other hand, HT and BTB autografts appear to have similar results, with the only concern being patients with jobs that require kneeling, in which cases an HT autograft would be better tolerated than a BTB autograft.

## Authors' approach

A detailed algorithm prepared by the authors is presented in Fig. 2. Every knee injury that includes more than one ligament reconstruction is considered an MKI. In this kind of case, where more than one ligament should be reconstructed, we advocate using at least one allograft, to limit donor-site morbidity due to autograft harvesting. We prefer to use allograft tissue to reconstruct the MCL, because



**Fig. 2** Authors' algorithm for graft choice in combined anterior cruciate ligament (ACL) and medial collateral ligament (MCL) reconstruction.

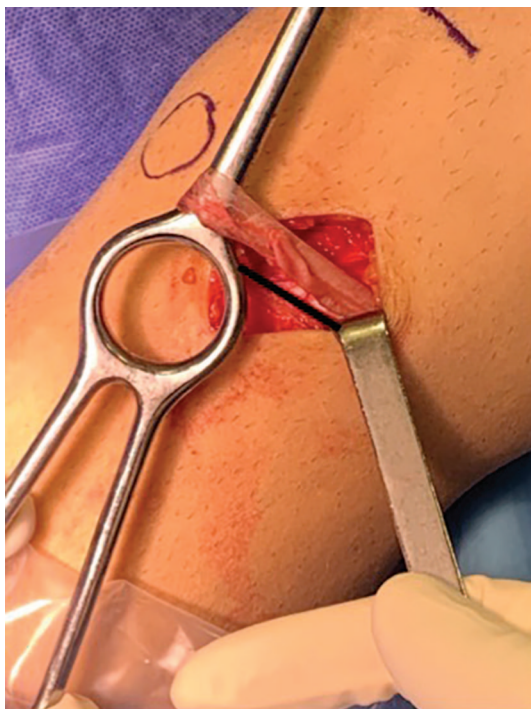Note. BTB, bone-tendon-bone autograft; HT, hamstring; S, sartorius; G, gracilis.

there is no evidence that suggests any preference for a graft in this type of reconstruction.

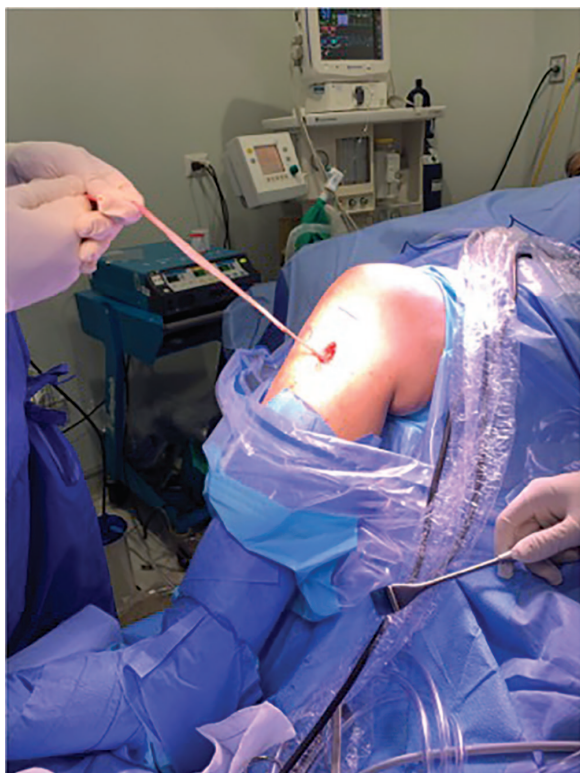
For ACL reconstruction in the case of a combined ACL and MCL reconstruction, we advocate the use of autograft in cases where evidence suggests its use (younger patients, more demanding patients), and allograft tissue in older and less demanding patients (usually older than 40 years). As scientific evidence shows an important role of the ST-G-S complex in valgus stability in an MCL-deficient knee, we prefer to use BTB autograft or HT autograft with a G and S fascia-sparing technique (harvesting only the ST, and using it as a quadruple graft; Figs 3 and 4).

## Conclusion

There is a concern regarding which grafts should be used in combined ACL and MCL reconstructions, with a paucity of recommendations focused on this specific topic. Expert opinions suggest the use of allograft-only reconstructions to limit donor-site morbidity or using at least one allograft and one autograft. When the latter approach is used and an HT autograft is harvested, techniques that maintain



**Fig. 3** Hamstring tendon harvesting using a sartorius fascia-sparing technique. Black line depicting an intact sartorius fascia after semitendinosus tendon release.



**Fig. 4** Semitendinosus tendon graft before release from the sartorius fascia, with a sufficient length to prepare a quadrupled graft.

both the integrity of the S fascia and the G are recommended because of the role that the ST-G-S complex plays in valgus stability in the setting of a MCL-deficient knee.

#### AUTHOR INFORMATION

- <sup>1</sup>Hospital Sótero del Río, Santiago, Chile.
- <sup>2</sup>Clínica Alemana-Universidad del Desarrollo, Santiago, Chile.
- <sup>3</sup>Hospital Padre Hurtado, Santiago, Chile.
- <sup>4</sup>Clínica do Dragão, Espregueira-Mendes Sports Centre – FIFA Medical Centre of Excellence, Porto, Portugal.
- <sup>5</sup>Dom Henrique Research Centre, Portugal.
- <sup>6</sup>3Bs Research Group – Biomaterials, Biodegradables and Biomimetics, University of Minho, Braga, Portugal.
- <sup>7</sup>ICVS/3Bs-PT Government Associate Laboratory, Braga, Portugal.
- <sup>8</sup>Orthopaedics Department of Minho University, Braga, Portugal.

Correspondence should be sent to: Francisco Figueroa, Vitacura 5951, Santiago, Chile.  
Email: franciscofigueroab@gmail.com

#### ICMJE CONFLICT OF INTEREST STATEMENT

DF reports board membership of SLARD-ISAKOS; and consultancy to Stryker, Smith & Nephew, outside the submitted work.

RC reports consultancy and payment for lectures from Stryker, outside the submitted work.

The other authors declare no conflict of interest relevant to this work.

#### FUNDING STATEMENT

No benefits in any form have been received or will be received from a commercial party related directly or indirectly to the subject of this article.

#### LICENCE

©2020 The author(s)

This article is distributed under the terms of the Creative Commons Attribution-Non Commercial 4.0 International (CC BY-NC 4.0) licence (<https://creativecommons.org/licenses/by-nc/4.0/>) which permits non-commercial use, reproduction and distribution of the work without further permission provided the original work is attributed.

#### REFERENCES

1. Lind M, Jacobsen K, Nielsen T. Medial collateral ligament (MCL) reconstruction results in improved medial stability: results from the Danish knee ligament reconstruction registry (DKRR). *Knee Surg Sports Traumatol Arthrosc* 2019. doi:10.1007/s00167-019-05535-x [Epub ahead of print].
2. Majewski M, Susanne H, Klaus S. Epidemiology of athletic knee injuries: a 10-year study. *Knee* 2006;13:184–188.
3. Phisitkul P, James SL, Wolf BR, Amendola A. MCL injuries of the knee: current concepts review. *Iowa Orthop J* 2006;26:77–90.
4. Wijdicks CA, Griffith CJ, Johansen S, Engebretsen L, LaPrade RF. Injuries to the medial collateral ligament and associated medial structures of the knee. *J Bone Joint Surg Am* 2010;92:1266–1280.
5. Marchant MH Jr, Tibor LM, Sekiya JK, Hardaker WT Jr, Garrett WE Jr, Taylor DC. Management of medial-sided knee injuries, part 1: medial collateral ligament. *Am J Sports Med* 2011;39:1102–1113.



6. **Zhu J, Dong J, Marshall B, Linde MA, Smolinski P, Fu FH.** Medial collateral ligament reconstruction is necessary to restore anterior stability with anterior cruciate and medial collateral ligament injury. *Knee Surg Sports Traumatol Arthrosc* 2018;26:550–557.
7. **Svantesson E, Hamrin Senorski E, Alentorn-Geli E, et al.** Increased risk of ACL revision with non-surgical treatment of a concomitant medial collateral ligament injury: a study on 19,457 patients from the Swedish National Knee Ligament Registry. *Knee Surg Sports Traumatol Arthrosc* 2019;27:2450–2459.
8. **Cinque ME, Chahla J, Kruckeberg BM, DePhillipo NN, Moatshe G, LaPrade RF.** Posteromedial corner knee injuries: diagnosis, management, and outcomes: a critical analysis review. *JBS Rev* 2017;5:e4.
9. **Alentorn-Geli E, Lazarides AL, Utturkar GM, et al.** Factors predictive of poorer outcomes in the surgical repair of multiligament knee injuries. *Knee Surg Sports Traumatol Arthrosc* 2019;27:445–459.
10. **Strauss MJ, Varatojo R, Boutefnouchet T, et al.** The use of allograft tissue in posterior cruciate, collateral and multi-ligament knee reconstruction. *Knee Surg Sports Traumatol Arthrosc* 2019;27:1791–1809.
11. **Tisherman R, Wilson K, Horvath A, Byrne K, De Groot J, Musahl V.** Allograft for knee ligament surgery: an American perspective. *Knee Surg Sports Traumatol Arthrosc* 2019;27:1882–1890.
12. **Wascher DC, Becker JR, Dexter JG, Blevins FT.** Reconstruction of the anterior and posterior cruciate ligaments after knee dislocation: results using fresh-frozen nonirradiated allografts. *Am J Sports Med* 1999;27:189–196.
13. **Fanelli GC, Giannotti BF, Edson CJ.** Arthroscopically assisted combined posterior cruciate ligament/posterior lateral complex reconstruction. *Arthroscopy* 1996;12:521–530.
14. **Harner CD, Waltrip RL, Bennett CH, Francis KA, Cole B, Irrgang JJ.** Surgical management of knee dislocations. *J Bone Joint Surg Am* 2004;86:262–273.
15. **Herbert M, Michel P, Raschke MJ, et al.** Should the ipsilateral hamstrings be used for anterior cruciate ligament reconstruction in the case of medial collateral ligament insufficiency? Biomechanical investigation regarding dynamic stabilization of the medial compartment by the hamstring muscles. *Am J Sports Med* 2017;45:819–825.
16. **Kremen TJ, Polakof LS, Rajaei SS, Nelson TJ, Metzger MF.** The effect of hamstring tendon autograft harvest on the restoration of knee stability in the setting of concurrent anterior cruciate ligament and medial collateral ligament injuries. *Am J Sports Med* 2018;46:163–170.
17. **Hulet C, Sonnery-Cottet B, Stevenson C, et al.** The use of allograft tendons in primary ACL reconstruction. *Knee Surg Sports Traumatol Arthrosc* 2019;27:1754–1770.
18. **Schuetz HB, Kraeutler MJ, Houck DA, McCarty EC.** Bone-patellar tendon-bone versus hamstring tendon autografts for primary anterior cruciate ligament reconstruction: a systematic review of overlapping meta-analyses. *Orthop J Sports Med* 2017;5:2325967117736484.
19. **Ajrawat P, Dwyer T, Whelan D, et al.** A comparison of quadriceps tendon autograft with bone-patellar tendon-bone autograft and hamstring tendon autograft for primary anterior cruciate ligament reconstruction: a systematic review and quantitative synthesis. *Clin J Sport Med* 2019. doi:10.1097/JSM.0000000000000765 [Epub ahead of print].
20. **Lind M, Strauss M, Nielsen T.** Quadriceps tendon graft has higher revision rates than hamstring and patellatendon grafts for ACL reconstruction: results from the Danish Knee Ligament Reconstruction Registry [abstract]. *ISAKOS Congress*, Cancun, Mexico, May 2019.