

Trauma and donation after circulatory death: a case series from a major trauma center

Journal of International Medical Research

49(3) 1–12

© The Author(s) 2021


Article reuse guidelines:

sagepub.com/journals-permissions

DOI: 10.1177/03000605211000519

journals.sagepub.com/home/imr



Alessandro Circelli¹, Etrusca Brogi² , Emiliano Gamberini¹, Emanuele Russo¹, Marco Benni¹, Giovanni Scognamiglio¹, Andrea Nanni¹, Federico Coccolini³, Francesco Forfori², Paola Fugazzola⁴, Luca Ansaloni⁴, Piergiorgio Solli⁵, Fabrizio Di Benedetto⁶, Matteo Cescon⁷ and Vanni Agnoletti¹

Abstract

Even with encouraging recipient outcomes, transplantation using donation after circulatory death (DCD) is still limited. A major barrier to this type of transplantation is the consequences of warm ischemia on graft survival; however, preservation techniques may reduce the consequences of cardiac arrest and provide better organ conservation. Furthermore, DCD in trauma patients could further expand organ donation. We present five cases in which organs were retrieved and transplanted successfully using normothermic regional perfusion (NRP) in trauma patients. Prompt critical care support and surgical treatment allowed us to overcome the acute phase. Unfortunately, owing to the severity of their injuries, all of the donors died. However, the advanced and continuous organ-specific supportive treatment allowed the maintenance of general clinical stability and organ preservation. Consequently, it was possible to retrieve and transplant the donors' organs. Death was ascertained in accordance with cardio-circulatory

¹Department of Intensive Care Anesthesia and Trauma Division, Cesena, Italy

²Department of Anesthesia and Intensive Care, University of Pisa, Pisa, Italy

³Department of Surgery, University of Pisa, Pisa, Italy

⁴Department of Surgery, Bufalini Hospital, Cesena, Italy

⁵Department of Cardio-Thoracic Surgery, Policlinico S. Orsola Malpighi University Hospital, Bologna, Italy

⁶Department of Hepato-Pancreato-Biliary Surgery and Liver Transplantation Unit, University of Modena and Reggio Emilia, Modena, Italy

⁷Department of Organ Insufficiency and Transplantation, General Surgery and Transplantation, University Hospital of Bologna, Policlinico S. Orsola-Malpighi, Bologna, Italy

Corresponding author:

Etrusca Brogi, Department of Anesthesia and Intensive Care, University of Pisa, Via Paradisa 2, Pisa, 56100 Italy.
Email: etruscabrogi@gmail.com



criteria, which was followed by NRP. We consider that DCD in trauma patients may represent an important source of organs.

Keywords

Organ donation, controlled donation after circulatory death, trauma, trauma donors, lung transplantation, liver transplantation, kidney transplantation, normothermic regional perfusion

Date received: 1 February 2021; accepted: 12 February 2021

Introduction

Donation after brain death (DBD) constitutes a major source of organs for transplantation.¹ Unfortunately, a significant gap between requests and the availability of organs persists. Several efforts have been made to overcome organ shortage, namely extended criteria donors, better donor identification, ex vivo organ perfusion, and donation after cardiac arrest.^{2,3} Donation after circulatory death (DCD) represents an additional pathway to organ procurement. In this setting, the donation takes place after death is declared in accordance with circulatory criteria.⁴ DCD has the potential to improve transplantation rates and decrease the length of waiting lists.⁵ Unfortunately, DCD remains underused, and increasing its use could provide substantially more organs than are currently retrieved.

Concern about warm ischemia represents one of the main worries in DCD for organ donation because of the possible consequences regarding organ quality and adverse graft survival.⁶ However, the use of normothermic regional perfusion (NRP) during DCD allows organ perfusion with a continuous flow, avoiding the reduction of cellular energy substrates and the accumulation of waste products.⁷ Consequently, NRP may help reduce warm ischemia injury and have positive

effects on graft survival.⁸ Importantly, DCD patients do not undergo catecholaminergic and cytokine storm with consequent hemodynamic instability, typical of DBD patients. However, it is important to keep in mind that hemodynamic instability requiring vasopressor support can be influenced by the nature of the injury leading to the donation (e.g., cardiac contusion or hemorrhagic shock following trauma). These systemic responses may affect organ preservation.⁹

In 2015, a meta-analysis was published comparing outcomes between donation after DCD and DBD. The authors found that 1-year survival was comparable between the two groups.¹⁰ Additionally, in 2019, two systematic reviews and meta-analyses were published on the same topic, showing similar results.^{11,12} Several studies have already underlined the positive effect of DCD on the number of organ donations;^{5,13} however, data regarding the use of DCD in trauma patients are scarce. Understandably, this particular setting requires optimization and standardization of donor selection and organ preservation. Moreover, DCD requires specific knowledge because medical staff must be experienced in extracorporeal life support, in particular venoarterial-extracorporeal membrane oxygenation (VA-ECMO), to avoid possible complications and pitfalls.¹⁴

In this case series, we report our single-center experience in organ procurement using NRP in trauma patients.

Case descriptions

The demographic and clinical characteristics of the five patients in this series are shown in Table 1. Data for each ECMO run are shown in Figure 1.

Case 1

A 43-year-old man was admitted to our emergency room (ER) after a suicide attempt with a firearm. The pre-hospital evaluation showed that he had bilateral mydriasis without pupillary responses and a Glasgow coma scale (GCS) score of 3. He was hypotensive and tachycardic. He was intubated by the helicopter emergency medical services (HEMS) team and referred to our hospital. On admission, no response for bilateral mydriasis to hyperosmolar saline and hyperventilation was observed. Brain computed tomography (CT) revealed the presence of cranial fractures with intracranial dislocation of multiple bone fragments, intracranial hemorrhage, uncal herniation, and cerebral lacerations and contusions. CT also showed an extensive hypodense region in the right hemisphere and diffuse cerebral swelling. There was no indication for emergent neurosurgery, and the patient was transferred to our intensive care unit (ICU). His medical history indicated Verneuil's disease. During the ICU stay, continuous-infusion norepinephrine and hormone replacement therapy (desmopressin, hydrocortisone, and levothyroxine) were started.¹⁵ Two units of red blood cells (RBC) were also transfused. Terlipressin was used to reduce the norepinephrine dosage, empirical antimicrobial therapy was initiated to treat aspiration, and airway secretion clearance was achieved with fiberoptic bronchoscopy.

After clinical, anamnestic, and neurological evaluation, ICU staff concluded that pursuing intensive support would be unlikely to change the poor prognosis and was therefore considered inappropriate. Moreover, brain death did not seem to be the probable outcome. Following extensive discussion with the patient's family, a decision was reached to withdraw life-sustaining treatments, and palliative sedation was initiated. According to Italian law, death was declared after 20 minutes of the absence of electrical cardiac activity on electrocardiography (EKG). NRP was started, and the donor's lungs, kidneys, and liver were retrieved and successfully transplanted later that day.

Case 2

A 43-year-old woman was brought in by EMS personnel after a car accident followed by complex extrication. The severity of her injuries and the short distance between the location of the accident and our level I trauma center led the EMS personnel to choose a "scoop and run" pre-hospital management strategy. On admission, the patient had a GCS of 7, and she was dyspneic, hypotensive, and tachycardic. Rapid sequence intubation (RSI) and bilateral pleural decompression were performed, and O-negative blood were transfused. Tranexamic acid and fibrinogen were also administered (in accordance with rotation thromboelastography (ROTEM[®]; Pentapharm GmbH, Munich, Germany)) results. Primary X-ray assessment showed mediastinal widening, cardiac tamponade, and perihepatic fluid collection. The patient's general status worsened rapidly to pulseless electrical activity (PEA). Adrenaline was administered, and left resuscitative thoracotomy was performed to relieve the cardiac tamponade. Return of spontaneous circulation (ROSC) was achieved, and, in the operating

Table 1. Demographic and clinical characteristics on admission and during the ICU stay for all five patients.

Donor characteristic	Case 1	Case 2	Case 3	Case 4	Case 5
Age (years)	43	43	51	30	63
Sex	M	F	F	M	M
BMI (kg/m ²)	24.2	27.8	24.2	22.1	23.1
Length of ICU stay (days)	5	17	6	2	5
pH (on admission)	7.38	7.22	7.29	7.26	NA
Lactate (mmol/L; highest value)	2.23	5.5	10.64	15.8	NA
BE	9.6	-10.2	-11.3	-16	NA
Hb (g/L)	0.088	0.089	0.091	0.074	0.126
HCO ₃ (mmol/L)	24.5	16.3	15.8	16.6	NA
MAP on admission (mmHg)	76	60	54	61	61
MAP during ICU stay (mmHg)	92	77	75	62	82
Heart rate (bpm)*	110	98	112	130	54
Heart rate during ICU stay (bpm)	63	95	100	110	65
Transfusion on admission	no	2 units RBC 2 units FFP 1 unit PLT	4 units RBC 2 units FFP 1 unit PLT	4 units RBC 2 units FFP	no
Transfusion during ICU stay	6 units RBC	1 units RBC	9 units RBC 5 units FFP 1 unit PLT	6 units RBC 4 units FFP	3 units RBC
AKI/CRRT/extracorporeal blood purification	AKI stage I, no CRRT	CVVHDF	CVVHDF	CytoSorb ^a	No CRRT
CVP	9	8	9	12	10
Noradrenaline	yes	yes	yes	yes	yes
Terlipressin	yes	no	no	no	no
Best PaO ₂ /FiO ₂	476	490	342	521	421
Bronchoscopy	yes	yes	no	no	no
Antibiotics	yes	yes	yes	yes	no
Organs retrieved	lungs, kidneys, liver	lungs, kidneys, liver; lungs were not transplanted	lungs, liver	both kidneys; one kidney transplanted	kidneys, liver

(continued)

Table 1. Continued.

Donor characteristic	Case 1	Case 2	Case 3	Case 4	Case 5
Recipient outcomes	1-year survival for lung and kidney	1-year survival	1-year survival	2-year survival	4-year survival

^aCytoSorbents, Monmouth Junction, NJ, USA. ICU, intensive care unit; M, male; F, female; BMI, body mass index; BE, base excess; Hb, Hemoglobin; HCO₃, bicarbonate; MAP, mean arterial pressure; bpm, beats per minute; RBC, red blood cells; FFP, fresh-frozen plasma; PLT, platelets; AKI, acute kidney injury; CRRT, continuous renal replacement therapy; CVVHDF, continuous veno-venous hemodiafiltration; CVP, central venous pressure; PaO₂/FIO₂, arterial partial pressure of oxygen/fraction of inspired oxygen.

room (OR), the thoracic incision was extended across the sternum and converted into a clamshell. Internal cardiac massage and low-energy internal defibrillation were also required because of the sudden development of ventricular fibrillation. Damage to the left atrial appendage was identified and repaired, with an estimated low-flow time of 30 minutes. Clinicians had already initiated massive transfusion protocols (MTPs), and 6 units of RBC, 2 units of fresh-frozen plasma (FFP), and 1 unit of platelets (PLT) were transfused. Return of sinus rhythm with diffuse cardiac hypokinesia was achieved. Continuous infusion of noradrenaline was also started. Exploratory laparotomy and hepatic packing were then performed to address a major hepatic laceration. Next, bilateral femoral artery cutdowns were performed and introducers were inserted for arteriography; no active blush was observed. Once hemodynamic stability had been achieved, the patient was transferred to the radiology department for secondary total-body CT assessment, which revealed pneumomediastinum, diffuse lung contusions, multiple rib fractures, and bilateral pleural effusion. Abdominal CT revealed multiple hepatic lacerations in the right hepatic lobe, without signs of active bleeding, and multifragmentary fracture of the right acetabulum with posterior coxo-femoral dislocation. In the ICU, a Swan–Ganz catheter was placed for continuous central venous oxygen saturation (ScvO₂) monitoring to guide fluid resuscitation and drug titration. After 48 hours, thoracic and abdominal second-look surgery was performed. The hepatic packing was removed, and pericardial repair with a biological prosthesis, and rib fixation were performed. The patient’s ICU stay was characterized by the following complications: septic shock requiring antibiotics and noradrenergic support, and acute kidney injury with the need for continuous renal replacement

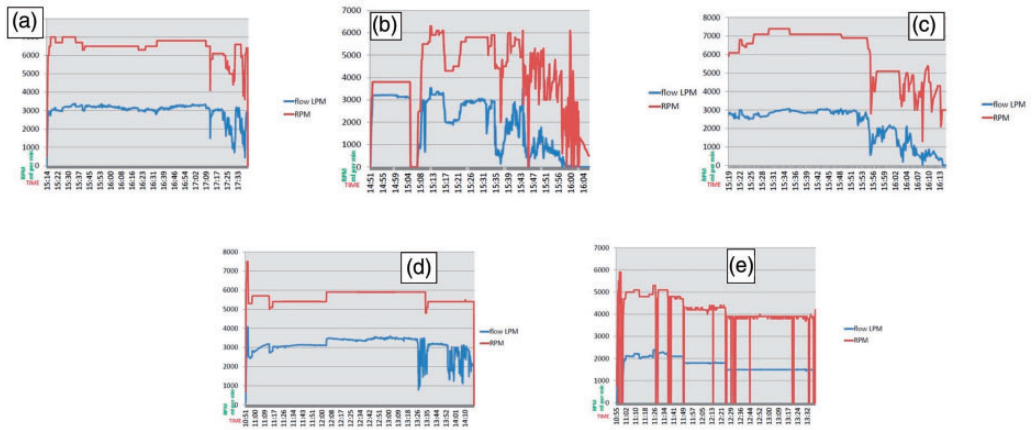


Figure 1. Extracorporeal membrane oxygenation (ECMO) treatment for the five cases in this series. a) Case 1: kidneys, lungs, and liver retrieved; total NRP time: 146 minutes; b) Case 2: kidneys, lungs, and liver retrieved; total NRP time: 72 minutes; c) Case 3: lungs and liver retrieved; total NRP time: 55 minutes; d) Case 4: kidneys retrieved; total NRP time: 200 minutes; e) Case 5: kidneys and liver retrieved; total NRP time: 158 minutes.

RPM, revolutions per minute; mL per minute, blood flow on the extracorporeal membrane oxygenation (ECMO) machine; TIME, duration of normothermic regional perfusion (NRP).

therapy (CRRT). Clinical evaluation showed severe neurological impairment with a GCS of 3, and a series of neurological tests were performed to obtain a prognostic evaluation (i.e., electroencephalography (EEG), somatosensory-evoked response (SSER), and neuron-specific enolase (NSE) measurement). Finally, magnetic resonance imaging (MRI) showed diffuse altered signals in the cerebral cortex, and caudate and lenticular nuclei, compatible with diffuse post-anoxic brain damage.

The patient's clinical status and neuro-radiological and neurophysiological evaluation were highly indicative of a poor prognosis, and continuing intensive care was considered inappropriate. Therefore, palliative sedation was initiated. After ascertaining death in accordance with the cardiocirculatory criteria, procedures for organ and tissue support with the purpose of therapeutic transplantation were started, according to DCD donor Maastricht category 3. NRP was started, and the donor's

lungs, kidneys, and liver were retrieved. Both the kidneys and the liver were transplanted successfully; however, the lungs were not transplanted owing to poor organ quality.

Case 3

A 51-year-old woman involved in a major road accident was admitted to our hospital. On pre-hospital evaluation, she had bilateral mydriasis, a GCS of 3, and left lower limb amputation. During air medical transportation, PEA was witnessed, and advanced life support (ALS) was promptly initiated, which achieved ROSC. A second cardiac arrest was witnessed during transportation, and cardiopulmonary resuscitation (CPR) was begun and was still in progress on admission to the ER. Bilateral pleural decompression was performed. MTPs were activated, and RBCs, tranexamic acid, and fibrinogen were administered. Primary radiologic survey showed an

open-book pelvic fracture, and preperitoneal pelvic packing was performed. The patient was then transferred to the OR. Intraoperative arteriography showed splenic active blush and abnormal appearance of the hypogastric artery. Subsequently, embolization of the splenic artery and hypogastric artery was performed. Next, external pelvic fixation was performed for temporary stabilization of the unstable pelvic fracture. RBC, FFP, PLT, and fibrinogen were administered, and hemodynamic stability was achieved. However, bilateral mydriasis without pupillary response to light persisted, and blood gas analysis showed severe metabolic acidosis. The patient was transferred to the radiology department for total-body CT. Brain CT scan showed a loss of differentiation between the gray and white matter, compatible with ischemic injury. Thoracic CT revealed the presence of pneumothorax, lung contusion, sternal fracture, multiple rib fractures, and bilateral pleural effusion. Finally, abdominal CT revealed an active perisplenic blush and blood collection in the psoas muscle. Additionally, multiple hepatic lacerations, and pancreatic and kidney contusions were observed. A decision was made to perform emergent splenectomy after a sudden new hypotensive event; consequently, the patient was once again transferred in the OR. After stabilization, she was transferred to the ICU; however, severe metabolic acidosis and slow bleeding from the lower limb stump persisted. Trauma-induced coagulopathy was diagnosed using rotational thromboelastometry, and FFP, PLT, and fibrinogen were transfused. Furthermore, rhabdomyolysis-induced acute kidney injury led to the need for CRRT. During the following days, neurologic evaluation (clinical evaluation, EEG, SSER, NSE measurement, MRI) showed severe brain damage with irreversible neurological impairment. Nevertheless, left

hemipelvectomy was indicated as treatment for the unstable pelvic fractures. However, according to the literature, this procedure is associated with high morbidity and mortality risks. In light of these findings, continuing intensive support was considered inappropriate. Death was declared according to Italian law, NRP was started, and the donor's lungs and liver were retrieved and transplanted successfully.

Case 4

A 30-year-old man was admitted to the ER after a suicide attempt. This was a complex suicide attempt characterized by thoracic self-stabbing followed by self-immolation. On pre-hospital evaluation, the patient had a GCS of 3 with hemodynamic instability. The estimated percentage of his total body surface affected by burns was approximately 50%. He was intubated by the HEMS team, and fluid resuscitation was started according to the Parkland formula. On admission to our ER, hemodynamic instability persisted. The stab wound was in the left third intercostal space, and asymmetrical chest wall movement was observed. MTPs were activated, and 2 units of RBC and 2 units of PFC were transfused. ROTEM assessment was performed, and tranexamic acid was administered. Primary trauma survey performed in the ER's shock room revealed massive hemopneumothorax; therefore, left mini-thoracotomy was performed, and a chest drain was inserted. The patient was then transferred to the OR. The thoracic incision was converted into a clamshell, and lacerations in the left ventricular free wall and pericardium were repaired, and escharotomy was performed to relieve compartment syndrome. Finally, the patient was transferred to the ICU. Hemodynamic instability led clinicians to initiate VA-ECMO support; however, the patient's clinical condition was critical and characterized by a

poor prognosis. Therefore, a decision was reached to withdraw life-sustaining treatments, and palliative sedation was started. After ascertaining death in accordance with the cardiocirculatory criteria, organ and tissue support strategies with the purpose of therapeutic transplantation were started according to DCD donor Maastricht category 3. NRP was started, and both kidneys were retrieved. Only one kidney was transplanted successfully; the other kidney was not transplanted for technical reasons. The liver was not retrieved owing to ischemic injury.

Case 5

A 63-year-old man was admitted to the ER after accidentally falling off his bicycle after hitting a pothole. During the pre-hospital evaluation, the patient was in PEA. ALS was initiated promptly, and ROSC was achieved after 10 minutes. He was intubated and then admitted to the ER. On arrival, he was hypotensive with normal sinus rhythm, and continuous noradrenaline infusion was started. The primary trauma survey was negative. He then underwent radiological imaging, including full-body CT and spine MRI, which revealed an unstable fracture of the odontoid process with posterior dislocation, a fracture of the body of the eighth thoracic vertebra, and a fracture of the lamina of the fifth cervical vertebra. On the following day, head CT was performed because of the persistence of poor neurological status. Brain CT showed severe hypoxic-ischemic damage to the deep gray nuclei and to the frontal, temporal, occipital, and parietal cortex compatible with post-anoxic encephalopathy in post-traumatic cervical spinal cord injury. The EEG was non-reactive. ICU physicians concluded that, owing to the poor prognosis, intensive care supports were to be discontinued because these were unlikely to change the prognosis and were

considered inappropriate; palliative sedation was started. Death was declared in accordance with Italian law, NRP was started, and both kidneys and the liver were retrieved and transplanted successfully.

DCD details

In all cases, an extensive and structured family consultation was performed regarding end-of-life care and the feasibility of organ donation. After discussing each patient's prognosis with their families, withdrawing life support and palliative sedation were started in the ICU according to the directives of our national scientific society, the Italian Society of Anesthesia, Analgesia, Intensive Care and Resuscitation (SIAARTI).¹⁶ The DCD procedures were initiated only after ascertaining death in accordance with the cardio-circulatory criteria. The femoral vessels (both artery and vein; usually the right) were cannulated using a percutaneous approach after the declaration of death in accordance with Italian law (i.e., absence of electrical cardiac activity for 20 minutes on the EKG), at the bedside in the ICU. An intra-aortic ER-REBOATM catheter (Prytime Medical Devices, Boerne, TX, USA) was positioned in zone 1 (i.e., supra-diaphragmatic) through the contralateral femoral artery (usually the left). Then, bedside control of the catheter position was performed either radiologically or by transesophageal echocardiography (TEE). A Novalung Xlung kit (Xenios AG, Heilbronn, Germany) for extracorporeal treatment plus an HLS MAQUET venous cannula (23-Fr, 38-cm; GETINGE, Rastatt, Germany) and a Novaport one arterial cannula (19-Fr, 15-cm; Xenios AG) were used for NRP. Notably, the "time to ECMO" is strictly dependent on cannulation time.

Recipients' outcomes

At the time of writing, all but one of the organ recipients in this report was still alive. The patient receiving the liver from case 1 died a few months after transplantation; survival after transplantation was 1 year for recipients of organs from case 1, 2, and 3; 2 years for recipients of organs from case 4; and 4 years for recipients of organs from case 5. In two of our cases, lungs, liver, and kidneys were retrieved successfully. In case 2, the lungs were not retrieved because of poor organ quality and, in case 4, the liver was not retrieved owing to ischemic injury (Table 1).

Discussion

This case series showed how donations and transplantation were successfully accomplished in different settings involving trauma patients. Regarding consent for donation, Italy uses an opt-out system. Additionally, the national organ procurement organization is responsible for the general coordination of all of the steps involved during organ donation.

A DCD program is an alternative way to increase the number of organs available for transplantation. A report from the UK National Transplant Registry showed that the rates of organ donation and transplantation have improved owing to an increase in DCD donation, with a higher 5-year graft survival for kidneys and livers.¹⁷ Similarly, the Belgian Transplant Society reported a growing DCD donation rate,¹⁸ and in Spain, DCD provides 24% of donors.¹⁹ Additionally, several studies and meta-analyses have been published, showing comparable results for 1-year survival after DBD or DCD transplantation for lung, liver, pancreas, and kidney.^{9,11-24} Traditionally, there are specific concerns about recipient survival, possibly reducing the rate of DCD usage and, consequently,

DCD is not performed in many countries. Warm ischemia represents one of the main fears in DCD.⁶ However, although there is no uniform definition of warm ischemia, it is generally considered the period of time between circulatory arrest and initiating graft reperfusion. Protracted warm ischemia time is detrimental for both graft function and long-term outcome.²⁵ In our center, we use NRP during DCD. In fact, NRP through VA-ECMO may help lessen warm ischemia injury and provide continuous flow organ perfusion.^{7,26-28} Technically, in our cases, NRP was started following cannulation of the femoral vessels (i.e., artery and vein).

Trauma donors represent an important organ source. In 2019, the US Scientific Registry of Transplant Recipients reported that trauma donors provided more organs per donor compared with non-trauma donors (3.5 vs. 2.4, respectively; $p < 0.001$)²⁹ Furthermore, trauma donors showed a lower kidney donor risk index. Indeed, developments in trauma and critical care management, especially in resuscitation protocols and organ-specific supportive treatment, have decreased acute-phase mortality, possibly leading to an increased number of potential donors. In fact, our patients presented with important trauma-related injuries with a high risk of pre-hospital and intra-hospital mortality. However, prompt damage-control strategies allowed us to overcome the acute phase. Unfortunately, although the patients died of their injuries, it was possible to retrieve and transplant their organs. It would be interesting to investigate whether traumatic mechanisms and injury severity scores (ISS) affect recipient outcomes after DCD transplantation. In case 2, despite the severity of the trauma and the presence of multiple hepatic lacerations, the liver was retrieved and transplanted successfully. Similarly, in case 3, despite the prolonged hemodynamic instability, multiple hepatic

lacerations, lung contusions, and a sternal fracture, the liver and lungs were recovered and transplanted successfully. Consequently, most critical traumatic lesions are not considered a priori absolute contraindications to organ donation.³⁰ Obviously, it is important to highlight that evaluating traumatic injuries and assessing medical suitability for organ donation are more challenging in trauma patients. However, this donation pathway could represent an important method of increasing the organ donation pool.

Finally, it is important to underline that the organ procurement system requires a multidisciplinary approach and, consequently, this system necessitates a multidisciplinary team in charge of the organ donation process. It has previously been demonstrated that the organization of a multidisciplinary and dedicated team enhances donation outcomes.³¹ The key goal of an effective team approach consists of systematic donor identification, donor co-ordination, and recipient identification. In addition to clinical expertise, the organ recovery process requires logistical coordination for organ recovery, distribution, and transplantation as well as support for the family's needs.³² The team is interdisciplinary, involved in both organ donation and transplantation, and consists of clinical transplant coordinators, transplant physicians, physicians, intensive care specialists, transplant surgeons, interventional radiologists, respiratory therapists, nurses, financial coordinators, and social workers. It is easy to understand that such a system requires a massive effort both clinically and financially. Local organ procurement coordinators, with organ procurement personnel, play a crucial role. The coordinators have a consultative role regarding the entire organ donation process, and they are in charge of organizing the procurement process between contributing institutions. Furthermore, the coordinator guarantees

that ethical and clinical standards are respected during the procurement process. At the same time, bedside clinicians have the duty to notify local procurement organizations of a possible donor and to provide the best treatments for the patients. Not to be underestimated, it is important to remember the great emotional and ethical impact that characterizes the donation process.³³ In fact, donation occurs in a unique emotional stressful moment for the donor's family. It is vital to engage in simultaneously clear and empathetic family consultation regarding end-of-life care and the feasibility of organ donation as well as providing psychological support. Furthermore, it is important to remember that transplants save lives, and donation represents an incredible gift.

In conclusion, we consider that DCD in trauma patients may represent an important source of organs. However, this particular setting necessitates specific programs led by the local procurement and transplantation network to enhance donor selection, organ allocation, and organ preservation.

Acknowledgements

The Authors wish to thank Manuel Labanti for help collecting the data regarding the recipients' outcomes. Affiliation: Centro Riferimento Trapianti dell'Emilia-Romagna (CRT-ER), Policlinico S. Orsola-Malpighi, Via Maarenti 13, 40138, Bologna, Italy.

Ethics statement

Written informed consent to participate and to publish this case series was obtained from the patients, in accordance with the rules of our local ethics committee. This study adheres to the CARE reporting guidelines.

Declaration of conflicting interest

The authors declare that they have no competing interests.

Funding

This research received no specific grant from any funding agency in the public, commercial, or not-for-profit sectors.

Author contributions

Authors AC, EB, EG, ER, MB, GS, AN, FC, FF, PF, LA, PS, FDB, MC, and VA: study concept and design, acquisition of data, interpretation of data, drafting/critical revision of the manuscript. All authors confirm that they had full control and guarantee that all aspects of the work were investigated and resolved. All authors read and approved the final version of the submitted manuscript.

ORCID iD

Etrusca Brogi  <https://orcid.org/0000-0001-9010-7941>

References

1. Johnson RJ, Bradbury LL, Martin K, et al. UK Transplant Registry. Organ donation and transplantation in the UK—the last decade: a report from the UK national transplant registry. *Transplantation* 2014; 97 Suppl 1: S1–S27.
2. Manara AR, Murphy PG and O’Callaghan G. Donation after circulatory death. *Br J Anaesth* 2012; 108: i108–i121.
3. Botha P, Trivedi D, Weir CJ, et al. Extended donor criteria in lung transplantation: impact on organ allocation. *J Thorac Cardiovasc Surg* 2006; 131: 1154–1160.
4. Thuong M, Ruiz A, Evrard P, et al. New classification of donation after circulatory death donors definitions and terminology. *Transpl Int* 2016; 29: 749–759.
5. Le Dinh H, Monard J, Delbouille MH, et al. A more than 20% increase in deceased-donor organ procurement and transplantation activity after the use of donation after circulatory death. *Transplant Proc* 2014; 46: 9–13.
6. Oniscu GC, Randle LV, Muiesan P, et al. In situ normothermic regional perfusion for controlled donation after circulatory death—the United Kingdom experience. *Am J Transplant* 2014; 14: 2846–2854.
7. Net M, Valero R, Almenara R, et al. Hepatic preconditioning after prolonged warm ischemia by means of S-adenosyl-L-methionine administration in pig liver transplantation from non-heart-beating donors. *Transplantation* 2003; 75: 1970–1977.
8. Morrissey PE and Monaco AP. Donation after circulatory death: current practices, ongoing challenges, and potential improvements. *Transplantation* 2014; 97: 258–264.
9. Avlonitis VS, Fisher AJ, Kirby JA, et al. Pulmonary transplantation: the role of brain death in donor lung injury. *Transplantation* 2003; 75: 1928–1933.
10. Krutsinger D, Reed RM, Blevins A, et al. Lung transplantation from donation after cardiocirculatory death: a systematic review and meta-analysis. *J Heart Lung Transplant* 2015; 34: 675–684.
11. Zhou J, Chen B, Liao H, et al. The comparable efficacy of lung donation after circulatory death and brain death: a systematic review and meta-analysis. *Transplantation* 2019; 103: 2624–2633.
12. Palleschi A, Rosso L, Musso V, et al. Lung transplantation from donation after controlled cardiocirculatory death. Systematic review and meta-analysis. *Transplant Rev (Orlando)* 2020; 34: 100513.
13. Saidi RF, Markmann JF, Jabbour N, et al. The faltering solid organ donor pool in the United States (2001-2010). *World J Surg* 2012; 36: 2909–2913.
14. Brogi E, Circelli A, Gamberini E, et al. Normothermic regional perfusion for controlled donation after circulatory death: a technical complication during normothermic regional perfusion. *ASAIO J* 2020; 66: e19–e21.
15. Brogi E, Russo E, Nanni A, et al. Terlipressin in brain death organ donors management reduces the need for noradrenalin continuous infusion. *Pharmacologyonline* 2019; 1: 403–407 ISSN:1827-8620.
16. SIAARTI - Italian Society of Anaesthesia Analgesia Resuscitation and Intensive Care Bioethical Board. End-of-life care and the intensivist: SIAARTI recommendations on the management of the dying patient. *Minerva Anestesiol* 2006; 72: 927–963.

17. Johnson RJ, Bradbury LL, Martin K, et al. Organ donation and transplantation in the UK—the last decade: a report from the UK national transplant registry. *Transplantation* 2014; 97: S1–S27. doi:10.1097/01.TP.0000438215.16737.68
18. Desschans B, Evrard P and Coordinator Transplant Section of the Belgian Transplant Society. Organ donation and transplantation statistics in Belgium for 2012 and 2013. *Transplant Proc* 2014; 46: 3124–3126. doi:10.1016/j.transproceed.2014.09.170
19. Miñambres E, Rubio JJ, Coll E, et al. Donation after circulatory death and its expansion in Spain. *Curr Opin Organ Transplant* 2018; 23: 120–129. doi:10.1097/MOT.0000000000000480
20. Chen G, Wang C, Ko DS, et al. Comparison of outcomes of kidney transplantation from donation after brain death, donation after circulatory death, and donation after brain death followed by circulatory death donors. *Clin Transplant* 2017; 31. doi: 10.1111/ctr.13110
21. De Carlis R, Di Sandro S, Lauterio A, et al. Liver grafts from donors after circulatory death on regional perfusion with extended warm ischemia compared with donors after brain death. *Liver Transpl* 2018; 24: 1523–1535.
22. van Loo ES, Krikke C, Hofker HS, et al. Outcome of pancreas transplantation from donation after circulatory death compared to donation after brain death. *Pancreatol* 2017; 17: 13–18.
23. Croome KP, Lee DD, Perry DK, et al. Comparison of longterm outcomes and quality of life in recipients of donation after cardiac death liver grafts with a propensity-matched cohort. *Liver Transpl* 2017; 23: 342–351.
24. Laing RW, Scalera I, Isaac J, et al. Liver transplantation using grafts from donors after circulatory death: a propensity score-matched study from a single center. *Am J Transplant* 2016; 16: 1795–1804.
25. Tennankore KK, Kim SJ, Alwayn IP, et al. Prolonged warm ischemia time is associated with graft failure and mortality after kidney transplantation. *Kidney Int* 2016; 89: 648–658.
2. Hessheimer AJ, Coll E, Torres F, et al. Normothermic regional perfusion vs. super-rapid recovery in controlled donation after circulatory death liver transplantation. *J Hepatol* 2019; 70: 658–665. doi:https://dx.doi.org/10.1016/j.jhep.2018.12.013.
27. Hagness M, Foss S, Sorensen DW, et al. Liver transplant after normothermic regional perfusion from controlled donors after circulatory death: the Norwegian experience. *Transplant Proc* 2019; 51: 475–478. doi:10.1016/j.transproceed.2019.01.066.
28. Watson CJE, Hunt F, Messer S, et al. In situ normothermic perfusion of livers in controlled circulatory death donation may prevent ischemic cholangiopathy and improve graft survival. *Am J Transplant* 2019; 19: 1745–1758. doi:10.1111/ajt.15241.
29. Ackerman A, Clark D, Lipinska J, et al. Organ donation after trauma: a 30-year review. *J Trauma Acute Care Surg* 2019; 87: 130–133. doi:10.1097/TA.00000000000002322
30. Fugazzola P, Ansaloni L, Benni M, et al. At the heart of organ donation. Case reports of organ donation after cardiac death in two patients with successfully repaired AAST grade V cardiac injuries. *World J Emerg Surg* 2019; 14: 60. Published 2019 Dec 19. doi:10.1186/s13017-019-0279-5
31. Kong AP, Barrios C, Salim A, et al. A multi-disciplinary organ donor council and performance improvement initiative can improve donation outcomes. *Am Surg* 2010; 76: 1059–1062.
32. Rudge C, Matesanz R, Delmonico FL, et al. International practices of organ donation. *Br J Anaesth* 2012; 108: i48–i55. doi:10.1093/bja/aer399
33. Fridh I, Forsberg A and Bergbom I. Close relatives' experiences of caring and of the physical environment when a loved one dies in an ICU. *Intensive Crit Care Nurs* 2009; 25: 111–119. doi:10.1016/j.iccn.2008.11.002