

Simplifying Bony Midface Reconstruction with Patient-specific Titanium Plates

Patrick A. Palines, MD*

James R. Ferrer, BS*

Aran Yoo, MD*

Hugo St. Hilaire, MD, DDS*†

Mark W. Stalder, MD*†

Summary: Virtual surgical planning and patient-specific osteosynthesis plates provide reconstructive surgeons with the ability to proceed with facial reconstruction of expanding complexity. Moreover, these advances have been shown to reduce the energy, effort, and operating time while helping guide the surgeon toward anatomically correct results. The currently available literature regarding custom-milled plates pertains mostly to reconstructive surgery of the mandible. This small 3-patient series illustrates the use of patient-specific titanium plating to simplify complex reconstruction of the midface. Composite defects requiring multiple bony and soft tissue segments are difficult to reconstruct intraoperatively without prior planning. Custom plates and associated cutting guides based on patient-specific anatomy allow for a more streamlined, stepwise protocol for assembly of intricate constructs. Custom-manufactured hardware will precisely fit bony contours and minimize additional manipulation of both the bone and plate, maximally preserving internal strength and allowing for improved stability, dental occlusion, and spatial positioning. In addition to these mechanical benefits, the ease of mind and overall cost reduction through a reduction in procedural time are significant advantages offered by pre-designed plates. We hope that this series illustrates the value of custom-printed plates for midface reconstruction. (*Plast Reconstr Surg Glob Open* 2021;9:e3555; doi: [10.1097/GOX.0000000000003555](https://doi.org/10.1097/GOX.0000000000003555); Published online 23 April 2021.)

The advent of virtual surgical planning (VSP) and the capability to manufacture patient-specific osteosynthesis plates have been noteworthy highlights of modern craniofacial surgery.^{1,2} Following oncologic ablation or major trauma to the facial architecture, well-adapted plates are essential to achieve segment stability, dental occlusion, and correct spatial position during reconstruction. The creation of custom plates has been shown to streamline the surgical process, reducing energy, effort, and operative time while obtaining a more accurate result.^{3,4} Despite increasing popularity in mandibular reconstruction,³ reports of custom plating in midface reconstruction remain sparse.^{4,5} Complex defects involving multiple tissue components make for challenging reconstructions, which may be made more feasible

through custom plate technology. Here, we present a series of 3 consecutively enrolled patients who underwent complex midface reconstruction with osteocutaneous free fibula flaps, facilitated through the use of custom 3-dimensional (3D) laser-sintered titanium plates.

CASE SERIES

Plate Design and Surgical Technique

Preoperatively, all patients underwent VSP and design of the bony construct, osteotomy guides, and custom osteosynthesis plates (Stryker, Kalamazoo, Mich.). First, patients underwent maxillofacial computerized tomography imaging from which a 3D model of the facial architecture was generated. These images were transferred to D2P software (3D Systems, Rock Hill, S.C.) for VSP. Through VSP, prefabricated low-profile titanium plates were designed based on each patient's unique anatomy, with each screw hole and strut designed to engage the thickest portions of bones, allowing for anatomic reconstruction of the maxilla with planned placement of dental implants.

On the day of surgery, all 3 patients underwent osteocutaneous free fibula flap harvest through standard technique.⁶ Fibular osteotomies were performed utilizing the designed cutting guides. The custom-printed

From the *Division of Plastic and Reconstructive Surgery, Louisiana State University Health Sciences Center, New Orleans, La.; and †University Medical Center – LCMC Health, New Orleans, La.

Received for publication October 11, 2020; accepted December 29, 2020.

Copyright © 2021 The Authors. Published by Wolters Kluwer Health, Inc. on behalf of The American Society of Plastic Surgeons. This is an open-access article distributed under the terms of the [Creative Commons Attribution-Non Commercial-No Derivatives License 4.0 \(CCBY-NC-ND\)](https://creativecommons.org/licenses/by-nc-nd/4.0/), where it is permissible to download and share the work provided it is properly cited. The work cannot be changed in any way or used commercially without permission from the journal.

DOI: [10.1097/GOX.0000000000003555](https://doi.org/10.1097/GOX.0000000000003555)

Disclosure: All the authors have no financial interest in relation to the content of this article. This study was not supported by any funding.

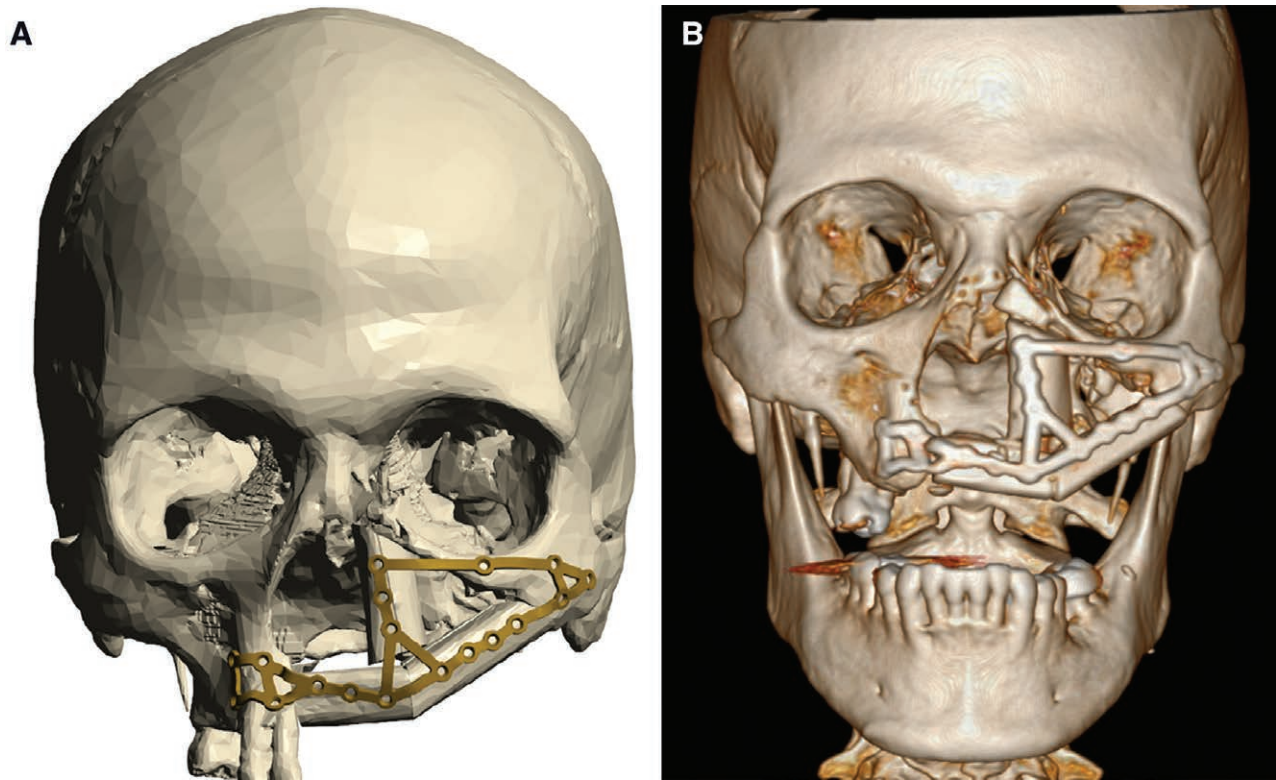


Fig. 1. A 61-year-old man with complex composite midface defect secondary to remote ablative procedure and radiation. A, VSP was used to design a 3-segment fibula flap and patient-specific laser-sintered titanium plate with 18 predesigned screw holes optimally placed to fixate the construct to the right hemimaxilla and left zygoma. B, Postoperative 3-dimensional computerized tomography model showing the installed construct and final hardware.

plates were then used to stabilize the construct before inset and fixation into the individual bony defect. All 3 patients were found to have accurate bony reconstructive outcomes at 2, 6, and 9 months follow-up, respectively. All patients provided written consent for inclusion in this report.

Patient 1

A 61-year-old man with Schneiderian papilloma was treated with left hemimaxillectomy. A 3-segment fibula construct was designed for reconstruction of the left hemimaxilla and nasomaxillary buttress, along with a pedicled skin paddle for intraoral coverage, and separate pedicled facial flap for intranasal lining to cover a costal cartilage dorsal strut graft. A single 1.0-mm-thick custom plate with 18 holes was used to precisely secure all segments with 1.7-mm self-tapping monocortical screws before anchoring to the midface (Fig. 1). The patient was discharged without complication.

Patient 2

A 50-year-old woman suffered a self-inflicted gunshot wound to the face, resulting in massive defects to the mandible, frontal sinus, bilateral orbits, zygomaticomaxillary complexes, mandible, and maxilla consistent with LeFort II fracture pattern. The fibula was divided into 2 separate free flaps: a single-segment flap for the mandible, and a 2-segment flap for reconstruction of

the left hemimaxilla that were secured using a 1.2-mm-thick custom midface plate with eleven screws (Fig. 2). The postoperative period was complicated by a minor intraoral dehiscence of the skin paddle, and she has since undergone additional iliac bone grafting to the orbital floor.

Patient 3

A 25-year-old man underwent infrastructure maxillectomy of an Ewing's sarcoma of the right nasal cavity and posterolateral hard palate. A single fibular segment was used for reconstruction of the posterior maxilla. VSP was used to design a 1.0-mm-thick custom titanium midface plate with eleven screws to secure the bony construct, and to simultaneously place osseointegrated implant posts at the time of his reconstruction (Fig. 3). Postoperative course was uncomplicated.

DISCUSSION

Custom plate technology offers several benefits compared with traditional premade plates. By designing the plates in conjunction with the free fibula construct, the surgeon can be confident that the construct will be accurately assembled as envisioned.⁵ As the plates are designed for the individual patient's anatomy, these low-profile plates should fit precisely and prevent unplanned surgical manipulation. The ability to position screw

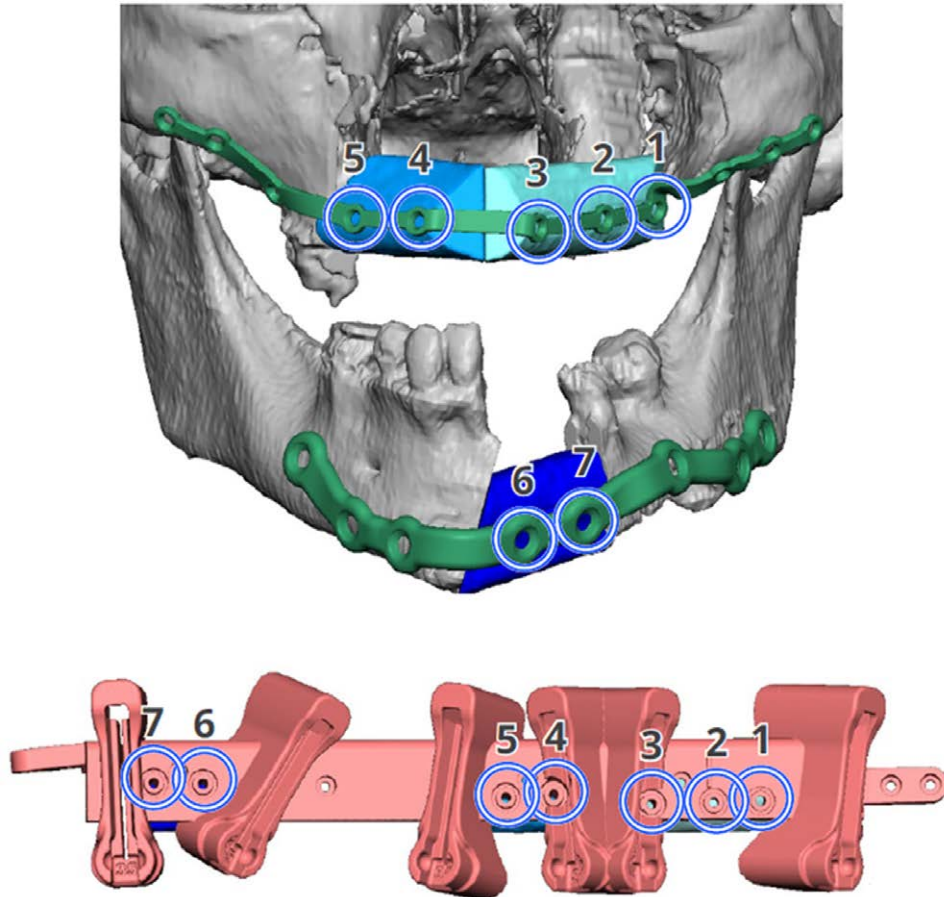


Fig. 2. A 50-year-old woman with composite tissue defects of both the maxilla and mandible secondary to self-inflicted gunshot wound. Image from VSP that demonstrates the planned fibula constructs for simultaneous maxillary and mandibular reconstruction, and patient-specific design of laser-sintered titanium midface plate and prefabricated custom osteotomy guide. Notably, predictive marking holes indicate the relationship between the final and original fibula segments, facilitating easy assembly of the constructs.

holes exactly where desired allows for reinforcement in areas such as the maxillary buttresses to support load bearing structures, and significantly fewer screws are ultimately required. Additionally, this technology allows the surgeon to save both energy and time in the operating room by negating the need to shape standard plates. One technique that has previously been demonstrated to help improve efficiency with this process is the pre-operative bending of standard plates based on virtually generated stereolithographic models.⁷ However, bending also induces metal fatigue, making the plates more likely to fracture or loosen screws following masticatory loading.⁴ As such, the design of patient-specific plates optimizes both the surgical procedure and construct integrity.

Only recently have 3D-printed titanium plates become available. Previous custom plates were milled from a solid block of titanium, and were used almost exclusively in mandible reconstruction due to thickness; 3D printing involves the laser sintering of titanium powder to form a single metal construct.^{2,5} As printing is additive rather than subtractive, it can offer greater freedom of shape,

accuracy, speed, and can help cut cost; our plates can be manufactured in 7 business days. Although not measured empirically, we typically spend about 1 hour in the planning session but save an estimated 2 hours in the operating room.

Literature elaborating on the use of custom titanium plating in the midface remains scarce. Melville et al were among the first to report the use of a 3D-printed titanium plate for a large maxillary defect.⁵ Concurrently, Yang et al prospectively assessed the effectiveness of custom-printed titanium plates for both mandible and maxillary reconstruction, concluding that the process was simplified and accurate.⁴ Others have reported on the use of custom milled plates for midface reconstruction, including LeFort I advancement,⁸ subscapular flap-based reconstruction,⁹ and orbital floor reconstruction.¹⁰

Despite a paucity of large case series, these accounts, in conjunction with ours, illustrate how custom plating can amplify the sophistication of complex reconstructive solutions. Ultimately, patient-specific plates promote a streamlined, accurate, and more rapid reconstructive process.

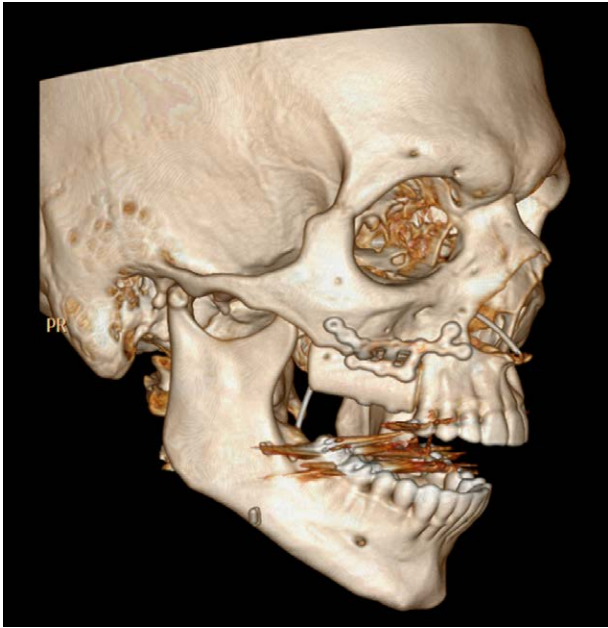


Fig. 3. A 25-year-old man with partial maxillary defect secondary to prior resection of Ewing's sarcoma. Postoperative 3-dimensional CT image demonstrates the inset fibula construct and patient-specific laser-sintered titanium plates. The patient also underwent immediate placement of osseointegrated implant posts for future dental restoration. Here, the ability of individualized custom plates to precisely fit areas of contour is well demonstrated.

Mark W. Stalder, MD

Division of Plastic and Reconstructive Surgery
Louisiana State University Health Sciences Center School of
Medicine
1542 Tulane Ave, Room 734
New Orleans, LA 70112
E-mail: mstald@lsuhsc.edu

ACKNOWLEDGMENT

Our institutional review board approved all content and procedures described within this article.

REFERENCES

1. Parthasarathy J. 3D modeling, custom implants and its future perspectives in craniofacial surgery. *Ann Maxillofac Surg.* 2014;4:9.
2. Matias M, Zenha H, Costa H. Three-dimensional printing: Custom-made implants for craniomaxillofacial reconstructive surgery. *Craniofacial Trauma Reconstr.* 2017;10:89–98.
3. Schepers RH, Raghoebar GM, Vissink A, et al. Accuracy of fibula reconstruction using patient-specific CAD/CAM reconstruction plates and dental implants: A new modality for functional reconstruction of mandibular defects. *J Craniofacial Surg.* 2015;43:649–657.
4. Yang WF, Choi WS, Leung YY, et al. Three-dimensional printing of patient-specific surgical plates in head and neck reconstruction: A prospective pilot study. *Oral Oncol.* 2018;78:31–36.
5. Melville JC, Manis CS, Shum JW, et al. Single-unit 3D-printed titanium reconstruction plate for maxillary reconstruction: The evolution of surgical reconstruction for maxillary defects—A case report and review of current techniques. *J Oral Maxillofac Surg.* 2019;77:874.e1–874.e13.
6. Hidalgo DA. Fibula free flap: A new method of mandible reconstruction. *Plast Reconstr Surg.* 1989;84:71–79.
7. Hanasono MM, Jacob RF, Bidaut L, et al. Midfacial reconstruction using virtual planning, rapid prototype modeling, and stereotactic navigation. *Plast Reconstr Surg.* 2010;126:2002–2006.
8. Runyan CM, Sharma V, Staffenberg DA, et al. Jaw in a day: State of the art in maxillary reconstruction. *J Craniofac Surg.* 2016;27:2101–2104.
9. Swendseid BP, Roden DF, Vimawala S, et al. Virtual surgical planning in subscapular system free flap reconstruction of midface defects. *Oral Oncol.* 2020;101:104508.
10. Eskander A, Kang SY, Teknos TN, et al. Advances in midface reconstruction: Beyond the reconstructive ladder. *Curr Opin Otolaryngol Head Neck Surg.* 2017;25:422–430.