

## Letter to the Editor

***Enterococcus thailandicus*, an unusual pathogen in humans encountered in an intra-abdominal infection**

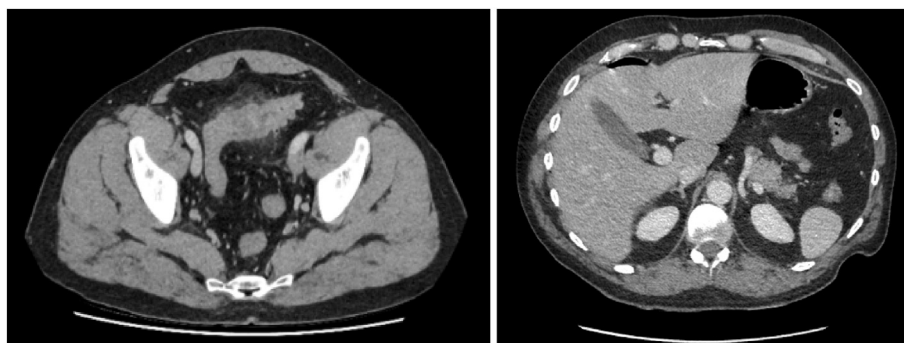
Dear Editor,

Enterococci are bacteria of the commensal digestive and genitourinary flora of humans and animals. They are gram-positive cocci, arranged in a chain or diplococcus, and have an aero-anaerobic metabolism [1]. They are also opportunistic pathogens, which can cause sepsis, urinary or abdominal infections of intestinal origin, as well as nosocomial infections, *Enterococcus faecium* and *Enterococcus faecalis* being the most frequently incriminated species [1]. *Enterococcus thailandicus* is a species whose pathogenicity in humans has not yet been reported.

This letter describes the very first case implicating *E. thailandicus* as a potential pathogen in an intra-abdominal infection in an alcohol-dependent patient presenting with fecaloid peritonitis by perforation of a sigmoid diverticulitis. He is a 43-year-old man who presented with significant abdominal pain evolving for less than 24 hours, without any notion of stopping of materials and gases. His lifestyle habits include the daily consumption of cannabis, around 18 cigarettes and 5 L of alcohol. Clinically, the patient was afebrile, cardiopulmonary auscultation was normal, the abdomen was non-supple, non-depressible and diffusely painful, with no sign of peritonitis. Abdominal CT revealed sigmoid diverticulitis of the proximal third with covered perforation. Biological analyzes showed predominantly neutrophilic leukocytosis, hemoglobin at 14.8 g/dL and C-reactive protein at 64.79 mg/L. Medical care consisted of the administration of analgesics, cefuroxime 1500 mg three times a day and metronidazole 1500 mg daily. Two days later, there was a sharp deterioration in the general condition of the patient, a state of pre-shock and diffuse peritonitis with abdominal defense. The CT scan showed worsening of the perforation with the presence of free pneumoperitoneum (Fig. 1). The patient underwent Hartmann-type surgery, with placement of 3 peritoneal drains and a colostomy, and was then transferred to intensive care. The post-op course was marked by

numerous complications such as sepsis, purulent pneumonitis with hypoxemia, pulmonary vascular overload with bilateral sero-haematic pleural effusion, abscess of the operative wound, and severe protein-calorie malnutrition. Peritoneal drain fluid culture revealed by MALDI-TOF-MS mass spectrometry, *E. faecalis*, *E. faecium*, *Morganella morganii*, *Candida albicans* and *E. thailandicus* which was identified in 2 separate peritoneal fluid samples, with scores of 2.08 and 2.13, respectively. According to the interpretation of the EUCAST 2021 guidelines, it was sensitive to the following antibiotics: ampicillin, vancomycin, linezolid, levofloxacin and ciprofloxacin. Of note, high-level gentamicin resistance was not detected. The patient was treated with a combination of antibiotics based on meropenem 1 g three times a day for 24 days, levofloxacin 500 mg daily for 29 days and vancomycin 1 g two times per day for 5 days. His clinical evolution was favorable. The patient had several risk factors for diverticulitis. This pathology is increasingly observed in people under the age of 50, mainly men [2]. The chronic consumption of alcohol, tobacco, and cannabis leads to a weakening of the immune system, and are also risk factors that the patient presented [2]. Immunocompromised people have increased mortality and morbidity after emergency surgery for diverticulitis compared to immunocompetent people [2], which could explain the multiple complications that were observed in the patient.

Very few studies on *E. thailandicus* exist. On the one hand, its therapeutic potential is highlighted, with probiotic activity [3] or *in vitro* anticancer activity similar to other enterococci. *E. faecium*, *E. faecalis*, as well as *E. thailandicus* would cause cell growth inhibition in hepatocellular carcinoma via its enterocin LNS18 [4]. On the other hand, it remains essential to assess the risks associated with the use of these bacteria as therapeutic agents, and to identify strains that are completely safe [4]. Another study also describes the probable pathogenic role of



**Fig. 1.** Abdominal CT images showing marked parietal thickening of the sigmoid colon at the level of its proximal third. We observe an inflammatory-looking sigmoid diverticulosis, associated with an infiltration of the neighboring fat, microbubbles of extra visceral air pleading for a perforation, a peritoneal fluid reaction, and a perihepatic pneumoperitoneum.

<https://doi.org/10.1016/j.nmni.2023.101137>

Received 13 April 2023; Accepted 20 April 2023

Article published online: 23 April 2023

2052-2975/© 2023 The Authors. Published by Elsevier Ltd. This is an open access article under the CC BY-NC-ND license (<http://creativecommons.org/licenses/by-nc-nd/4.0/>).

*E. thailandicus* in animals. Xiaoying et al. identified *E. thailandicus* in pig feces, and observed alterations in intestinal villi and crypts [5]. To date, this bacterium has never been identified in a sample of human origin. The context of the patient's immunosuppression and the demonstration of *E. thailandicus* in 2 separate peritoneal fluid samples led us to consider it as a potential pathogen in an intra-abdominal infection. However, further investigations are expected to identify the origin of the acquisition of *E. thailandicus* in this patient (via a stay abroad, consumption of certain types of food or close contact with animals ....) but also to elucidate the whole of its pathogenic mechanisms.

### Ethical approval

All the procedures were in accordance with the 1964 Helsinki Declaration and its later amendments.

### Declaration of competing interest

The authors declare that they have no known competing financial interests or personal relationships that could have appeared to influence the work reported in this paper.

### Acknowledgements

The authors thank all the members of the clinical laboratory staff for technical assistance.

### References

- [1] Khalil MA, Alorabi JA, Al-otaibi LM, Ali SS. Antibiotic resistance and biofilm formation in *Enterococcus* spp . Isolated from urinary tract infections. 2023. p. 1–14.

- [2] Francis NK, et al. EAES and SAGES 2018 consensus conference on acute diverticulitis management: evidence-based recommendations for clinical practice. *Surg Endosc* 2019;33(9):2726–41. <https://doi.org/10.1007/s00464-019-06882-z>.
- [3] Li T, et al. A newly isolated *E. thailandicus* strain d5B with exclusively antimicrobial activity against *C. difficile* might be a novel therapy for controlling CDI. *Genomics* 2021;113(1):475–83. <https://doi.org/10.1016/j.ygeno.2020.09.032>.
- [4] Grenda A, Grenda T, Domaradzki P, Kwiatek K. Enterococci—involved in pathogenesis and therapeutic potential in cancer treatment: a mini-review. *Pathogens* 2022;11(6):1–9. <https://doi.org/10.3390/pathogens11060687>.
- [5] Wu X, Wu B, Li Y, Jin X, Wang X. Identification and safety assessment of *Enterococcus thailandicus* TC1 isolated from healthy pigs. *PLoS One* 2021;16(7):1–10. <https://doi.org/10.1371/journal.pone.0254081>.

Patricia Mbouche, Laurent Blairon, Roberto Cupaiolo  
Department of Laboratory Medicine, Iris Hospitals South, Brussels, Belgium

Yasmine Zaouak, Bernard Hainaux  
Department of Radiology, Iris Hospitals South, Brussels, Belgium

Ingrid Beukinga  
Department of Laboratory Medicine, Iris Hospitals South, Brussels, Belgium

Marie Tré-Hardy\*  
Department of Laboratory Medicine, Iris Hospitals South, Brussels, Belgium  
Faculty of Medicine, Université libre de Bruxelles, Brussels, Belgium  
Department of Pharmacy, Namur Research Institute for Life Sciences,  
University of Namur, Namur, Belgium

\* Corresponding author. Department of Laboratory Medicine, Iris Hospitals South, rue Jean Paquot 63, 1050, Brussels, Belgium.  
E-mail address: [mtrehardy@his-izz.be](mailto:mtrehardy@his-izz.be) (M. Tré-Hardy).