



Same-quadrant Baerveldt Glaucoma Implant-250 to Baerveldt Glaucoma Implant-350 exchange

Inae J. Kim, Jessie Wang, Mary Qiu *

The University of Chicago Department of Ophthalmology and Visual Sciences, Chicago, IL, USA

ARTICLE INFO

Keywords:

Baerveldt-350
Baerveldt-250
Tube exchange
Aqueous shunt
Tube shunt
Tube revision
Autologous patch graft
Capsule autograft

ABSTRACT

Purpose: In eyes with a prior failed aqueous shunt (or “tube”) requiring additional intraocular pressure (IOP) control, options include angle surgery, cyclodestruction, second tube, tube revision, or tube exchange. We present a case of a same-quadrant tube exchange of a Baerveldt-250 (BGI-250) to BGI-350.

Observations: The patient is a 71-year-old African American female with severe-stage primary open angle glaucoma of both eyes, and this case focuses on the right eye. This eye had prior cataract surgery with iStent, prior BGI-250 in the anterior chamber (AC), and prior iStent removal with gonioscopy assisted transluminal trabeculotomy (GATT). The visual acuity (VA) was 20/150, and the IOP was 26 mmHg on 3 IOP-lowering medications. The prior superotemporal BGI-250 had its “wings” on top of the superior and lateral rectus muscles and its tube tip in the AC. The implant was removed in its entirety including the superficial and deep layers of its capsule. The new BGI-350 was stented with a 3-0 polypropylene ripcord, ligated with a 7-0 polyglactin suture, and implanted with its wings under the rectus muscles and the tube tip in the sulcus. For early IOP-lowering prior to ligature dissolution, 2 needle stab fenestrations and an additional 7-0 polyglactin wick was used. The capsule from the prior BGI-250 was used as a patch graft for the new BGI-350. The ligature dissolved at postoperative week (POW) 6. By POW8, the IOP was 18 mmHg on 3 IOP-lowering medications and frequent topical steroid, the AC was quiet, and the ripcord was removed. A slow steroid taper finished at postoperative month (POM) 6. By POM 12, the VA was still at baseline 20/150, and the IOP was 14 mmHg on 3 IOP-lowering medications.

Conclusions & importance: Patients with a prior failed tube requiring additional IOP-lowering can undergo a same-quadrant tube exchange. BGI-350s may offer more IOP-lowering than BGI-250s, but the IOP-lowering achieved in this patient’s case could be attributable to differences in postoperative management in addition to endplate size; longer follow-up is needed. A tube exchange offers the opportunity to reposition the tube tip from the AC to the sulcus and to use the prior tube’s capsule as a patch graft for the new tube.

1. Introduction

Aqueous shunts (or “tubes”) are typically implanted in eyes with severe or refractory glaucoma. In eyes with elevated intraocular pressure (IOP) despite a prior tube, options for additional IOP lowering include angle surgery,¹ cyclodestruction,² second tube, tube revision,³ or tube exchange.⁴ A variety of tubes are available, differing in shape, size, and structure (valved versus non-valved). A commonly used non-valved tube is the Baerveldt Glaucoma Implant (BGI) (Johnson and Johnson Surgical Vision, Irvine, California), available with an endplate area of 250 or 350 mm² (BGI-250 and BGI-350 respectively). A fibrous capsule grows around the endplate which provides resistance to aqueous outflow and contributes to the IOP outcome.

The BGI-350 is the type of tube commonly used in studies comparing non-valved tubes to valved tubes and trabeculectomy.^{5,6,7,8} Trials have demonstrated more favorable IOPs with BGI-350 compared to the Ahmed FP7 Glaucoma Valve (AGV) (New World Medical, Rancho Cucamonga, California),^{8,9} and we have published our technique for same-quadrant Ahmed to BGI-350 exchange whereby we described advantages of same-quadrant tube exchange over a second tube.⁴ When comparing different non-valved tubes, larger endplates may have a theoretical advantage of achieving lower IOPs, but there is no consensus in the literature.^{10,11} Herein, via an illustrative case example, we propose that eyes with a prior BGI-250 requiring additional IOP-lowering may benefit from a same-quadrant tube exchange for a BGI-350, with the goal of avoiding or delaying a second tube. A surgical video

* Corresponding author. 5758 S. Maryland Ave, Suite 1B, Chicago, IL, 60637, USA.

E-mail address: maryqiu@bsd.uchicago.edu (M. Qiu).

<https://doi.org/10.1016/j.ajoc.2023.101975>

Received 1 October 2023; Received in revised form 18 November 2023; Accepted 4 December 2023

Available online 7 December 2023

2451-9936/© 2023 The Authors. Published by Elsevier Inc. This is an open access article under the CC BY-NC-ND license (<http://creativecommons.org/licenses/by-nc-nd/4.0/>).

demonstrating the steps of the surgical procedure is included in the supplemental materials.

2. Case report

The patient is a 71-year-old African American female with primary open angle glaucoma of both eyes. This report focuses on the right eye, which has had prior cataract surgery with first-generation iStent (Glaukos, San Clemente, California) and subsequent implantation of a superotemporal BGI-250 with the endplate wings on top of the superior and lateral rectus muscles and the tube tip in the anterior chamber (AC). She was referred to us with an IOP of 30 mmHg on 3 topical IOP-

lowering medications. We removed the iStent and performed a gonioscopy-assisted transluminal trabeculotomy (GATT). Ten months later, the visual acuity (VA) was baseline 20/150, IOP was 26 mmHg on 3 topical IOP-lowering medications, which was her maximum tolerated medication therapy. Options included cyclodestruction, a second tube, or a same-quadrant tube exchange, and she elected the latter.

The conjunctiva was opened at the limbus, and the prior tube and scleral patch graft were identified. The AC was filled with viscoelastic, the prior superotemporal BGI-250 was disinserted from the AC, and the tube track was sutured with 8-0 polyglactin suture on a tapered needle. A 6-0 polyglactin posterior scleral traction suture was placed to rotate the eye. The endplate and capsule were removed, and the capsule was

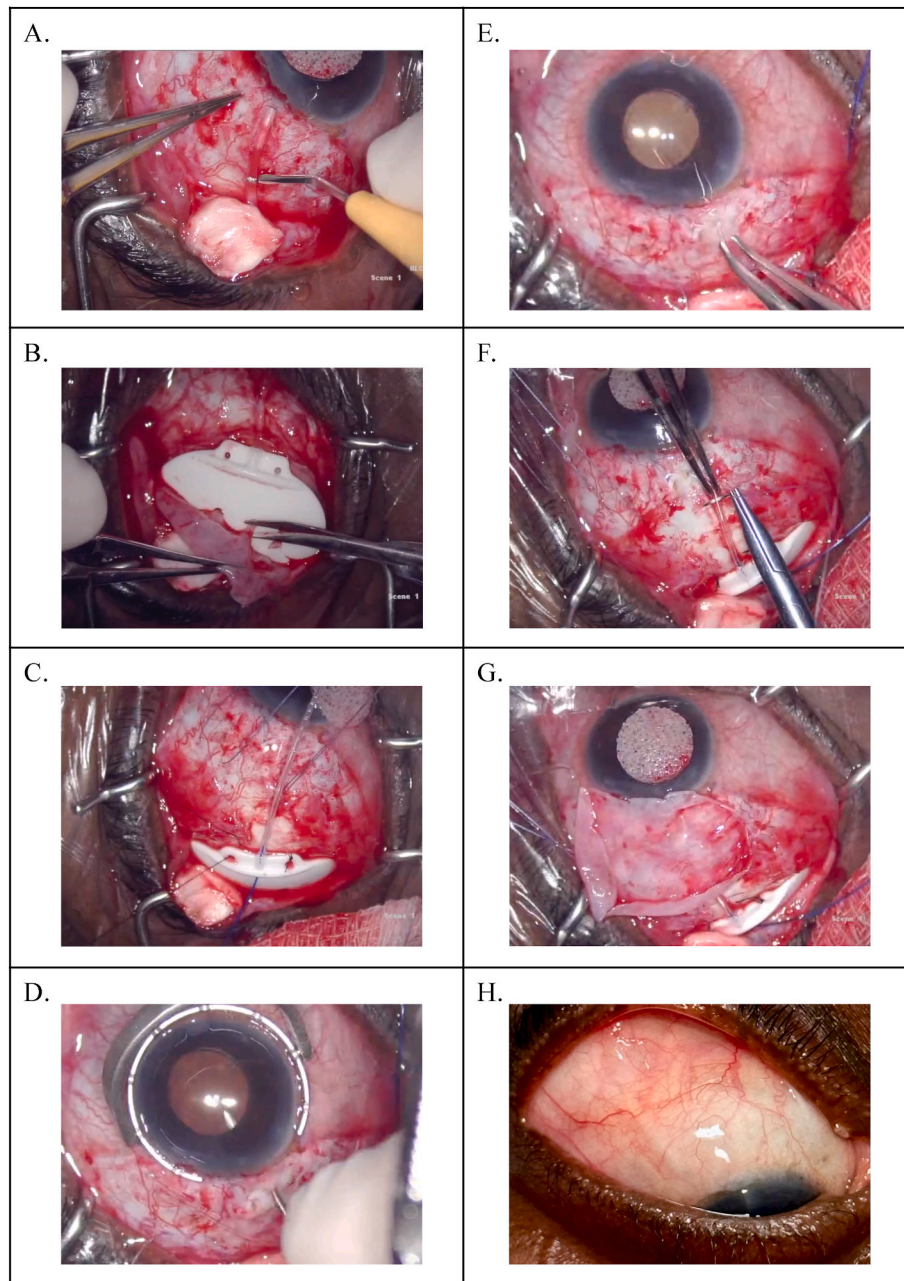


Fig. 1. Video stills highlighting key didactic points from the surgery. **A.** Dissection of prior BGI-250 off of globe - separation of tube from sclera. **B.** Dissection of anterior capsule off of the prior BGI-250 device plate. The anchoring stalks growing through the holes are severed, and the capsule is harvested and preserved for use as autologous patch graft. **C.** New BGI-350 in place with 7-0 polyglactin suture ligature and 3-0 polypropylene ripcord in lumen of tube. **D.** Non-tunneled sclerotomy created with 23G straight needle. **E.** Tube inserted into sulcus and tube tip visible through pupil. **F.** Stab-needle fenestrations created for early IOP-lowering. **G.** Prior BGI-250 capsule tissue positioned over new BGI-350 tube as autologous patch graft to be sutured onto sclera. **H.** Post-operative month 12. Image of superotemporal BGI-350.

dissected off of the surface of the superior and lateral rectus muscles (Fig. 1A). A block of capsule tissue was harvested for subsequent use as a patch graft (Fig. 1B).¹² A new superotemporal BGI-350 was stented with a 3-0 polypropylene ripcord suture, ligated with a 7-0 polyglactin ligature, and affixed to the bare sclera in the superotemporal quadrant with 8-0 silk suture with the implant wings under the superior and lateral rectus muscles (Fig. 1C). A 23-gauge needle was used to make a non-tunneling sclerotomy into the ciliary sulcus, through which the tube was inserted (Fig. 1D and E). Two fenestrations were made with a SE-160-9 spatulated needle, and an additional 7-0 polyglactin wick was used for early IOP-lowering prior to ligature dissolution (Fig. 1F). The autologous capsule patch graft was used to cover the new tube entry site and old tube removal site (Fig. 1G). The 3-0 polypropylene ripcord was tunneled subconjunctivally and routed to the inferior subconjunctival space. The conjunctiva was reapproximated to the limbus and closed with 7-0 surgical gut suture without tension. Viscoelastic was rinsed out of the AC with balanced salt solution on an AC cannula, and intracameral antibiotic was administered, along with subconjunctival antibiotics and steroids. Intravenous steroid was administered by the anesthesia team. Topical antibiotic, steroid, and cycloplegic eyedrops were administered, and the eye was patched and shielded.

On postoperative day 1, the VA was count fingers, IOP was 2 mmHg, AC was deep, and there were no visible choroidal effusions in the posterior pole; but it was assumed that she likely had peripheral choroidal effusions. Topical steroid (prednisolone acetate every 2 hours), antibiotic, and cycloplegic eyedrops were initiated, and the baseline 3 IOP-lowering medications were stopped. By postoperative week (POW) 1, the VA was still count fingers, IOP was 4 mmHg, AC was deep, and there were visible peripheral choroidal effusions; steroid and cycloplegic eyedrops were continued. By POW2, the VA improved to 20/500, IOP rose to 28 mmHg, AC was deep, and the choroidal effusions had resolved; the steroid was increased to 4 times per day (patient was mistakenly using 2 times per day), the cycloplegic was stopped, and the 3 baseline IOP-lowering medications were resumed. By POW4, the VA improved to 20/200, IOP was 8 mmHg on 3 IOP-lowering medications, AC was deep, and choroidal effusions remained resolved; the steroid was again emphasized to be 4 times per day (patient was still mistakenly using 2 times per day), and the 3 baseline IOP-lowering medications were continued. By POW7, the ligature had dissolved, the VA improved to baseline 20/150, IOP was 18 mmHg on 3 IOP-lowering medications, and AC was deep with 1+ cell in part due to ongoing patient error with topical steroid frequency (she was still mistakenly using the prednisolone 2 times per day); steroids were again emphasized to be 4 times per day to reduce AC inflammation prior to considering ripcord removal. By POW8, the VA remained stable at baseline 20/150, IOP was still 18 mmHg on 3 IOP-lowering medications, and the AC was quiet; the ripcord was removed, and she was instructed to do a slow steroid taper by reducing the steroid frequency by one drop-per-day per month. Six weeks later, at POM3, the VA remained 20/150, IOP was 15 mmHg on 3 IOP-lowering medications and steroid was still 4 times per day (patient mistakenly did not taper to 3 times per day). At POM4, the VA remained 20/150, IOP was 15 mmHg on 3 IOP-lowering medications and steroid 3 times per day. At POM5, VA remained 20/150, IOP was 16 mmHg on 3 IOP-lowering medications and steroid 2 times per day. She was lost to follow-up between POM5 and POM10 but did complete her steroid taper on schedule. At POM10, VA remained 20/150, IOP was 15 mmHg on 3 IOP-lowering medications, and she had been off steroid for 4 months. At POM12, the most recent follow-up, VA remained at baseline 20/150, and IOP was 14 mmHg on 3 IOP-lowering medications (Fig. 1H).

3. Discussion & conclusions

In eyes with a prior BGI-250 requiring further IOP-lowering, we propose a same-quadrant BGI-250 to BGI-350 exchange. In all complex tube revision surgeries, we advocate for general anesthesia and a posterior scleral traction suture to enhance patient comfort and exposure of

the surgical field. In addition to exchanging the device for one with a larger endplate to promote lower long-term IOP, a same-quadrant tube exchange also offers the opportunity to reposition the tube tip from the AC to sulcus which may be favorable for the cornea¹³ while minimizing the potential complications associated with a second tube.³ Furthermore, a same-quadrant tube exchange offers the opportunity for an autologous capsular autograft to be harvested from the old tube and used to cover the new tube.¹² We have described our technique for same-quadrant Ahmed FP7 to Baerveldt-350 exchange,⁴ and this report describes our technique and special considerations for performing a BGI-250 to BGI-350 exchange.

In our case, the prior tube's entire capsule was removed, and the new tube was sutured to the bare sclera and allowed to grow a new capsule "from scratch". The old tube had been placed on top of the muscles which rendered it relatively easier to access and remove the entire superficial and deep layers of the capsule. If the prior tube endplate and been positioned under the rectus muscles, the capsule would have had to be dissected and removed from under the muscle edge in order to create enough space for the new wider endplate, which may have been more technically challenging. Several other factors besides the endplate size have likely contributed to the success of the new BGI-350 so far. We do not have records from the postoperative period after her original BGI-250, and different surgeons have vastly different practice patterns for postoperative steroid dosing after non-valved tubes.¹⁴ We administered intravenous steroids at the time of surgery, started her on topical prednisolone every 2 hours, and instructed her to do a relatively slow 6-month steroid taper. We hypothesize that our steroid dosing may help reduce encapsulation of the new BGI-350's endplate and favorable IOP outcomes. We did not have any reason to consider opening the tube early, since the IOP at POW4 was 8 mmHg on 3 IOP-lowering medications, but even if the IOP had been above target at that time point, we would advocate for waiting for the ligature to spontaneously dissolve, since opening tubes early may introduce pro-inflammatory aqueous over the endplate which may promote excessive encapsulation, which is a concept borrowed from employing early aqueous suppression after valved tube shunt surgery.¹⁵ In addition, when the ligature spontaneously dissolved on schedule and there was 1+ AC inflammation, the 3-0 polypropylene ripcord was left in place and the steroid dose was increased to achieve a quiet AC prior to considering ripcord removal. It is common for eyes to develop AC inflammation and/or hypotony associated complications when the ligature spontaneously dissolves. Since the ripcord provides partial lumen obstruction and reduces aqueous outflow over the endplate, delayed ripcord removal provides an opportunity to adjust the dosing of steroids and/or IOP-lowering medications to achieve more optimized conditions before fully opening the tube.¹⁶ Different surgeons have vastly different practice patterns for ripcord usage in non-valved tubes,¹⁴ and we propose that a thick ripcord may be helpful when performing a same-quadrant tube exchange for a new non-valved tube. Eyes may not behave as expected after a tube exchange compared to a primary tube, and having a thick ripcord in place provides an additional point of titration for anti-inflammatory and IOP-lowering medications when the new tube's ligature spontaneously dissolves, which may facilitate a more predictable and less volatile postoperative course. This step is not critically necessary and a same-quadrant tube exchange can still be performed without a ripcord. We did not have access to the operative note from her original BGI-250 surgery, so we do not know if and how a ripcord was used; regardless, we hypothesize that our judicious usage and management of the 3-0 polypropylene ripcord contributed to her successful postoperative course. A tube exchange is a relatively longer surgery which may induce more postoperative inflammation and decreased aqueous production in the setting of postoperative inflammation can also contribute to choroidal effusions. We recommend much higher steroid dosing after tube exchange than with a primary tube.

There are some limitations to our surgical strategy and this patient's postoperative course. Since BGI-350s are non-valved, exchanging for a

new BGI-350 requires employing a strategy to achieve acceptable early IOP-lowering prior to spontaneous ligature dissolution, such as an orphan trabeculectomy,¹⁷ adjunctive goniotomy,¹⁸ cyclodestruction, or fenestrations with or without wicks.^{14,19} Our usual practice pattern for primary non-valved consists of (1) 3 needle-stab fenestrations, which may create more uniform slits those that created with a blade, (2) no wick, and (3) an adjunctive goniotomy if the angle anatomy and clinical circumstances are amenable. Since this patient already underwent a prior 360-degree GATT, an adjunctive goniotomy would not be possible, so we employed 2 needle-stab fenestrations and an additional 7-0 polyglactin wick, which represents a more aggressive early IOP-lowering strategy than our usual approach. A retrospective comparative case series in the literature described outcomes of BGI-350s with fenestrations (3 venting slits created by a Supersharp blade) with or without a 7-0 polyglactin wick. In the wick group, the rate of hypotony (IOP \leq 5 mmHg) in the first two postoperative months was 21 %, and the rate of choroidal effusions was not reported.¹⁷ Our patient received a similar 7-0 polyglactin wick with 2 needle stab fenestrations rather than 3 Supersharp blade fenestrations and did develop early postoperative hypotony (IOP \leq 5 mmHg) and peripheral choroidal effusions which resolved by POW2. We hypothesize that this was due to the relatively large 7-0 polyglactin wick that was used, and a smaller wick such as a 10-0 suture may have reduced the risk of early choroidal effusions. Since we did expect robust outflow from the relatively large wick, we did instill cycloplegic eyedrops at the end of the surgery and maintained her on postoperative cycloplegic eyedrops until the choroidal effusions resolved.

In summary, this pseudophakic patient with a prior failed BGI-250 in the AC already failed prior GATT and subsequently underwent a same-quadrant exchange for a new BGI-350 in the sulcus. She maintained baseline VA while achieving 12 mmHg of additional IOP-lowering, from 26 mmHg to 14 mmHg on the same 3 baseline IOP-lowering medications, with 12 months of follow-up. Aside from early self-limited peripheral choroidal effusions, she did not experience any other intraoperative or postoperative complications. The larger endplate size in addition to judicious intraoperative and postoperative management contributed to her successful outcome so far. Longer follow-up will be needed to describe the long-term success rates of same-quadrant BGI-250 to BGI-350 exchange.

Patient consent

Consent to publish the case report was not obtained. This report does not contain any personal information that could lead to the identification of the patient.

Funding

There was no funding or grant support for this report.

Authorship

All authors attest that they meet the current ICMJE criteria for Authorship.

CRediT authorship contribution statement

Inae J. Kim: Data curation, Writing – original draft, Writing – review & editing. **Jessie Wang:** Data curation, Writing – original draft, Writing – review & editing. **Mary Qiu:** Conceptualization, Data curation, Supervision, Writing – original draft, Writing – review & editing.

Declaration of competing interest

The authors declare that they have no known competing financial interests or personal relationships that could have appeared to influence

the work reported in this paper.

Acknowledgements

None.

Appendix A. Supplementary data

Supplementary data to this article can be found online at <https://doi.org/10.1016/j.ajoc.2023.101975>.

References

- Grover DS, Godfrey DG, Smith O, Shi W, Feuer WJ, Fellman RL. Outcomes of gonioscopy-assisted transluminal trabeculectomy (GATT) in eyes with prior incisional glaucoma surgery. *J Glaucoma*. 2017 Jan;26(1):41–45. <https://doi.org/10.1097/JG.0000000000000564>.
- Levinson JD, Giangiacomo AL, Beck AD, et al. A comparison of sequential glaucoma drainage device implantation versus cyclophotocoagulation following failure of a primary drainage device. *J Glaucoma*. 2017 Apr;26(4):311–314. <https://doi.org/10.1097/JG.0000000000000370>.
- Si Z, Theophanous C, Khanna S, Qiu M. Early intraocular pressure control via capsule revision of a failed valved aqueous shunt during concurrent placement of a nonvalved aqueous shunt. *Ophthalmol Glaucoma*. 2022 Mar-Apr;5(2):229–232. <https://doi.org/10.1016/j.ogla.2021.08.006>. Epub 2021 Sep. 6.
- Kim IJ, Kanter JA, Qiu M. A surgical technique for same-quadrant ahmed to Baerveldt exchange. *Ophthalmol Glaucoma*. 2023. <https://doi.org/10.1016/j.ogla.2023.05.004>.
- Luo N, Liu M, Hao M, et al. Comparison of tube shunt implantation and trabeculectomy for glaucoma: a systematic review and meta-analysis *BMJ Open*. 2023;13, e065921. <https://doi.org/10.1136/bmjopen-2022-065921>.
- Gedde SJ, Schiffman JC, Feuer WJ, Herndon LW, Brandt JD, Budenz DL. Tube versus trabeculectomy study group. Treatment outcomes in the tube versus trabeculectomy (TVT) study after five years of follow-up. *Am J Ophthalmol*. 2012 May;153(5):789–803.e2. <https://doi.org/10.1016/j.ajo.2011.10.026>. Epub 2012 Jan 15.
- Gedde SJ, Feuer WJ, Lim KS, et al. Primary tube versus trabeculectomy study group. Treatment outcomes in the primary tube versus trabeculectomy study after 3 years of follow-up. *Ophthalmology*. 2020 Mar;127(3):333–345. <https://doi.org/10.1016/j.ophtha.2019.10.002>. Epub 2019 Oct 9.
- Budenz DL, Barton K, Gedde SJ, et al, Ahmed Baerveldt Comparison Study Group. Five-year treatment outcomes in the Ahmed Baerveldt comparison study. *Ophthalmology*. 2015 Feb;122(2):308–316. <https://doi.org/10.1016/j.ophtha.2014.08.043>. Epub 2014 Oct 17.
- Christakis PG, Kalenak JW, Tsai JC, et al. The ahmed versus Baerveldt study: five-year treatment outcomes. *Ophthalmology*. 2016 Oct;123(10):2093–2102. <https://doi.org/10.1016/j.ophtha.2016.06.035>. Epub 2016 Aug 17.
- Rodgers CD, Meyer AM, Sherwood MB. Relationship between glaucoma drainage device size and intraocular pressure control: does size matter? *J Curr Glaucoma Pract*. 2017;11(1):1–2. <https://doi.org/10.5005/jp-journals-10008-1212>.
- Allan EJ, Khaimi MA, Jones JM, Ding K, Skuta GL. Long-term efficacy of the Baerveldt 250 mm2 compared with the Baerveldt 350 mm2 implant. *Ophthalmology*. 2015 Mar;122(3):486–493. <https://doi.org/10.1016/j.ophtha.2014.09.002>.
- Qiu M. Aqueous shunt revision with autologous capsular patch graft: surgical technique description and preliminary results. *Ophthalmol Glaucoma*. 2021 Nov-Dec;4(6):646–648. <https://doi.org/10.1016/j.ogla.2021.05.005>.
- Zhang Q, Liu Y, Thanapaisal S, et al. The effect of tube location on corneal endothelial cells in patients with ahmed glaucoma valve. *Ophthalmology*. 2021 Feb;128(2):218–226.
- Zhang JY, Qiu M. Techniques and preferences for nonvalved aqueous shunts: a survey of American glaucoma society members, 00133-3 *Ophthalmol Glaucoma*. 2023 Jul 16;S2589–4196(23). <https://doi.org/10.1016/j.ogla.2023.07.006>. Epub ahead of print.
- Pakravan M, Rad SS, Yazdani S, Ghahari E, Yaseri M. Effect of early treatment with aqueous suppressants on Ahmed glaucoma valve implantation outcomes. *Ophthalmology*. 2014 Sep;121(9):1693–1698. <https://doi.org/10.1016/j.ophtha.2014.03.014>. Epub 2014 May 10. Erratum in: *Ophthalmology*. 2017 Jun;124(6):922.
- Wang J, Chun LY, Qiu M. Baerveldt-350 with 3-0 prolene ripcord to minimize hypotony-associated complications after spontaneous ligature dissolution, 00132-1 *Ophthalmol Glaucoma*. 2023 Jul 15;S2589–4196(23). <https://doi.org/10.1016/j.ogla.2023.07.005>. Epub ahead of print.
- Schwartz KS, Lee RK, Gedde SJ. Glaucoma drainage implants: a critical comparison of types. *Curr Opin Ophthalmol*. 2006 Apr;17(2):181–189. <https://doi.org/10.1097/01.icu.0000193080.55240.7e>.
- Kanter JA, Khanna S, Theophanous C, Qiu M. Baerveldt-350 with adjunctive goniotomy: pilot results. *AJO Case reports*. 2023 Dec;32. <https://doi.org/10.1016/j.ajoc.2023.101950>.
- Rothman AL, An SJ, Herndon Jr LW. The effect of suture wick technique on early intraocular pressure control after nonvalved (Baerveldt 350) glaucoma drainage device surgery. *J Glaucoma*. 2018 Dec;27(12):1145–1150. <https://doi.org/10.1097/JG.0000000000001080>.