

## Clinical, Magnetic Resonance Imaging, and Histopathologic Findings in 6 Dogs with Surgically resected Extraparenchymal Spinal Cord Hematomas

D.W. Hague, S. Joslyn, W.W. Bush, E.N. Glass, and A.C. Durham

**Background:** Extraparenchymal spinal cord hematoma has been described in veterinary medicine in association with neoplasia, intervertebral disk disease, and snake envenomation. There are rare reports of spontaneous extraparenchymal spinal cord hematoma formation with no known cause in human medicine. Multiple cases of spontaneous extraparenchymal spinal cord hematoma have not been described previously in veterinary medicine.

**Objectives:** To describe the signalment, clinical findings, magnetic resonance imaging (MRI) features, and surgical outcomes in histopathologically confirmed extraparenchymal spinal cord hematomas in dogs with no identified underlying etiology.

**Animals:** Six dogs had MRI of the spinal cord, decompressive spinal surgery, and histopathologic confirmation of extraparenchymal spinal cord hematoma not associated with an underlying cause.

**Methods:** Multi-institutional retrospective study.

**Results:** Six patients had spontaneous extraparenchymal spinal cord hematoma formation. MRI showed normal signal within the spinal cord parenchyma in all patients. All hematomas had T2-weighted hyperintensity and the majority (5/6) had no contrast enhancement. All dogs underwent surgical decompression and most patients (5/6) returned to normal or near normal neurologic function postoperatively. Follow-up of the patients (ranging between 921 and 1,446 days) showed no progression of neurologic clinical signs or any conditions associated with increased bleeding tendency.

**Conclusions and Clinical Importance:** Before surgery and histopathology confirming extraparenchymal hematoma, the primary differential in most cases was neoplasia, based on the MRI findings. This retrospective study reminds clinicians of the importance of the combination of advanced imaging combined with histopathologic diagnosis. The prognosis for spontaneous spinal cord extraparenchymal hematoma with surgical decompression appears to be favorable in most cases.

**Key words:** Hemorrhage; Laminectomy; Myelopathy.

In dogs, extraparenchymal spinal cord hemorrhage most often is associated with intervertebral disk herniation.<sup>1–6</sup> There also are some case reports of hemorrhage around the spinal cord secondary to coagulopathies, such as Von Willebrand's Disease,<sup>7</sup> brown snake envenomation,<sup>8</sup> and hemophilia A.<sup>9</sup> In addition, there are reports of hemorrhage associated with granular cell neoplasia in the lumbar spine,<sup>10</sup> hemangiosarcoma in the thoracic spinal cord,<sup>11</sup> trauma,<sup>12</sup> and spinal surgery.<sup>13</sup>

In human patients, the most common causes of extraparenchymal spinal cord hematoma include coagulopathies, anticoagulant treatment, vascular anomalies, intervertebral disk disease, neoplasia, and epidural catheters.<sup>14</sup> Of those patients diagnosed with

---

### Abbreviations:

CBC	complete blood count
MRI	magnetic resonance imaging

---

extraparenchymal hematoma, an underlying etiology of the bleeding cannot be determined in 29.7% of cases. These cases are classified as spontaneous hematoma.<sup>14</sup>

The goal of this report was to describe the condition of spontaneous extraparenchymal spinal cord hemorrhage in dogs including the signalment, history, initial clinical presentation, diagnostic findings, and surgical outcomes. A recent case report describes the MRI features and surgical outcome in an intradural, extraparenchymal spinal cord hematoma.<sup>15</sup> To the author's knowledge, this report is the first retrospective evaluation of multiple cases of spontaneous extraparenchymal spinal cord hemorrhage in dogs.

## Materials and Methods

### Criteria for Selection of Cases

A search of the University of Pennsylvania, School of Veterinary Medicine, Department of Pathobiology surgical biopsy database included all dogs with hemorrhage associated with the vertebral canal from 2000 to 2012. Cases with histopathologic evidence of neoplasia or disk material were excluded. The medical records were searched using the following search criteria: MRI of the spinal cord, surgical removal and biopsy of the hemorrhagic tissue, histopathologic diagnosis of hematoma, neurologic examination (pre- and postsurgery), no evidence of prior or progressive hemorrhagic states, and no history of trauma. For

---

*From the Department of Veterinary Clinical Medicine, College of Veterinary Medicine, University of Illinois, Urbana, IL (Hague, Joslyn); the Clinical Neurology, Bush Veterinary Neurology Service, Leesburg, VA (Bush); the Section of Neurology and Neurosurgery, Red Bank Veterinary Hospital, Tinton Falls, NJ (Glass); and the Department of Pathobiology, School of Veterinary Medicine, University of Pennsylvania, Philadelphia, PA (Durham).*

*This retrospective study was presented as an abstract in the 2012 ACVIM Forum, New Orleans, LA.*

*Corresponding author: D.W. Hague, DVM, Department of Veterinary Clinical Medicine, College of Veterinary Medicine, University of Illinois at Urbana-Champaign, Urbana, IL 61802; e-mail: [hague@illinois.edu](mailto:hague@illinois.edu).*

*Submitted January 25, 2014; Revised August 6, 2014; Accepted September 11, 2014.*

*Copyright © 2015 by the American College of Veterinary Internal Medicine*

*DOI: 10.1111/jvim.12481*

the latter criteria, patients were evaluated for the following factors: Normal CBC findings including erythrocyte and platelet numbers, normal coagulation profiles (available for only 1 patient), and no history of anticoagulant treatment (eg, aspirin).

### **Procedures**

Six cases diagnosed with extraparenchymal hematoma met the search criteria. Three cases were from Bush Veterinary Neurology Service, 2 cases were from Red Bank Veterinary Hospital, and 1 case was from the University of Pennsylvania. The following information was retrieved from the medical records: signalment, history, physical examination findings (including neurologic examination findings), clinical laboratory results, MRI findings, and surgical description. In addition, short-term follow-up (12–16 days after surgery) at suture removal with physical examination findings (including neurologic examination findings) also were recorded. When available, long-term follow-up (>2 years from surgery) was completed by telephone or email conversation with the owners.

The neurologic grade was determined for each patient pre- and postsurgery (10–17 days) using an adjusted modified Frankel spinal cord injury scale (Fig 1).<sup>16</sup> High-field MRI<sup>a, b</sup> was utilized and all patients were imaged pre- and post-IV gadolinium contrast administration.<sup>c, d</sup> The images initially were reviewed by a board-certified neurologist or radiologist, or both involved with the case, and retrospectively, all MRI findings were reviewed by a single board-certified radiologist (SJ). The T1-weighted (pre- and postgadolinium contrast) and T2-weighted characteristics of the extraparenchymal hemorrhagic material were recorded in comparison to the spinal cord parenchyma.<sup>17</sup>

## **Results**

### **Signalment**

There were 2 mixed breed dogs and 1 of each of the following breeds: Greyhound, Australian cattle dog, Boxer, and Labrador Retriever. Three dogs were spayed females and 3 were castrated males. The median age at diagnosis was 6 years (range, 1–9 years). The median body weight was 31 kg (range, 19–42 kg).

### **History and Initial Clinical Presentation**

The median time between the initial clinical signs reported by the owners and time to presentation and imaging was 3.5 days (range, 1–13 days). All dogs had a history of progressive clinical signs. Two dogs had an acute onset (1–2 days) and 4 dogs had a chronic onset (3 days to 2 weeks). On initial neurologic examination, the majority of patients were ambulatory with some degree of paresis, 2 patients were nonambulatory paretic, and 1 patient was paraplegic. All ambulatory

patients also exhibited proprioceptive ataxia. On examination of the majority of patients, pain was elicited by manipulation of the vertebral column at the level of associated hemorrhage (5/6). Based on neurologic examination, 3 patients had neurologic lesions localized to C1–C5, 1 patient to T3–L3, and 2 patients to L4–S3.

### **Ancillary Diagnostics**

All patients had preanesthetic CBC and serum biochemistry profiles. The most common abnormality identified was a mild leukocytosis or neutrophilia, or both (4/6) and mild hyperglycemia (3/4), consistent with stress. All patients had normal platelet counts and a coagulation profile (prothrombin time/partial thromboplastin time) performed in 1 patient was normal.

Abdominal ultrasound examinations were performed in 2 patients (33%) and showed no abnormalities. Cerebrospinal fluid analysis was performed in 1 patient and was normal.

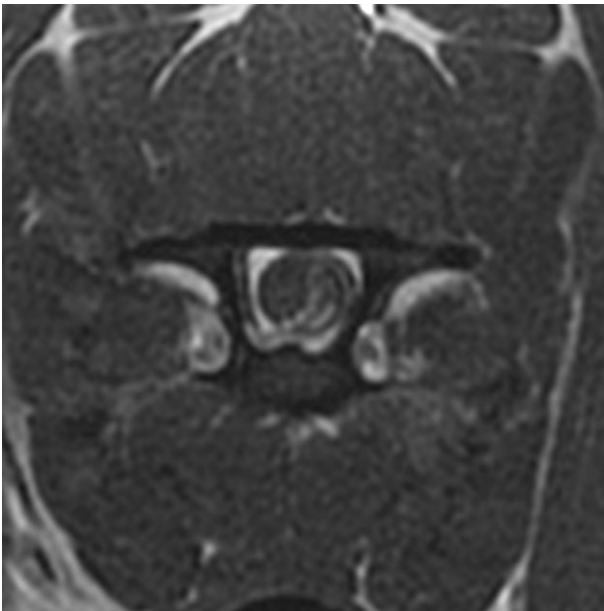
### **MRI Findings**

Magnetic resonance imaging of the cervical and thoracic spinal cord segments was performed in 3 patients and of the thoracic, lumbar, and sacral spinal cord segments in the other 3 patients. Extraparenchymal lesions were observed at the following vertebral segments: the cervical spine in 3 patients (C2, C4–5, and C5), the thoracolumbar spine in 1 patient (T13–L1), and in the lumbar spine in 2 patients (L5 and L6–7). In 5 cases, the hemorrhage was extradural and 1 case it was intradural extraparenchymal.

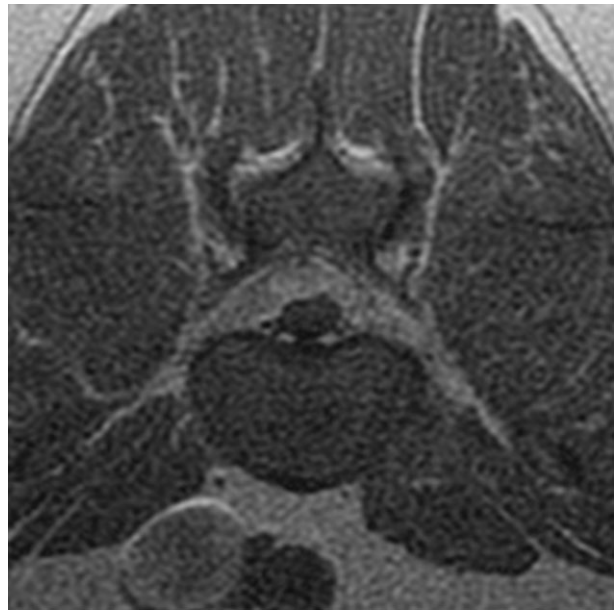
In all cases, the following MRI sequences were available for review and comparison: T1-weighted pre-contrast (sagittal and transverse), T2-weighted sagittal and transverse, and T1-weighted postcontrast transverse images (Figs 2–4). Compared to the spinal cord parenchyma, the T2-weighted imaging of the extraparenchymal material was mildly hyperintense in half of the cases, strongly hyperintense in 2/6 of cases, and heterogenous to slightly hyperintense in 1 case. The extraparenchymal hemorrhagic material appeared isointense on the T1-weighted images in the majority of cases (4/6), mildly heterogeneously hyperintense in 1 case, and had peripheral ring hyperintensity in 1 case. The extraparenchymal hemorrhagic material showed strong contrast enhancement in 1 case and no contrast enhancement in the other 5 cases. A T2\* was available

Grade 1 – Plegia with absent nociceptive sensation
Grade 2 – Plegia with intact nociceptive sensation
Grade 3b - Nonambulatory paresis; inability to bear weight in limbs without support
Grade 3a – Nonambulatory paresis; ability to bear weight in limbs without support
Grade 4 - Ambulatory paresis
Grade 5 – Normal gait with paraspinous hyperesthesia

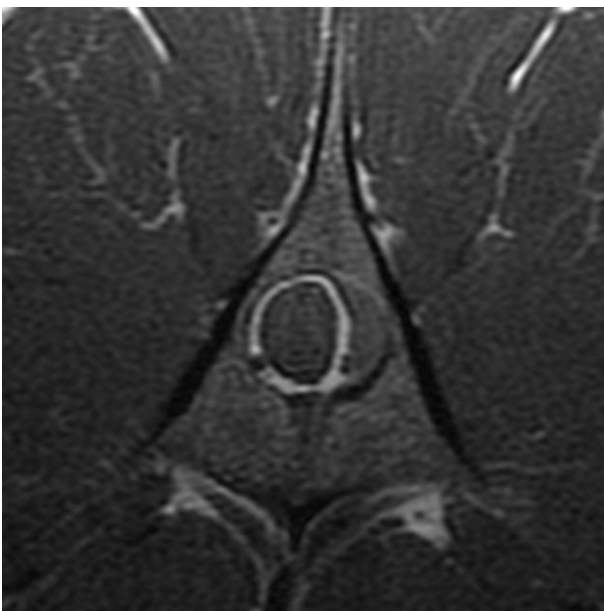
**Fig 1.** Adjusted modified Frankel spinal cord injury score.<sup>16</sup>



**Fig 2.** Transverse T2-weighted image at the level of the C4 vertebra. There is a large mildly hyperintense extraparenchymal heterogeneous lesion causing moderate left-sided lateral spinal cord compression.



**Fig 4.** Transverse T1-weighted image at the level of the L6-7 vertebra. There is a large collection of extraparenchymal mixed signal intensity dorsal to the spinal cord. This extended the length of the lumbar and lumbosacral spine.



**Fig 3.** Transverse T1-weighted image at the level of the L5 vertebra. There is an isointense extraparenchymal lesion causing moderate left-sided distortion of the spinal canal as it is displaced toward the right.

in 1 case, in which the extraparenchymal material appeared hypointense, consistent with hemorrhage.

Postoperative MRI was performed in 1 patient and showed complete removal of the intradural, extraparenchymal material and decompression of the spinal cord.

### *Histopathology Findings*

All 6 biopsy samples were formalin fixed, paraffin embedded, and stained with hematoxylin and eosin (HE). A board-certified veterinary pathologist reviewed the samples; the slides were retrospectively reviewed by a single pathologist (AD). All of the samples showed a coagulum of erythrocytes and fibrin, consistent with hematoma, and no evidence of disk material or neoplasia was observed.

### *Surgical Outcomes*

The following surgical procedures were performed: right hemilaminectomy at C2-3, modified dorsal left laminectomy at C4-5, dorsal laminectomy at C5, right hemilaminectomy at T13-L1, left hemilaminectomy at L3-5, and dorsal laminectomy at L6-7. All of the extraparenchymal material was completely removed in 5/6 cases. Hemorrhage material was adhered to the spinal cord that could not be removed in the patient that underwent dorsal laminectomy at L6-7. This was the only patient that showed worsening of neurologic grade postoperatively (from Grade 2 to 1).

In the 5 patients who improved, 4 improved by 1 neurologic grade and 1 improved by one-half a grade. Three patients were neurologically normal at postoperative assessment (within 13 days).

### *Long-term Follow-up*

Telephone or email follow-up with owners of 5 of the 6 patients was achieved. Four of the 5 patients did not develop any further neurologic or medical

problems from the time of surgery to follow-up and all were walking normally, according to the owners. One patient was euthanized 1,446 days after surgery for unknown reasons. The median time between surgery and follow-up was 1,103 days (range, 921–1,446 days). There was no follow-up available on the patient that did not show neurologic improvement postoperatively.

### Discussion

The findings of this retrospective case series show that extraparenchymal hematomas can occur spontaneously in dogs. The term extraparenchymal is used to represent both material within the dura and outside of the parenchyma (intradural, extraparenchymal) and outside of the dura (extradural, extraparenchymal).

The MRI characteristics were variable with mild to moderate T2W hyperintensity, isointense to mildly hyperintense T1-weighted precontrast sequences, and typically absent contrast enhancement (with 1 case showing strong contrast enhancement). Extraparenchymal hemorrhage could cause subsequent inflammation of fat and the superimposition of fat signal also could contribute to the T2 hyperintensity seen with these patients. Surgical decompression had a favorable outcome in most patients. Histopathology confirmed hematoma in all cases and should be considered a differential diagnosis in cases with a noncontrast-enhancing extraparenchymal mass.

In people, the chief complaint of spinal cord extraparenchymal hematoma in the majority of patients is pain and variable degrees of neurologic dysfunction.<sup>18–20</sup> Neurologic function was variable in this retrospective review of affected dogs. In addition, pain was exhibited in the majority of dogs in this study. The pain is likely multifactorial (similar to the causes of pain in intervertebral disk herniation), resulting from direct mechanical compression, by chemical induction of nociceptors, and loss of normal blood supply. Direct compression on the dorsal root ganglion, meninges, vertebral ligaments, or some combination of these can lead to inflammation via release of phospholipase A and inflammatory cytokines and increased pathologic pain because of release of substance P.<sup>21</sup>

The underlying pathophysiology of spontaneous extradural bleeding remains unknown. Many hypotheses have been proposed: increased blood pressure spikes associated with coughing or straining causes increased intra-abdominal or intrathoracic pressure which increases the pressure on valveless veins in the internal vertebral plexus, axial movement of the thecal sac, and abnormal vessels.<sup>18,19</sup> Although none of the cases in this report had histopathologic evidence of extruded disk material present in the material removed surgically, it is possible that the amount of this material was so small that it was not sampled during surgery. It is likely that the underlying cause in these cases is multifactorial.

The MRI characteristics of hematoma have been well defined in the literature, but can be unreliable in

clinical practice.<sup>22–24</sup> Regardless of the time from clinical signs to imaging, the MRI appearance of the hematoma in all patients in this study was mild to moderate hyperintensity on all T2 images and isointensity or hyperintensity on the T1 images. Isointensity on T1-weighted images and hyperintensity on T2-weighted images typically are seen in the hyperacute phase (<12 hours) with spinal cord hematoma on high-field MRI.<sup>22</sup> These imaging characteristics are because of fresh oxygenated blood containing oxyhemoglobin.

Hyperintensity on T1-weighted and T2-weighted images can be seen in the late subacute (1–2 weeks) spinal cord hematoma on high-field MRI.<sup>22</sup> This is because of the proton-electron and dipolar-dipolar electron relaxation enhancement of extracellular methemoglobin causing mild shortening of the T1 and T2 relaxation times after lysis of red blood cells. Two patients in this study had extraparenchymal hematomas showing both T1- and T2-weighted hyperintensity characteristics. One of these patients had MRI performed during the late subacute time period (ie, showed clinical signs of disease 9 days before MRI), whereas the other patient showed clinical signs 4 days before MRI. This would be characterized as an early subacute time period (3–7 days). Typically, the MRI appearance of intraspinal hematoma during the early subacute time period is characterized by T2-weighted hypointensity and T1-weighted hyperintensity because of the oxidation of deoxyhemoglobin to methemoglobin causing a T1 shortening and intracellular methemoglobin causing a shortening of T2.<sup>22</sup>

Unlike the pattern of temporal hemorrhage degradation seen with intracranial hemorrhage, the pattern of extraparenchymal spinal cord hemorrhage does not appear to follow the same timeline.<sup>3,23,24</sup> Signal intensity characteristics of hematomas are dependent on many factors, which can include patient age, time, size of lesion, location of the lesion, hemoglobin oxidation state of the hematoma, clot matrix formation, degree of clot retraction, edema surrounding the hematoma, tissue pH, and hematocrit of the patient.<sup>25,26</sup> Mixed signal intensities can be seen in extraparenchymal hematomas because of continued bleeding. These factors likely account for the variability seen with our patients and can cause difficulty in the ability to accurately determine the age of the hemorrhage.

In human medicine, the management of extradural and intradural hematomas is a neurosurgical emergency. The prognosis for recovery depends on the severity of the neurologic deficit before surgery. There is controversy in the human literature regarding the time of removal of the hematoma related to outcome. In 1 study, rapidly evacuated hematomas had a good prognosis,<sup>18,27</sup> whereas other studies indicate there is no correlation between time to surgery and outcome.<sup>19,20</sup>

In a recent review of conservative management of spontaneous spinal cord hematomas in people, the severity of the neurologic deficit and clinical course directed the decision to pursue conservative treatment.<sup>28</sup> However, no factors were found to guide the



treatment plan toward conservative management. It is uncertain if any of our cases would have had similar outcomes with conservative management rather than surgery. Based on our cohort of patients, there appears to be functional neurologic improvement postoperatively with complete surgical removal of the compressive hemorrhagic material.

In our study, 1 patient showed functional neurologic worsening postoperatively. This patient was paraplegic with intact sensation and the dog's clinical condition worsened to absence of perception of noxious stimulus. Because of the single patient with a poor outcome, we are unable to correlate any specific risk factors relating to the outcome in this patient compared to the other patients. However, this patient had the worst preoperative neurologic grade (Modified Frankel Score Grade 2) of all of the patients in this study, and all of the hemorrhagic material could not be removed surgically, which may have contributed to the poor outcome.

This study had several limitations, because of the retrospective design. We did not have coagulation profiles in all patients to confirm that there was no evidence of an underlying clotting disturbance. However, all patients had normal platelet counts and no gross clotting abnormalities were observed in surgery. In addition, no patients developed any coagulopathies or had neoplasia that could account for the hemorrhage.

We reviewed the medical records for each patient, obtained the preoperative and postoperative neurologic examination findings for each patient, and assigned the Modified Frankel Score (MFS). Because this was a retrospective study and there is no definitive distinction in differentiating between superficial and deep pain sensation,<sup>29</sup> we used a scoring system that defines a score of 1 as plegic with an absence of nociceptive function rather than differentiating between deep pain and superficial nociceptive sensation.

The MFS is a simple scoring system. Using the 14-point motor score (which evaluates gait and weight-bearing ability) or using the Texas Spinal Cord Injury Scale (which analyses complex gait and uses a 10-grade scale) may have been more accurate in evaluation of functional differences preoperatively rather than postoperatively in this patient population.<sup>30,31</sup> However, the neurologic examination in the medical records was not detailed enough to use these more complex functional scoring systems in the majority of cases. This corresponds to findings in several studies. One study has validated the use of the MFS with high interrater agreement.<sup>31</sup> Another study showed that the simpler MFS appears more appropriate for retrospective studies, in which prospectively derived examination information is not available.<sup>32</sup>

In addition, because of the retrospective nature of this study, we were unable to perform additional MRI sequences, which may have helped elucidate that the extraparenchymal material was consistent with hemorrhage. The lack of imaging that enhances the ability to determine hemorrhage (such as T2\*) or MR angiography was a substantial limitation that could not be

addressed because of the retrospective nature of this study. The T2\* sequence is commonly used in brain imaging and we recommend use of this sequence when imaging the spinal cord in cases where hematoma or vascular abnormalities are suspected.

Similar to the situation in humans, the prevalence of spontaneous extraparenchymal spinal cord hematoma appears to be rare. With increased use of MRI in spinal cord cases, the frequency of hematomas has increased.<sup>14</sup> The MRI characteristics seen in all of the dogs in this retrospective study showed mild to moderate hyperintensity on all T2 images and isointensity or hyperintensity on the T1 images. These signal characteristics also are found in patients with other disease processes (eg, neoplasia, inflammatory disease). Therefore, the prevalence of this clinical syndrome may be underestimated in veterinary medicine if postmortem examination or surgery is not performed.

In summary, hematoma should be considered as a differential in patients with extradural or intradural material with variable contrast enhancement, mild to strong T2-weighted signal intensity, and mildly hyperintense or isointense signal on pre-T1-weighted contrast images. In addition, surgical decompression of extraparenchymal hematoma appears to have a favorable outcome in the majority of patients, especially if the material is easily removed and not adhered to the spinal cord and the patient has a preoperative MFS neurologic grade of 3 (paresis) or more.

---

## Footnotes

<sup>a</sup> Signa HDe 1.0 GE Genesis Signa, Waukesha, WI

<sup>b</sup> Optima GE 1.5T, Waukesha, WI

<sup>c</sup> Optimark; Tyco Healthcare St. Louis, MO

<sup>d</sup> Magnevist; Bayer Healthcare Pharmaceuticals, Wayne, NJ

---

## Acknowledgment

*Conflict of Interest Declaration:* The authors disclose no conflict of interest.

*Off-label Antimicrobial Declaration:* The authors declare no off-label use of antimicrobials.

## References

1. Cerda-Gonzalez S, Olby NJ. Fecal incontinence associated with epidural spinal hematoma and intervertebral disk extrusion in a dog. *J Am Vet Med Assoc* 2006;228:230–235.
2. Chang Y, Dennis R, Platt SR, Penderis J. Magnetic resonance imaging of traumatic intervertebral disc extrusion in dogs. *Vet Rec* 2007;160:795–799.
3. Mateo I, Lorenzo V, Foradada L, Munoz A. Clinical, pathologic, and magnetic resonance imaging characteristics of canine disc extrusion accompanied by epidural hemorrhage or inflammation. *Vet Radiol Ultrasound* 2011;52:17–24.
4. Suran JN, Durham A, Mai W, Seiler GS. Contrast enhancement of extradural compressive material on magnetic resonance imaging. *Vet Radiol Ultrasound* 2011;52:10–16.

5. Tartarelli CL, Baroni M, Borghi M. Thoracolumbar disc extrusion associated with extensive epidural haemorrhage: A retrospective study of 23 dogs. *J Small Anim Pract* 2005;46:485–490.
6. Tidwell AS, Specht A, Blaeser L, Kent M. Magnetic resonance imaging features of extradural hematomas associated with intervertebral disc herniation in a dog. *Vet Radiol Ultrasound* 2002;43:319–324.
7. Applewhite AA, Wilkens BE, McDonald DE, et al. Potential central nervous system complications of Von Willebrand's Disease. *J Am Anim Hosp Assoc* 1999;35:423–429.
8. Ong RKC, Lenard ZM, Swindells KL, Rasisis AL. Extradural haematoma secondary to brown snake (*Pseudonaja* species) envenomation. *Aust Vet J* 2009;87:152–156.
9. Thompson MS, Kreeger JM. Acute paraplegia in a puppy with hemophilia A. *J Am Anim Hosp Assoc* 1999;35:36–37.
10. Rao D, Rylander H, Drees R, et al. Granular cell tumor in a lumbar spinal nerve of a dog. *J Vet Diagn Invest* 2010;22:638–642.
11. De La Fuente C, Pumarola M, Anor S. Imaging diagnosis—Spinal epidural hemangiosarcoma in a dog. *Vet Radiol Ultrasound* 2014;55:424–427.
12. Olby N. The pathogenesis and treatment of acute spinal cord injuries in dogs. *Vet Clin Small Anim* 2010;40:791–807.
13. Downes CJ, Gemmill TJ, Gibbons SE, McKee WM. Hemilaminectomy and vertebral stabilization for the treatment of thoracolumbar disc protrusion in 28 dogs. *J Small Anim Pract* 2009;50:525–535.
14. Kreppel D, Antoniadis G, Seeling W. Spinal hematoma: A literature survey with meta-analysis of 613 patients. *Neurosurg Rev* 2003;26:1–49.
15. Gutierrez-Quintana R, Haley A, Penderis J. What is your diagnosis? *J Am Vet Med Assoc* 2013;242:1345–1346.
16. Levine JM, Levine GJ, Kerwin SC, et al. Association between various physical factors and acute thoracolumbar intervertebral disk extrusion or protrusion in Dachshunds. *J Am Vet Med Assoc* 2006;229:370–375.
17. Karpova A, Sorin C, Soo-Yong C, et al. Accuracy and reliability of MRI quantitative measurements to assess spinal cord compression in cervical spondylotic myelopathy: A prospective study. *Evid Based Spine Care J* 2010;1:56–57.
18. Langmayr JJ, Ortler M, Dessl A, et al. Management of spontaneous extramedullary spinal haematomas: Results in eight patients after MRI diagnosis and surgical decompression. *J Neurol Neurosurg Psychiatry* 1995;59:442–447.
19. Tewari MK, Tripathi LN, Mathuriya SN, et al. Spontaneous spinal extradural hematoma in children. Report of three cases and a review of the literature. *Childs Nerv Syst* 1992;8:53–55.
20. Born W, Mohr K, Hassepass U, et al. Spinal hematoma unrelated to previous surgery: Analysis of 15 consecutive cases treated in a single institution within a 10 year period. *Spine* 2004;29:E555–E561.
21. Webb AA. Potential sources of neck and back pain in clinical conditions of dogs and cats: A review. *Vet J* 2003;165:193–213.
22. Braun P, Kazmi K, Nogues-Melendez P, et al. MRI Findings in spinal subdural and epidural hematomas. *Eur J Radiol* 2007;64:119–125.
23. Fukui MB, Swarmkar AS, Williams RL. Acute spontaneous spinal epidural hematomas. *AJNR Am J Neuroradiol* 1999;20:1365–1372.
24. Sklar EM, Post JM, Falcone S. MRI of acute spinal epidural hematomas. *J Comput Assist Tomogr* 1999;23:238–243.
25. Allkemper T, Tombach B, Schwindt W, et al. Acute and subacute intracerebral hemorrhages: Comparison of MR Imaging at 1.5 and 3.0 T. *Radiology* 2004;232:874–881.
26. Cakirer S, Karaarslan E, Arslan A. Spontaneously T1-hyperintense lesions of the brain on MRI: A pictorial review. *Curr Probl Diagn Radiol* 2003;32:194–217.
27. McQuirrie LG. Recovery from paraplegia caused by spontaneous spinal epidural haematoma. *Neurology* 1978;28:224.
28. Groen RJ. Non-operative treatment of spontaneous spinal epidural hematoma: A review of the literature and a comparison with operative cases. *Acta Neurochir (Wien)* 2004;146:103–110.
29. Delahunta A, Glass E, eds. *Veterinary Neuroanatomy and Clinical Neurology*, 3rd ed. Philadelphia, PA: WB Saunders; 2009.
30. Olby NJ, De Risio L, Munana KR, et al. Development of a functional scoring system in dogs with acute spinal cord injuries. *Am J Vet Res* 2001;62:1624–1628.
31. Levine GJ, Levine JM, Budke CM, et al. Description and repeatability of a newly developed spinal cord scale for dogs. *Prev Vet Med* 2009;89:121–127.
32. Van Wie EY, Fosgate JM, Mankin JM, et al. Prospectively recorded versus medical record-derived spinal cord injury scores in dogs with intervertebral disc disease. *J Vet Intern Med* 2013;27:1273–1277.

## Supporting Information

Additional Supporting Information may be found in the online version of this article:

**Table S1.** Patient description, neurologic grade (pre and post) and MRI characteristics.