

Tricuspid valve endocarditis in pregnancy: a case report and review of the literature

Robert Libera^a, Kyle Macaulay^b, Anthony A. Donato ^b, Jared Green^c and Christine McCarty

^aInternal Medicine, Philadelphia College of Osteopathic Medicine, Philadelphia, PA, USA; ^bDepartment of Internal Medicine, Reading Hospital, Reading, PA, USA; ^cDepartment of Cardiology, Reading Hospital, Reading, PA, USA

ABSTRACT

Infective endocarditis (IE) is a rare complication in pregnancy that is associated with significant morbidity and mortality to both mother and fetus. We present a case of a 27-year-old female at 22-weeks gestation with a history of intravenous drug abuse (IVDA) who developed methicillin sensitive *Staphylococcus aureus* tricuspid valve endocarditis with persistent bacteremia and septic emboli necessitating tricuspid valve excirpation. Four days later, worsening decompensated heart failure required cesarean section at 23w5d. Although the patient's volume status and dyspnea improved significantly, fetal demise occurred 9 days after operative delivery.

ARTICLE HISTORY

Received 4 August 2020
Accepted 13 October 2020

KEYWORDS

Infective endocarditis;
tricuspid valve; second
trimester pregnancy;
echocardiography

1. Introduction

Infective endocarditis (IE) can be a rare complication of pregnancy occurring in 1 out of 8,000 births. [1,2] While the incidence of IE in pregnancy remains low, the mortality rate is reportedly 33%. [3] In nonpregnant adults, the mortality rate is significantly lower, 18%, highlighting the importance of studying IE in pregnancy. [4] In IE, valvular endothelial injury sets the stage for platelet aggregation, fibrin mediated thrombus formation, and formation of vegetations in the setting of bacteremia[5]. Pregnancy presents with important physiologic changes, including high preload and low afterload, making valvular disease in pregnancy potentially more symptomatic[6]. Significant modulation of the immune system also occurs in pregnancy, including tolerance of fetal antigens, a decrease in cytotoxic B cells, and changes in the inflammatory environment that augment fetal growth and delivery. There is a dynamic cytokine shift throughout pregnancy resulting in increased systemic inflammation in the first and third trimesters of pregnancy, and decreased systemic inflammation in the second trimester. Modulation of the immune system in pregnancy leads to a deferential response based on both the microorganism and stage of pregnancy. [7] The study of IE in pregnancy has been difficult to study in randomized controlled trials due to heterogeneity of presentation, risk factors, and inciting microbial organisms. [3] In this report, we describe a case of tricuspid valve IE in pregnancy and offer a review of tricuspid valve IE complicating pregnancy over the last 50 years.

2. Case description

A 27-year-old female G4P2113 at 22-weeks gestation with a past medical history significant for intravenous drug abuse (IVA) and no prior complicated pregnancies presented to the emergency department with shortness of breath, fevers, and bilateral leg swelling for 2 weeks. She last used IV heroin 3 weeks prior, but denied recent travel, history of blood clots, sputum production, abdominal pain, or urinary symptoms. She denied any oral lesions or history of recent dental procedures. Presenting vitals included a blood pressure of 101/44 mmHg, heart rate 120 bpm, and temperature of 101.7°F. She was tachypneic at 24 breaths/min and saturating 98% on room air. A two-sixths holosystolic murmur was appreciated at the left lower sternal border. Pitting edema (2+) was noted in the lower extremities with no other significant skin findings. No JVD was noted. Labs were significant for a leukocytosis of 12.3 K/ μ L. Hemoglobin was 7.0 g/dL, MCV 93 fL, with LDH 181 IU/L and haptoglobin 281 mg/dL. Transabdominal ultrasound confirmed a live uterine pregnancy. Due to suspicion of bacterial endocarditis, she was started on antibiotics with intravenous vancomycin and piperacillin-tazobactam after blood cultures were drawn. Transthoracic echocardiogram (TTE) revealed a large tricuspid valve vegetation with severe tricuspid valve regurgitation. Blood cultures grew presumed *staphylococcus* species, which did not resolve after 3 days so she was transferred to another facility. When blood cultures confirmed methicillin sensitive *staphylococcus aureus*, antibiotics were narrowed to intravenous cefazolin.

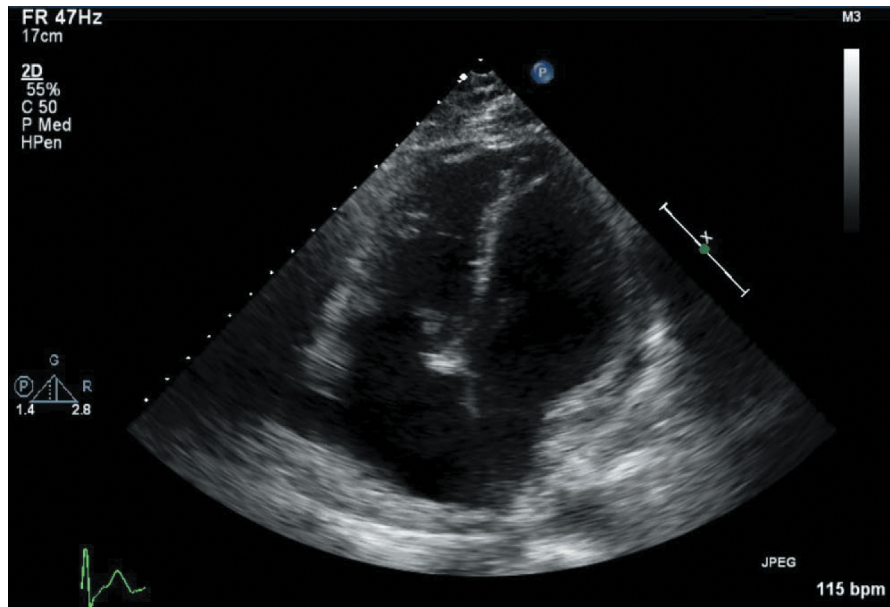


Figure 1. Tricuspid valve vegetation on transthoracic echocardiogram on hospitalization day 5.

Repeat TTE (Figure 1) was performed which demonstrated the tricuspid vegetations previously described, in addition to moderately severe tricuspid regurgitation. A large mobile vegetation seen on the anterior leaflet of the tricuspid valve measured approximately 1.6×2.3 cm. Another small 8×6 mm mobile vegetation was seen on septal leaflet of the tricuspid valve. Both vegetations affected the atrial side of the leaflets. Pulmonary artery pressure was 39 mmHg. Obstetrics, cardiothoracic surgery, cardiology, nephrology, infectious disease, and internal medicine were all consulted. Initially, a non-surgical approach was taken due to the patient's relative clinical stability and active pregnancy, which consisted of intravenous antibiotics for treatment of bacterial endocarditis.

Due to volume overload and worsening tachypnea, the patient required multiple doses of intravenous furosemide. CT chest with contrast revealed cavitory lesions in both lungs concerning for septic emboli. On day 10 of hospitalization, a transesophageal echocardiogram was performed which confirmed the large mobile mass on the tricuspid valve with no involvement of other valves or cardiac tissue. She received two doses of dexamethasone for fetal lung development.

After being afebrile for over a week, on day 12 of hospitalization she became febrile again to 102°F with worsening tachypnea and persistent bacteremia. She was taken for tricuspid valve extirpation by cardiothoracic surgery. After removal of the tricuspid valve, blood cultures cleared while on cefazolin. The day after

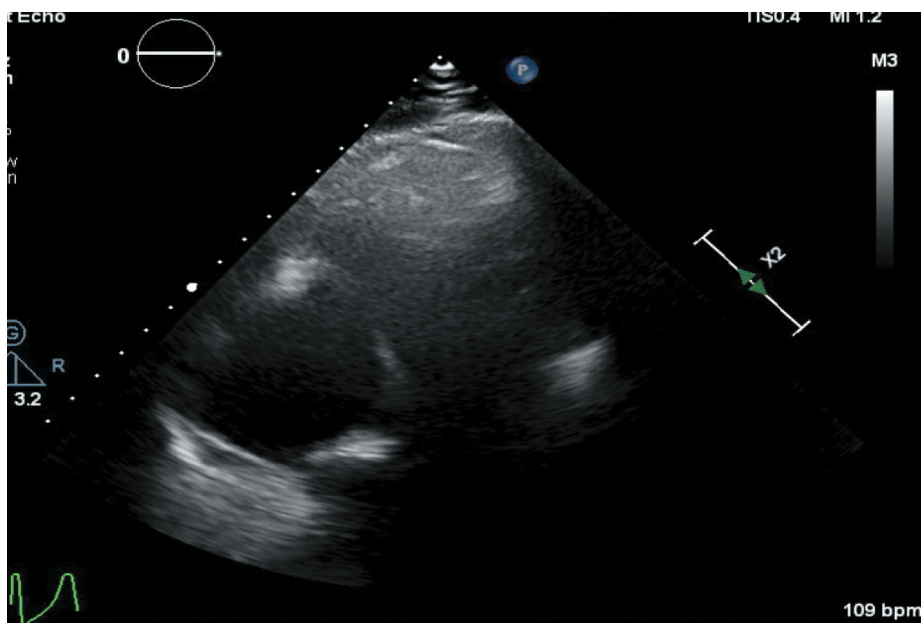


Figure 2. Transthoracic echocardiogram status post tricuspid valve extirpation on hospitalization day 15.

surgery her WBC count improved from 49,700/ μ L to 13,000/ μ L. She required some pressor support with neosynephrine and remained on furosemide infusion. On day 15, echocardiography depicted free blood flow through the valve-less right-sided chambers (Figure 2). On day 16, despite being weaned off neosynephrine, she had worsening decompensated heart failure presumably from her significant volume overloaded state prior to valve extirpation. This necessitated a cesarean section at 23w5d despite initial plans of symptomatic management until reaching the term. While the patient's volume status and dyspnea improved significantly following cesarian section, fetal demise occurred 9 days after operative delivery.

Antibiotic therapy was continued for 6 weeks after the clearance of blood cultures via a PICC line. The patient was discharged home in stable condition on day 50 with plans to follow up with cardiothoracic surgery for future replacement of her tricuspid valve dependent on her sobriety status. She was advised against becoming pregnant again until undergoing valve replacement.

3. Discussion

Case reports of IE in pregnancy are heterogenous in regard to etiology, inciting pathogens, cardiac structures affected, and stage of pregnancy at presentation. In their 2020 comprehensive review of IE, Hubers SA et al. described several special populations affected by IE; however, the authors do not discuss pregnancy as a special population. [8] In Table 1, a summary of case reports describing IE affecting the tricuspid valve in pregnancy is provided. The literature review was conducted utilizing the PubMed database with keywords 'Infective Endocarditis,' 'Pregnancy' and 'Tricuspid Valve' from 1969-present. Inclusion criteria required description of pregnancy stage, diagnosis of IE, positive blood cultures, and echocardiographic evidence of tricuspid valve vegetation(s). Only eight reports matched this criterion, highlighting the rarity of this condition and challenge facing providers managing such patients.

Our case shares some similarities with the following case reports which can be used in conjunction to aid in clinical decision making. Campuzano et al. report a 19-year-old pregnant patient at 32 weeks gestation with tricuspid IE caused by *Streptococcus viridans* who delivered a healthy infant on the third day of admission, followed by tricuspid repair several weeks later[5]. Ahres et al. report a 30-year-old female with a history of IVDA at 29 weeks gestation presented with tricuspid IE due to MSSA and *Streptococcus mitis* and underwent simultaneous tricuspid valve replacement and cesarean section on the 9th day of hospitalization[9]. Muretti et al. describe a 24-year-old female with a history of IVDA who presented at 22 weeks gestation with mitral valve IE caused by *Staphylococcus aureus*. In this case, mitral

valve replacement was performed shortly after admission and Cesarean section was delayed until 34 weeks gestation[10]. A similar report to our case was described by Quinones et al. of a 24-year-old who presented at 21 weeks gestation with IE secondary to MSSA complicated by tricuspid valve vegetations. Conservative management with intravenous ceftriaxone resolved the patient's fever, reduced the vegetation, and allowed time for successful cesarean section at term[11].

Our case report and the cases described above share key overlapping principles in management strategy. Early formation of a multidisciplinary team (MDT) is imperative for improving outcomes [9,12]. In cases of IE in preterm pregnancies, initial conservative management with narrowed intravenous antibiotics is agreed upon to allow for fetal development [3,9]. While MDTs balance maternal illness and fetal development they need to monitor for surgical indications. In IE, surgery is considered for persistent right-sided heart failure despite medical therapy, recurrent pulmonary septic emboli, septic shock, abscess formation, and failure of infection control with antimicrobial agents[13].

The indication for surgical intervention in our patient's case was failure of infection control refractory to antibiotics with evidence of septic embolization on chest CT. Prosthetic valve placement at our institution requires a 6-month period of abstinence from IVDA. Due to recent IVDA, valve replacement was contraindicated considering institutional policy and extirpation was performed. Plans for future tricuspid valve replacement were discussed with the patient.

On hospital day 16, 4 days after tricuspid valve extirpation, the patient developed right-sided heart failure. While she did not previously carry a diagnosis of pulmonary hypertension, her preoperative echocardiogram revealed a pulmonary artery pressure of 39 mmHg. We suspect underlying pulmonary hypertension precipitated the patient's right-sided heart failure in the setting of recent tricuspid valve removal. In pregnancy, cardiac output gradually increases beginning at the 12th week and peaks at the 36th week[1]. In our patient's case, the combination of underlying pulmonary hypertension and the hyperdynamic circulatory state of pregnancy caused her clinical status of volume overload. Despite fever resolution and normalization of the patient's white blood cell count following tricuspid valve extirpation, operative delivery of the fetus was indicated due to worsening heart failure.

In this case, we demonstrate an approach to the management of a 27-year-old IVDA who presented with tricuspid valve IE in the second trimester of pregnancy. Without clear guidelines on this rare pregnancy complication, we recommend early formation of a MDT, initial conservative care, and careful monitoring for acute decline indicating surgical intervention.

Table 1. Literature review of case reports describing tricuspid valve IE in pregnancy. Conducted utilizing the PubMed database with keywords 'Infective Endocarditis', 'Pregnancy', and 'Tricuspid Valve' from 1969-present. Inclusion criteria required description of pregnancy stage, diagnosis of IE, positive blood cultures, and echocardiographic evidence of tricuspid valve vegetation(s).

Patient Presentation	Etiology of IE	Bacteria	Antibiotic	Surgical Intervention	Delivery	Maternal and Fetal Outcomes
28-year-old at 26-weeks gestation ^[14]	IVDA	MSSA	Vancomycin	Tricuspid Valve replacement	CS at 28 weeks gestation	Patient and infant were successfully managed through the perioperative period.
30-year-old at 29-weeks gestation ^[9]	IVDA	MSSA	Cefazolin	Simultaneous TVR and CS.	CS at 30 weeks gestation	On the 24-month follow-up, both the mother and the baby were healthy.
19-year-old at 32-weeks gestation ^[5]	Underlying structural heart disease (VSD)	<i>Streptococcus viridans</i>	Ceftriaxone	Tricuspid Valve replacement	CS at 32 weeks and 6 days of gestation.	Patient discharged on hospital day 33 and newborn discharged on day 27 of life.
29-year-old at 17-weeks gestation ^[15]	Recent dental procedure, history of rheumatic fever.	<i>Streptococcus viridans</i>	Penicillin G	None	SVD at 36 weeks gestation	Uneventful postpartum course for mother and newborn.
24-year-old at 21-weeks gestation ^[11]	IVDA	MSSA	Nafcillin	None	CS at term	Mother and baby were doing well at the postpartum evaluation.
24-year-old at 14-weeks gestation ^[16]	IVDA	MSSA	Daptomycin	None	CS at 37 weeks and 2 days.	The mother and baby had no adverse sequelae related to the infection or daptomycin following CS.
24-year-old at 18-weeks gestation ^[17]	IVDA	<i>Enterobacter Cloacae & Enterococcus</i>	Nafcillin + Gentamicin	Tricuspid Valvectomy	SVD at 38 weeks	Uneventful delivery of healthy fetus. Patient seen five months post-op for prosthetic TV placement.
20-year-old at 32-weeks gestation ^[18]	IVDA	<i>Staphylococcus Aureus</i>	Nafcillin + Gentamicin	None	SVD at 32 weeks	Both stable at time of discharge, with plan for follow-up care.

Intra Venous Drug Abuse (IVDA), Ventral Septal Defect (VSD), Methicillin Sensitive Staphylococcus Aureus (MSSA), Spontaneous Vaginal Deliver (SVD), Tricuspid Valve replacement (TVR), Cesarean section (CS).

Disclosure statement

No potential conflict of interest was reported by the authors.

ORCID

Anthony A. Donato  <http://orcid.org/0000-0002-8294-6769>

References

- Nazarian M, McCullough G, Fielder D. Bacterial endocarditis in pregnancy successful surgical correction. *J Thorac Cardiovasc Surg.* 1976;71:880–883.
- Aoyagi A, Akasu K, Amako M, et al. Infective endocarditis during pregnancy: report of a case. *Ann Thorac Cardiovasc Surg* 2005;11:51–54.
- Kebed KY, Bishu K, Al Adham RI, et al. Pregnancy and postpartum infective endocarditis: A systematic review. *Mayo Clin Proc.* 2014;89(8):1143–1152.
- Wallace S, Walton B, Kharbanda R, et al. Mortality from infective endocarditis: clinical predictors of outcome. *Heart.* 2002;88:53–60.
- Campuzano K, Roqu H, Bolnick A, et al. Bacterial endocarditis complicating pregnancy: case report and systematic review of the literature. *Arch Gynecol Obstet* 2003;268:251–255.
- Chung E, Leinwand LA. Pregnancy as a cardiac stress model. *Cardiovasc Res.* 2014;101(4):561–570.
- Mor G, Cardenas I. The immune system in pregnancy: a unique complexity. *Am J Reprod Immunol.* 2010;63(6):425–433.
- Hubers SA, DeSimone DC, Gersh BJ, et al. Infective endocarditis: a contemporary review. *Mayo clin proc.* 2020;95(5):982–997.
- Ahres A, Rubóczy G, Somogyi P, et al. Pregnant intravenous drug user tricuspid valve infective endocarditis treated with a successful simultaneous valve replacement and cesarean section. *Echocardiography.* 2018;35:1452–1455.
- Muretti M, Torre TM, Mauri R, et al. Mitral valve replacement in pregnancy: a successful strategy for fetal survival. *J Heart Valve Dis.* 2010;19(6):789–791.
- Quiñones JN, Campbell F, Coassolo KM, et al. Tricuspid valve endocarditis during the second trimester of pregnancy. *Obstet Med.* 2010;3:78–80.
- Connolly C, O'Donoghue K, Doran H, et al. Infective endocarditis in pregnancy: case report and review of literature. *Obstet Med.* 2015;8(2):102–104.
- Yong M, Coffey S, Prendergast B, et al. Surgical management of tricuspid valve endocarditis in the current era: A review. *Int J Cardiol.* 2016;202:44–48.
- Lin D, Mullan C, Deshmukh U, et al. Drug use associated tricuspid valve infective endocarditis in pregnancy. *J Card Surg.* 2020;35:2392–2395.
- Felice P, Salom I, Levine R. Bivalvular endocarditis complicating pregnancy a case report and literature review. *Angiology* 1995; 46:441–444.
- Stroup J, Wagner J, Badzinski T. Use of daptomycin in a pregnant patient with *Staphylococcus aureus* endocarditis. *Ann Pharmacother.* 2010;44:746–749.
- Schondelmeyer R, Sunderrajan E, Atay A, et al. Successful tricuspid valvectomy without replacement for endocarditis during pregnancy. *Am Heart J.* 1986;112(4):859–861.
- Collins J, Gomes G, Brown J, et al. Infective endocarditis presenting with a pneumothorax in a patient 32 weeks pregnant. 1985;137(5):60–63. *J La State Med Soc.*