

Advantages and Disadvantages of Multi-axis Intraoperative Angiography Unit for Percutaneous Pedicle Screw Placement in the Lumbar Spine

Hiroto KAGEYAMA,¹ Shinichi YOSHIMURA,¹ Kazutaka UCHIDA,¹ and Tomoko IIDA¹

¹Department of Neurosurgery, Hyogo College of Medicine, Nishinomiya, Hyogo, Japan

Abstract

We analyzed clinical usefulness of the high resolution imaging system in a hybrid operation room (OR) for posterior lumbar interbody fusion. A total of 17 patients with lumbar spondylolisthesis between February 2014 and August 2016 were included. Multi-axis imaging system in a hybrid OR was used in 12 patients (hybrid OR group); the conventional C-arm fluoroscopy, in 5 patients (C-arm group). The time to confirm the first percutaneous pedicle screw (PPS) angle (hybrid OR, 80 vs C-arm, 249 s; $P = 0.0026$) and the second to the last PPS angle (77 vs 90 s; $P = 0.040$) were shorter in the hybrid OR group. Placement accuracy was higher in the hybrid OR group (88.0 vs 59.1%; $P = 0.010$). Irradiation dose was significantly lower in the C-arm group (462 vs 102 mGy; $P = 0.0013$). This study suggested that the accuracy of PPS placement and time to confirm the PPS angle are the advantages in a hybrid OR.

Key words: percutaneous pedicle screw, lumbar spine, hybrid operation room, fluoroscopy, multi-axis angiography unit

Introduction

Posterior lumbar interbody fusion (PLIF) using percutaneous pedicle screws (PPSs) is widely implemented because it is simple and minimally invasive, and has become a standard procedure.^{1,2)} PPSs are usually inserted using a mobile fluoroscope, such as a C-arm. Recently, surgical support devices used when inserting pedicle screws have been undergoing rapid development, and performing more accurate and minimally invasive surgery has become possible by (i) combining a navigation system with a mobile fluoroscope that can acquire three-dimensional images, such as the Arcadis Orbic Isocentric C-arm (Siemens Healthcare, Germany)^{3,4)} or the O-arm (Medtronic, USA),^{5–7)} or (ii) combining a navigation system with a Computed tomography (CT) device^{8,9)} or the mobile CT device Airo (Brainlab AG, Germany).¹⁰⁾ In this study, we used a hybrid operating room (OR) equipped with a multi-axis angiography unit (Artis Zeego, Siemens Healthcare, Germany), which is capable of obtaining high-quality intraoperative fluoroscopic images over a

broad area and can capture CT-like images. Moreover, fluoroscopy operations were also facilitated by storing set angles and positions. However, several issues, including intraoperative radiation exposure, surgical maneuver limitations, and standing position of the operator due to the size of the panel and arm, exist. Here, we employed a hybrid OR equipped with a multi-axis angiography unit in 12 patients who underwent PLIF, and 5 patients received conventional treatment using a C-arm. We investigated the clinical benefits and shortcomings of each approach.

Materials and Methods

We initiated this study approximately 1 year after the introduction of a multi-axis angiography unit in our hybrid OR. We conducted a retrospective study of 17 patients who underwent PLIF using PPSs for lumbar spondylolisthesis from February 2014 to August 2016. Twelve patients received treatment in the hybrid OR using the multi-axis angiography unit (Artis Zeego, VC21-B, Siemens Healthcare, Germany) (hybrid OR group), and five patients were treated using the conventional C-arm (Veradius Unity, release 1-1, Philips, Netherlands) (C-arm group). We performed a retrospective investigation of the surgical technique of each group at our facility by measuring the time

Received March 2, 2017; Accepted June 22, 2017

Copyright© 2017 by The Japan Neurosurgical Society
This work is licensed under a Creative Commons Attribution-NonCommercial-NoDerivatives International License.

elapsed, radiation exposure time, radiation dose, JOA (Japanese Orthopedic Association) score for recovery, PPS accuracy, and actual number of vertebrae visible within the imaging range.

Surgical technique

All surgeries were performed by one surgeon. Posterolateral fusion was performed using PPSs (CDH SOLERA SEXTAN or CDH SOLERA VOYAGER, Medtronic, Minneapolis, MN, USA) after interbody fusion. The fluoroscopic device was operated by a radiology technician in the hybrid OR group and by a physician in the C-arm group. Fluoroscopic operations for both groups were, as much as possible, performed with the anteroposterior orientation, rotational angle, and left-right balance of the vertebral arch pedicles, taking into consideration the fluoroscopic angle.¹¹⁾ The operation was performed with the patient in the prone position (Fig. 1). The median PLIF and paramedian PPS incisions were determined fluoroscopically in both groups. Moreover, in the hybrid OR group, storing the

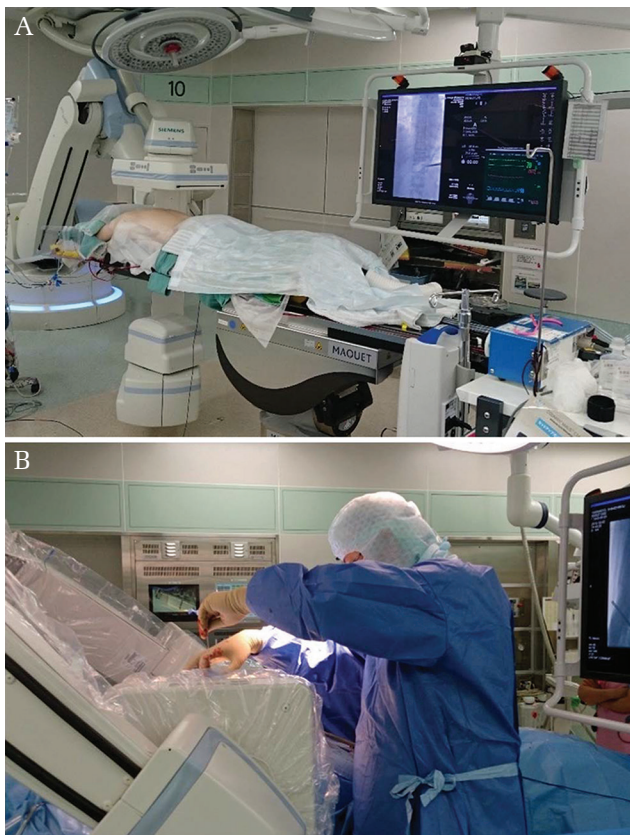

Fig. 1 Intraoperative photography. (A) Hybrid operating room (OR) with a multi-axis angiography unit (Artis Zeego, Siemens, Germany) and a large monitor. The patient is placed in prone position on the full carbon table. (B) Flat panel detector limiting the surgeon's positioning and interfering the procedure.

fluoroscopy angle and the position to insert each ideal PPS was possible. The approach was made using a spinous process longitudinal splitting method,¹²⁾ and the surgical level was confirmed intraoperatively. Laminectomy, facetectomy and interbody fusion were performed. Subsequently, PPSs were installed. The skin incision for PPS was performed and a Jamshidi needle was inserted under frontal fluoroscopy. A K-wire was inserted under lateral fluoroscopy, followed by tapping and screwing (Fig. 2). Axial and sagittal images were obtained using the CT-like image in the hybrid OR group, and frontal, lateral, and oblique images were captured using fluoroscopy in the C-arm group to confirm the screw positioning (Fig. 2). The rod was fastened thereafter.

Measurement method

The time elapsed for each surgical technique was measured and recorded. Measurement 1 was the time from body position adjustment until surgical level confirmation using lateral fluoroscopy (preoperative confirmation of spinal level) was possible, while measurement 2 was the time immediately after median incision determination until the setting of the PPS incision lines was complete (skin incision for PPS). Measurement 3 was the time from the start of the fluoroscopic operation until interspinous process confirmation (intraoperative confirmation of spinal level), while measurement 4 was the time from the start of the skin incision until the end of intervertebral fusion (skin incision to interbody fusion). Measurement 5 was the time from the start of moving the fluoroscope during the PPS procedure until the insertion angle for the first screw had been determined (confirmation of the first screw angle), measurement 6 was the time from the change in fluoroscope angle for the insertion of the second and subsequent screws until the determination of the insertion angle (confirmation of the second to the last screw angles), and measurement 7 was the time from K-wire insertion until the completion of screwing (K-wire insertion and screwing). Measurement 8 was the time from the start until the completion of rod fastening (fastening rod), and measurement 9 was the time from the start of the median incision until the completion of final suturing (total operation time). The total operation time was obtained from patients' records. Duration of each operative manipulation was routinely measured by paramedical staff in the operation room who were familiar with operational procedures.

Evaluation of screw position

Screw accuracy was evaluated in both groups using postoperative CT imaging with axial, sagittal and

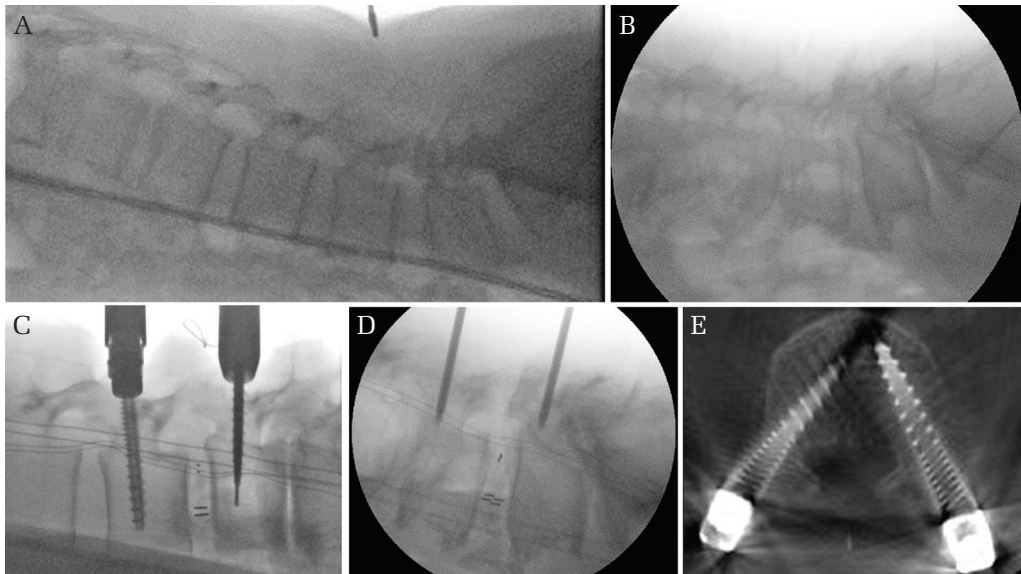


Fig. 2 Intraoperative imaging. (A, B) Fluoroscopic image with a multi-axis angiography unit (A) and C-arm (B). These figures show that a larger field of view and higher image quality are obtained in a multi-axis angiography unit. Seven or more lumbar and sacral vertebrae can be viewed on the monitor of a multi-axis angiography unit in a hybrid OR. (C, D) Percutaneous pedicle screw (PPS) with a multi-axis unit in a hybrid OR (C) and C-arm (D). The tips of the guide wire can be seen clearly with a multi-axis angiography unit. (E) The resolution of a CT-like image using a hybrid OR is sufficient to judge the deviation of screws. Intraoperative CT-like image is not available with the C-arm.

coronal view. Based on the report of Neo et al.,¹³⁾ screw accuracy was evaluated as follows: Grade 0 = no deviation (perfectly within the pedicle), Grade 1 = deviation <2 mm (violation the cortex less than 2 mm), Grade 2 = deviation >2 mm but <4 mm (violation the cortex 2–4 mm), and Grade 3 = deviation >4 mm (violation the cortex more than 4 mm). In our study, Grade 0 was considered accurate; Grades 1–3, inaccurate.

Data extraction

The time elapsed for each surgical procedure, radiation dose, radiation exposure time, JOA score for recovery, PPS accuracy, and number of vertebrae that could be imaged were compared between the two groups.

Statistical analysis

The Wilcoxon / Kruskal-Wallis test was used for comparison between the two groups and Fisher's exact test was used for PPS accuracy, and the significance threshold was $P < 0.05$. The statistical software JMP Pro 11 (SAS Institute, USA) was used for the analysis.

Results

No significant differences between the groups in any of the demographic or baseline characteristics were

observed (Table 1). For the time of each surgical procedure, measurement 5 was significantly shorter in the hybrid OR group (hybrid OR, 80 vs C-arm, 249 s; $P = 0.0026$). Measurement 6 was also significantly shorter in the hybrid OR group (77 vs 90 s; $P = 0.040$). No difference between the groups in measurements 1, 2, 3, 4, 7, 8, and 9 was noted (Table 2). Although no difference in irradiation time was found, irradiation dose was significantly lower in the C-arm group (462 vs 102 mGy; $P = 0.0052$) (Table 3). Moreover, when the 12 patients in the hybrid OR group were divided into two groups, i.e., six early cases and six late cases, the median irradiation time was significantly shorter in the later cases (138 s (76, 371)) than in the early cases (950 s (593, 1262)) ($P = 0.0051$), and the median irradiation dose was significantly lower in the later cases (441 mGy (284, 484)) than in the early cases (578 mGy (433, 761)) ($P = 0.031$) (Fig. 3).

In the hybrid OR group, 44 screws were categorized into Grade 0 and 6 in Grade 1. In the C-arm group, 13 screws were categorized into Grade 0, 7 in Grade 1, and 1 in each of Grades 2 and 3. Since we defined only Grade 0 as being accurate in this study, the resulting PPS accuracy was significantly higher in the hybrid OR group (88 vs 59%; $P = 0.010$). The median number of vertebrae that could be visualized fluoroscopically

Table 1 Patient demographics

	Hybrid OR group (<i>n</i> = 12)	C-arm group (<i>n</i> = 5)	<i>P</i> value
Men, <i>n</i> (%)	3 (25)	3 (60)	0.17
Age-yr, median (IQR)	68.0 (63.5, 69.8)	70.0 (54.0, 70.5)	0.87
BMI (kg/m ²), median (IQR)	23.3 (21.8, 26.5)	26.0 (24.3, 28.5)	0.20
Preoperative JOA score median (IQR)	18 (14, 21)	20 (17, 24)	0.26
Height of OP field (cm) median (IQR)	35 (34, 37)	41 (33, 47)	0.26

BMI: body mass index, IQR: interquartile range, JOA: Japanese Orthopedic Association.

Table 2 Duration of each operative manipulation

Measurement number	Operative manipulation	Hybrid OR group	C-arm group	<i>P</i> value
1	Preoperative confirmation of spinal level (s), median (IQR)	410 (182, 670)	239 (154, 246)	0.56
2	Skin incision for PPS (s), median (IQR)	279 (233, 359)	254 (212, 367)	0.56
3	Intraoperative confirmation of spinal level (s), median (IQR)	208 (126, 260)	137 (129, 182)	0.25
4	Skin incision to interbody fusion (min) median (IQR)	203 (173, 220)	182 (168, 318)	1.0
5	Confirmation of the first screw angle (s) median (IQR)	80 (69, 113)	249 (185, 327)	0.0026
6	Confirmation of the second to the last screw angle (s), median (IQR)	77 (53, 87)	90 (83, 224)	0.040
7	Inserting K-wire and screwing (s) median (IQR)	141 (114, 195)	128 (73, 298)	1.0
8	Fastening rod (s), median (IQR)	686 (578, 1128)	766 (592, 1530)	0.60
9	Total operation time (min), median (IQR)	355 (324, 401)	389 (313, 583)	0.11

PPS, percutaneous pedicle screw.

Table 3 Irradiation and clinical result between two groups

	Hybrid OR group	C-arm group	<i>P</i> value
Irradiation time (s), median (IQR)	495 (115, 1065)	570 (362, 802)	0.83
Irradiation dose (mGy), median (IQR)	462 (432, 612)	102 (78, 274)	0.0052
Recovery rate of JOA score (%), median (IQR)	63 (47, 75)	56 (49, 72)	0.63
Accuracy rate of PPS (%) (perfectly within the pedicle or not)	88.0	59.1	0.010

was significantly greater in the hybrid OR group (7 (6, 7) and 5 (4.5, 5) in the C-arm group; *P* = 0.012) (Figs. 2 and 4).

Discussion

In this study, we performed a retrospective evaluation of 17 cases of PLIF performed at our facility using a hybrid OR equipped with a multi-axis angiography unit or using the conventional C-arm by comparing the time elapsed for each surgical procedure,

radiation dose, radiation exposure time, PPS accuracy, and JOA score for recovery. For the time elapsed of each surgical procedure, the hybrid OR group had a significant reduction in the time to confirm the first screw angle and the second to the last screw angles. PPS accuracy was also significantly higher in the hybrid OR group. Although no difference in radiation exposure time was observed, the radiation dose was significantly less in the C-arm group. In addition, no difference between the groups in the JOA score for recovery was found.

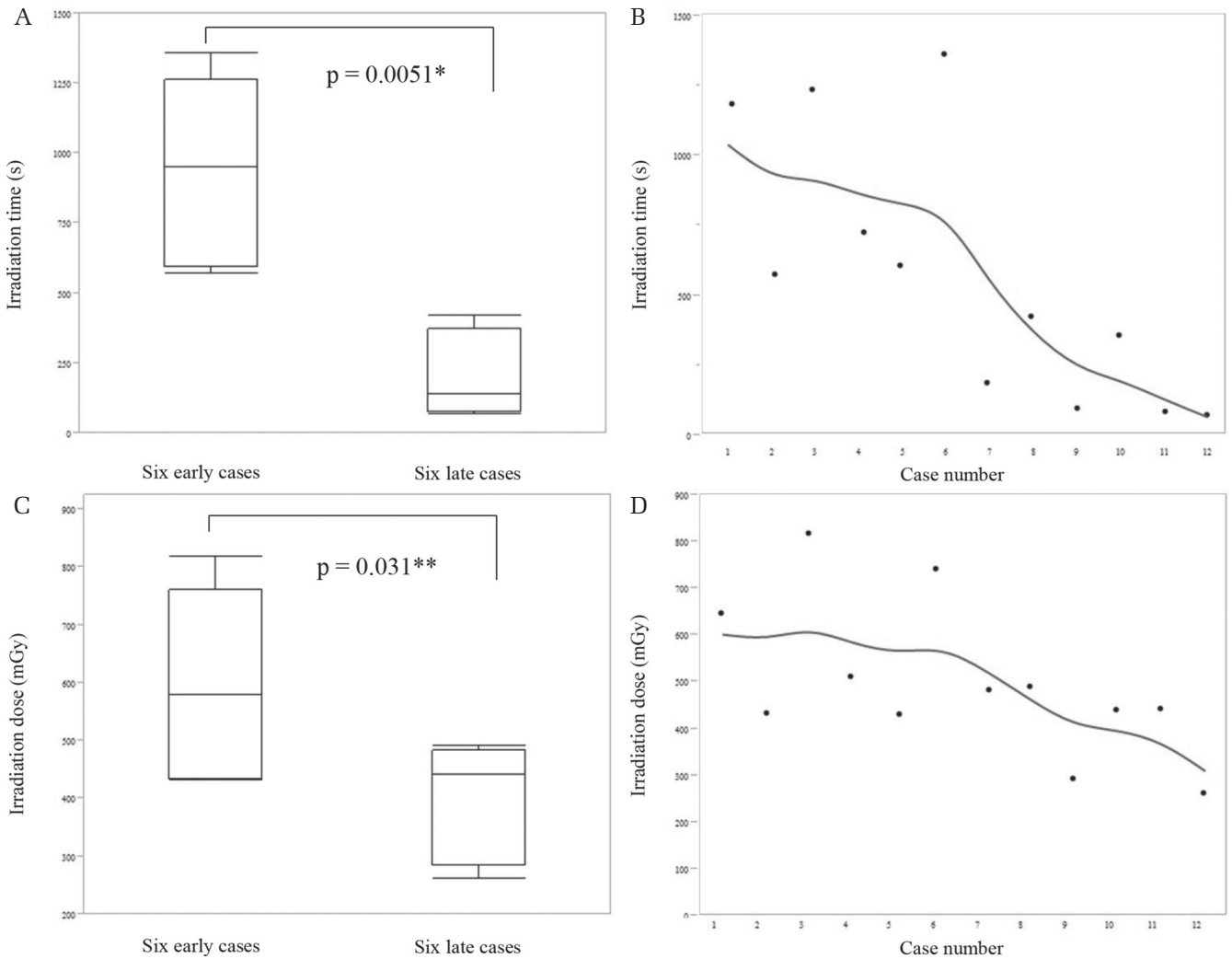


Fig. 3 Comparison of irradiation time and dose between the six early cases and six late cases in the hybrid OR group. (A, C) Irradiation time was significantly shorter and irradiation dose was significantly lower in the late than in the early cases. (B, D) Irradiation time and dose are decreasing gradually, indicating a learning curve.

Richter et al. performed surgery for orthopedic trauma using a hybrid OR combined with a navigation system and reported on its usefulness for spinal surgery and pelvic/sacral surgery because of the image quality, wide imaging range, and ability to store fluoroscopy angles and to confirm screw positioning with CT-like images.¹⁴⁾ Czerny et al. used navigation in a hybrid OR when inserting a K-wire into a vertebra of a cadaver and reported on the K-wire inserting time and accuracy.¹⁵⁾ Our study is the first to compare a multi-axis angiography unit in a hybrid OR with the conventional C-arm for spinal surgery. We found that the hybrid OR yielded clear imaging across a wide area and was able to capture 3D images, and the K-wire tip position, which was difficult to confirm using the conventional C-arm, could be clearly visualized. Consequently, the

hybrid OR group had a significantly higher screw accuracy than the C-arm group (88 vs. 59%). In addition, the screw positions could be evaluated using the CT-like image obtained in the operating room immediately after PPS insertion. By contrast, intraoperative 3D imaging is not possible with a C-arm; thus, a detailed evaluation is not possible until the surgery is completed, and the patient is transferred to a CT room for imaging after awakening from anesthesia. This process resulted in one case where PPS replacement surgery was required. The screws were accurately inserted in the hybrid OR group, and none of the patients who needed re-insertion after CT-like images in the present series. Although the time and dose of irradiation could be reduced by limiting the use of CT-like image in patients at high risk for tissues associated

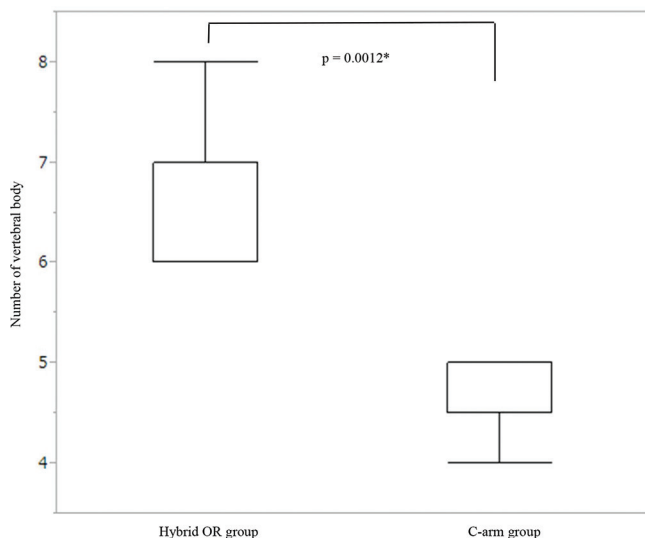


Fig. 4 The number of vertebral body that can be confirmed using a multi-axis angiography unit is significantly higher than that using the C-arm.

with screw insertion, we believed that the routine use of this imaging technique was quite useful to avoid reoperation after wound closure.

Furthermore, when we measured the time elapsed for each surgical procedure, a significant shortening in the hybrid OR group not only in the measurements of the large-scale movements of the fluoroscopic unit but also in the measurements requiring only fine adjustments to the angle was observed. Although no difference between the groups in the other measured times when the fluoroscope unit was not moved was observed, it was suggested that the ability of the hybrid OR equipped with a multi-axis angiography unit to store fluoroscopic positions and angles was useful.

Currently, C-arms that ordinarily have no 3D imaging functionality are commonly used as a surgery-assisting device for PPS insertion.¹⁾ Although C-arms capable of obtaining 3D images are now available,³⁾ their imaging range is inferior to that of the multi-axis angiography units. Moreover, reports on the use of the O-arm⁵⁾ and mobile CT¹⁶⁾ exist; however, greater interference in the surgical process than that with the C-arm or multi-axis angiography unit is involved. Thus, it is common for surgery to be performed using a navigation system based on an initially captured image. Therefore, performing procedures with real-time visualization remains challenging.

In this study, we showed that the multiaxial imaging had advantages in the accuracy of pedicle crewing over the C-arm, and, furthermore, its real-time and high resolution imaging would be a great

advantage over O-arm providing the virtual reality imaging constructed using the images obtained before.

Accuracy has been reported to be 77–85% with the conventional C-arm method, 88–96% with the CT navigation method, and 93–98% with the O-arm navigation method.^{6–8,17,18)} In these reports, Grades 0–1 and higher grades were typically considered accurate and inaccurate, respectively, because of the possibility of vascular damage and poor neurological findings. In our study, 100% of the screw placements were Grade 0 or 1 in the hybrid OR group; thus, our results were at least similar to those of reports that combine the use of a navigation system and other auxiliary diagnosis devices. Shinn et al. reported that the O-arm with navigation had a higher accuracy, however, the C-arm was faster when preparing for screw insertion and during the actual screw insertion.^{6,7)} It was suggested that the PPS insertion accuracy using a hybrid OR in our study was equivalent to that using the O-arm, and that the speed could be superior to that of the C-arm.

Producing a 3D, CT-like image during the operation is useful for PPS positioning evaluation; however, it increases the radiation dose. In our study, of the 12 patients in the hybrid OR group, the six late cases had significantly less radiation exposure time and lower radiation dose (Fig. 3), which could be attributed to a learning curve. This suggests that further improvement in exposure time is possible. Furthermore, since sufficiently evaluating screw position using the CT-like image during the operation in the hybrid OR group is possible, postoperative CT imaging where radiation dose could amount to about 380 mGy may not be required. Consequently, the total radiation dose may be unchanged or even reduced compared with that in the C-arm group. However, when a navigation system is combined with mobile CT or an O-arm, 3D CT imaging is necessary, nevertheless, subsequent X-ray-free PPS insertion⁶⁾ and confirming screw positioning immediately postoperatively are possible. Thus, concomitant navigation use would be of further use in reducing exposure dose. Therefore, performing an operation with a navigation system based on an image captured by a multi-axis angiography unit in the hybrid OR and subsequently performing intra-operative fluoroscopy as needed would be closest to the ideal setup considering accuracy and exposure reduction.

The hybrid OR equipped with a multi-axis angiography unit used in this study was originally developed for use in brain and cardiovascular surgery^{19,20)} and was eventually used in vascular operations in the field of neurosurgery because of its high image quality.²¹⁾ The flat panel detector was

40 × 50 cm, which is larger than the 28 cm diameter of the C-arm; thus, obtaining images covering a broad range was possible. The monitor was also large and easy to read. A significantly greater number of vertebrae could be visualized fluoroscopically in the hybrid OR group (Fig. 2). Confirming the surgical level and visualization of the K-wire and screw tip were extremely easy with the high image quality, and the operating table made of carbon fiber enabled easy fluoroscopy. However, the size of the apparatus limited the operator's position and posture (Fig. 1), and the mat on the operating table used for the prone position was thicker than the one commonly used, increasing the likelihood of the arm to come in contact with the patient when rotating during 3D imaging. Consequently, the surgeon, radiology technician, and operating room staff had to position the patient to avoid such contact, thereby securing a clear area. These tasks can be handled intraoperatively.

This study was a retrospective investigation performed at a single institution with a total of 17 subjects. The number of the patients was much smaller in the C-arm group, which may be due to the operator's better impression in terms of accuracy in screw placement. So, hybrid OR was used preferentially if the room was available. Therefore, our results need to be interpreted carefully. Future studies must include an investigation randomly comparing surgeries with a hybrid OR and those using only a C-arm in multiple institutions.

Conclusion

This study suggested that the accuracy of PPS placement and time to confirm the PPS angle are the advantages of lumbar spine surgery in a hybrid OR equipped with a multi-axis angiography unit. This study also showed that pedicle placement in a hybrid OR was safer than that with the conventional C-arm. The radiation dose, which was higher in the former than that in the latter, can decrease by experience.

Acknowledgement

We would like to thank Dr. Yukoh Ohara for leading us to perform percutaneous pedicle screw placement.

Conflicts of Interest Disclosure

None of the authors received financial support for this study.

Hiroto Kageyama, Shinichi Yoshimura, Kazutaka Uchida and Tomoko Iida declare that they have no conflict of interest.

References

- 1) Nakahara M, Yasuhara T, Inoue T, et al.: Accuracy of Percutaneous Pedicle Screw Insertion Technique with Conventional Dual Fluoroscopy Units and a Retrospective Comparative Study Based on Surgeon Experience. *Global Spine J* 6: 322–328, 2016
- 2) Grass R, Biewener A, Dickopf A, Rammelt S, Heineck J, Zwipp H: [Percutaneous dorsal versus open instrumentation for fractures of the thoracolumbar border. A comparative, prospective study]. *Unfallchirurg* 109: 297–305, 2006
- 3) Kluba T, Rühle T, Schulze-Bövingloh A, et al.: [Reproducibility of readings of ISO C 3D and CT lumbar pedicle screw scans]. *Rofo* 181: 477–482, 2009
- 4) Nottmeier EW, Crosby T: Timing of vertebral registration in three-dimensional, fluoroscopy-based, image-guided spinal surgery. *J Spinal Disord Tech* 22: 358–360, 2009
- 5) Xiao R, Miller JA, Sabharwal NC, et al.: 347 Clinical outcomes following spinal fusion using an intraoperative computed tomographic three-dimensional imaging system. *Neurosurgery* 63 Suppl 1: 202, 2016
- 6) Shin MH, Hur JW, Ryu KS, Park CK: Prospective Comparison Study Between the Fluoroscopy-guided and Navigation Coupled With O-arm-guided Pedicle Screw Placement in the Thoracic and Lumbosacral Spines. *J Spinal Disord Tech* 28: E347–E351, 2015
- 7) Shin MH, Ryu KS, Park CK: Accuracy and Safety in Pedicle Screw Placement in the Thoracic and Lumbar Spines: Comparison Study between Conventional C-Arm Fluoroscopy and Navigation Coupled with O-Arm® Guided Methods. *J Korean Neurosurg Soc* 52: 204–209, 2012
- 8) Shin BJ, James AR, Njoku IU, Härtl R: Pedicle screw navigation: a systematic review and meta-analysis of perforation risk for computer-navigated versus freehand insertion. *J Neurosurg Spine* 17: 113–122, 2012
- 9) Ito H, Neo M, Yoshida M, Fujibayashi S, Yoshitomi H, Nakamura T: Efficacy of computer-assisted pedicle screw insertion for cervical instability in RA patients. *Rheumatol Int* 27: 567–574, 2007
- 10) Lian X, Navarro-Ramirez R, Berlin C, et al.: Total 3D Airo® navigation for minimally invasive Transforaminal Lumbar Interbody Fusion. *Biomed Res Int* 2016: 5027340, 2016
- 11) Wiesner L, Kothe R, Rüther W: Anatomic evaluation of two different techniques for the percutaneous insertion of pedicle screws in the lumbar spine. *Spine* 24: 1599–1603, 1999
- 12) Watanabe K, Hosoya T, Shiraiishi T, Matsumoto M, Chiba K, Toyama Y: Lumbar spinous process-splitting laminectomy for lumbar canal stenosis. Technical note. *J Neurosurg Spine* 3: 405–408, 2005
- 13) Neo M, Sakamoto T, Fujibayashi S, Nakamura T: The clinical risk of vertebral artery injury from

- cervical pedicle screws inserted in degenerative vertebrae. *Spine* 30: 2800–2805, 2005
- 14) Richter PH, Yarboro S, Kraus M, Gebhard F: One year orthopedic trauma experience using an advanced interdisciplinary hybrid operating room. *Injury* 46 Suppl 4: S129–S134, 2015
 - 15) Czerny C, Eichler K, Croissant Y, et al.: Combining C-arm CT with a new remote operated positioning and guidance system for guidance of minimally invasive spine interventions. *J Neurointerv Surg* 7: 303–308, 2015
 - 16) Hecht N, Kamphuis M, Czabanka M, et al.: Accuracy and workflow of navigated spinal instrumentation with the mobile AIRO(®) CT scanner. *Eur Spine J* 25: 716–723, 2016
 - 17) Gertzbein SD, Robbins SE: Accuracy of pedicular screw placement in vivo. *Spine* 15: 11–14, 1990
 - 18) Tian NF, Huang QS, Zhou P, et al.: Pedicle screw insertion accuracy with different assisted methods: a systematic review and meta-analysis of comparative studies. *Eur Spine J* 20: 846–859, 2011
 - 19) Jongkind V, Akkersdijk GJ, Yeung KK, Wisselink W: A systematic review of endovascular treatment of extensive aortoiliac occlusive disease. *J Vasc Surg* 52: 1376–1383, 2010
 - 20) Piazza M, Ricotta JJ, Bower TC, et al.: Iliac artery stenting combined with open femoral endarterectomy is as effective as open surgical reconstruction for severe iliac and common femoral occlusive disease. *J Vasc Surg* 54: 402–411, 2011
 - 21) Iihara K, Satow T, Matsushige T, et al.: Hybrid operating room for the treatment of complex neurovascular and brachiocephalic lesions. *J Stroke Cerebrovasc Dis* 22: e277–e285, 2013

Address correspondence to: Shinichi Yoshimura, MD, PhD, Department of Neurosurgery, Hyogo College of Medicine, 1-1 Mukogawa, Nishinomiya, Hyogo 663-8501, Japan.
e-mail: s-yoshi@hyo-med.ac.jp