

Case Report

Young woman with a four-year history of epilepsy and progressive focal cortical atrophy – What is the diagnosis?



S. Pati^{a,*}, M.I. Cobos-Sillero^b, B. Buchbinder^c, E. Eskandar^d, A.J. Cole^a

^a Epilepsy Service, Massachusetts General Hospital, Boston, MA, USA

^b Neuropathology Service, Massachusetts General Hospital, Boston, MA, USA

^c Neuroradiology Service, Massachusetts General Hospital, Boston, MA, USA

^d Neurosurgery Service, Massachusetts General Hospital, Boston, MA, USA

ARTICLE INFO

Available online 20 March 2014

Keywords:

Progressive epilepsy
Neuroinflammation
Rasmussen's encephalitis
Perinatal stroke

ABSTRACT

The pathogenesis of disease progression in drug-refractory epilepsy is poorly understood. We report the case of a young woman with a four-year history of epilepsy that progressed rapidly as evidenced by the development of progressive focal cortical atrophy. She underwent biopsy that showed perinatal ischemia and a prominent inflammatory response, including T-cell infiltration and microglial activation. There was no consensus reached on the final diagnosis although the hypothesis of dual pathology (adult variant of Rasmussen's encephalitis and perinatal stroke) was considered. The possible role of inflammation in the progression of epilepsy caused by a "static" lesion (perinatal stroke) is discussed.

© 2014 The Authors. Published by Elsevier Inc. This is an open access article under the CC BY-NC-ND license (<http://creativecommons.org/licenses/by-nc-nd/3.0/>).

1. Introduction

Disease progression in drug-refractory epilepsy has been evaluated in multiple studies using serial cognitive assessments [1] and MRI volumetric analysis [2,3]. Although the pathogenesis of such changes is not fully understood, experimental [4] and clinical studies [5,6] suggest that they may be related to recurrent seizures. The duration of progression is often up to a decade before being evident as cortical atrophy on serial MRI [7]. Management is challenging as the underlying etiopathogenesis is unclear and the outcome is often suboptimal. We report a case of a young woman with focal epilepsy that progressed rapidly within four years of onset.

2. Case report

A 28-year-old, right-handed woman with a four-year history of medication-resistant epilepsy was referred for further management. Seizure semiology included auras that she described as "gradual loss of hearing, feels as if distant" followed by loss of consciousness, generalized tonic-clonic convulsions, and postictal confusion and lethargy. There was no diurnal preference for these seizures, and they were not specifically related to her sleep-wake cycle. Initially, the seizures occurring once a month steadily increased in frequency to 2–3/month.

Her birth history was unremarkable, and her development was normal. She graduated from law school and was working at a company

as a manager. Neurological examination was unremarkable. Neuropsychological testing displayed strengths in the areas of her fund of knowledge, verbal expression and fluency, information-processing speed, and executive cognitive control. Mild relative weaknesses were seen in visuospatial and perceptual skills, visual learning, left hand speed and coordination, and in concentration and working memory. Overall, the neuropsychological testing revealed a mildly lateralized cognitive profile that was suggestive of nondominant frontal lobe dysfunction.

Magnetic resonance imaging of the brain performed at the time of initial presentation showed encephalomalacia affecting the anterior and the inferior portion of the right frontal lobe, with involvement of the anterior aspect of the right middle and perifrontal gyri as well as the right orbitofrontal gyrus. There was another discrete noncontiguous focus of encephalomalacia involving the posterior right frontal operculum. The hippocampi were symmetric and normal in size and signal intensity. Subsequent serial brain MRIs performed yearly showed progressive atrophy in the right anterior quadrant that was confirmed by quantitative volumetric analysis (Figs. 1 and 2). Fluorine-18 fluorodeoxyglucose (¹⁸FDG) PET scan showed marked cortical hypometabolism in the right hemisphere, most pronounced proximal to the areas of encephalomalacia in the anterior right frontal lobe and in the right frontal operculum.

Interictal EEG recorded from scalp showed frequent intermittent focal delta slowing over the right anterior quadrant and abundant epileptiform sharp waves over the right frontotemporal region. Five electroclinical seizures recorded from the scalp began with an experiential followed by head version to left, left arm tonic extension and right arm flexion, and then tonic-clonic activity. The electrographic

* Corresponding author at: Massachusetts General Hospital, Wang ACC 739 L, Fruit Street, Boston, Massachusetts 02114. Tel.: +1 617 726 3311; fax: +1 617 726 9250.

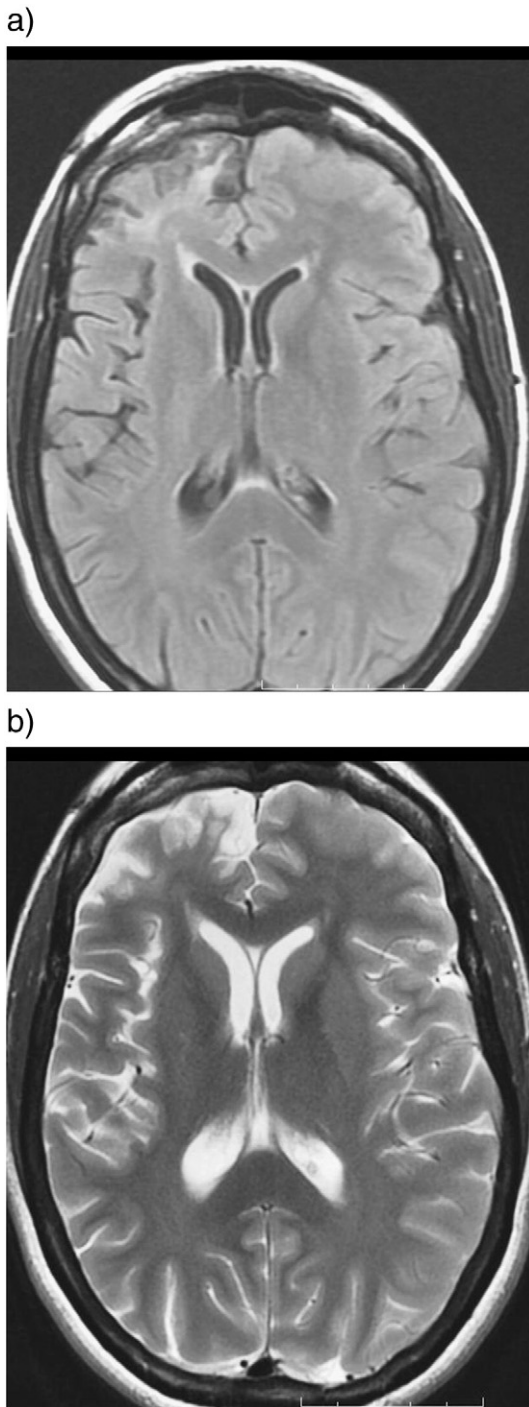


Fig. 1. (a) Brain MRI axial FLAIR and (b) T2-weighted sequence showing encephalomalacia in the anterior right frontal lobe and another discrete noncontiguous focus of encephalomalacia involving the posterior right frontal operculum.

onset preceded the clinical onset by approximately 40 s and was either over the right frontopolar (Fp2) or the right superior frontal region (F4).

Given her increased seizure frequency and resultant disability, epilepsy surgery was considered. In the epilepsy surgical conference, the discussion was focused around two key aspects: a) possible etiology of focal epilepsy and b) surgical planning. Many members of the group felt that she might benefit from a frontal polar resection. Most felt that an invasive investigation to further clarify the site of onset of her seizures would be required. Competing factors included the nature of

her warning, which might suggest early temporal involvement, and the nature of her behavior which appeared much more frontopolar. Of note, her EEG changes appeared to be maximal in the F4 and FP2 electrode positions early in the events. The question of progression of her underlying lesion as evidenced by serial MRI quantitative volumetric analysis raised the possibility of a low-grade adult-onset chronic focal Rasmussen's encephalitis. This variant of Rasmussen's encephalitis has rarely been reported in adults and has been treated with variable success using immunomodulatory drugs and focal corticectomy. Given the uncertainty in the diagnosis, the end consensus was to biopsy one of her right frontal lesions. Eventually, the patient underwent right frontopolar corticectomy.

The histopathology was quite unexpected. There were focal ulegyria, cavitory gliosis sparing the molecular layer of the cortex, and multiple foci of inflammatory cells, mainly T cells. There were no microglial nodules, but there was generalized microglial activation and, probably, proliferation. There was some perivascular cuffing. An HSV1 immunostain was negative. Overall, the histopathology was suggestive of perinatal ischemia and a prominent inflammatory response (Fig. 3). There was no consensus reached on the diagnosis of Rasmussen's encephalitis.

At the last follow-up, she continued to have seizures, albeit at a reduced frequency. Additional investigations including CSF examination, serum inflammatory markers (C-reactive protein, erythrocyte sedimentation rate), and antinuclear antibody (ANA) screen have been normal. The future plans are to repeat her brain MRI, with special attention to the cerebral volumes, and to reassess whether additional epilepsy surgery or an immunomodulatory therapy would be worthwhile.

3. Discussion

Acute symptomatic seizures are common after perinatal arterial ischemic stroke, but recurrent seizures (i.e., epilepsy) have been reported to develop in up to 67% [8,9] of patients. Incidence rates are variable and depend on the population studied, the follow-up period, and the extent of stroke. Regardless of the discrepancies between studies, it is clear that the risk of childhood epilepsy after neonatal stroke is higher with larger strokes [10]. Larger stroke also leads to long-term neurological disability, including congenital hemiplegia (hemiplegic cerebral palsy) and cognitive disorders. Term or near-term infants without any focal neurological deficits can have "silent" perinatal stroke. In an autopsy series of 592 infants, 5.4% were found to have perinatal arterial stroke, and none showed focal neurologic features during the newborn period [11]. Our patient had no identifiable risk factors for cortical insult or any focal neurological deficits that should have raised the suspicion of perinatal stroke. The right frontal encephalomalacia seen in the MRI is a nonspecific finding. Her first seizure occurred in adulthood, and, within a span of four years after onset, the epilepsy worsened as evident by progressive cortical atrophy and increased seizure frequency. This rapid progression is atypical, considering that perinatal strokes are "static" lesions. So why is there a progressive cortical atrophy? There was marked inflammation noted in the histopathology. Is this a consequence of repeated seizures, or is the inflammation contributing to the progression of the epilepsy and atrophy? Finally, biopsy was done from one of the two noncontiguous adjacent lesions. Could this be a dual pathology consisting of perinatal stroke and a focal, adult variant of Rasmussen's encephalitis?

Extensive inflammation, namely, T cells and microglial activation, were evident in histopathology. Experimental and clinical studies have demonstrated the role of neuroinflammation in establishing and maintaining seizures in focal epilepsy [12,13]. Inflammation contributes to neuronal hyperexcitability and network plasticity, can initiate seizures, and contributes to the progression of epilepsy [14]. Inflammation can also be triggered by seizures [15]. In this patient, the frequency and the temporal relation of seizures before biopsy were not documented; hence, it is difficult to infer whether the inflammation is the cause or effect following seizures. Nevertheless, inflammation as a contributory

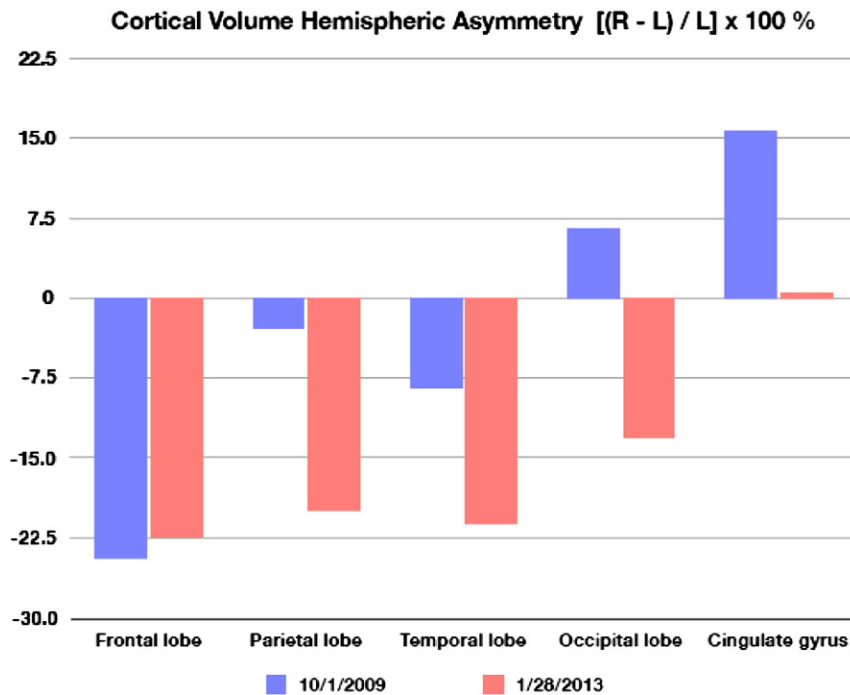


Fig. 2. Volumetric analysis of serial brain MRI showing frontal lobe asymmetry (right worse than left).

factor to the progression of an epilepsy caused by a “static” lesion remains an attractive plausible hypothesis.

Rasmussen's encephalitis is a rare but severe inflammatory brain disorder leading to unilateral hemispheric atrophy, associated progressive neurological dysfunction, and intractable seizures [16]. Even though Rasmussen's encephalitis has largely been considered a childhood disease, adolescent and adult patients have been reported by several groups [17–19]. Adults appear to have a more protracted and milder clinical course with less residual functional deficits and lower degrees of hemiatrophy but identical histopathological as well as clinical, electrophysiological, and neuroimaging findings [20]. Our patient has not developed epilepsy partialis continua, and there was no cortical deficit. Histopathology showed T-cell-dominated inflammation with activated microglia, but there were no nodules which are typically seen in Rasmussen's encephalitis [21]. Together with the MRI findings of slow progressive cortical atrophy, the case at least fulfills the proposed diagnostic criteria for Rasmussen's encephalitis [22] (Table 1, criteria b). Therefore, it is possible that we are dealing with a dual pathology: perinatal stroke and Rasmussen's encephalitis. The coexistence of Rasmussen's encephalitis with stroke has been reported [23]. In a series reported from Montreal, 10% of Rasmussen's encephalitis was associated with dual pathology including low-grade tumor, stroke, and cortical dysplasia [23].

How should we treat this patient? Antiinflammatory and immunomodulatory treatments have largely been unsuccessful in most published studies [24]. Epilepsy surgery, namely, corticectomy or electrophysiology-guided extended lesionectomy in adult-variant Rasmussen's encephalitis, has been reported with variable success [20]. The case underscores the importance of considering dual pathology in progressive disease.

References

- [1] Hermann BP, Seidenberg M, Dow C, Jones J, Rutecki P, Bhattacharya A, et al. Cognitive prognosis in chronic temporal lobe epilepsy. *Ann Neurol* 2006;60(1):80–7.
- [2] Seidenberg M, Kelly KG, Parrish J, Geary E, Dow C, Rutecki P, et al. Ipsilateral and contralateral MRI volumetric abnormalities in chronic unilateral temporal lobe epilepsy and their clinical correlates. *Epilepsia* 2005;46(3):420–30.
- [3] Helmstaedter C, Kurthen M, Lux S, Reuber M, Elger CE. Chronic epilepsy and cognition: a longitudinal study in temporal lobe epilepsy. *Ann Neurol* 2003;54:425–32.
- [4] Sanabria ER, da Silva AV, Spreafico R, Cavalheiro EA. Damage, reorganization, and abnormal neocortical hyperexcitability in the pilocarpine model of temporal lobe epilepsy. *Epilepsia* 2002;43(Suppl. 5):96–106.
- [5] Briellmann RS, Berkovic SF, Syngeniotis A, King MA, Jackson GD. Seizure-associated hippocampal volume loss: a longitudinal magnetic resonance study of temporal lobe epilepsy. *Ann Neurol* 2002;51:641–4.
- [6] Salmenpera T, Kalviainen R, Partanen K, Mervaala E, Pitkanen A. MRI volumetry of the hippocampus, amygdala, entorhinal cortex, and perirhinal cortex after status epilepticus. *Epilepsy Res* 2000;40:155–70.
- [7] Bernhardt BC, Worsley KJ, Kim H, Evans AC, Bernasconi A, Bernasconi N. Longitudinal and cross-sectional analysis of atrophy in pharmacoresistant temporal lobe epilepsy. *Neurology* 2009;72(20):1747–54.
- [8] Koelfen W, Freund M, Varnholt V. Neonatal stroke involving the middle cerebral artery in term infants: clinical presentation, EEG and imaging studies, and outcome. *Dev Med Child Neurol* 1995;37:204–12.
- [9] Golomb MR, Garg BP, Carvalho KS, Johnson CS, Williams LS. Perinatal stroke and the risk of developing childhood epilepsy. *J Pediatr* 2007;151(4):409–13.
- [10] Uvebrant P. Hemiplegic cerebral palsy. Aetiology and outcome. *Acta Paediatr Scand Suppl* 1988;345:1–100.
- [11] Barmada MA, Moossy J, Shuman RM. Cerebral infarcts with arterial occlusion in neonates. *Ann Neurol* 1979;6:495–502.
- [12] Ravizza T, Gagliardi B, Noè F, Boer K, Aronica E, Vezzani A. Innate and adaptive immunity during epileptogenesis and spontaneous seizures: evidence from experimental models and human temporal lobe epilepsy. *Neurobiol Dis* 2008;29(1):142–60.
- [13] Maroso M, Balosso S, Ravizza T, Liu J, Aronica E, Iyer AM, et al. Toll-like receptor 4 and high-mobility group box-1 are involved in ictogenesis and can be targeted to reduce seizures. *Nat Med* 2010;16(4):413–9.
- [14] Vezzani A, French J, Bartfai T, Baram TZ. The role of inflammation in epilepsy. *Nat Rev Neurol* 2011;7(1):31–40.
- [15] Librizzi L, Noè F, Vezzani A, de Curtis M, Ravizza T. Seizure-induced brain-borne inflammation sustains seizure recurrence and blood–brain barrier damage. *Ann Neurol* 2012;72(1):82–90.
- [16] Andermann F, editor. Chronic encephalitis and epilepsy. Rasmussen's syndrome. Boston: Butterworth-Heinemann; 1991.
- [17] Hart YM, Andermann F, Fish DR, Dubeau F, Robitaille Y, Rasmussen's T, et al. Chronic encephalitis and epilepsy in adults and adolescents: a variant of Rasmussen's syndrome? *Neurology* 1997;48:418–24.
- [18] Gray F, Serdaru M, Baron H, Daumas Duport C, Loron P, Sauron B, et al. Chronic localised encephalitis (Rasmussen's) in an adult with epilepsy partialis continua. *J Neurol Neurosurg Psychiatry* 1987;50:747–51.
- [19] McLachlan RS, Girvin JP, Blume WT, Reichman H. Rasmussen's chronic encephalitis in adults. *Arch Neurol* 1993;50:269–74.
- [20] Oguni H, Andermann F, Rasmussen's TB. The natural history of the syndrome of chronic encephalitis and epilepsy: a study of the MNI series of forty-eight cases. In: Andermann F, editor. Chronic encephalitis and epilepsy. Rasmussen's syndrome. Boston: Butterworth-Heinemann; 1991. p. 7–35.

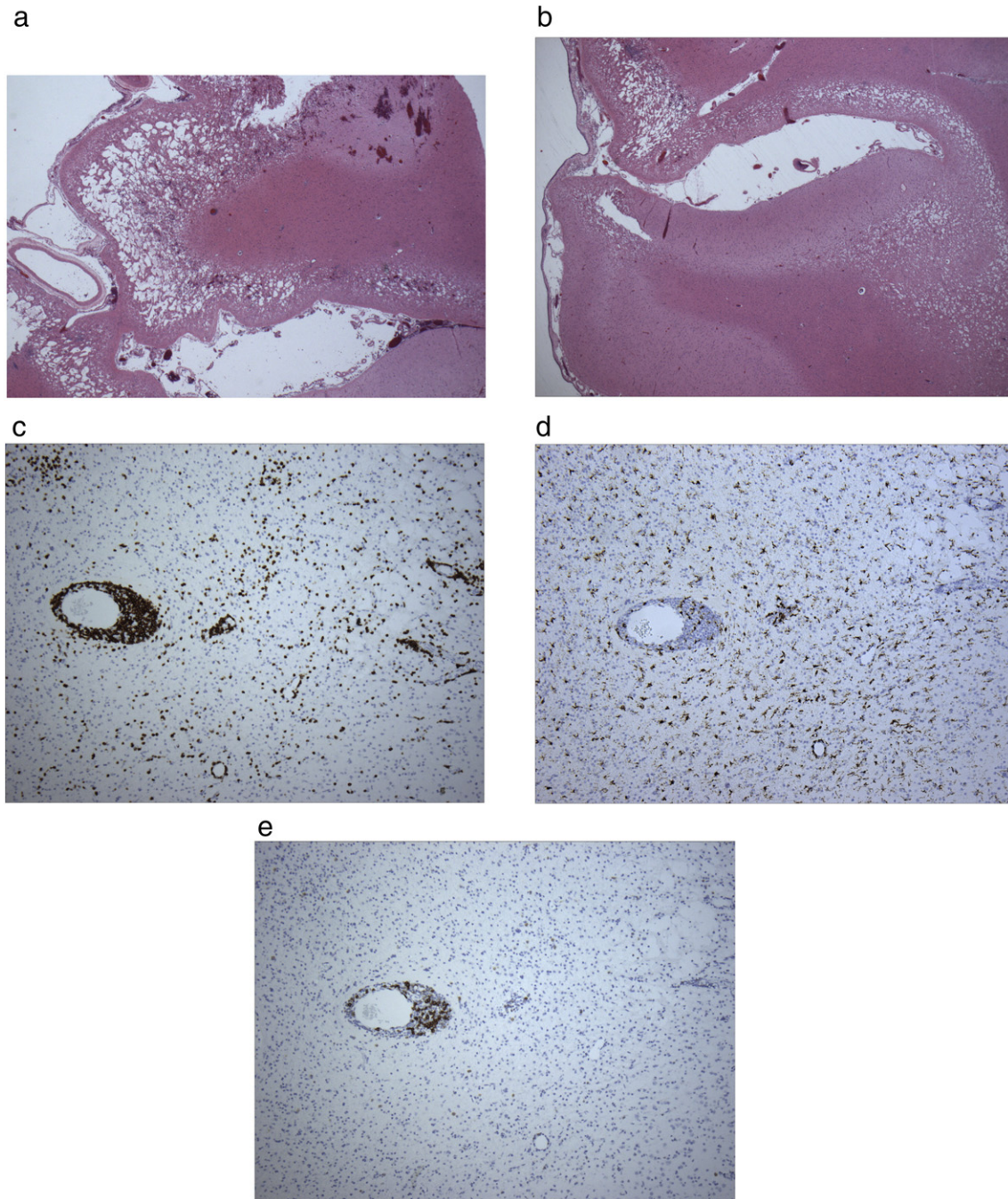


Fig. 3. Right frontal biopsy showing focal cavitory gliosis sparing the molecular layer of the cortex (a) and ulegyria (b) in H&E staining; inflammatory cells CD-3/T-cells (c), CD-68/microglia (d), and CD-20/B-cells (e).

Table 1

Diagnostic criteria of Rasmussen's encephalitis.

Adapted from Bien et al. [22].

Part A

1. Clinical – focal seizures (with or without epilepsy partialis continua) and unilateral cortical deficit(s)
2. EEG – unihemispheric slowing with or without epileptiform activity and unilateral seizure onset
3. Brain MRI – unihemispheric focal cortical atrophy and at least one of the following:
Gray or white matter T2/FLAIR hyperintense signal
Hyperintense signal or atrophy of the ipsilateral caudate head

Part B

1. Clinical – epilepsy partialis continua or progressive unilateral cortical deficit(s)
2. MRI – two sequential MRIs showing progressive unihemispheric focal cortical atrophy
3. Histopathology – T-cell-dominated encephalitis with activated microglial cells (typically, but not necessarily, forming nodules) and reactive astroglia

RE can be diagnosed if either all three criteria of Part A or two out of three criteria of Part B are present.

- [21] Bien CG, Urbach H, Deckert M, Schramm J, Wiestler OD, Lassmann H, et al. Diagnosis and staging of Rasmussen's encephalitis by serial MRI and histopathology. *Neurology* 2002;58:250–7.
- [22] Bien CG, Granata T, Antozzi C, Cross JH, Dulac O, Kurthen M, et al. Pathogenesis, diagnosis and treatment of Rasmussen's encephalitis: a European consensus statement. *Brain* 2005;128(3):454–7.
- [23] Hart YM, Andermann F, Robitaille Y, Laxer KD, Rasmussen's T, Davis R. Double pathology in Rasmussen's syndrome: a window on the etiology? *Neurology* 1998;50:731–5.
- [24] Varadkar S, Bien CG, Kruse CA, Jensen FE, Bauer J, Pardo CA, et al. Rasmussen's encephalitis: clinical features, pathobiology, and treatment advances. *Lancet Neurol* 2014;13(2):195–205.