


# Term Neonate With Liver Laceration, Obstructive Uropathy, and Ascites—Secondary to Extravasation of Total Parenteral Nutrition: A Complication of Malpositioned Umbilical Venous Catheter

Global Pediatric Health  
Volume 3: 1–6  
© The Author(s) 2016  
Reprints and permissions:  
[sagepub.com/journalsPermissions.nav](http://sagepub.com/journalsPermissions.nav)  
DOI: 10.1177/2333794X16670494  
[gph.sagepub.com](http://gph.sagepub.com)  


Olubukunola Adesanya, MD, MSPH<sup>1</sup>, and Mubariz Naqvi, MD<sup>1</sup>

## Abstract

We report a rare, but serious, complication of a malpositioned umbilical venous catheter in a term male infant who developed laceration, hematoma, and necrosis of liver, ascites, and left-sided obstructive uropathy secondary to extravasation of total parenteral nutrition. Abdominal paracentesis confirmed the presence of parenteral nutrition in the peritoneal cavity. Although, the umbilical venous catheterization is a common intravenous access used in neonatal intensive care units, judicious continued monitoring of its use should be practiced to avoid serious complications.

## Keywords

hepatic laceration, neonates, hepatic mass, umbilical vein catheter, ascites, obstructive uropathy, total parenteral nutrition

Received August 12, 2016. Accepted for publication August 16, 2016.

## Introduction

Umbilical venous catheterization is one of the most commonly utilized procedures to infuse total parenteral nutrition (TPN) in neonates who are unable to achieve enteric nutrition due to various medical and surgical reasons. Intraperitoneal extravasation of TPN has been previously reported in preterm neonates as one of the complication associated with malpositioned umbilical venous catheter (UVC), leading to vessel perforation or liver disruption as a result of hepatic necrosis.<sup>1-3</sup> Prognosis is usually good if not associated with serious liver laceration with uncontrollable hemorrhage. There is paucity of information regarding this complication in term neonates.

## Case Report

The case is about a male infant weighing 3562 grams at 39 4/7 weeks gestation, appropriate for gestational age, delivered vaginally after 11 hours of spontaneous rupture

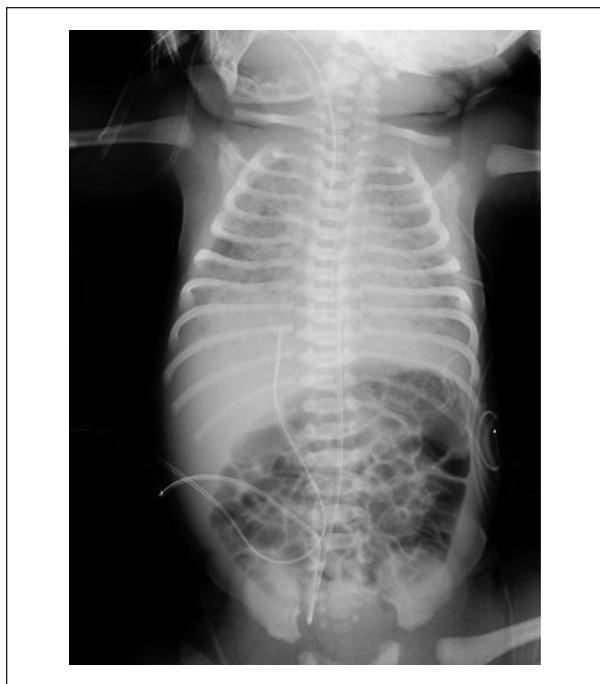of membrane to an 18-year-old Hispanic primipara woman. Pregnancy history was uneventful; prenatal labs were all negative, except for positive group B streptococcus rapid test; and herpes simplex virus (HSV) IGG antibody. No active herpes genital lesions were present at the time of infant's delivery. The mother received adequate treatment for group B streptococcus prior to the delivery of the infant. Amniotic fluid was reported to be moderately meconium stained, and the infant had perinatal asphyxia at birth with Apgar scores of 2<sup>1</sup>, 6<sup>5</sup>, and 9<sup>10</sup> at 1, 5, and 10 minutes, respectively. The infant was oral and endotracheal suctioned, given positive pressure ventilation, and later orally intubated and

<sup>1</sup>Texas Tech University Health Sciences Center, Amarillo, TX, USA

## Corresponding Author:

Olubukunola Adesanya, Department of Pediatrics, Division of Perinatal-Neonatal-Medicine, Texas Tech University Health Sciences Center 1400 S Coulter Street, Amarillo, TX 79106-1786, USA.  
Email: [olu.adesanya@ttuhsc.edu](mailto:olu.adesanya@ttuhsc.edu)



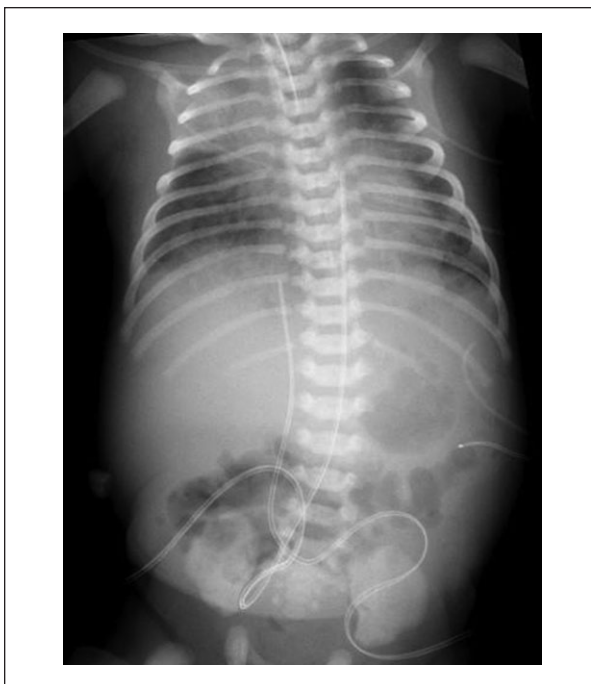

**Figure 1.** Day of life 1. Initial X-ray for line placement shows UVC tip at T9, UAC tip at T6, ET tip at T2.5, diffuse patchy lung infiltrate, and normal bowel gas pattern.

placed on mechanical ventilation. Admission diagnosis included severe respiratory distress from meconium aspiration syndrome, perinatal depression; and suspected neonatal sepsis. Management included intubation, placement on ventilator support, surfactant meconium lavage, surfactant replacement therapy, antibiotics for neonatal sepsis prophylaxis (with ampicillin and gentamicin), and placement of umbilical venous and arterial catheters.

A size 5-Fr UVC was placed at admission without complication, and the initial position was confirmed to be in the ductus venosus at the level of thoracic vertebrae-T9 (Figure 1). The infant's initial blood workup for sepsis remained negative. Respiratory status was improving on the ventilator, with hypoxia and respiratory acidosis resolving, and the infant was weaned to minimal settings, in preparation for extubation by day of life 7.

On day of life 6, liver enlargement was noted on a routine abdominal X-ray. Liver enzymes were mildly elevated, and the infant was febrile, but otherwise hemodynamically stable. A presumptive diagnosis of disseminated neonatal HSV infection was entertained, due to past history of HSV in the mother prior to pregnancy, and IGG HSV positive in this pregnancy. The infant was started on Acyclovir, pending HSV polymerase chain reaction results, and blood culture and blood cell parameters were



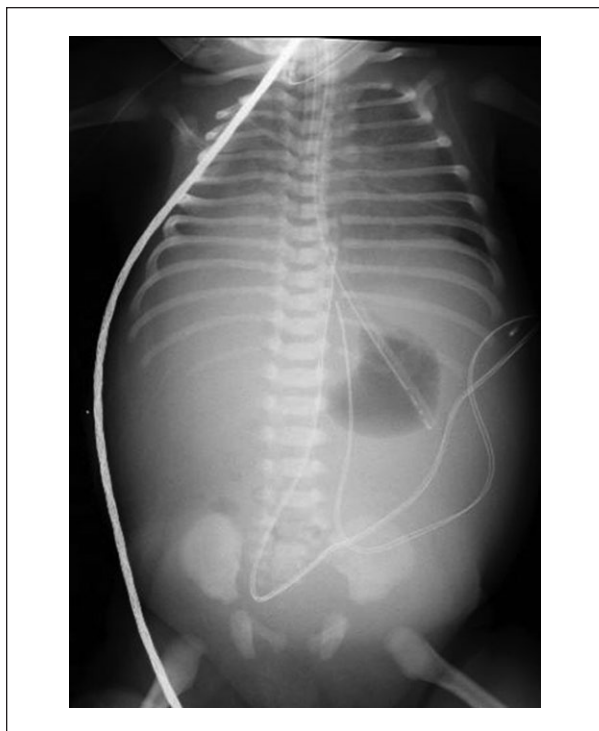
**Figure 2.** Early part of day of life 7. Right upper lobe infiltrate, enlarged liver, and paucity of bowel gas. Stomach shadow with bowel gas pushed to lower half of abdomen. UVC tip at T10 on right.

repeated. Antibiotics coverage with Ampicillin and Gentamicin started at birth were continued.

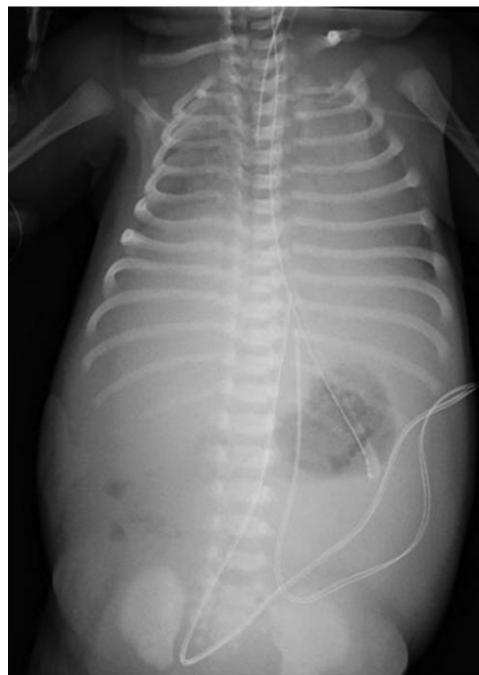
On the morning of day of life 7 with the infant on minimal settings on ventilator, the infant's endotracheal tube was removed and extubated to nasal cannula. Within 6 hours, the infant failed extubation due to upper airway edema from 7 days of being intubated. Also later, failure of extubation was attributed to worsening respiratory status due to progressively increased abdominal girth.

On the evening of day of life 7, moderately high liver enzyme was noted on blood chemistry. Also, abdomen with chest X-ray showed paucity of bowel gas and UVC tip at T10 (Figure 2). UVC had migrated into the liver, with insidious onset of abdominal distension, ascites, liver enlargement, markedly elevated liver enzymes, obstructive uropathy, and progressive worsening of respiratory status.

By early hours of day of life 8, abdominal girth had increased by 5 cm over the previous 6 hours, from 36 cm to 41 cm, and there was an increase in liver size, by clinical assessment and radiologically (Figures 2-5). X-ray of chest and abdomen revealed small lung volume, compressed by gasless abdomen, huge liver, marked abdominal distension, and ascites (Figures 3 and 4). Liver enzymes markedly increased from the previous 24



**Figure 3.** Later part of day of life 7. Inadequate lung volume due to compression by abdominal content, small stomach gas, no bowel gas, huge liver, and ascites. UVC tip at T10 now to the left.



**Figure 4.** Early hours of day of life 8. Very hazy, low lung volume (especially right side), massively distended abdomen, large liver and ascites, small gastric shadow, no bowel gas. UVC tip at T10 and to the left hepatic.

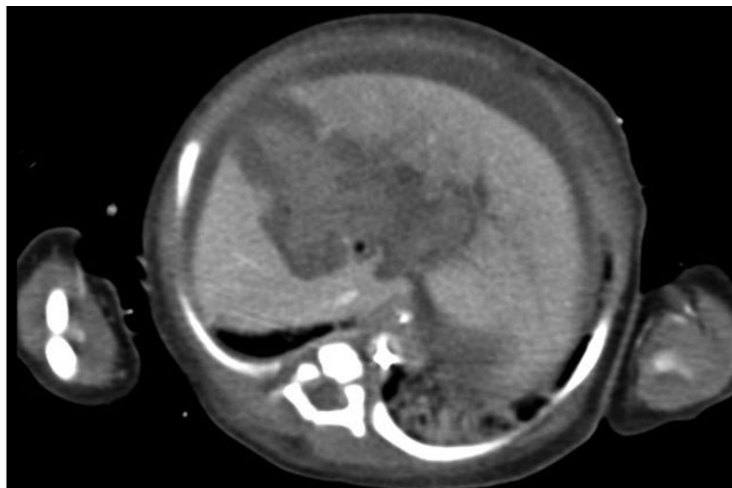
hours, aspartate transaminase from 173 U/L to 929 U/L; alanine transaminase from 82 U/L to 380 U/L (both 5 to 8 times increase from previous); total/D bilirubin 4.1/1.5 g/dL, from previous day's total bilirubin of 2.7 g/dL; lactate dehydrogenase 1861 IU/L (see Table 1). Abdominal ultrasound and computed tomography done on day of life 8 (Figure 5) confirmed ascites, huge liver with an echogenic mass within it, mild left hydronephrosis and obstructive uropathy, and intrahepatic biliary duct dilatation. TPN extravasation via UVC was suspected, UVC infusion stopped, and UVC was removed. TPN infusate at time of diagnosis had an osmolarity concentration of 1008 mOsm/L.

A peripheral intravenous (IV) access was obtained and dextrose with electrolytes started. Pediatric surgeon was consulted, and performed exploratory laparotomy, clot removal, ascites drainage and Penrose drain placement in the Peritoneal cavity. Paracentesis confirmed TPN extravasation (peritoneal fluid described as milky and yellow and peritoneal fluid analysis chemistry showed protein 1213 mg/dL; triglyceride 591 mg/dL; glucose 539 mg/dL).

On day of life 10, HSV polymerase chain reaction was reported negative, and IV acyclovir was discontinued;

repeat blood culture done on day of life 6 was also negative, and so IV ampicillin and gentamicin were also discontinued by day of life 11, when blood culture was final.

The infant's clinical status improved significantly by day of life 10, within 48 to 96 hours of surgically draining the ascites and removal of peritoneal blood clots via exploratory laparotomy. A Penrose drain was placed in the peritoneal cavity, and removed 5 days later, when drainage ceased. The infant required and received two 20 mL/kg of packed red blood cell transfusion during the immediate 24 hours post operation for anemia due to liver laceration and hemorrhage. Elevated liver enzymes dropped dramatically till normal, hematuria resolved, and Penrose drain was removed by the fifth day postoperative, which was on day of life 13. No sign of disseminated intravascular coagulopathy was noted. Enteric nutrition was started on fourth day postoperative, day of life 12, and attained full enteric feedings 7 days later, on day of life 19. The infant was extubated to room air on day of life 19, and started on nipple feeding, breast and bottle, Similac Advance, all per oral by day of life 25. Clinically and biochemically the liver laceration, liver mass, obstructive uropathy, and ascites resolved, as evident by normal liver and renal function tests at time



**Figure 5.** Day of life 8. Computed tomography abdomen, showing hypo-echogenic mass within liver on the right, tracking into the peritoneal cavity and hydronephrosis with obstructive uropathy on the left. Liver mass, hydronephrosis with ascites secondary to TPN extravasation via the UVC.

of home discharge. Abdominal ultrasound done on day of life 27 was normal, except for small residual liver mass, which the pediatrician followed at outpatient. The infant remained in stable clinical condition and was discharged home on day of life 28.

## Discussion

UVC is used to provide a quick access for fluid administration in both term and preterm neonates in the neonatal intensive care unit.<sup>1,3</sup> The appropriate position of UVC just above or at the level of the diaphragm (T7 to T9) between inferior vena cava and right atrium on radiography is crucial to prevention of complications. Placement below this point (T10 or below) in majority of cases are in the liver.<sup>1-3</sup> A normal positioned UVC between T7 and T9 (above the ductus venosus and hepatic veins, in the inferior vena cava, or lower part of the right atrium) can stay in use up to 14 days, if intravenous access is a problem. Otherwise it is advised to discontinue UVC by day 10 and replace with a percutaneous intravenous central catheter.

A malpositioned UVC, below T9 with critical need, should be replaced by 48 to 72 hours to avoid complications.<sup>3,4</sup> Among the complications of a malpositioned UVC tip is intraperitoneal spillage, from hepatic vessel perforation, leading to hepatic laceration, intraabdominal hemorrhage/organ enlargement with mass effect or obstruction, and ascites from TPN extravasation. The complication of intraperitoneal spillage has an insidious onset with abdominal distension and absence of

hemodynamic instability as demonstrated in this case and previously described by Coley et al.<sup>3</sup> Hepatic necrosis leading to disruption of the liver capsule is believed more likely the antecedent event.<sup>3-5</sup>

As in our case, an insidious onset of liver enlargement precedes ascites was first noted on day of life 7, as worsening in respiratory status resulted in reintubation within 6 hours of extubation and increase in abdominal girth. Diagnosis of TPN extravasation via UVC was confirmed on the early hours of day of life 8, with ascitic fluid consistent with TPN infusate.

Hepatic perforation or laceration with ascites secondary to TPN extravasation has only been previously reported in preterm neonates.<sup>1-5</sup> These complications in either preterm or term neonates are believed to be related to the same reasons, as follows: improper positioning of the catheters within the liver rather than the inferior vena cava or right atrium, the hypertonicity or elevated pH of material infused through them, and longer than 3 days duration of hypertonic infusate via a malpositioned UVC.<sup>3-5</sup> In previous cases reported in preterm infants the neonates were receiving hypertonic TPN ranging from approximately 500 to 1100 mOsmol through their UVC, at the time complications occurred. Our patient was receiving TPN with osmolality concentration of 1008 mOsmol/L.<sup>1,3,5</sup> The mean duration of UVC use before diagnosis of TPN extravasation was 5.5 to 8.9 days.<sup>1,3-5</sup> In our case, the diagnosis was suspected on day 7 of UVC use. No pathophysiology of the process of UVC perforation and complication has been previously reported in term neonates or compared to the process in the preterm neonates until now.

**Table 1.** Ventilator Setting, Respiratory Status, Blood Gas, Liver Enzyme, and Renal Function Tests at Various Days of Life, Before, During, and After UVC Perforation.

Day of Life	AST (15-41 U/L)	ALT (11-39 U/L)	TB/DB (TB = 0.4-2 mg/dL; DB = <20% TB)	Cr/BUN (Cr = 0.1-0.6 mg/dL; BUN = 2-19 mg/dL)	LDH (98-192 IU/L)	ABG/Vent Setting	Abdominal Girth (cm)
2	50	38	5.6	0.4/10		7.25/58/52/18/-8 (on SIMV rate 40, press 22/5, 40% oxygen)	35
4	74	50	4.7	0.3/10		7.31/50/41/32 (on SIMV rate 30, press 20/5)	35
5	64	44	3.5	0.31/10		7.31/65/41/32 (on SIMV rate 40, press 20/5)	35
6 (started acyclovir)	107	64	3.0	0.24/10		7.35/61/45/34/9 (on SIMV rate 60, PIP 22, PEEP 5, 40% to 0% oxygen)	35
7 (in AM)	173	82	2.7	0.28/9		7.42/61/55/40 (on SIMV rate 30, press 20/5, oxygen 47%; weaned down to rate 15, press 16/5, at trial of extubation done and failed)	36
8 (preop, Penrose drain placed)	<b>929</b>	<b>380</b>	<b>4.1/1.5</b>	<b>0.5/27</b>	<b>1861</b>	<b>7.36/58.2/53/33.4/8,</b> reintubated and back (on SIMV 65%, rate 40, press 22/5)	41
10 (HSV-PCR negative, off acyclovir)	84	85	1.7	0.17/6.0		7.31/61/51/31 (on SIMV 40%, rate 35, press 22/5)	35
12 (normal levels, started enteric feeding)	<u>33</u>	<u>46</u>	<u>1.2</u>	<u>0.21/8</u>		7.38/51/61/30 (on SIMV rate 35, PIP 20, PEEP 5, oxygen 35%)	35
14 (normal levels)	32	27	0.9	0.18/10	393, normalizing		

Abbreviations: UVC, umbilical venous catheter; AST, aspartate transaminase; ALT, alanine transaminase; TB, total bilirubin; DB, D bilirubin; Cr, creatinine; BUN, blood urea nitrogen; LDH, lactate dehydrogenase.

Note: Laboratory result in Bold was pre operative and signify Liver enzymes markedly increased from previous 24 hours, AST from 173U/L to 929 U/L; ALT from 82U/L to 380U/L; both 5-8 times increased from previous; Total/D bilirubin 4.1/1.5 gm/dl, from previous day's Total bilirubin of 2.7gm/dl; LDH- 1861IU/L, very high, indicative of liver ischemia/injury; Renal function tests -Cr and BUN was also higher compared to previous level, indicating Renal injury;

While low UVC placement may be clinically unavoidable, TPN administered through such malpositioned catheters is not without complication. High index of suspicion should be used to follow malpositioned UVC, so that prompt diagnosis can be made and a life-threatening complication can be avoided.

#### Author Contributions

OA: Contributed to conception and design; contributed to acquisition, analysis, and interpretation; drafted manuscript; critically revised manuscript; gave final approval; agrees to be accountable for all aspects of work ensuring integrity and accuracy.

MN: Contributed to conception; contributed to acquisition and analysis; critically revised manuscript; gave final approval; agrees to be accountable for all aspects of work ensuring integrity and accuracy.

#### Declaration of Conflicting Interests

The author(s) declared no potential conflicts of interest with respect to the research, authorship, and/or publication of this article.

#### Funding

The author(s) received no financial support for the research, authorship, and/or publication of this article.

**References**

1. Rejjal AR, Galal MO, Nazer HM, Karim AA, Osba YA. Complication of parenteral nutrition via an umbilical vein catheter. *Eur J Pediatr*. 1993;152:624.
2. Shareena I, Khu YS, Cheah FC. Intraperitoneal extravasation of total parenteral nutrition infusate from an umbilical venous catheter. *Singapore Med J*. 2008;49(2):e35-e36.
3. Coley BD, Seguin J, Cordero L, Hogan MJ, Rosenberg E, Reber K. Neonatal total parenteral nutrition ascites from liver erosion by umbilical vein catheters. *Pediatr Radiol*. 1998;28:923-927.
4. Hui JYH, Lo KKL, Lo J, Chan MLM, Chan JCS. Neonatal total parenteral nutrition ascites secondary to umbilical venous catheterisation. *J HK Coll Radiol*. 2001;4:288-290.
5. Gülcan H, Hanta D, Törer B, Temiz A, Demir S. Hepatic laceration as a life-threatening complication of umbilical venous catheterization. *Turk J Pediatr*. 2011;53:342-345.