

Asystole in Orthognathic Surgery: A Case Report

Stamatis Baronos, MD,* Wayne Fong, MD,* Nicholas P Saggese, DMD,† Jonathan Luke, DDS,‡ Khaja Ahmed, DO,* and Joel Yarmush, MD*

A previously healthy 26-year-old man presented for elective Le Fort I osteotomy, bilateral mandibular osteotomy, and genioplasty. During the intraoperative course, the patient developed sudden bradycardia and asystole on placement of a bite block. Asystole is an extremely rare consequence of the trigeminocardiac reflex, and awareness of this potentially life-threatening complication is pivotal in its management. (A&A Practice. 2019;12:249–51.)

The trigeminocardiac reflex is thought to be a brainstem reflex affecting the sympathetic and parasympathetic branches of the autonomic nervous system. It can present as bradycardia (rarely tachycardia), hypotension, hypertension, apnea, gastric hypermobility, and, in uncommon circumstances, asystole.^{1,2} The most common subcategory of trigeminocardiac reflex is the oculocardiac reflex. However, any stimulation along the trigeminal nerve distribution can elicit the response. In this report, we present an extreme example of trigeminocardiac reflex where asystole and bradycardia occur in a patient undergoing orthognathic surgery. The patient provided written consent for the publication of this case report.

CASE DESCRIPTION

A 26-year-old Asian man presented for elective Le Fort I osteotomy, bilateral mandibular osteotomy, and genioplasty. He had general anesthesia in the past with no adverse events. Physical examination and laboratory values were within normal limits. His preoperative blood pressure and heart rate (HR) were 131/87 mm·Hg and 65 beats/min, respectively. In the operating room, standard American Society of Anesthesiologist monitors were applied. His electrocardiogram showed normal sinus rhythm. The patient was induced with midazolam 2mg, propofol 200mg, fentanyl 50 µg, followed by rocuronium 50mg and nasotracheal intubation under direct laryngoscopy. An arterial line was placed, and anesthesia was maintained with oxygen (40%), desflurane (4.8%–7.4%), and a remifentanyl infusion

(0.02–0.05 µg/kg/min). This surgery required controlled hypotension with a target mean arterial pressure (MAP) of 60–65 mm Hg. This was achieved with the above agents along with labetalol boluses (20 mg total).

Le Fort I and mandibular osteotomies were completed, and both jaws were presumptively placed into the correct position. Both inferior alveolar nerves were noted to be intact. The new jaw positions were secured with plates and screws. A bite block was then placed, and severe sinus bradycardia immediately followed by asystole was noted. The surgeon was asked to remove the bite block. Asystole (about 10 seconds) evolved into a junctional escape rhythm immediately followed by a sinus rhythm with the return of normal vital signs. Repetition of the bite block maneuver triggered bradycardia to the 30–40s (Supplemental Digital Content, Video 1, <http://links.lww.com/AACR/A252>). This reflex was elicited 2 more times before the decision was made to administer glycopyrrolate 0.4mg intravenously, which increased the HR to 100–115 beats/min. The dental occlusion was noted to be incorrect on the left side due to misalignment of the left mandibular condyle. The malocclusion was subsequently corrected through revision of the left mandibular osteotomy. Afterward, the HR remained in the 70s each time the bite block was placed. The patient was successfully extubated and was monitored in the surgical stepdown unit overnight. After having no further episodes of trigeminocardiac reflex in the postoperative period, the patient was discharged home the next day.

DISCUSSION

Although bradycardia in maxillofacial surgery was originally attributed to a variation of the oculocardiac reflex, Shelly and Church³ were the first to appoint the term trigeminocardiac reflex in 1988. This term described the clinical phenomenon of bradycardia on stimulation of any branch of the trigeminal nerve.³ Trigeminocardiac reflex is presently defined as a decreased HR and MAP of ≥20% on surgical manipulation in the vicinity of any trigeminal nerve branch.⁴

The incidence of trigeminocardiac reflex in the literature varies from 5% to 90% depending on the nature and location of the surgical stimulus (Table 1).^{1,2} The incidence of trigeminocardiac reflex in all craniofacial surgeries is 20% with the highest occurring in facial trauma (32%) and the lowest in lower face reconstruction (3.6%).⁶ Orthognathic surgery has a trigeminocardiac reflex incidence of 9.1%.⁶ Table 2 lists commonly reported risk factors.

The most important trigger of the reflex includes sudden mechanical stretch of the nerve. However, the reflex has been documented to occur with thermal, electrical,

From the *Department of Anesthesiology, NewYork-Presbyterian Brooklyn Methodist Hospital, Brooklyn, NY; †Department of Oral and Maxillofacial Surgery, Brookdale University Hospital and Medical Center, Brooklyn, NY; and ‡Department of Dental Medicine, NewYork-Presbyterian Brooklyn Methodist Hospital, Brooklyn, NY.

Accepted for publication January 4, 2019.

Funding: Department of Anesthesiology, NewYork-Presbyterian Brooklyn Methodist Hospital.

The authors declare no conflicts of interest.

Supplemental digital content is available for this article. Direct URL citations appear in the printed text and are provided in the HTML and PDF versions of this article on the journal's website (www.cases-anesthesia-analgesia.org).

Address correspondence to Stamatis Baronos, MD, NewYork-Presbyterian Brooklyn Methodist Hospital, 506 6th St, Brooklyn, NY 11215. Address e-mail to sbaronos@gmail.com.

Copyright © 2019 The Author(s). Published by Wolters Kluwer Health, Inc. on behalf of the International Anesthesia Research Society. This is an open-access article distributed under the terms of the Creative Commons Attribution-Non Commercial-No Derivatives License 4.0 (CCBY-NC-ND), where it is permissible to download and share the work provided it is properly cited. The work cannot be changed in any way or used commercially without permission from the journal.

DOI: 10.1213/XAA.0000000000000979

infectious, and biochemical stimuli.^{1,5,6} Bilateral stimulation of trigeminal nerve structures produces a more pronounced reflex compared to unilateral stimulation.⁵ In our patient, bilateral mechanical stretch of the mandibular division of the trigeminal nerve (V3) through the application of a bite block likely triggered the asystole. We speculate that the nerve affected by the bite block was either the inferior alveolar nerve and/or the auriculotemporal branch of V3, which was stretched by the malpositioned left mandibular condyle. When the left mandibular condyle was repositioned, the trigeminocardiac reflex did not occur again.

Table 1. Common Procedures That Can Trigger Trigemino-cardiac Reflex^a

Neurosurgical procedures (especially cerebellopontine angle surgeries)
Microvascular decompression or rhizolysis of the trigeminal nerve
Transphenoidal pituitary resection
Cavernous sinus procedures
Ophthalmic surgery
Dental and craniomaxillofacial surgery

^aAdapted from Singh and Chowdhury,¹ 2017, and Chowdhury et al,⁵ 2015.

Table 2. Risk Factors for Trigemino-cardiac Reflex^a

Mechanical stretch
Young age (most susceptible group is 21–30 age range)
Male sex (incidence up to 77%)
Higher resting parasympathetic tone
Hypoxemia
Hypercapnia
Light plane of anesthesia (4.5 times higher incidence)
Strong and long-lasting provoking stimulus
Opioids
Calcium channel blockers
β-Blockers

^aAdapted from Singh et al,¹ 2017; Meuwly et al,⁴ 2015; Shanab and Albarji,⁶ 2016; Chowdhury et al,⁵ 2015; and Joshi et al,⁷ 2016.

The Figure illustrates the trigeminocardiac reflex arc. Peripheral stimulation can produce any of the following 3 trigeminocardiac reflex subtypes: oculocardiac reflex (V1), maxillomandibulocardiac reflex (V2, V3), and diving reflex, all of which present with bradycardia and apnea. However, blood pressure response varies. The first 2 subtypes can result in normotension or hypotension, whereas the diving reflex, which occurs on stimulation of the anterior ethmoidal nerve, produces hypertension. The reason for the latter is thought to be a phylogenetically inherited reflex from birds and mammals that causes apnea, bradycardia, peripheral vasoconstriction, increase in MAP, and increase in cerebral blood flow, in response to hypoxic environments (diving).^{2,5,6} Central stimulation beyond the Gasserian ganglion can present with bradycardia, hypotension, and apnea. However, stimulation at the ganglion can produce apnea and a mixed sympathetic/parasympathetic response with bradycardia, tachycardia, hypotension, or hypertension.^{5,6}

Most cases of asystole secondary to trigeminocardiac reflex have been reported in neurosurgery or ophthalmic surgery. Nonsurgical cases of trigeminocardiac reflex have also been reported such as with herpetic ophthalmicus and associated with a nonoperative zygomatic arch fracture.⁴ Asystole is an extremely rare occurrence in maxillofacial surgery with a paucity of reports in the literature. Precious and Skulsky⁸ performed a retrospective review of 502 patients who underwent maxillofacial surgery and reported 8 cases of dysrhythmias (1.6%). Six cases occurred during Le Fort I osteotomies (bradycardia when a maxillary segment was mobilized anteriorly) and 2 during temporomandibular joint reconstruction (asystole). One episode of asystole was thought to occur from stretching the temporalis tendon complex on placement of a side action mouth prop.⁸ The second patient undergoing temporomandibular joint surgery had cardiac arrest on detachment of muscle

TRIGEMINOCARDIAC REFLEX

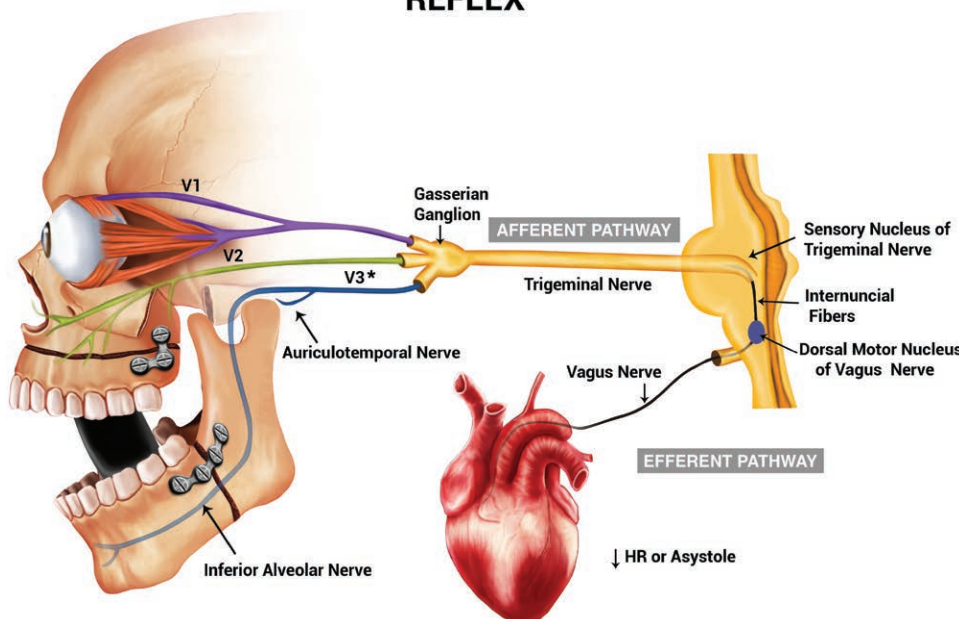


Figure. The trigeminocardiac reflex arc via the mandibular branch of the trigeminal nerve secondary to placement of a bite block. If the condyle or osteotomy sites are malpositioned, maximum jaw opening can potentially stimulate either the inferior alveolar nerve or auriculotemporal nerve. Adapted from Singh et al,¹ 2017.

and tendon fibers from the coronoid process. Ragno et al⁹ were the first to report a case of asystole after inferior displacement of the Le Fort I osteotomy segment. Lang et al¹⁰ reported a case of intraoperative asystole secondary to trigeminocardiac reflex on anterior movement of the maxillary segment. This was treated with the immediate release of forwarding pressure and atropine. Another case of trigeminocardiac reflex occurred when using a channel retractor along the medial border of the mandibular ramus, which was treated with a mandibular nerve block and atropine.¹⁰ In both cases, asystole did not recur during the surgery. Morey and Bjoraker¹¹ reported a case of asystole on irrigation of the temporomandibular joint, and Campbell et al¹² reported asystole during a Le Fort I osteotomy on cutting the maxillary tuberosity.

A mandibular nerve block and careful surgical technique in the distribution of the trigeminal nerve may provide protection against trigeminocardiac reflex.¹² Avoidance or treatment of factors predisposing to trigeminocardiac reflex such as hypoxia, acidosis, hypercarbia, a light plane of anesthesia, and narcotics can prevent the reflex. Close monitoring is pivotal for early detection and immediate termination of trigeminocardiac reflex, especially if opioids and β -blockers are used for controlled hypotension.

In our case, replacement of the bite block reproduced the reflex. Repositioning of the condyle and the use of glycopyrrolate allowed us to proceed without significant hemodynamic perturbations. The trigeminocardiac reflex, unlike the oculocardiac reflex, does not appear to be fatigable as stated in the literature,¹¹ and the use of vagolytic agents can counteract hemodynamically significant bradycardia. Atropine, however, may not always prevent bradycardia,² and its use is highly disputable.⁴ Furthermore, hypotension and bradycardia in trigeminocardiac reflex might not always result from increased vagal stimulation but from decreased sympathetic tone. In such cases, a vagolytic agent will likely not be effective, and epinephrine should be used instead.⁵

To summarize, trigeminocardiac reflex is a serious complication that can result in bradycardia, cardiac arrest, and even death during maxillofacial surgery.⁶ Although the trigeminocardiac reflex can occur during many surgeries, the use of prophylactic anticholinergics is questionable.¹² We found the repositioning of the condyle and the use of anticholinergics after repeated occurrences of trigeminocardiac reflex to be protective against further hemodynamic fluctuations. We concur with many authors³ that changing the term oculocardiac reflex to trigeminocardiac reflex would

increase awareness of the maxillomandibulocardiac subtype. The anesthesiologist and maxillofacial surgeon should be aware of this rare, but potentially life-threatening complication. ■■

DISCLOSURES

Name: Stamatis Baronos, MD.

Contribution: This author helped care for the patient and write the manuscript.

Name: Wayne Fong, MD.

Contribution: This author helped care for the patient and write the manuscript.

Name: Nicholas P. Saggese, DMD.

Contribution: This author helped care for the patient and write the manuscript.

Name: Jonathan Luke, DDS.

Contribution: This author helped care for the patient and write the manuscript.

Name: Khaja Ahmed, DO.

Contribution: This author helped write the manuscript.

Name: Joel Yarmush, MD.

Contribution: This author helped write the manuscript.

This manuscript was handled by: BobbieJean Sweitzer, MD, FACP.

REFERENCES

1. Singh GP, Chowdhury T. Brain and heart connections: the trigeminocardiac reflex! *J Neuroanaesthesiol Crit Care*. 2017;4:71–77.
2. Schaller B, Cornelius JF, Prabhakar H, et al; Trigemino-Cardiac Reflex Examination Group (TCREG). The trigemino-cardiac reflex: an update of the current knowledge. *J Neurosurg Anesthesiol*. 2009;21:187–195.
3. Shelly MP, Church JJ. Bradycardia and facial surgery. *Anaesthesia*. 1988;43:422–422.
4. Meuwly C, Chowdhury T, Sandu N, Reck M, Erne P, Schaller B. Anesthetic influence on occurrence and treatment of the trigemino-cardiac reflex: a systematic literature review. *Medicine (Baltimore)*. 2015;94:e807.
5. Chowdhury T, Mendelowith D, Golanov E, et al; Trigemino-Cardiac Reflex Examination Group. Trigeminocardiac reflex: the current clinical and physiological knowledge. *J Neurosurg Anesthesiol*. 2015;27:136–147.
6. Shanab HG, Albargi HH. Incidence of trigeminocardiac reflex in maxillofacial surgery: a retrospective study. *J Health Spec*. 2016;4:151–156.
7. Joshi UM, Munnangi A, Shah K, Patil SG, Thakur N. Trigeminocardiac reflex: a phenomenon neglected in maxillofacial surgery? *J Maxillofac Oral Surg*. 2017;16:181–185.
8. Precious DS, Skulsky FG. Cardiac dysrhythmias complicating maxillofacial surgery. *Int J Oral Maxillofac Surg*. 1990;19:279–282.
9. Ragno JR Jr, Marcoot RM, Taylor SE. Asystole during Le Fort I osteotomy. *J Oral Maxillofac Surg*. 1989;47:1082–1083.
10. Lang S, Lanigan DT, van der Wal M. Trigeminocardiac reflexes: maxillary and mandibular variants of the oculocardiac reflex. *Can J Anaesth*. 1991;38:757–760.
11. Morey TE, Bjoraker DG. Asystole during temporomandibular joint arthroscopy. *Anesthesiology*. 1996;85:1488–1491.
12. Campbell R, Rodrigo D, Cheung L. Asystole and bradycardia during maxillofacial surgery. *Anesth Prog*. 1994;41:13–16.