

Unexpected side effect in mCRC

A care-compliant case report of regorafenib-induced hyperammonemic encephalopathy

Michela Quirino, MD, PhD^a, Sabrina Rossi, MD^{b,*}, Giovanni Schinzari, MD, PhD^a, Michele Basso, MD, PhD^a, Antonia Strippoli, MD, PhD^a, Alessandra Cassano, MD, PhD^a, Carlo Barone, MD, PhD^a

Abstract

Rationale: Regorafenib represents a treatment option in heavily pretreated patients affected by metastatic colorectal cancer (mCRC). Its safety profile is typical of small-molecule tyrosine-kinase inhibitors (TKIs) and most adverse events are manageable.

Patient concerns: A 56 years-old Caucasian man affected by mCRC with normal hepatic reserve was treated with regorafenib as second-line treatment. After only 2 days of therapy, the patient presented to the emergency department due to impairment of both spatial and temporal orientation and motor function with bradylalia.

Interventions: Serum ammonia level was 191 mmol/L, liver function tests and complete blood count were normal. Regorafenib was withheld and branched chain amino acids and lactulose were administered.

Outcomes: Serum ammonia level returned within the normal range, but when regorafenib was restarted at a lower dose level, a new episode of acute confusion arised.

Main lesson: Discontinuation of regorafenib after confirmation of hyperammonemia is strongly recommended; reintroduction of the therapy at lower doses after resolution of symptoms related to hyperammonemic encephalopathy has to be discouraged.

Abbreviations: AE = adverse event, HE = hyperammonemic encephalopathy, mCRC = metastatic colorectal cancer, RPLS = reversible posterior leukoencefalopathy syndrome, TKI = tyrosine-kinase inhibitor.

Keywords: case report, hyperammonemic encephalopathy, regorafenib, TKI

1. Introduction

The introduction of regorafenib has increased overall survival (OS) in patients with metastatic colorectal cancer (mCRC) who had previously received all standard therapies, as shown in the CORRECT study.^[1] Although advantage in median OS between the experimental arm and the control arm was only 1.4 months, the hazard ratio (HR) of 0.77 produced a 23% reduction in risk of death during the course of the study in this population of patients with a poor prognosis and a high clinical unmet needs.

Editor: Eric Bush.

Ethical Conduct of Research: The study has been conducted in accordance with the rules of the local Ethics Committee and the Declaration of Helsinki. The patient provided a written consent for use of his clinical data.

The authors have no funding and conflicts of interest to disclose.

^a Department of Medical Oncology, Catholic University of Sacred Heart, Rome,

^b Department of Medical Oncology, Humanitas Clinical and Research Center, Rozzano, Milan, Italy.

* Correspondence: Sabrina Rossi, Department of Medical Oncology, Humanitas Clinical and Research Center, Via Manzoni, 56, 20089 Rozzano, Milan, Italy (e-mail: sbrn.rossi85@gmail.com).

Copyright © 2017 the Author(s). Published by Wolters Kluwer Health, Inc. This is an open access article distributed under the terms of the Creative Commons Attribution-Non Commercial-No Derivatives License 4.0 (CCBY-NC-ND), where it is permissible to download and share the work provided it is properly cited. The work cannot be changed in any way or used commercially without permission from the journal.

Medicine (2017) 96:16(e6522)

Received: 30 December 2016 / Received in final form: 26 February 2017 /

Accepted: 9 March 2017

<http://dx.doi.org/10.1097/MD.0000000000006522>

Regorafenib also showed to be effective in terms of progression-free survival (PFS) and disease control rate and, at present, it may be considered a new standard of care in late-stage mCRC.

The safety profile of regorafenib is typical of small-molecule tyrosine-kinase inhibitors (TKIs). In the CORRECT trial the most frequent adverse events (AEs) of grade 3 or higher were hand-foot skin reaction, fatigue, diarrhea, hypertension, rash, and desquamation. Occurrence of liver toxicity was higher in the regorafenib than in the placebo group; the difference was attributable mainly to grade 1 or 2 events, but 1 fatal case of drug-induced liver injury was reported. Hyperammonemic encephalopathy (HE) related to regorafenib use has reported only in 1 patient with advanced GIST,^[2] and it is a rare occurrence even with other TKIs. To our knowledge, this is the 1st case of HE under regorafenib treatment in a patient affected by mCRC with normal hepatic reserve.

2. Case report

A 56 years-old Caucasian man, affected by hypertension under treatment control, was referred to our Center in July 2014 and underwent left emicolectomy with lymph nodes dissection for a pT4a pN2b moderately differentiated mucinous adenocarcinoma of descending colon; mutational analysis of RAS and BRAF shown a wild-type sequence. Computed tomography (CT) scan at diagnosis did not demonstrate any secondary lesion. From September 2014 to May 2015 12 courses of adjuvant chemotherapy with FOLFOX-4 regimen were administered. In June 2015, the CT scan showed 4 metastases in the right lobe of the liver (2.5 cm maximum diameter) and 2 pulmonary metastases in the lung (1.3 cm maximum diameter). In July

2015, a 1st-line chemotherapy with FOLFIRI plus bevacizumab was started; after 8 courses of chemotherapy, the CT scan showed a progressive disease according to RECIST criteria,^[3] with 3 new liver metastases in the right lobe (1.6 cm maximum diameter). On 7th January 2016, 4 weeks after the last FOLFIRI-Bevacizumab administration, regorafenib was started at standard dose of 160 x0200A;mg daily, for the 1st 3 weeks of each 4 week cycle. After only 2 days of therapy, the patient presented to the emergency department of a zone hospital due to impairment of both spatial and temporal orientation and motor function with bradylalia. On admission liver function tests and complete blood count were normal, but serum ammonia level was 191 µmol/L

(thrice the upper normal range of 60 µmol/L). The patient was not an alcohol addicted nor treated with cytochrome P450 inducers or inhibitors. A brain CT scan excluded any intracranial pathology; an abdominal ultrasound (US) confirmed the presence of liver metastases, in absence of biliary ducts distension or signs of portal hypertension. No cardiac or pulmonary alterations were found. Regorafenib was withheld and branched chain amino acids and lactulose was administered, with a complete resolution of the confusional status in 24 hours. After 3 days the patient was discharged, and in 10 days serum ammonia level returned within the normal range (57 µmol/L). Regorafenib was thereafter restarted at a lower dose level (80 mg daily every 3 weeks of a

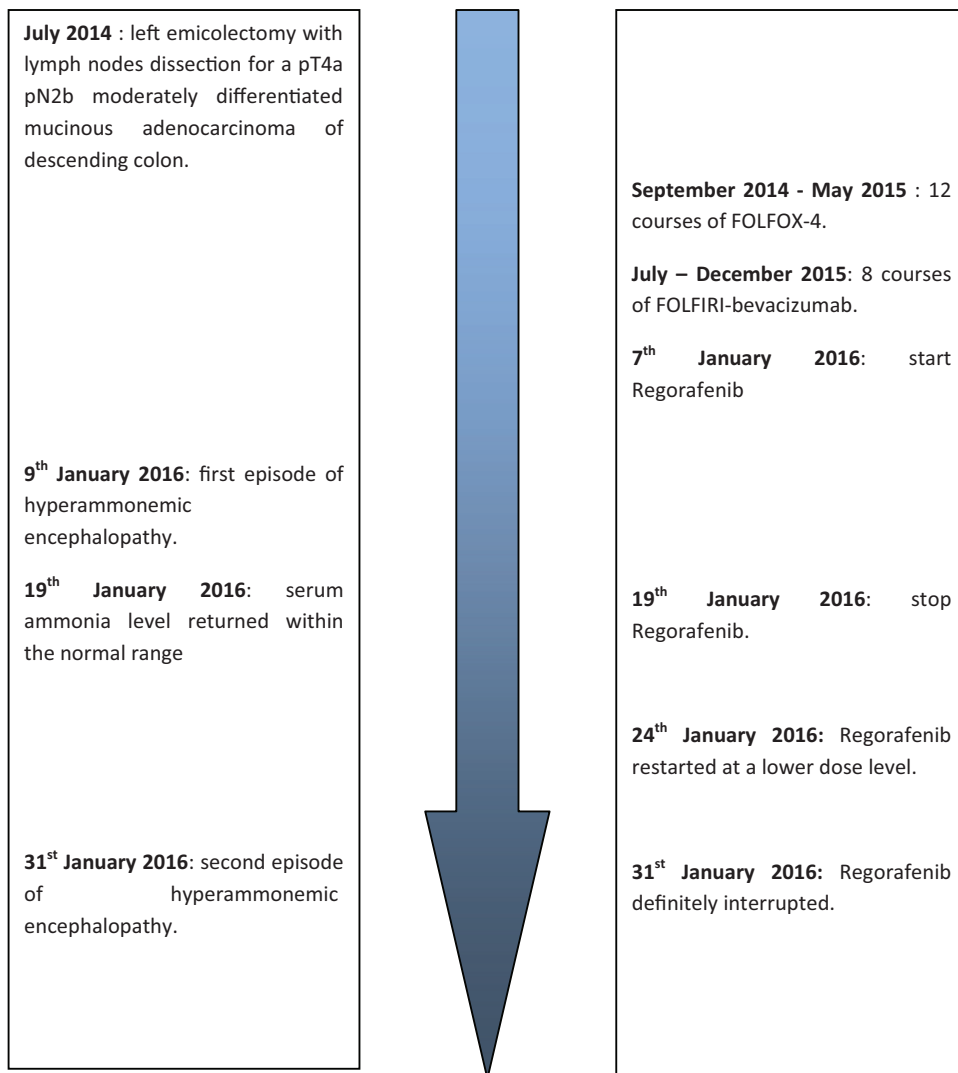


Figure 1. Timeline of relevant events.

Table 1**Case reports of reversible posterior leukoencephalopathy syndrome in patients treated with TKIs.**

Ref	Drug	Age	Ethnicity	Primary tumor	Liver metastases	Ammonium level	Interval between drug commencement and hyperammonemia	Interval between drug stopping and symptoms resolution
Kuo et al	Regorafenib	61	Caucasian	GIST	Yes	105 (NL < 50 $\mu\text{mol/L}$)	10 d	72 h
Brandi et al	Sorafenib	77	Unknown	HCC	–	92 (NL < 35 mg/dL)	10 d	<2 wk
Shea et al	Sunitinib	61	Unknown	pNET	Yes	147 (NL < 33 $\mu\text{mol/L}$)	14 d	24 h
Lee et al	Sunitinib	58	Asian	GIST	Yes	210 (NL < 45 $\mu\text{g/dL}$)	17 d	24 h
Lee et al	Sunitinib	68	Asian	GIST	No	389 (NL < 45 $\mu\text{g/dL}$)	10 d	24 h

GIST=gastrointestinal stromal tumor, HCC=hepatocellular carcinoma, pNET=pancreatic neuroendocrine tumor, TKI=tyrosine-kinase inhibitor.

4 week cycle). After 7 days of therapy, a new episode of acute confusion arised, and he was admitted to the zone hospital again. Liver function tests and complete blood count were normal, while serum ammonia level was 195 $\mu\text{mol/L}$ so branched chain amino acids and lactulose were restored with rapid improvement of the cognitive status. Regorafenib was definitely interrupted and a rescue treatment was started. This AE was reported to the local drug control committee. The sequence of events is reported in Fig. 1.

3. Discussion

Regorafenib is an oral inhibitor of angiogenic, oncogenic, and stromal kinases and of the RAF/MEK/ERK signaling pathway. The expected AEs of regorafenib are similar to those reported with other multitarget TKIs (hypertension, hand-foot syndrome, diarrhea, etc.); other rare AEs include hepatotoxicity, hemorrhage, gastrointestinal perforation, myocardial infarction, and reversible posterior leukoencephalopathy syndrome (RPLS).^[4] RPLS is a neurological syndrome characterized by headache, seizures, impaired vision, acute hypertension, and typical imaging findings (bilateral edema of the gray and white matter in the posterior regions of cerebral hemispheres); its pathogenesis depends on capillary endothelium damage in the brain due to hypertension leading to capillary leak and brain edema.^[5] HE has been reported in patients receiving chemotherapy, mostly in patients with hematologic malignancies during neutropenic phases following cytoreductive therapy and high-dose chemotherapy for bone marrow transplantation, or in patients with solid tumors treated with fluorouracil, as well as in patients affected by either primary hepatocellular carcinoma or neuroendocrine tumor with liver metastases.^[6–8] Hyperammonemia occurs when ammonia is either overproduced or insufficiently eliminated from the serum; HE is an uncommon alteration in mental status that may arise in the absence of obvious liver disease.^[9]

Several cases of RPLS have been reported for either regorafenib or other TKIs,^[10–12] but – at the best of our knowledge – only 5 cases of HE associated to TKIs have been described in literature.^[2,13–15] Among these, only 1 case of regorafenib-induced HE is described,^[2] whereas the other have been related to sorafenib (1 case) and sunitinib (3 cases).^[13,15] In 4 out of 5 patients, liver was involved as primary or metastatic site of disease; in all cases HE was developed after about 2 week after the start of TKI therapy and resolution of symptoms occurred mostly after 24 to 72 hours after stopping treatment and starting of antihyperammonemic therapy (Table 1). In our patient, the presence of hyperammonia and normal liver function supports the hypothesis of drug-induced metabolic encephalopathy.

Actually, he had a limited metastatic load with normal liver and renal tests, and no typical clinical and radiological features of RPLS were present, thus supporting the exclusion of a neurologic drug induced disease. No interactions with liver enzymes were known as the patient did not take any concomitant drugs and is not a drinker. In addition, the very close time relationship between drug administration and the onset of neurological symptoms and their recurrence on regorafenib rechallenge strongly support a causative role of regorafenib. The Naranjo scale suggests a probable adverse drug reaction with a score of 7,^[16] even if a plausible biological explanation for the potential neurotoxicity of regorafenib would remain to be established. An interference of TKIs in cerebral signaling pathways regulated by tyrosine kinases or a distress due to their antiangiogenic action leading to brain suffering in patients with predisposing conditions have been hypothesized as possible mechanisms.^[14] Hyperammonemia without any sign of liver impairment has also been reported in a Japanese study in which sunitinib was administered to a patient affected by GIST; the authors suggested that this AE might be caused, in part, by a vascular disorder related to the antiangiogenic properties of sunitinib.^[17] Anyhow, genetic polymorphisms in pharmacokinetic and pharmacodynamic pathways can also be suggested as a possible cause of this phenomenon.

Our case is the 2nd of HE associated with regorafenib and the 1st case in a patient affected by mCRC. Discontinuation of regorafenib after confirmation of hyperammonemia is strongly recommended; reintroduction of the therapy at lower doses after resolution of symptoms related to HE has to be discouraged.

References

- [1] Grothey A, Van Cutsem E, Sobrero A, et al. Regorafenib monotherapy for previously treated metastatic colorectal cancer (CORRECT): an international, multicenter, randomized, placebo-controlled, phase 3 trial. *Lancet* 2013;381:303–12.
- [2] Kuo JC1, Parakh S, Yip D. Regorafenib-induced hyperammonemic encephalopathy. *J Clin Pharm Ther* 2014;39:446–844.
- [3] Eisenhauer EA, Therasse P, Bogaerts J, et al. New response evaluation criteria in solid tumours: revised RECIST guideline (version 1.1). *Eur J Cancer* 2009;45:228–47.
- [4] Crona DJ, Keisler MD, Walko CM. Regorafenib: a novel multitargeted tyrosine kinase inhibitor for colorectal cancer and gastrointestinal stromal tumors. *Ann Pharmacother* 2013;47:1685–96.
- [5] Roth C, Ferbert A. The posterior reversible encephalopathy syndrome: what's certain, what's new? *Pract Neurol* 2011;11:136–44.
- [6] Liaw CC, Wang HM, Wang CH, et al. Risk of transient hyperammonemic encephalopathy in cancer patients who received continuous infusion 5-fluorouracil with the complication of dehydration and infection. *Anticancer Drugs* 1999;10:275–81.
- [7] Davies SM, Szabo E, Wagner JE, et al. Idiopathic hyperammonemia: a frequently lethal complication of bone marrow transplantation. *Bone Marrow Transplant* 1996;17:1119–25.

- [8] Willson KJ, Nott LM, Broadbridge VT, et al. Hepatic encephalopathy associated with cancer or anticancer therapy. *Gastrointest Cancer Res* 2013;6:11–6.
- [9] Nott L, Price TJ, Pittman K, et al. Hyperammonemia encephalopathy: an important cause of neurological deterioration following chemotherapy. *Leuk Lymphoma* 2007;48:1702–11.
- [10] Chen A, Agarwal N. Reversible posterior leukoencephalopathy syndrome associated with sunitinib. *Intern Med J* 2009;39:341–2.
- [11] Dogan E, Aksoy S, Arslan C, et al. Probable sorafenib-induced reversible encephalopathy in a patient with hepatocellular carcinoma. *Med Oncol* 2010;27:1436–7.
- [12] Myint ZW, Sen JM, Watts NL, et al. Reversible posterior leukoencephalopathy syndrome during regorafenib treatment: a case report and literature review of reversible posterior leukoencephalopathy syndrome associated with multikinase inhibitors. *Clin Colorectal Cancer* 2014;13:127–30.
- [13] Lee NR, Yhim HY, Yim CY, et al. Sunitinib-induced hyperammonemic encephalopathy in gastrointestinal stromal tumors. *Ann Pharmacother* 2011;45:e56.
- [14] Brandi G, De Rosa F, Calzà L, et al. Can the tyrosine kinase inhibitors trigger metabolic encephalopathy in cirrhotic patients? *Liver Int* 2013;33:488–93.
- [15] Shea YF1, Chiu WY, Mok MY, et al. Sunitinib-induced hyperammonaemia in a patient with pancreatic neuroendocrine tumour. *J Clin Pharm Ther* 2013;38:327–9.
- [16] Naranjo CA, Busto U, Sellers EM, et al. A method for estimating the probability of adverse drug reactions. *Clin Pharmacol Ther* 1981;30:239–45.
- [17] Matsumoto K, Sawaki A, Mizuno N, et al. Clinical efficacy and safety of sunitinib after imatinib failure in Japanese patients with gastrointestinal stromal tumor. *Jpn J Clin Oncol* 2011;41:57–62.