

From the Clinic

C1q nephropathy in the setting of granulomatosis with polyangiitis treated with tacrolimus

Granulomatosis with polyangiitis (GPA, formerly known as Wegener's granulomatosis) is a rare necrotizing vasculitis of small and medium-sized blood vessels known to cause inflammation of the respiratory tract (e.g. rhinitis, pulmonary capillaritis) and kidney disease (ranging from microhematuria to rapidly progressive glomerulonephritis) [1]. More than 75% of patients with GPA eventually develop renal involvement which can progress to end-stage renal disease. The classic renal biopsy finding is pauci-immune crescentic or segmental necrotizing glomerulonephritis [1].

We report here a 14-year-old male who presented with a 3-week history of sinusitis, arthralgias, epistaxis, conjunctivitis and a petechial rash over his lower extremities. His laboratory workup was significant for high titer cytoplasmic anti-neutrophil cytoplasmic antibodies (c-ANCA) at 1:640; however, anti-proteinase 3 (PR3) and anti-myeloperoxidase (MPO) antibodies were initially negative. Serologic testing also revealed an elevated ESR at 35 mm/h (35 mm/h), elevated CRP at 52.4 nmol/L (5.5 mg/L), and an elevated rheumatoid factor at 36 kIU/L (36 IU/mL). His initial serum creatinine was 61.88 μ mol/L (0.7 mg/dL), and his urinalysis showed hematuria with no leukocyturia and no proteinuria (random urine protein/creatinine ratio was 0.14). Plasma protein and serum albumin were normal at 77 g/L (7.7 g/dL) and 41 g/L (4.1 g/dL), respectively. He had a pulmonary nodule and right maxillary sinus opacification revealed by radiography. The patient was diagnosed with GPA without significant renal involvement and was started on daily prednisone (0.5 mg/kg/day) and weekly methotrexate (15 mg/m²/week). Monthly cyclophosphamide infusions (750 mg/m² per dose) were initiated soon after due to the severity of the symptoms. Despite 3 months of therapy, however, the patient suffered from worsening arthritis, fatigue, cough, rash and elevation in CRP to 187.6 nmol/L (19.7 mg/L). His prednisone dose was subsequently increased to 1 mg/kg/day. Six months after the onset of symptoms, anti-PR3 antibodies were positive. Concern grew for poor response to the standard therapy given the persistent symptoms and worsening serology despite treatment with steroids, methotrexate and cyclophosphamide for more than a year. Fifteen months after the onset of symptoms, and 1 year after the initiation of therapy, the patient experienced an 8 kg weight loss, fatigue, continued epistaxis and sinusitis, and development of nephrotic-range proteinuria (3400 mg/day). Serum albumin remained normal at 44 g/L (4.4 g/dL). The serum creatinine mildly increased from 53 μ mol/L (0.6 mg/dL) to 70.7 μ mol/L (0.8 mg/dL). A kidney biopsy was performed. Light microscopy revealed 16 glomeruli, with 5 showing segmental sclerosis; 3, global sclerosis; and 1, fibrous crescent (Figure 1A). Immunofluorescence (IF) showed comma-shaped C1q and trace granular IgG deposits in the glomeruli, as well as C3 deposition in the blood vessels (Figure 1B). Electron microscopy (EM) demonstrated focal foot process effacement as

well as focal subendothelial and paramesangial electron dense deposits. Based on these biopsy findings, the patient was diagnosed with C1q nephropathy (C1qN). Given the lack of clinical response to the original therapy, prednisone, methotrexate and cyclophosphamide were discontinued and tacrolimus was started at 1 mg twice daily. Plasmapheresis and rituximab were considered as therapeutic options; however, due to the patient's good response to tacrolimus, these treatments were not performed. A month later, lisinopril was initiated to treat the patient's hypertension.

The patient has been followed for 2 years since diagnosis. After initiation of tacrolimus, an improvement in his pulmonary, musculoskeletal and ophthalmic symptoms was observed. His proteinuria decreased from a peak of 3389 to 598 mg/day (Figure 1C); the c-ANCA titer decreased from a peak of 1:640 to 1:320; and the anti-PR3 antibody titer decreased from a peak of 72 to 62 units.

C1qN was originally defined by Jeanette and Hipp as a disease process characterized by nephrotic-range proteinuria, with kidney biopsy findings demonstrating dominant C1q staining in a predominantly mesangial pattern on IF [2]. The glomeruli may show minimal abnormalities, focal segmental glomerulosclerosis or mesangial proliferation. Widespread effacement of the podocyte foot processes can also be seen on EM. Exclusion criteria for C1qN include evidence of systemic lupus erythematosus, IgA nephropathy or membranoproliferative glomerulonephritis type I [2]. Clinical manifestations can range from relatively benign cases of isolated hematuria or proteinuria to severe cases of nephrotic syndrome, nephritic syndrome or a combination of the two [2]. Very few cases of ANCA-associated vasculitis with C1qN have been reported to date [3, 4], and to our knowledge, C1qN has not been reported specifically in association with anti-PR3-positive GPA. In our patient, we postulate that B-cell activation may have resulted in glomerular immunoglobulin deposition, allowing for binding of C1q to the Fc portion of the IgG antibodies. This case may also represent two concurrent rare diseases in one individual without a causal relationship. Since the overall pathogenesis of C1qN remains incompletely understood, the exact mechanism by which the patient developed C1qN in the background of GPA remains unknown.

According to recent case series reports, most patients with C1qN and steroid-resistant nephrotic syndrome achieved remission with the addition of a calcineurin inhibitor, e.g. cyclosporine or tacrolimus [5]. We hypothesize that in our patient with GPA and C1qN resistant to conventional therapy, treatment with tacrolimus resulted in systemic immunomodulation leading to a decrease in the intensity of the symptoms of systemic autoimmune disease, as well as reduction of proteinuria. Lisinopril likely further assisted in the resolution of proteinuria.

This is the first case to our knowledge of a patient with C1qN associated with GPA, who demonstrated dramatic improvement of his nephrotic-range proteinuria and extra-renal symptoms with tacrolimus. While this represents a rare case of C1qN in the setting of GPA, consideration should be given to this entity in patients with refractory GPA and proteinuria, as these manifestations

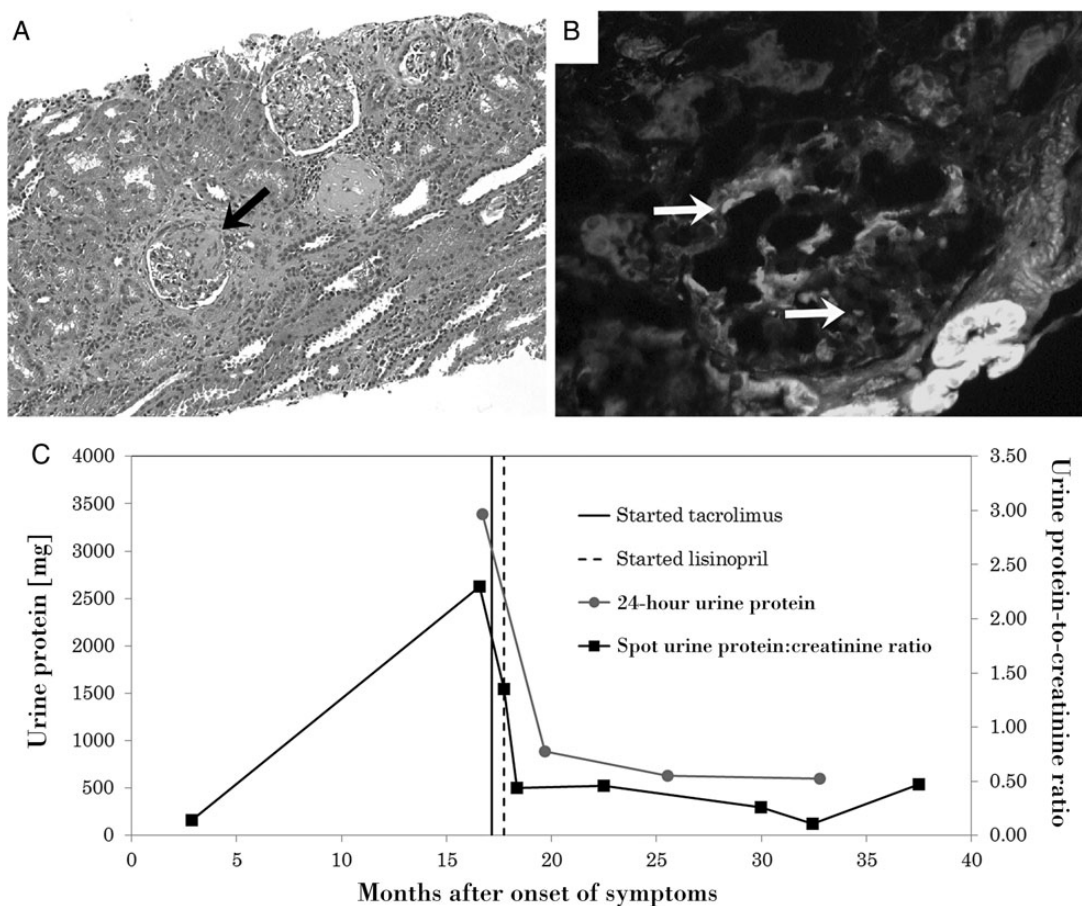


Fig. 1. Renal histological findings and response to treatment with tacrolimus and lisinopril. **(A)** Light microscopy shows focal segmental and global glomerulosclerosis along with varying degrees of interstitial inflammatory infiltrate and fibrosis. Arrow points to segmentally sclerosed glomerulus (hematoxylin and eosin stain $\times 100$). **(B)** Immunofluorescence shows glomerular and mesangial C1q deposits with the classic 'comma-shaped' morphology (white arrows). **(C)** Proteinuria worsened despite treatment with prednisone, methotrexate and cyclophosphamide for over a year. Initiation of tacrolimus and lisinopril resulted in rapid improvement of proteinuria. The decrease in urine protein was also accompanied by a decrease in the severity of systemic GPA symptoms.

could portend a worse prognosis. Moreover, this report suggests that tacrolimus could be considered as a therapeutic option in such cases.

Acknowledgements. The parents of our patient gave consent for this case report.

Conflict of interest statement. The authors declare that the results presented in this paper have not been published previously in whole or in part.

¹Department of Pediatrics, Washington University School of Medicine, St. Louis, MO 63110, USA

²Department of Pathology and Immunology, Washington University School of Medicine, St. Louis, MO 63110, USA

³Department of Pediatrics, Children's National Medical Center, Washington, DC 20010, USA

Correspondence and offprint requests to: Sun-Young Ahn; E-mail: SYAhn@childrensnational.org

Joseph G. Maliakkal¹
Helen Liapis²
Andrew J. White¹
Sun-Young Ahn^{1,3}

References

- Seo P, Stone JH. The antineutrophil cytoplasmic antibody-associated vasculitides. *Am J Med* 2004; 117: 39–50
- Jennette JC, Hippi CG. C1q nephropathy: a distinct pathologic entity usually causing nephrotic syndrome. *Am J Kidney Dis* 1985; 6: 103–110
- Neumann I, Regele H, Kain R *et al.* Glomerular immune deposits are associated with increased proteinuria in patients with ANCA-associated crescentic nephritis. *Nephrol Dial Transplant* 2003; 18: 524–531
- Chen M, Xing GQ, Yu F *et al.* Complement deposition in renal histopathology of patients with ANCA-associated pauci-immune glomerulonephritis. *Nephrol Dial Transplant* 2009; 24: 1247–1252
- Butani L, Ramsamooj R. Experience with tacrolimus in children with steroid-resistant nephrotic syndrome. *Pediatr Nephrol* 2009; 24: 1517–1523

Received for publication: 13.3.14; Accepted in revised form: 11.7.14

doi: 10.1093/ckj/sfu087

Advance Access publication 5 August 2014