

Corrosive upper gastrointestinal strictures in children: Difficulties and dilemmas

Moinak Sen Sarma, Parijat Ram Tripathi, Sachin Arora

ORCID number: Moinak Sen Sarma 0000-0003-2015-4069; Parijat Ram Tripathi 0000-0002-2690-3641; Sachin Arora 0000-0001-7236-555X.

Author contributions: Sarma MS contributed conceptualisation, intellectual inputs, final drafting; Tripathi PR contributed data retrieval, primary manuscript drafting; Arora S contributed intellectual inputs on surgical aspects.

Conflict-of-interest statement: The authors have no conflict of interest for this manuscript.

Open-Access: This article is an open-access article that was selected by an in-house editor and fully peer-reviewed by external reviewers. It is distributed in accordance with the Creative Commons Attribution NonCommercial (CC BY-NC 4.0) license, which permits others to distribute, remix, adapt, build upon this work non-commercially, and license their derivative works on different terms, provided the original work is properly cited and the use is non-commercial. See: <http://creativecommons.org/licenses/by-nc/4.0/>

Specialty type: Pediatrics

Country/Territory of origin: India

Peer-review report's scientific

Moinak Sen Sarma, Department of Pediatric Gastroenterology, Sanjay Gandhi Postgraduate Institute of Medical Sciences, Lucknow 226014, Uttar Pradesh, India

Parijat Ram Tripathi, Department of Pediatric Gastroenterology, Ankura Hospital for Women and Children, Hyderabad 500072, Telangana, India

Sachin Arora, Department of Surgical Gastroenterology, Sanjay Gandhi Postgraduate Institute of Medical Sciences, Lucknow 226014, Uttar Pradesh, India

Corresponding author: Moinak Sen Sarma, MBBS, MD, Associate Professor, Department of Pediatric Gastroenterology, Sanjay Gandhi Postgraduate Institute of Medical Sciences, Lucknow 226014, Uttar Pradesh, India. moinaksen@gmail.com

Abstract

Children constitute 80% of all corrosive ingestion cases. The majority of this burden is contributed by developing countries. Accidental ingestion is common in younger children (< 5 years) while suicidal ingestion is more common in adolescents. The severity of injury depends on nature of corrosive (alkali or acid), pH, amount of ingestion and site of exposure. There are multiple doubts and dilemmas which exist in management of both acute ingestion and chronic complications. Acute ingestion leads to skin, respiratory tract or upper gastrointestinal damage which may range from trivial to life threatening complications. Esophagogastroduodenoscopy is an important early investigation to decide for further course of management. The use of steroids for prevention of stricture is a debatable issue. Upper gastrointestinal stricture is a common long-term sequelae of severe corrosive injury which usually develops after three weeks of ingestion. The cornerstone of management of esophageal strictures is endoscopic bougie or balloon dilatations. In case of resistant strictures, newer adjunctive therapies like intralesional steroids, mitomycin and stents can be utilized along with endoscopic dilatation. Surgery is the final resort for strictures resistant to endoscopic dilatations and adjunctive therapies. There is no consensus on best esophageal replacement conduit. Pyloric strictures require balloon dilatation, failure of which requires surgery. Patients with post-corrosive strictures should be kept in long term follow-up due to significantly increased risk of carcinoma. Despite all the endoscopic and surgical options available, management of corrosive stricture in children is a daunting task due to high chances of recurrence, perforation and complications related to poor nutrition and surgery.

quality classification

Grade A (Excellent): 0
 Grade B (Very good): 0
 Grade C (Good): C
 Grade D (Fair): 0
 Grade E (Poor): 0

Received: February 22, 2021

Peer-review started: February 22, 2021

First decision: June 5, 2021

Revised: July 30, 2021

Accepted: September 19, 2021

Article in press: September 19, 2021

Published online: November 9, 2021

P-Reviewer: Guo JT

S-Editor: Gao CC

L-Editor: A

P-Editor: Yuan YY



Key Words: Corrosive; Stricture; Children; Endoscopic dilatation; Adjunctive therapy; Surgery

©The Author(s) 2021. Published by Baishideng Publishing Group Inc. All rights reserved.

Core Tip: Corrosive ingestion is a life-threatening problem in children. The sequelae are grave and tenacious. There are multiple dilemmas in the acute management of corrosive ingestion. Endoscopic dilatations have challenges and are the cornerstone in management of upper gastrointestinal strictures. Adjunctive therapies may play a pivotal role. Surgery is required in refractory cases.

Citation: Sarma MS, Tripathi PR, Arora S. Corrosive upper gastrointestinal strictures in children: Difficulties and dilemmas. *World J Clin Pediatr* 2021; 10(6): 124-136

URL: <https://www.wjgnet.com/2219-2808/full/v10/i6/124.htm>

DOI: <https://dx.doi.org/10.5409/wjcp.v10.i6.124>

INTRODUCTION

Burden of disease

Corrosive ingestion is one of the commonest causes of upper gastrointestinal strictures in children[1]. Worldwide, children represent 80% of all corrosive substance ingestion cases. The introduction of corrosives as household cleaning purposes has led to a rapid rise in accidental and suicidal ingestion in children. Majority are accidental[2,3] especially in children younger than 5 years who constitute 60%-80% of all pediatric corrosive ingestion cases[4,5]. Corrosives include both acidic and alkali substances. When these caustics come in contact with the skin or mucosa, they lead to variable extents of damage. In developed countries, corrosive injuries have decreased significantly due to strong efforts like childproof containers and biohazard labeling of caustics[6]. In developing countries, these substances are inexpensive, sold across the counter, unlicensed and often unlabeled for biosafety hazards[7]. The issue is worsened by poor literacy and unawareness. When it reaches the consumer, the caustics are stored in empty soft drink bottles and not kept out of reach of the children. Moreover, acid substances are transparent, resembling water. Younger children often fall prey to accidental ingestion out of temptation, curiosity or thirst[4]. As toddlers are verbally non-expressive, accidental ingestions may be unwitnessed and unreported till major symptoms arise. Suicidal and intentional ingestion is usually seen in dysfunctional adolescents with psychosocial trauma or in those with pre-existing psychiatric problems. In suicidal cases, caustic consumption is of large volume and symptoms are masked. Hence the cases present delayed with higher severity. Once acute complications are managed, strictures may develop at any site starting from the oropharynx, laryngeal inlet, esophagus or stomach, depending upon site of maximum contact. Strictures can be single or multiple, short or long and may involve multiple sites (e.g., combined esophageal and pyloric strictures). The overall rate of esophageal stricture formation after caustic ingestion is reported between 2%-63%[4,8,9]. Rate of stricture formation varies with the severity of esophageal injury. Developing countries have mean death rate of 4.1% (0%-11.9%) due to corrosive ingestion[10]. Endoscopic dilatation and surgery are the mainstay for the management of strictures. From the emergency room at the time of first presentation to the management of stricture, there are many dilemmas regarding acute management, optimal timing of endoscopy, choice of dilatation (bougie *vs* balloon), use of adjuvant therapies, need of the surgery and long term prognosis of corrosive strictures. There is a paucity of literature on the management of corrosives in children. Practice varies from center to center with lack of uniformity. Therapeutic protocols or formulating guidelines are not available so far.

CLINICO-PATHOLOGICAL ISSUES

Commonly ingested corrosives are given in Table 1. Clinical manifestations are

Table 1 Commonly ingested corrosives in children

Acid	
Sulfuric acid	Batteries, industrial cleaning agents, metal plating, toilet cleaner
Hydrochloric acid	Solvents, metal cleaners, lime solvents, toilet and drain cleaners, muriatic acid, antirust compounds
Acetic acid	Pickling vinegar, vinegar spirit, wart solution
Phosphoric acid	Toilet cleaners
Oxalic acid	Paint thinners, metal cleaners, toilet cleaner
Alkali	
Sodium hydroxide	Grease/oil cleaners, drain cleaners, sink openers, oven cleaners, oil removers
Potassium hydroxide	Oven cleaners, washing powders, paint remover
Sodium carbonate	Soap manufacturing, fruit drying on farms
Sodium hypochlorite	Household bleaches
Ammonium hydroxide	General cleaner and grease remover
Miscellaneous	
Hydrogen peroxide	Surface and food cleaner
Potassium permanganate	Disinfectants, hair dyes

elaborated in Table 2. Alkaline substances have a higher viscosity, and hence remain in contact with esophageal mucosa for longer periods after ingestion. Alkali causes liquefactive necrosis and penetrate deeper into the tissue. Acids that have lower viscosity reach stomach faster, running along lesser curvature to reach the pylorus where there will be physiological stasis. Acid causes coagulative necrosis and deeper penetration is limited due to the same. Other factors that determine site and severity are chemical properties, contact time, contact surface area and urgency of referral. Many of the times, the nature and volume of corrosives are unclear from the history in children. Acids are available as pungent liquids; hence their intake is limited as soon as it is consumed accidentally. Alkalis are available both as liquids or solids (*e.g.*, soap and detergents). Since alkalis are tasteless, their consumption is higher before the patient realises the mistake. Retained solid alkali causes maximum injury to the oral mucosa, oropharynx and laryngeal inlet and lesser to lower esophagus and stomach. In the stomach, some of the ingested alkali may get partially neutralised by the gastric acid lowering the damage further. Ingestion of caustic after food cause a lesser degree of injury in the stomach due to lesser contact surface. Erroneous emergency interventions such as administering emetics and stomach wash cause repeated exposures of the caustic to the esophagus. Both alkali and acids are known to cause severe esophageal burns[11,12]. Initial corrosive injury causes an inflammatory response followed by thrombosis in arterioles and venules leading to ischemic necrosis [2]. Mucosal sloughing and bacterial invasion develop over four to seven days after ingestion warranting antimicrobial therapy. Granulation tissue and fibrin coat cover the ulcers. Ulcers extending beyond the muscle layer may cause perforation. The esophagus is physiologically devoid of serosa and allows the caustic damage to be exposed to the mediastinum. On day four, fibroblasts are recruited and repair of the damaged mucosa starts at day ten. Stricture usually develops by the third week and completes over the next few months[13]. As collagen deposition usually starts after two weeks, the strength of the injured tissue is poor in the first three weeks, contraindicating any intubation or endoscopic procedures. Spontaneous perforation of esophagus or stomach is usually encountered within the first 2 weeks of corrosive ingestion. From the third week onwards till the next few months, scar retraction leads to stricture formation and shortening of gastrointestinal tract. At this time, the pressure of the lower esophageal sphincter decreases and allows gastroesophageal reflux. Repeated acid exposure accelerates stricture formation[14]. In deeper burns (grade 2b and 3), fibrosis is usually complete by 3-6 mo, finally culminating into a stricture[15]. Strictures are hardly seen in grade 1 esophageal injury. Esophageal stricture rates in grades 2a, 2b and 3 are < 5%, 15%-68% and 75%-90% respectively[16, 17]. Diverticulae and deeper damage in the esophagus may result in tracheo-esophageal fistulae. Contraction of the body of the stomach causes hour glass appearance, decreased capacity and rarely fistulous opening into small or large bowel.

Table 2 Clinical features of corrosive ingestion

Symptoms of acute corrosive ingestion	
Organ system	
Skin	Burning sensation and pain on face, mostly perioral
Respiratory tract	Cough, difficulty in breathing, aphonia or dysphonia, chest pain, cyanosis. Aspiration of large volume of corrosive may lead to endobronchial inflammation, necrosis and mediastinitis
Gastrointestinal tract	Oral burn, hypersalivation, nausea, vomiting (with or without blood), retrosternal and upper abdomen pain, dysphagia. Rarely perforation of gastrointestinal tract may happen and present with abdominal distension, tenderness and rigidity
Symptoms after gastrointestinal stricture formation	
Esophageal	Vomiting, dysphagia, hematemesis, acute obstruction due to food impaction at stricture site, growth failure
Pyloric	Non-bilious stale food vomiting, upper abdominal distension, growth failure

Antropyloric strictures cause gastric outlet obstruction. Proximal duodenal strictures are very rare. Compromise in nutrition leads to cachexia, dyselectrolytemia, apathy and poor quality of life. The above issues lead to a number of complications (Figure 1). Clinical, endoscopic and radiologic pictures of post-corrosive ingestion are shown in Figure 2.

DILEMMAS IN ACUTE CORROSIVE INGESTION MANAGEMENT

The flow chart for management of corrosive ingestion is shown in Figure 3. The first step is always to prioritize airway, breathing and circulation. Patients presenting with respiratory difficulty, dysphonia or aphonia need urgent airway management like endotracheal intubation and ventilation[18]. Urgent steroids are indicated in life-threatening laryngeal edema. However, there are many dilemmas and doubts which arise during acute management as well as while dealing with strictures.

What are the contraindicated practices?

Gastric lavage and induction of vomiting are common practices after accidental ingestion of corrosive[4,5]. In a survey performed recently in India, it was found that 57% of referred cases had history of induced emesis by the primary physicians[5]. Any effort of induced vomiting will lead to re-exposure of esophageal mucosa to the corrosive and increased risk of aspiration. Cold milk ingestion is not useful and may lead to aspiration and obscures an endoscopist's view. Blind insertion of a nasogastric tube for lavage or feeding may lead to mucosal injury and perforation. Another practice that is not recommended is the trial of neutralization with weak acid or base to decrease the effect of corrosive. The reaction of acid and alkali leads to an exothermic reaction which may cause added thermal burn to an already damaged tissue[18].

Is there any role of adjunctive pharmacotherapy?

Patients with grade 1 and 2a injury do not need any specific treatment, can be initiated on oral feeds and monitored closely. Children with grade 2b and 3 injuries need further treatment depending on clinical, endoscopic and radiological severity[7]. Antacids, H2 receptor blockers and proton pump inhibitors (PPIs) are prescribed in acute ingestion but their efficacies are not proven[2,19]. PPI is used in the majority of cases and may help by decreasing acid exposure to damaged tissue and prevention of stress ulcer formation[5]. Sucralfate which needs an acidic medium to activate provides a protective coating over the ulcers and may aid in delaying stricture formation[20]. However, the role of sucralfate in esophageal ulcers, alkali ingestion and in combination with PPI is debatable. There is no consensus as to how long acid suppression should be administered. In a questionnaire survey, it was found that most physicians arbitrarily prefer 4 week of acid suppression[5]. Antibiotics are not routinely prescribed in corrosive ingestion with grade 1 and 2a injuries. Since oral microbiota is a potential source of infection, injuries higher than grade 2b may merit antibiotic therapy. A combination of gram positive (for oral microbiota) and gram negative cover (gastrointestinal microbiota) is optimal. Optimal duration of antibiotic is not defined but it is preferable to use for 1-2 weeks for an uncomplicated injury. Syrups and suspensions are preferred over tablets and capsules. In a suspected or

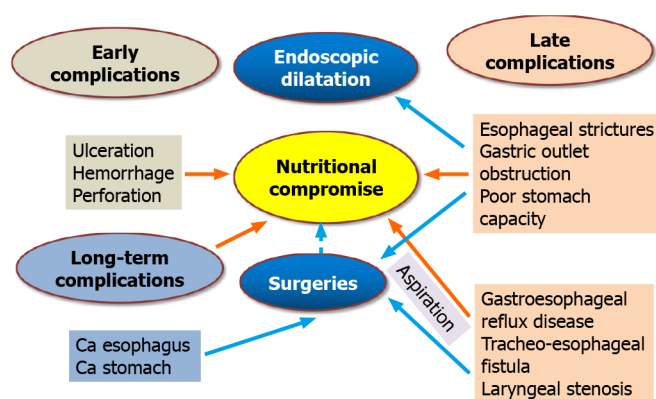


Figure 1 Complications in gastrointestinal system due to corrosive injury.

proven perforation, it would be prudent to add an anaerobic cover. Additional situations meriting antibiotic therapy are aspiration pneumonia, high grade fever and suspected bacteremia[21]. Theoretically, steroids have been potentially considered for use in early post-corrosive ingestion to decrease inflammation and lowering stricture formation. However steroids have not shown consistent improvement in the outcome [22]. In adults, steroids have been associated with higher mortality. In children, an exceptional situation to use steroids is grade 2b injury. Usta *et al*[23] showed in a randomized controlled trial that early use of high dose steroids (1 g/1.73 m² per day for 3 d) in grade 2b injuries lead to decreased stricture formation in follow-up. There is no evidence of improvement in other grades of injuries[7,23].

What is the indication and timing for early endoscopy?

In acute caustic ingestion, esophagogastroduodenoscopy (EGD) is the investigation of choice to ascertain the grade of mucosal injury. Esophageal injury is graded as per Zargar classification[24] as shown in Table 3. Endoscopy is best performed within the first 48-72 h of corrosive ingestion after initial stabilization. After 72 h, the injured areas become soft, edematous and friable. There is an increased risk of perforation during the EGD. EGD should be performed gently preferably with a thin (5.5 mm) endoscope, minimal air insufflation and under proper sedation. Blind advances and biopsies are not recommended. Negotiation beyond a charred esophagus to assess the stomach may be a daunting task. Oral or skin injuries are unreliable indicators of esophageal or stomach injury. In a large retrospective study by Doğan *et al*[25], 61% of children with esophageal injury on EGD had no oral burn. Betalli *et al*[26] in a multicentre study found that severe esophageal burns correlate well with symptoms. Risk of esophageal damage increased only with increasing severity of symptoms and signs. Hence the authors concluded that endoscopy can be avoided in asymptomatic patients with accidental ingestion[26]. European Society of Gastrointestinal Endoscopy and the European Society for Pediatric Gastroenterology Hepatology and Nutrition (ESPGHAN) 2017 guidelines agree, EGD can be withheld if the child is asymptomatic without any oral symptoms (drooling, hypersalivation or oral ulcers). However, in such cases, close vigilance is required for the development of delayed symptoms[7]. EGD is mandatory in adolescents with suicidal intent who may mask symptoms. The real dilemma of endoscopy arises in delayed presentation or referral (after 72 h). Since the tissue is most friable between days 3 to 21, diagnostic endoscopy is best avoided during this period where expertise and resources are limited. In the author's opinion, an endoscopic assessment may be daunting in this period, best reserved for tertiary care centers where appropriate endoscopes and expert endoscopists are available. Questionnaire surveys reveal that 90% prefer endoscopy between days 1-5, 70% agree that it should be deferred between days 6-21 and 50% agree that endoscopists should not venture beyond a charred area[5]. After 3-4 wk, fibrosis fully sets in making it conducive once again for endoscopic assessment of the stricture.

What is the role of radiology in acute management?

Chest X ray is usually performed in an acute setting[5] and may show mediastinal air in case of esophageal perforation. Computed tomography (CT) scan is a non-invasive test and can be used to ascertain the severity of injury and the need for surgery in complicated cases. Lurie *et al*[27] in a study on adult subjects concluded that CT tends to underestimate the severity of corrosive ingestion compared with endoscopy. CT

Table 3 Zargar classification for corrosive esophageal injury

Zargar classification	
Grade 0	Normal examination
Grade 1	Edema and hyperemia of the mucosa
Grade 2	
2a	Friability, hemorrhages, erosions, blisters, whitish membranes, exudates and superficial ulcerations
2b	Grade 2a plus deep discrete or circumferential ulceration
Grade 3	
3a	Multiple ulcerations and areas of necrosis (areas of brown-black or grayish discoloration were taken as evidence of necrosis)
3b	Small scattered areas of necrosis; extensive necrosis

scan had higher specificity but lesser sensitivity in ascertaining severity of injury in acute corrosive ingestion. The sensitivities of endoscopy in grades 2b and 3 injuries to predict mortality and emergency laparotomy were 1 and 0.8 while it was 0.4 and 0.28 for CT scan. The specificities were 0.38 and 0.37 for endoscopy while for CT scan the specificities were 0.94 and 0.93, respectively. CT scan can additionally show pulmonary infiltrates, features of mediastinitis and perforation[27]. A contrast study is carefully considered and performed only if indicated. Barium is ionic, may lead to chemical pneumonitis due to aspiration or tracheoesophageal fistula. Ingestion of barium also limits endoscopy if retained in luminal stasis. Hence a non-ionic contrast is preferred though the quality of study may be poor.

Should a nasogastric tube be preemptively placed for stricture prevention?

The pre-emptive placement of a nasoenteric tube is controversial. Though it may maintain patency of the esophageal lumen, the tube itself could worsen or contribute to complications. The tube may facilitate greater acidic reflux, delay mucosal healing and cause long strictures. Blind insertion could cause esophageal perforation. Should a tight stricture develop, positioning a tube has the advantage of providing a lumen for dilatation. Experimental studies were performed on rabbits with caustic esophageal burns. One group was treated with a silicone tube was placed immediately after causing the burns, while an untreated group was observed for the natural course of the burn. On day 22, an esophagectomy was performed on all animals. Histopathologic Damage Score and wall thickness were similar in both groups. Stenosis Index and lumen diameter were significantly lower in the treated group than the untreated group. It was concluded that an early placement of an intraesophageal tube with a solid dilator prevents stenosis formation and does not produce greater tissue damage [28]. To limit acid reflux it would be prudent to add an acid suppressant in the presence of a nasogastric tube.

What are the difficulties in sustaining nutrition?

Maintaining nutrition is a challenge in the first 3-4 wk. Nutritional compromise is anticipated due to odynophagia, multiple hospital admissions and overcautious management to prevent perforation. Adequate calories should be provided due to a high catabolic state. In rabbits models, it was found that weight gain is significantly higher after 22 d of caustic ingestion in those animals with nasogastric tubes[28]. Nasoenteric tubes must be placed under endoscopic or fluoroscopic vision. A nasojejunal tube is preferred in those with gastric injuries but may be challenging to place endoscopically especially through an inflamed pylorus. A safer alternative is to consider a gastrostomy tube in an isolated esophageal injury and a jejunostomy tube in gastric injury. Energy dense liquid and semisolid feeds are ensured in tube feeding. Parenteral nutrition is rarely required except for the patients with perforation and shock.

DIFFICULTIES IN MANAGEMENT OF CORROSIVE STRICTURES IN CHILDREN

Once the patient develops a symptomatic stricture, serial endoscopic dilatation is the

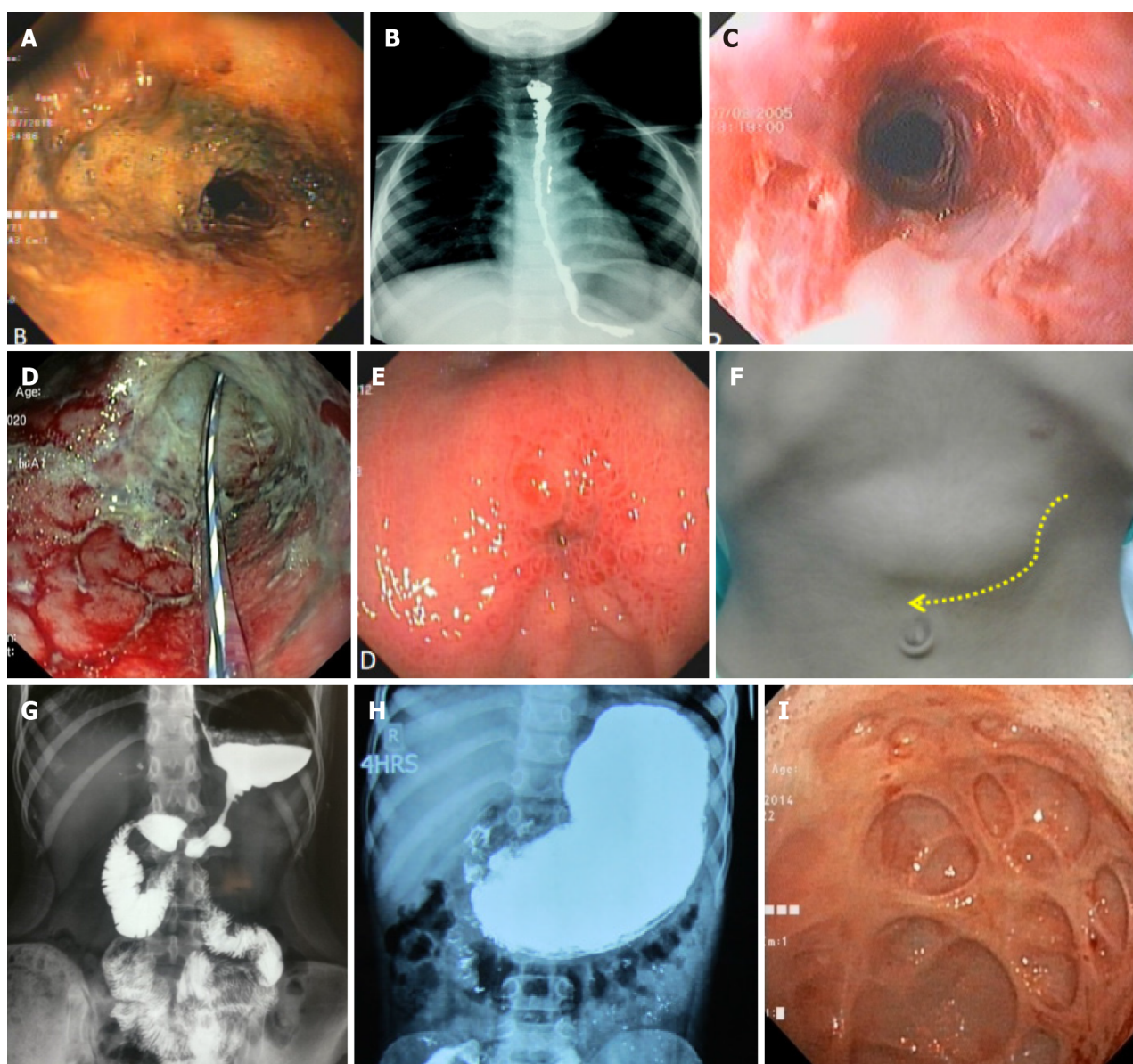


Figure 2 Clinical, endoscopic and radiological images of corrosive injury in children. A: Endoscopic view of corrosive injury of esophagus (areas of necrosis); B: Barium swallow study showing long esophageal stricture; C: Endoscopic view of esophagus after initial healing; D: Endoscopic view of post-acid ingestion antropylic injury with transpyloric tube *in situ*; E: Endoscopic view of pyloric stricture; F: Dilated stomach in a patient with pyloric stricture; G: Barium meal follow-through study showing corrosive stricture involving body and prepyloric region (Hour-glass appearance); H: Barium meal follow through study showing post-corrosive pyloric stricture; I: Endoscopic view of diverticulae in stomach in pyloric stricture.

mainstay of therapy to restore the previous anatomy and preserve the normal physiology. A barium study is indicated as a road map prior to endoscopy. The techniques of endoscopic dilatation are taken on a case-to-case basis depending on length, site, diameter, tortuosity and complexity of the stricture. A combination of thin and regular endoscopes may be required for assessment and procedures. Intubation may be a major issue in those with laryngeal stenosis. Unintubated patients are at significant risk of respiratory compromise during the procedure. Surgical therapy may be required for feeding purposes along with dilatation, to manage complications of endoscopic dilatation like perforation and for strictures resistant to endoscopic dilatation.

Should we use a bougie or balloon for endoscopic dilatation?

Strictures can develop as early as 3 weeks. Endoscopic dilatation is done every 2-3 weekly intervals and numbers of dilatation vary widely depending on the anatomy of the strictures. Endoscopic dilatation should be performed by a trained gastroenterologist under general anesthesia and with surgical backup. The first dilemma faced is, the choice of method for dilatation *i.e.*, bougie *vs* controlled radial expansion (CRE)

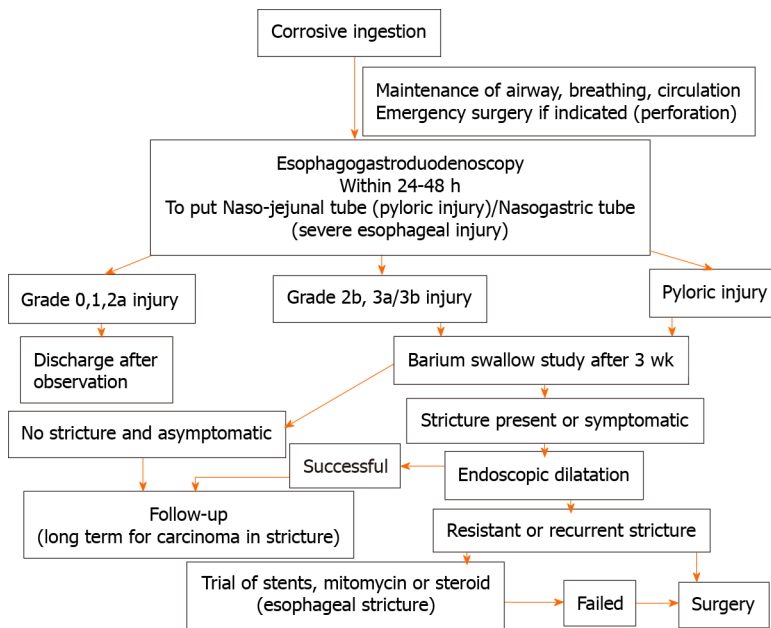


Figure 3 Flowchart for management of corrosive ingestion and upper gastrointestinal strictures.

balloon in an esophageal stricture. Bougie dilates the stricture with a tangential pressure while the CRE balloon asserts a radial pressure over the stricture. Bougie is a better option for multiple or long tortuous strictures while the balloon is preferred for single short strictures[29]. But practically, there are other factors also which influence the final decision like the experience of the endoscopist with both methods, availability of endoscopic accessories and financial constraints[5]. Bougie can be reused multiple times, lowering the overall cost of treatment. There are no head-to-head comparative studies between balloon and bougie. Balloon dilatation is found safe with variable success of 14%-100% [17,30]. Successful dilatation with bougie is 50%-96% [29,31]. It should also be kept in mind that thinner endoscopes have a limited channel length for balloon accessories. Softer guidewires than metallic ones are preferred to negotiate inflamed strictures. In tortuous strictures, optimal positioning of the patient and repeated gentle attempts are required for negotiation. Navigation is often aided by hydrophilic Terumo guidewire. Over the guidewire balloons are preferred if the anatomy of the lumen is uncertain.

Are corrosive esophageal strictures more resistant to dilate?

Of all benign esophageal strictures in children, corrosives are the most challenging to dilate due to the intense fibrosis and complexity. Corrosive strictures require a higher number of sessions of dilatation, have a higher risk of dilatation-related complications and may need surgical therapy more often as compared to other etiologies like post-trachea-esophageal fistula repair and peptic strictures[29,31]. The main complication of dilatation is perforation which is reported from around 2.5% to as high as 50% [31-33]. Other reported complications of dilatation are mediastinitis, lung abscess, empyema, pericardial effusion, sepsis and death.

When should we begin stricture dilatation?

Another dilemma is timing to start dilatation *i.e.* early *vs* late dilatation. Gün *et al* [32] compared patients who underwent early dilatation starting from 3rd week after corrosive ingestion *vs* patients who underwent late dilatation after 6-12 wk of corrosive ingestion. Children with late dilatation of stricture had a poorer response (25% *vs* 65%) along with higher rates of perforation (50% *vs* 21%). None of the patients with late dilatation recovered within 1 year period while 60% with early dilatation improved within the same time period[32]. Patients who are referred late often have a resistant stricture due to extensive fibrosis over time[2]. In a study by Contini *et al* [33], patients who were started on dilatation late (> 6 wk) had recurrence of strictures in 73% *vs* 30% in timely dilatation group ($P < 0.01$).

How to manage refractory esophageal strictures?

ESPGHAN guidelines for endoscopy have defined refractory and recurrent strictures as an anatomic restriction because of cicatricial luminal compromise or fibrosis that results in dysphagia in the absence of endoscopic evidence of inflammation. This may be defined in two clinical settings. Firstly there may be an inability to successfully remediate the anatomic problem to obtain age-appropriate feeding after a maximum of 5 dilation sessions (refractory) with maximal 4-week intervals. Secondly, there may be an inability to maintain a satisfactory luminal diameter for 4 week once the age-appropriate feeding diameter has been achieved (recurrent)[7]. In this subgroup of patients, the following options can be utilized before surgery.

Intralesional steroids: Intralesional steroid injection increases the effect of dilatation by inhibiting inflammatory response to injury, decreases collagen synthesis and cross-linking at the stricture site. Bhan *et al*[34] published data of 32 children with resistant strictures where Triamcinolone acetonide was injected in four quadrants prior to dilatation. 92% of patients with short strictures improved completely. None of the patients with long stricture (> 3 cm) had a resolution of dysphagia and all required esophageal replacement. A meta-analysis of 6 randomized control trials including 176 adult patients with benign esophageal stricture found that intralesional steroid therapy decreased stricture formation rate along with the requirement of endoscopic dilatations without an increase in complications[35].

Mitomycin: Mitomycin is an antineoplastic drug that inhibits cell division and fibroblast proliferation. A mucosal tear during dilatation heals with fibrosis. Hence mitomycin is used to limit this process and augment the effect of dilatation. Mitomycin soaked gauze (0.4 mg/mL) is applied over the stricture after dilatation for 3-4 min[36, 37]. Sweed *et al*[37] compared 18 children who underwent mitomycin injection with dilatation *vs* 12 children with routine dilatation. Results suggested that between the two groups, there were no major differences in the number of dilatations. However, there was a significant improvement in dysphagia in the mitomycin group. In another double-blind, randomized, placebo-controlled trial, the mitomycin group had complete resolution of stricture in 80% of patients as compared to 35% in the non-mitomycin group[38]. Méndez-Nieto *et al*[36] compared patients treated with mitomycin ($n = 16$) with a retrospective cohort of steroid-treated patients ($n = 34$). Mitomycin group required significantly less number of dilatation sessions [4.5 (3-8) *vs* 11 (4-24), $P < 0.01$].

Stents: The use of esophageal stents in children is still evolving and experience is limited. Resistant caustic strictures are the most common indication of stent placement in children[39]. Zhang *et al*[40] used nitinol-alloy self-expanding esophageal stent in eight children (2-12 years). Stents were deployed for 1-4 weeks. Stent migration occurred in one patient while two patients required further dilatation. None of the patients had any severe side effects. The use of stents in children is limited due availability of age-appropriate sizes and significant chances of migration. It is not possible to place stents in patients where stricture starts from the upper esophagus or from the pharyngeal inlet.

ESPGHAN guidelines suggest the use of temporary stent placement or application of topical mitomycin following dilation for refractory esophageal stenosis rather than routine use of intralesional steroids for refractory esophageal stenosis in children. There is a theoretical possibility of induction of dysplasia after mitomycin application although there is no proven evidence yet[7].

When is surgery indicated in esophageal strictures?

Surgery is the last resort for recurrent or refractory corrosive esophageal strictures. The optimal time for reconstruction is 6-12 mo post corrosive ingestion. The waiting period is beneficial for the final arrest of the progression of stricture (length, level and tenacity) and optimization of nutritional status. The major controversy in the surgical management of corrosive esophageal stricture is resection *vs* bypass. Currently majority of the surgeons prefer bypass since there is a lesser incidence of malignancy in the residual esophagus and lesser morbidity and mortality as compared to resection. Choices of esophageal replacement are gastric advancement/pull-up, colonic interposition and jejunal interposition. There is no consensus on the ideal replacement for the esophagus. The jejunum is not a preferred conduit because of its limited length. Free jejunal grafts may be used to bridge short defects after excision of localized esophageal stricture. Colonic interposition is a complex surgery requiring multiple anastomoses and affected by issues such as colonic redundancy. However,

colon is a favourable option because of the abundant vascularity and space of the lumen. Two options in colonic interposition are a right colon or a left colon conduit. The choice between these two is still debated. Gastric pull-up is comparatively a simpler surgery but it is dependent on the availability of a healthy stomach which may be partially involved or difficult to assess in corrosive ingestion. Routes available for conduit placement are posterior mediastinum, retrosternal and subcutaneous. The subcutaneous route is less preferred because of poor cosmesis. The retrosternal route is most commonly used in corrosive esophageal stricture as the native esophagus is left in situ. Colonic and gastric replacements both have shown good outcomes [21,41,42]. Studies have shown that there are no significant differences in terms of early complications (cervical anastomotic leaks, vocal cord palsy, and pulmonary complications) in colonic interposition or gastric pull-up[43]. Long term outcomes of these two procedures are also comparable. Overall complications of surgery include anastomotic leak, wound infection, graft redundancy, conduit failure and anastomotic strictures. Endoscopic dilatation may be required for anastomotic strictures[41,44].

What are the challenges in pyloric stricture management?

Acute caustic ingestion causes pylorospasm which increases the duration of contact in antrum and pylorus leading to antropyloric strictures. Adequate gastric decompression is recommended prior to endoscopy to reduce the volume of retained gastric juices. Antral strictures may appear as a pseudopylorus. In the authors' experience, an abnormally dilated stomach alters the usual endoscopic technique of negotiation along the lesser curvature to reach the pylorus. In a contracted stomach, pyloric strictures are often superiorly and eccentrically located than the usual position of pylorus surrounded by a "bird feet appearance" around the narrowing. These strictures are best identified on retroflexion with right-ward deflection of the endoscope. Multiple diverticulae are often misleading in identifying the real pyloric stricture, especially if the lumen is pin-hole in caliber. Blind negotiation of the guidewire may be catastrophic. In the first endoscopy, considerable attempts may be required to negotiate the guidewire. Increased friability of mucosa may lead to considerable bleeding and further edema of the opening. Balloon dilatation is the primary endoscopic procedure of choice. In very narrow strictures, a graded dilatation with biliary balloons is followed by CRE balloons. Unlike esophageal strictures, the bougie is not an option for pyloric strictures and there is limited experience with other adjunctive therapies like steroid and mitomycin in children. In earlier days, surgery was the primary mode of treatment for pyloric strictures. Various surgical options are gastro-jejunostomy with or without vagotomy, pyloroplasty, or antrectomy with Bilroth I anastomosis[45]. One important consideration is that retrocolic gastrojejunostomy should be avoided as it increases the technical difficulty or sometimes it precludes future colonic bypass by interfering with the middle colic vascular arcade. Patients may require repeat surgery due to anastomotic stricture although the incidence is low and patients do well in long term follow up[46,47].

With increasing endoscopic experience, surgery can be avoided especially if successive endoscopic dilatation attempts are successful[48]. This ensures restoration of normal anatomy and sustenance of the physiological outflow.

LONG TERM GASTROINTESTINAL COMPLICATIONS

There are a few other sequelae of corrosive ingestion which increase morbidity in addition to stricture formation.

Gastro-esophageal reflux disease

Cicatriziation due to fibrosis in the esophagus leads to gastroesophageal reflux disease. Repeated acid exposure may lead to additional peptic stricture. These subgroups of patients require long term acid suppression for successful endoscopic dilatation[49].

Dysmotility

Corrosive injury and resulting fibrosis may damage the enteric plexus in the esophagus and stomach leading to esophageal dysmotility and gastroparesis respectively. Cicatrized stomach leads to issues of gastric accommodation and antral milling effect of chyme. These complications add to the existing symptoms of dysphagia, gastric outlet obstruction and may lead to persistence of symptoms even after adequate dilatation[50].

Risk of neoplasia

The incidence of esophageal carcinoma can be significantly higher in patients with corrosive ingestion as compared to the general population[51]. Carcinoma develops mostly at the site of stricture. Endoscopic dilatation or surgery does not prevent the development of carcinoma. Development of carcinoma may range anywhere from 1 to 7 decades after corrosive ingestion[52]. Change or onset of new symptoms in a patient with the past history of corrosive ingestion may be an indicator of carcinoma esophagus.

CONCLUSION

Corrosive ingestion is a common and preventable cause of esophageal and gastric injury in children. Development of stricture in the upper gastrointestinal tract is associated with prolonged morbidity, the need for long-term therapy and procedure-related complications affecting the quality of life in children. Despite many daunts and dilemmas in management, the clinical outcome is generally rewarding with endoscopic dilatations. Newer adjunctive therapies may decrease the need for surgery although for resistant and recurrent strictures. Even after the resolution of symptoms these patients should be kept on long-term follow-up. There is a need for further large volume studies regarding the efficacy and safety of newer adjunctive therapies. Long-term follow-up studies are required to evaluate stricture and management-related complications in children.

REFERENCES

- 1 **Vandenplas Y.** Management of Benign Esophageal Strictures in Children. *Pediatr Gastroenterol Hepatol Nutr* 2017; **20**: 211-215 [PMID: 29302501 DOI: 10.5223/pghn.2017.20.4.211]
- 2 **Contini S, Scarpignato C.** Caustic injury of the upper gastrointestinal tract: a comprehensive review. *World J Gastroenterol* 2013; **19**: 3918-3930 [PMID: 23840136 DOI: 10.3748/wjg.v19.i25.3918]
- 3 **Hall AH, Jacquemin D, Henny D, Mathieu L, Josset P, Meyer B.** Corrosive substances ingestion: a review. *Crit Rev Toxicol* 2019; **49**: 637-669 [PMID: 32009535 DOI: 10.1080/10408444.2019.1707773]
- 4 **Urganci N, Usta M, Kalyoncu D, Demirel E.** Corrosive substance ingestion in children. *Indian J Pediatr* 2014; **81**: 675-679 [PMID: 23918323 DOI: 10.1007/s12098-013-1170-0]
- 5 **Bolia R, Sarma MS, Biradar V, Sathiyasekaran M, Srivastava A.** Current practices in the management of corrosive ingestion in children: A questionnaire-based survey and recommendations. *Indian J Gastroenterol* 2021; **40**: 316-325 [PMID: 33991312 DOI: 10.1007/s12664-021-01153-z]
- 6 **Johnson CM, Brigger MT.** The public health impact of pediatric caustic ingestion injuries. *Arch Otolaryngol Head Neck Surg* 2012; **138**: 1111-1115 [PMID: 23247229 DOI: 10.1001/jamaoto.2013.672]
- 7 **Thomson M, Tringali A, Dumonceau JM, Tavares M, Tabbers MM, Furlano R, Spaander M, Hassan C, Tzvinikos C, Ijsselstijn H, Viala J, Dall'Oglio L, Benninga M, Orel R, Vandenplas Y, Keil R, Romano C, Brownstone E, Hlava Š, Gerner P, Dolak W, Landi R, Huber WD, Everett S, Vecsei A, Aabakken L, Amil-Dias J, Zambelli A.** Paediatric Gastrointestinal Endoscopy: European Society for Paediatric Gastroenterology Hepatology and Nutrition and European Society of Gastrointestinal Endoscopy Guidelines. *J Pediatr Gastroenterol Nutr* 2017; **64**: 133-153 [PMID: 27622898 DOI: 10.1097/MPG.0000000000001408]
- 8 **Karaman İ, Koç O, Karaman A, Erdoğan D, Çavuşoğlu YH, Afşarlar ÇE, Yılmaz E, Ertürk A, Balci Ö, Özgüner IF.** Evaluation of 968 children with corrosive substance ingestion. *Indian J Crit Care Med* 2015; **19**: 714-718 [PMID: 26813230 DOI: 10.4103/0972-5229.171377]
- 9 **Geng LL, Liang CP, Chen PY, Wu Q, Yang M, Li HW, Xu ZH, Ren L, Wang HL, Cheng S, Xu WF, Chen Y, Zhang C, Liu LY, Li DY, Gong ST.** Long-Term Outcomes of Caustic Esophageal Stricture with Endoscopic Balloon Dilatation in Chinese Children. *Gastroenterol Res Pract* 2018; **2018**: 8352756 [PMID: 30158970 DOI: 10.1155/2018/8352756]
- 10 **Contini S, Swarray-Deen A, Scarpignato C.** Oesophageal corrosive injuries in children: a forgotten social and health challenge in developing countries. *Bull World Health Organ* 2009; **87**: 950-954 [PMID: 20454486 DOI: 10.2471/BLT.08.058065]
- 11 **Zargar SA, Kochhar R, Nagi B, Mehta S, Mehta SK.** Ingestion of corrosive acids. Spectrum of injury to upper gastrointestinal tract and natural history. *Gastroenterology* 1989; **97**: 702-707 [PMID: 2753330 DOI: 10.1016/0016-5085(89)90641-0]
- 12 **Zargar SA, Kochhar R, Nagi B, Mehta S, Mehta SK.** Ingestion of strong corrosive alkalis: spectrum of injury to upper gastrointestinal tract and natural history. *Am J Gastroenterol* 1992; **87**: 337-341 [PMID: 1539568]
- 13 **Osman M, Russell J, Shukla D, Moghadamfalahi M, Granger DN.** Responses of the murine

- esophageal microcirculation to acute exposure to alkali, acid, or hypochlorite. *J Pediatr Surg* 2008; **43**: 1672-1678 [PMID: 18779005 DOI: 10.1016/j.jpedsurg.2008.01.069]
- 14 **Mutaf O**, Genç A, Herek O, Demircan M, Ozcan C, Arıkan A. Gastroesophageal reflux: a determinant in the outcome of caustic esophageal burns. *J Pediatr Surg* 1996; **31**: 1494-1495 [PMID: 8943108 DOI: 10.1016/s0022-3468(96)90163-3]
 - 15 **Kalayarasan R**, Ananthakrishnan N, Kate V. Corrosive Ingestion. *Indian J Crit Care Med* 2019; **23**: S282-S286 [PMID: 32021005 DOI: 10.5005/jp-journals-10071-23305]
 - 16 **Temiz A**, Oguzkurt P, Ezer SS, Ince E, Hicsonmez A. Long-term management of corrosive esophageal stricture with balloon dilation in children. *Surg Endosc* 2010; **24**: 2287-2292 [PMID: 20177917 DOI: 10.1007/s00464-010-0953-x]
 - 17 **Taşkinlar H**, Bahadır GB, Yiğit D, Erdoğan C, Avlan D, Nayci A. Effectiveness of endoscopic balloon dilatation in grade 2a and 2b esophageal burns in children. *Minim Invasive Ther Allied Technol* 2017; **26**: 300-306 [PMID: 28281403 DOI: 10.1080/13645706.2017.1298621]
 - 18 **Goussard P**, Mfingwana L, Morrison J, Ismail Z, Wagenaar R, Janson J. Corrosive injury of the trachea in children. *Clin Case Rep* 2019; **7**: 1999-2003 [PMID: 31624626 DOI: 10.1002/ccr3.2395]
 - 19 **Rafeey M**, Ghajazadeh M, Sheikhi S, Vahedi L. Caustic Ingestion in Children: a Systematic Review and Meta-Analysis. *J Caring Sci* 2016; **5**: 251-265 [PMID: 27757390 DOI: 10.15171/jcs.2016.027]
 - 20 **Hoffman RS**, Burns MM, Gosselin S. Ingestion of Caustic Substances. *N Engl J Med* 2020; **382**: 1739-1748 [PMID: 32348645 DOI: 10.1056/NEJMr1810769]
 - 21 **Arnold M**, Numanoglu A. Caustic ingestion in children-A review. *Semin Pediatr Surg* 2017; **26**: 95-104 [PMID: 28550877 DOI: 10.1053/j.sempedsurg.2017.02.002]
 - 22 **Fulton JA**, Hoffman RS. Steroids in second degree caustic burns of the esophagus: a systematic pooled analysis of fifty years of human data: 1956-2006. *Clin Toxicol (Phila)* 2007; **45**: 402-408 [PMID: 17486482 DOI: 10.1080/15563650701285420]
 - 23 **Usta M**, Erkan T, Cokugras FC, Urganci N, Onal Z, Gulcan M, Kutlu T. High doses of methylprednisolone in the management of caustic esophageal burns. *Pediatrics* 2014; **133**: E1518-E1524 [PMID: 24864182 DOI: 10.1542/peds.2013-3331]
 - 24 **Zargar SA**, Kochhar R, Mehta S, Mehta SK. The role of fiberoptic endoscopy in the management of corrosive ingestion and modified endoscopic classification of burns. *Gastrointest Endosc* 1991; **37**: 165-169 [PMID: 2032601 DOI: 10.1016/s0016-5107(91)70678-0]
 - 25 **Doğan Y**, Erkan T, Cokuğraş FC, Kutlu T. Caustic gastroesophageal lesions in childhood: an analysis of 473 cases. *Clin Pediatr (Phila)* 2006; **45**: 435-438 [PMID: 16891276 DOI: 10.1177/0009922806289618]
 - 26 **Betalli P**, Falchetti D, Giuliani S, Pane A, Dall'Oglio L, de Angelis GL, Caldore M, Romano C, Gamba P, Baldo V; Caustic Ingestion Italian Study Group. Caustic ingestion in children: is endoscopy always indicated? *Gastrointest Endosc* 2008; **68**: 434-439 [PMID: 18448103 DOI: 10.1016/j.gie.2008.02.016]
 - 27 **Lurie Y**, Slotky M, Fischer D, Shreter R, Bentur Y. The role of chest and abdominal computed tomography in assessing the severity of acute corrosive ingestion. *Clin Toxicol (Phila)* 2013; **51**: 834-837 [PMID: 24032468 DOI: 10.3109/15563650.2013.837171]
 - 28 **Defagó V**, Moyano J, Bernhardt C, Sambuelli G, Cuestas E. Protective effect of early placement of nasogastric tube with solid dilator on tissue damage and stricture formation after caustic esophageal burns in rabbits. *J Pediatr Surg* 2015; **50**: 1264-1268 [PMID: 25783296 DOI: 10.1016/j.jpedsurg.2014.11.040]
 - 29 **Poddar U**, Thapa BR. Benign esophageal strictures in infants and children: results of Savary-Gilliard bougie dilation in 107 Indian children. *Gastrointest Endosc* 2001; **54**: 480-484 [PMID: 11577311 DOI: 10.1067/mge.2001.118253]
 - 30 **Youn BJ**, Kim WS, Cheon JE, Kim WY, Shin SM, Kim IO, Yeon KM. Balloon dilatation for corrosive esophageal strictures in children: radiologic and clinical outcomes. *Korean J Radiol* 2010; **11**: 203-210 [PMID: 20191068 DOI: 10.3348/kjr.2010.11.2.203]
 - 31 **Lakhdar-Idrissi M**, Khabbache K, Hida M. Esophageal endoscopic dilations. *J Pediatr Gastroenterol Nutr* 2012; **54**: 744-747 [PMID: 22270040 DOI: 10.1097/MPG.0b013e31824b16b2]
 - 32 **Gün F**, Abbasoğlu L, Celik A, Salman ET. Early and late term management in caustic ingestion in children: a 16-year experience. *Acta Chir Belg* 2007; **107**: 49-52 [PMID: 17405598 DOI: 10.1080/00015458.2007.11680010]
 - 33 **Contini S**, Garatti M, Swarray-Deen A, Depetris N, Cecchini S, Scarpignato C. Corrosive oesophageal strictures in children: outcomes after timely or delayed dilatation. *Dig Liver Dis* 2009; **41**: 263-268 [PMID: 18801710 DOI: 10.1016/j.dld.2008.07.319]
 - 34 **Bhan MK**, Khoshoo V, Chowdhary D, Jain R, Raj P, Jayashree S, Kumar R. Increased faecal alpha-1-antitrypsin excretion in children with persistent diarrhoea associated with enteric pathogens. *Acta Paediatr Scand* 1989; **78**: 265-267 [PMID: 2784616 DOI: 10.1097/SLE.0000000000000351]
 - 35 **Zhang YW**, Wei FX, Qi XP, Liu Z, Xu XD, Zhang YC. Efficacy and Safety of Endoscopic Intralesional Triamcinolone Injection for Benign Esophageal Strictures. *Gastroenterol Res Pract* 2018; **2018**: 7619298 [PMID: 30158968 DOI: 10.1155/2018/7619298]
 - 36 **Méndez-Nieto CM**, Zarate-Mondragón F, Ramírez-Mayans J, Flores-Flores M. Topical mitomycin C vs intralesional triamcinolone in the management of esophageal stricture due to caustic ingestion. *Rev Gastroenterol Mex* 2015; **80**: 248-254 [PMID: 26455483 DOI: 10.1016/j.rgmx.2015.07.006]
 - 37 **Sweed AS**, Fawaz SA, Ezzat WF, Sabri SM. A prospective controlled study to assess the use of mitomycin C in improving the results of esophageal dilatation in post corrosive esophageal stricture in

- children. *Int J Pediatr Otorhinolaryngol* 2015; **79**: 23-25 [PMID: [25465445](#) DOI: [10.1016/j.ijporl.2014.10.024](#)]
- 38 **El-Asmar KM**, Hassan MA, Abdelkader HM, Hamza AF. Topical mitomycin C application is effective in management of localized caustic esophageal stricture: a double-blinded, randomized, placebo-controlled trial. *J Pediatr Surg* 2013; **48**: 1621-1627 [PMID: [23895984](#) DOI: [10.1016/j.jpedsurg.2013.04.014](#)]
- 39 **Kramer RE**, Quiros JA. Esophageal stents for severe strictures in young children: experience, benefits, and risk. *Curr Gastroenterol Rep* 2010; **12**: 203-210 [PMID: [20425474](#) DOI: [10.1007/s11894-010-0105-4](#)]
- 40 **Zhang C**, Yu JM, Fan GP, Shi CR, Yu SY, Wang HP, Ge L, Zhong WX. The use of a retrievable self-expanding stent in treating childhood benign esophageal strictures. *J Pediatr Surg* 2005; **40**: 501-504 [PMID: [15793725](#) DOI: [10.1016/j.jpedsurg.2004.11.041](#)]
- 41 **ul-Haq A**, Tareen F, Bader I, Burki T, Khan NU. Oesophageal replacement in children with indolent stricture of the oesophagus. *Asian J Surg* 2006; **29**: 17-21 [PMID: [16428092](#) DOI: [10.1016/s1015-9584\(09\)60287-6](#)]
- 42 **Soccorso G**, Parikh DH. Esophageal replacement in children: Challenges and long-term outcomes. *J Indian Assoc Pediatr Surg* 2016; **21**: 98-105 [PMID: [27365900](#) DOI: [10.4103/0971-9261.182580](#)]
- 43 **Javed A**, Pal S, Dash NR, Sahni P, Chattopadhyay TK. Outcome following surgical management of corrosive strictures of the esophagus. *Ann Surg* 2011; **254**: 62-66 [PMID: [21532530](#) DOI: [10.1097/SLA.0b013e3182125ce7](#)]
- 44 **Coopman S**, Michaud L, Halna-Tamine M, Bonneville M, Bourgeois B, Turck D, Gottrand F. Long-term outcome of colon interposition after esophagectomy in children. *J Pediatr Gastroenterol Nutr* 2008; **47**: 458-462 [PMID: [18852638](#) DOI: [10.1097/MPG.0b013e31815ce55c](#)]
- 45 **El-Asmar KM**, Allam AM. Surgical management of corrosive-induced gastric injury in children: 10years' experience. *J Pediatr Surg* 2018; **53**: 744-747 [PMID: [28576428](#) DOI: [10.1016/j.jpedsurg.2017.05.014](#)]
- 46 **Ozokutan BH**, Ceylan H, Ertaşkin I, Yapici S. Pediatric gastric outlet obstruction following corrosive ingestion. *Pediatr Surg Int* 2010; **26**: 615-618 [PMID: [20443118](#) DOI: [10.1007/s00383-010-2613-6](#)]
- 47 **Temiz A**, Oguzkurt P, Ezer SS, Ince E, Gezer HO, Hicsonmez A. Management of pyloric stricture in children: endoscopic balloon dilatation and surgery. *Surg Endosc* 2012; **26**: 1903-1908 [PMID: [22234589](#) DOI: [10.1007/s00464-011-2124-0](#)]
- 48 **Shukla RM**, Mukhopadhyay M, Tripathy BB, Mandal KC, Mukhopadhyay B. Pyloric and antral strictures following corrosive acid ingestion: A report of four cases. *J Indian Assoc Pediatr Surg* 2010; **15**: 108-109 [PMID: [21124669](#) DOI: [10.4103/0971-9261.71749](#)]
- 49 **Park KS**. Evaluation and management of caustic injuries from ingestion of Acid or alkaline substances. *Clin Endosc* 2014; **47**: 301-307 [PMID: [25133115](#) DOI: [10.5946/ce.2014.47.4.301](#)]
- 50 **Genç A**, Mutaf O. Esophageal motility changes in acute and late periods of caustic esophageal burns and their relation to prognosis in children. *J Pediatr Surg* 2002; **37**: 1526-1528 [PMID: [12407532](#) DOI: [10.1053/jpsu.2002.36177](#)]
- 51 **Kiviranta UK**. Corrosion carcinoma of the esophagus; 381 cases of corrosion and nine cases of corrosion carcinoma. *Acta Otolaryngol* 1952; **42**: 89-95 [PMID: [14932967](#) DOI: [10.3109/00016485209120330](#)]
- 52 **Appelqvist P**, Salmo M. Lye corrosion carcinoma of the esophagus: a review of 63 cases. *Cancer* 1980; **45**: 2655-2658 [PMID: [7378999](#) DOI: [10.1002/1097-0142\(19800515\)45:10<2655::aid-cnrcr2820451028>3.0.co;2-p](#)]



Published by **Baishideng Publishing Group Inc**
7041 Koll Center Parkway, Suite 160, Pleasanton, CA 94566, USA

Telephone: +1-925-3991568

E-mail: bpgoffice@wjgnet.com

Help Desk: <https://www.f6publishing.com/helpdesk>

<https://www.wjgnet.com>

