



Diffuse primary cutaneous infection by *Alternaria alternata* in a liver transplant recipient with pulmonary nocardiosis: Importance of prompt identification for clinical resolution

Caterina Campoli^a, Sara Ferraro^b, Nunzio Salfi^{c,d}, Simona Coladonato^a, Maria Cristina Morelli^e, Maddalena Giannella^a, Simone Ambretti^b, Pier Luigi Viale^a, Monica Cricca^{f,*}

^a Infectious Diseases Unit, Department of Medical and Surgical Sciences, Sant'Orsola Malpighi Hospital, University of Bologna, Via Massarenti 9, Bologna, Italy

^b Operative Unit of Clinical Microbiology, Policlinico Sant'Orsola Malpighi, Via Massarenti 9, 40138, Bologna, Italy

^c Histopathology Unit, S. Orsola-Malpighi Hospital, Via Massarenti 9, 40138, Bologna, Italy

^d Pathology Unit, Giannina Gaslini Children's Research Hospital, Via Gerolamo Gaslini 5, 16147, Genova, Italy

^e Department for Care of Organ Failures and Transplants, Internal Medicine for the Treatment of Severe Organ Failures, Policlinico Sant'Orsola Malpighi, Via Massarenti 9, 40138, Bologna, Italy

^f Department of Experimental, Diagnostic and Specialty Medicine, Alma Mater Studiorum, University of Bologna, Via Massarenti 9, 40138, Bologna, Italy



ARTICLE INFO

Keywords:

Alternaria alternata
Phaeohyphomycosis
Nocardiosis
Liver transplantation
Immunocompromised host

ABSTRACT

Fungal infections are rare in the general population but are an emerging cause of disease in immunosuppressed patients, especially solid organ transplant recipients. Here, we report the case of a female Caucasian liver transplant patient who developed pulmonary nocardiosis two months after an episode of liver rejection. At the time of lung nocardiosis, she was being treated with tacrolimus and corticosteroids and suffered from diffuse papular skin lesions. She was initially suspected of having a cutaneous nocardial infection but culture examination revealed the presence of a dematiaceous fungus; *Alternaria alternata*. The prompt identification of the fungus and administration of oral Voriconazole resolved the skin infection with complete remission.

1. Introduction

Nocardia is an increasingly important opportunistic pathogen in immunosuppressed patients, such as solid organ transplant (SOT) recipients [1]. Independent risk factors for this infection are high-doses of steroids, a history of cytomegalovirus infection, and high dosages of calcineurin inhibitors [2]. *Nocardia* most commonly affects the lungs but dissemination to other organs, especially the central nervous system and skin, occurs in up to 40% of transplant recipients [3]. Trimethoprim and sulfamethoxazole are the first-line treatment for *Nocardia* infections, and combination therapy with at least two antimicrobial agents is recommended for disseminated or severe nocardiosis [4]. Corticosteroid therapy and SOT are also important predisposing factors for phaeohyphomycosis by dematiaceous fungi. The list of dematiaceous fungi implicated in cutaneous and subcutaneous infections is growing longer, in line with the availability of more sophisticated methods of identification, the rising number of immunosuppressed patients and climate change. *Alternaria spp.* are the pathogens most frequently isolated from transplant recipients [5]. Solitary lesions are

easily treated with surgery, but larger or multiple lesions may require lengthy medical treatment with azole drugs combined with surgery and modification of immunosuppressive medication [6]. At present, no standardized therapies are available [7], however azoles demonstrate the most consistent activity against this group of fungi [8].

2. Case presentation

In April 2018 a 56-year-old Caucasian female patient was admitted to Riuniti Hospital, Reggio Calabria, Italy, for jaundice and elevated liver enzymes. The patient had a clinical history of liver transplantation in 1999 due to fulminant HBV-hepatitis. Bolus injection of corticosteroid was started on day -57 (1g then tapering) to tackle liver rejection. In June 2018, on day + 1, the patient presented at the Emergency Department, Sant'Orsola Malpighi Hospital, Bologna, Italy, with intense asthenia and hypotension. Electrocardiography showed atrial fibrillation and a chest X-Ray revealed a triangular lung lesion, so a CT-scan was performed. There was no evidence of pulmonary embolism but an excavated lesion with a halo sign was documented (Fig. 1). No

* Corresponding author.

E-mail address: monica.cricca3@unibo.it (M. Cricca).

<https://doi.org/10.1016/j.mmcr.2020.04.007>

Received 23 March 2020; Received in revised form 19 April 2020; Accepted 21 April 2020

Available online 04 May 2020

2211-7539/ © 2020 The Authors. Published by Elsevier B.V. on behalf of International Society for Human and Animal Mycology. This is an open access article under the CC BY-NC-ND license (<http://creativecommons.org/licenses/by-nc-nd/4.0/>).

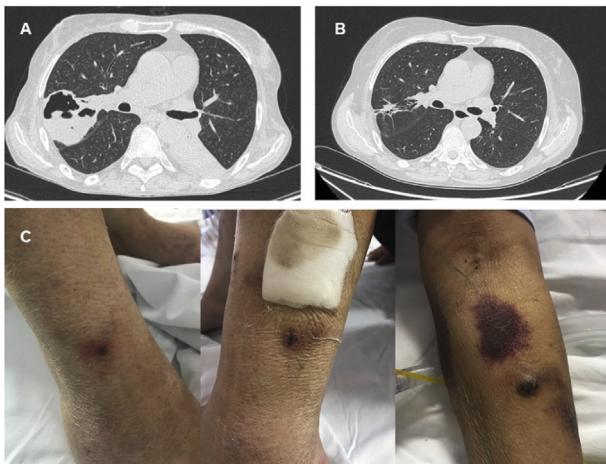


Fig. 1. CT scan images. At +57 days (A) an excavated lesion was noted on CT scan image. Complete resolution was observed after nine months (B). Subcutaneous multiple nodular and erythematous lesions due to *Alternaria alternata* (C). Some of them had shallow ulceration and were spontaneously painful.

pathological findings were reported for the brain CT-scan. On physical examination the patient also had various papular pigmented cutaneous lesions all over the body in particular on her limbs. Some of the lesions had shallow, painful ulcerations (Fig. 1). One lesion on her right hand needed local debridement.

On day + 2 she underwent flexible bronchoscopy and bronchoalveolar lavage (BAL). Tuberculosis was excluded by Xpert MTB/RIF Ultra assay (Ultra, Cepheid, Sunnyvale, USA) and then by culture. Both direct microscopic examination, after 10% KOH digestion and calcofluor staining, and BAL cultures excluded the presence of filamentous fungi. Galactomannan was negative (GM Index 0.070) as was blood culture.

The patient developed cytomegalovirus (CMV) viremia **on day + 4** and was treated with valgancyclovir until undetectable blood levels were documented (**day + 35**). BAL culture was positive for *Nocardia cyriacogeorgica* (**day + 10**), identified using MALDI-TOF MS (MALDI Biotyper Instrument, Bruker Daltonics, Germany). Susceptibility testing was performed using serial 2-fold microdilution in Mueller-Hinton broth, as recommended by the National Committee for Clinical Laboratory Standards. *Nocardia cyriacogeorgica* was sensitive to Cefotaxime, Linezolid, Amikacin, co-trimoxazole and intermediate to Amoxicillin/Clavulanic Acid and Ciprofloxacin. **On day + 12** treatment with linezolid (600 mg twice daily) was started, but then switched to co-trimoxazole (1600/320 mg twice daily) for moderate anemia requiring hemotransfusion (**day + 29**). In the end we decided to continue with ceftriaxone 2 g/day iv in single daily dose (**day + 41**) due to further myelotoxicity.

On day + 13 the patient had new-onset mitral insufficiency due to chordae tendinae rupture (II grade), with no vegetations at esophageal echocardiography. In this clinical setting endocarditis due to *Nocardia* was strongly suspected as well as blood dissemination of the pathogen to the skin, (Fig. 1), but this was not confirmed by blood cultures or clinical evolution. **On day + 14** a skin biopsy was taken from a papular pigmented lesion on the right leg. The skin tissue was inoculated into Brain Heart Infusion (BHI) broth as well as onto Horse blood agar (HBA) and selective media (Vacutest Kima, Italy) and incubated at 37 °C in aerobic and anaerobic conditions. Sabouraud dextrose agar + Chloramphenicol (SDA-CAF) was also inoculated to diagnose fungal infection. Surprisingly, after 3–4 days of culture at 30 °C in aerobic condition, a filamentous fungus appeared on SDA-CAF which was dark olive-brown on the surface and dark brown/black on the reverse side. Microscopic examination of a scotch tape prep in

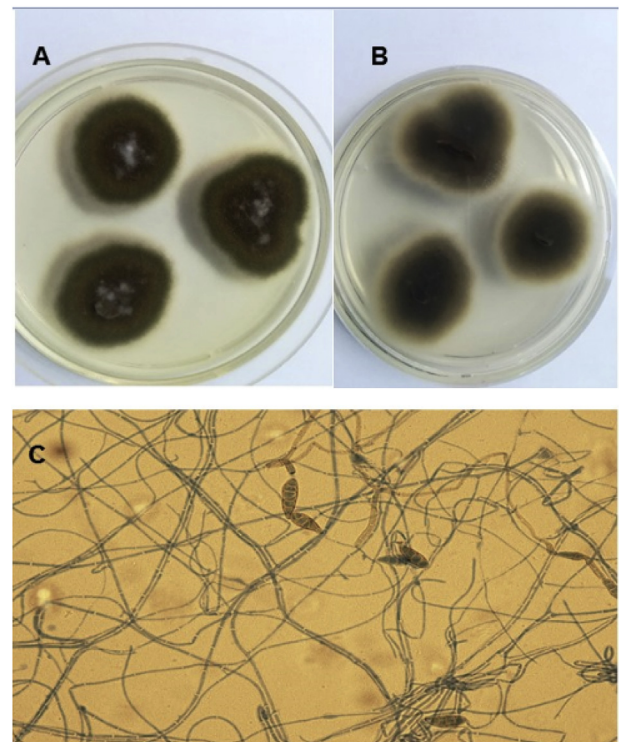


Fig. 2. Subculture of *Alternaria alternata* on SAB-DEX media: dark olivaceous-brown appearance on the front (A) and dark brown black pigment on the back (B). Microscopic examination of a scotch tape prep in lactophenol cotton blue revealed septate hyphae with large dark muriform conidia with tapering apices (40X, C). (For interpretation of the references to colour in this figure legend, the reader is referred to the Web version of this article.)

lactophenol cotton blue revealed septate hyphae with large dark muriform conidia with tapering apices (Fig. 2). These findings are consistent with the morphological characteristics of an *Alternaria* species. The species was identified as *Alternaria alternata* (Fig. 3) by MALDI-TOF MS. In order to exclude the possibility that *Alternaria alternata* might be a contaminant, histopathological sections were sent to the pathologists: the skin biopsy showed a necrotic granulomatous flogistic process, with the presence of numerous spores and septate hyphae (Fig. 4). Antifungal susceptibility testing (AFST) by broth microdilution method was performed following EUCAST guideline E.Def 7.3 for filamentous fungi. AFST produced the following minimal inhibitory concentrations (MIC): fluconazole 32 µg/ml, voriconazole 0.25 µg/ml, posaconazole 0.25 µg/ml; itraconazole 0.5 µg/ml and amphotericin B 0.25 µg/ml. These MICs are similar to those reported elsewhere [9–10]. Treatment with oral voriconazole (300 mg twice daily) was started **on day + 20** with close monitoring of tacrolimus blood levels. Beta-D-glucan was tested every three weeks after patient admission at Sant'Orsola Malpighi Hospital. All of the determinations were above the upper limit of test sensitivity (> 523.4 pg/mL). Six months after starting antimicrobial and antifungal treatment the patient showed complete remission of pulmonary and skin lesions.

3. Discussion

Immunosuppressive and prophylactic regimens have greatly evolved in the last few years, but a variety of opportunistic infections occur in immunocompromised hosts, especially dermatological complication in organ transplant recipients [11]. *Nocardia* is one of the opportunistic infections that deserves special consideration in immunocompromised hosts due to the success of early treatment and the bad prognosis in cases of delayed diagnosis and disseminated infection [12]. For the occurrence of *Nocardia* infection, history of CMV is

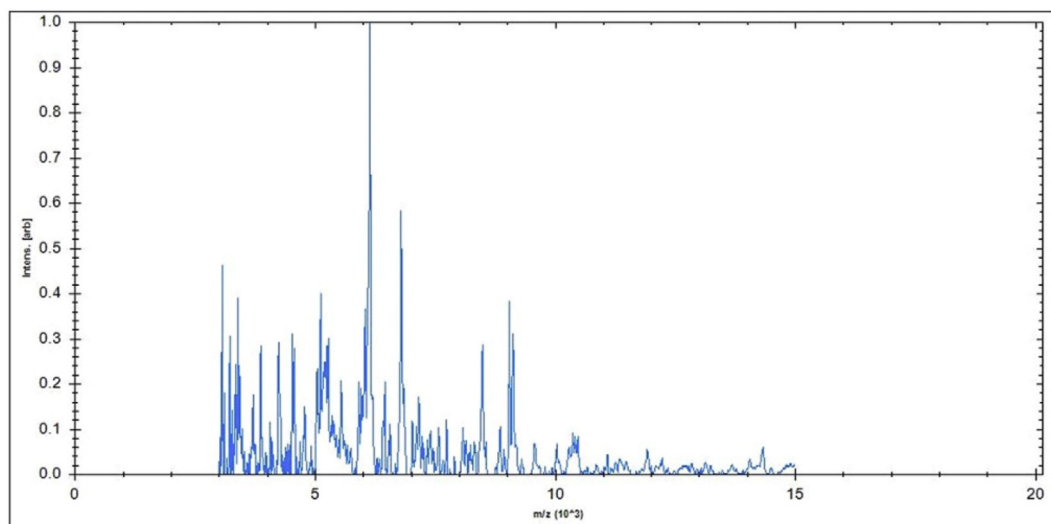


Fig. 3. MALDI-TOF spectra of *Alternaria alternata*. The identification score index was 2.23.

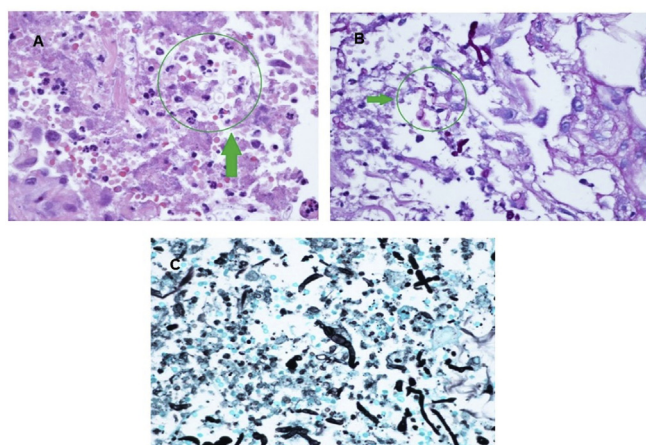


Fig. 4. Histopathological examination of the skin biopsy. (A) Round to oval, thick-walled fungal structures (green arrow, HE stain, 40X). (B) Rare hyphal fragments (green arrow, PAS stain, 40X), (C) Black narrow septate hypha (Grocott–Gomori methenamine silver stain, 40X). (For interpretation of the references to colour in this figure legend, the reader is referred to the Web version of this article.)

reported to be an independent risk factor [2]. In our case a CMV infection was diagnosed some days before the onset of Nocardiosis. Nocardia usually disseminates to the central nervous system and skin via the blood [3]. *Nocardia* and fungi co-infections are rarely observed [13], nevertheless, immunosuppressive therapy, mainly hypercorticism, may induce cutaneous fragility, an important co-factor permitting direct inoculation of opportunistic fungi from the environment [14]. Our liver transplant patient developed pulmonary nocardiosis and phaeohyphomycosis by *Alternaria alternata* during tacrolimus and immunosuppressive therapy following an episode of liver rejection. Phaeohyphomycosis can remain latent for years and the route of infection is generally skin injury [15]. We suppose that *Alternaria* penetration may have been the result of cutaneous fragility, as our patient had not been exposed to environmental risk factors. At present, there are no treatment guidelines for cutaneous and subcutaneous *Alternaria* spp. infections [7]. Several systemic antifungals have been used, either in combination with surgical removal or alone, with variable results. Surgery alone could be useful in the treatment of solitary skin lesions, mainly in transplant patients with difficulty controlling immunosuppression. In cases of multiple lesions, systemic therapy

becomes essential [6]. Reduction of the level of immunosuppression and the long-term use of systemic azoles are recommended. Azoles have proven to be efficient in the case of diffuse *Alternaria* spp. skin infection. Nevertheless, the unusual failure of itraconazole treatment for cutaneous ulcerative alternariosis has been reported [16–18] and so antifungal susceptibility testing is paramount for clinical management. In our case there was complete resolution of skin Alternariosis with oral voriconazole. It is possible that in our case the prompt microbiological diagnosis and initiation of an efficient antifungal therapy were fundamental for clinical resolution. We have also confirmed that oral voriconazole can be considered a possible choice for the treatment of *A. alternata* phaeohyphomycosis in liver transplant patients.

In conclusion, melanized fungal infections should be considered in the differential diagnosis of all chronic skin lesions in transplant recipients, especially in case of opportunistic infections that disseminate to the skin, such as lung nocardiosis. Our case highlights the challenges of diagnosing and managing opportunistic co-infection in an immunocompromised host. The roles of both the microbiologist and pathologist were fundamental in excluding cutaneous disseminated nocardiosis and potential contamination by environmental fungi as well as initiating efficient antifungal therapy immediately.

Ethics statement

Written informed consent was obtained for the publication of this case report and any potentially-identifying information/images.

Funding

No funding was received.

Declaration of competing interest

The authors declare that the research was conducted in the absence of any commercial or financial relationships that could be construed as a potential conflict of interest. All the authors agree on the final version of the manuscript.

Acknowledgements

Not applicable.

References

- [1] D. Lebeaux, E. Morelon, F. Suarez, F. Lanternier, A. Scemla, P. Frange, et al., Nocardiosis in transplant recipients, *Eur. J. Clin. Microbiol. Infect. Dis.* 33 (5) (2014) 689–702.
- [2] A.Y. Peleg, S. Husain, Z.A. Qureshi, F.P. Silveira, M. Sarumi, K.A. Shutt, et al., Risk factors, clinical characteristics, and outcome of Nocardia infection in organ transplant recipients: a matched case-control study, *Clin. Infect. Dis.* 44 (10) (2007) 1307–1314.
- [3] S.W. Chapman, J.P. Wilson, Nocardiosis in transplant recipients, *Semin. Respir. Infect.* 5 (1) (1990) 74–79.
- [4] A. Restrepo, N.M. Clark, Infectious diseases community of practice of the American society of transplantation. Nocardia infections in solid organ transplantation: guidelines from the infectious diseases community of practice of the American society of transplantation, *Clin. Transplant.* 33 (9) (2019) e13509.
- [5] J.S. Schieffelin, J.B. Garcia-Diaz, G.E. Loss Jr., E.N. Beckman, R.A. Keller, C. Staffeld-Coit, et al., Phaeohyphomycosis fungal infections in solid organ transplant recipients: clinical presentation, pathology, and treatment, *Transpl. Infect. Dis.* 16 (2) (2014) 270–278.
- [6] C. Ferrández-Pulido, M.T. Martín-Gómez, T. Repiso, C. Juárez-Dobjanschi, B. Ferrer, López-Lerma, et al., Cutaneous infections by dematiaceous opportunistic fungi: diagnosis and management in 11 solid organ transplant recipients, *Mycoses* 62 (2) (2019) 121–127.
- [7] O.A. Cornely, M. Cuenca-Estrella, J.F. Meis, A.J. Ullmann, European society of clinical microbiology and infectious diseases (ESCMID) fungal infection study group (EFISG) and European confederation of medical mycology (ECMM) 2013 joint guidelines on diagnosis and management of rare and emerging fungal diseases, *Clin. Microbiol. Infect.* 20 (3) (2014) 1–4.
- [8] F.J. Pastor, J. Guarro, Alternaria infections: laboratory diagnosis and relevant clinical features, *Clin. Microbiol. Infect.* 14 (8) (2008) 734–746.
- [9] F.(1) Sabatelli, R. Patel, P.A. Mann, C.A. Mendrick, C.C. Norris, R. Hare, et al., In vitro activities of posaconazole, fluconazole, itraconazole, voriconazole, and amphotericin B against a large collection of clinically important molds and yeasts, *Antimicrob. Agents Chemother.* 50 (6) (2006) 2009–2015.
- [10] M. Cuenca-Estrella, A. Gomez-Lopez, E. Mellado, M.J. Buitrago, A. Monzon, J.L. Rodriguez-Tudela, Head-to-head comparison of the activities of currently available antifungal agents against 3,378 Spanish clinical isolates of yeasts and filamentous fungi, *Antimicrob. Agents Chemother.* 50 (3) (2006) 917–921.
- [11] L. Naldi, A. Venturuzzo, P. Invernizzi, Dermatological complications after solid organ transplantation, *Clin. Rev. Allergy Immunol.* 54 (1) (2018) 185–212.
- [12] S. Jimenez-Galanes Marchan, J.C. Meneu Díaz, O. Caso Maestro, B. Perez Saborido, A. Moreno Elola-Olaso, M. Abradelo Usera, et al., Disseminated nocardiosis: a rare infectious complication following non-heart-beating donor liver transplantation, *Transplant. Proc.* 41 (6) (2009) 2495–2497.
- [13] F. Gomes, P. La Feria, C. Costa, H. Teixeira, *Nocardia cyriacigeorgica* and *Aspergillus* Co-infection in a patient with giant-cell arteritis, *Eur J Case Rep Intern Med* 6 (1) (2019) 000997.
- [14] L. Machet, V. Jan, M.C. Machet, L. Vaillant, G. Lorette, Cutaneous alternariosis: role of corticosteroid-induced cutaneous fragility, *Dermatology* 193 (4) (1996) 342–344.
- [15] M. Garnica, M. Nucci, F. Queiroz-Telles, Difficult mycoses of the skin: advances in the epidemiology and management of eumycetoma, phaeohyphomycosis and chromoblastomycosis, *Curr. Opin. Infect. Dis.* 22 (6) (2009) 559–563.
- [16] P. Lyskova, M. Kubanek, V. Hubka, E. Sticova, L. Voska, D. Kautznerova, et al., Successful posaconazole therapy of disseminated alternariosis due to *Alternaria* infectoria in a heart transplant recipient, *Mycopathologia* 182 (3–4) (2017) 297–303.
- [17] C.C. Hsu, S.S. Chang, P.C. Lee, S.C. Chao, Cutaneous alternariosis in a renal transplant recipient: a case report and literature review, *Asian J. Surg.* 38 (1) (2015) 47–57.
- [18] K.E. Lyke, N.S. Miller, L. Towne, W.G. Merz, A case of cutaneous ulcerative alternariosis: rare association with diabetes mellitus and unusual failure of itraconazole treatment, *Clin. Infect. Dis.* 32 (8) (2001) 1178–1187.