



# Asymptomatic maternal 3-methylcrotonylglycinuria detected by her unaffected baby's neonatal screening test

Sun Hee Lee, MD<sup>1</sup>, Yong Hee Hong, MD<sup>2</sup>

<sup>1</sup>Department of Pediatrics, Gachon University Gil Medical Center, Incheon, <sup>2</sup>Department of Pediatrics, Soonchunhyang University Bucheon Hospital, Bucheon, Korea

3-methylcrotonyl-coenzyme A carboxylase (3MCC) deficiency is an autosomal recessive disorder in which leucine catabolism is hampered, leading to increased urinary excretion of 3-methylcrotonylglycine. In addition, 3-hydroxyisovalerylcarnitine levels increase in the blood, and the elevated levels form the basis of neonatal screening. 3MCC deficiency symptoms are variable, ranging from neonatal onset with severe neurological abnormality to a normal, asymptomatic phenotype. Although 3MCC deficiency was previously considered to be rare, it has been found to be one of the most common metabolic disorders in newborns after the neonatal screening test using tandem mass spectrometry was introduced. Additionally, asymptomatic 3MCC deficient mothers have been identified due to abnormal results of unaffected baby's neonatal screening test. Some of the 3MCC-deficient mothers show symptoms such as fatigue, myopathy, or metabolic crisis with febrile illnesses. In the current study, we identified an asymptomatic 3MCC deficient mother when she showed abnormal results during a neonatal screening test of a healthy infant.

**Key words:** Neonatal screening, 3-Methylcrotonyl CoA carboxylase, Asymptomatic disease, Mother, Unaffected newborn

**Corresponding author:** Sun Hee Lee, MD  
Department of Pediatrics, Gachon University Gil Medical Center, 1198, Guwol-dong, Namdong-gu, Incheon 405-760, Korea  
Tel: +82-32-460-3596  
Fax: +82-32-460-3596  
E-mail: sun-9268@hanmail.net

Received: 17 September, 2014

Revised: 7 February, 2014

Accepted: 5 March, 2014

## Introduction

3-methylcrotonyl-coenzyme A carboxylase (3MCC) deficiency is a rare defect of L-leucine metabolism<sup>1</sup>. The urinary excretion of 3-hydroxyisovaleric acid (3-HIVA) and 3-methylcrotonylglycine (3-MCG) is increased. 3MCC deficiency is one of the most common inborn errors of metabolism detected in neonatal screening programs (1/36,000 births) using tandem mass spectrometry<sup>2</sup>.

Although the manifestation of 3MCC deficiency is variable, most infants detected by tandem mass screening are asymptomatic and remain healthy during the follow-up, and a number of apparently asymptomatic mothers have been diagnosed with 3MCC deficiency through their infant's newborn screen<sup>3,4</sup>. Recently, there have been an increased number of cases of 3MCC deficiency in Korea after tandem mass spectrometry was introduced as the newborn screening test<sup>5,6</sup>. However, there is only one case report about maternal 3MCC deficiency in Korea<sup>7</sup>. We identified a case of asymptomatic maternal 3MCC deficiency detected by her son's tandem mass spectrometry.

Copyright © 2014 by The Korean Pediatric Society

This is an open-access article distributed under the terms of the Creative Commons Attribution Non-Commercial License (<http://creativecommons.org/licenses/by-nc/3.0/>) which permits unrestricted non-commercial use, distribution, and reproduction in any medium, provided the original work is properly cited.

### Case report

A 14-day-old boy was referred to our Endocrinology and Metabolic Disease Clinic because of increased levels of 3-hydroxyisovaleryl carnitine on a neonatal screening test performed at one week of age.

The patient was born at gestational age 39<sup>+3</sup> weeks by vaginal delivery. His birth weight was 3.2 kg, and he did not have immediate perinatal problems. There were no complaints of nausea, vomiting, or poor oral feeding. He did not show tremor, seizures or any other neurologic symptoms. He is the first baby of his parents. There was no specific medical history in his family.

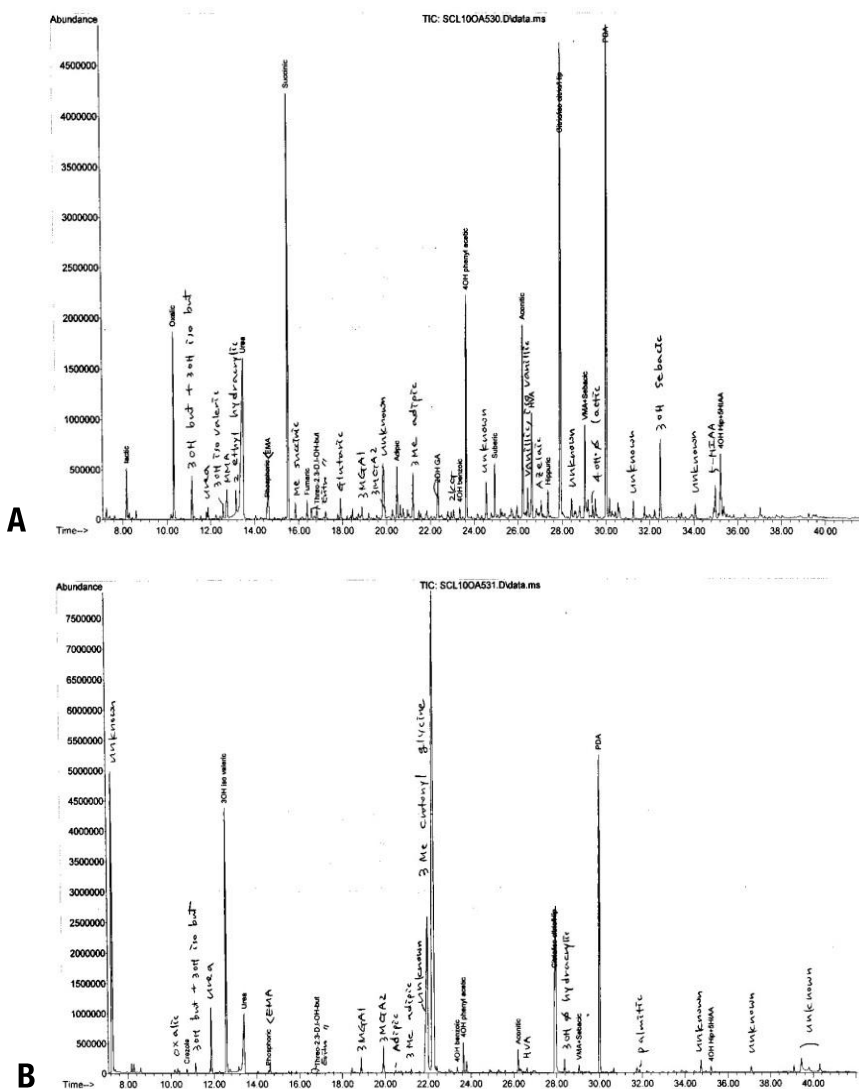
He was not ill looking. His height was 54 cm (0.26 standard deviation score), weight was 3.8 kg (-1.22 standard deviation

score), and head circumference was 37 cm (50–75 percentile). His blood pressure was 80/49 mmHg, pulse rate was 142 beats/min, respiratory rate was 31 breaths/min, and body temperature was 36.6°C. The physical exam was unremarkable. He was alert and showed normal findings on the neurologic examination, and his muscle tone was not hypotonic.

Leucine-free formula feeding and carnitine (100 mg/kg/day) supplementation was started because we suspected he had a 3MCC deficiency.

The laboratory studies showed a normal complete blood count, normal electrolytes, and normal renal and liver function test results. In addition, there was no acidosis on the venous blood gas analysis, and his ammonia level was also within the normal range.

Metabolic investigations showed normal serum amino acids



**Fig. 1.** Profile of the urine organic acid analysis of the mother and her infant. (A) The results of the infant's urine organic acid analysis. (B) The results of the mother's urine organic acid analysis.

and normal concentrations of free and total carnitine. 3-MCG and isovaleric acid were not detected in the urine organic acid analysis.

We then suspected maternal 3MCC deficiency, and a urine organic acid analysis of the patient's mother was performed. The 3-MCG level was increased (227.98 mmol/mol Cr, control: not detectable) in her urine (Fig. 1). She was diagnosed as having maternal 3MCC deficiency. She was asymptomatic until diagnosed as having 3MCC deficiency. There were no abnormal findings on her physical examination, and she was not lethargic and had no specific symptoms of acute illness according to her past medical history. We did not perform an exact IQ test, but her intellect appeared normal. We recommended further evaluation such as a plasma amino acid analysis, enzyme activity test and genetic study. However, she refused further investigation and gene analysis because she was asymptomatic.

After maternal 3MCC deficiency was diagnosed, the leucine-free formula and carnitine supplementation for her baby was stopped, and breast milk feeding was started.

After 3 months, the mother and her baby were doing well, and they had no symptoms associated with 3MCC.

## Discussion

3MCC deficiency is an abnormality of leucine metabolism<sup>1</sup>. It is induced by mutations in the *MCCC1* and *MCCC2* genes encoding the  $\alpha$  and  $\beta$  subunits, respectively<sup>8</sup>.

3-HIVA and 3-MCG are increased in the urine of 3MCC deficiency subjects. Additionally, 3-hydroxyisovalerylcarnitine is also high in the blood and urine, and it is detected by the neonatal screening test. Carnitine deficiency can also develop in many 3MCC-deficient patients<sup>1</sup>.

Signs/symptoms previously described in 3MCC deficiency include poor feeding, vomiting, hypotonia, seizures, failure to thrive, developmental delay, and Hypoglycemia<sup>11</sup>. However, the neonatal screening test using tandem mass spectrometry, which has become quite prevalent recently, has revealed that the clinical picture of MCC deficiency is heterogeneous and often highly variable, even within the same family<sup>4,9,10</sup>. Some patients usually have no symptoms but do show symptoms such as vomiting, involuntary movements, seizures, coma and apnea associated with metabolic acidosis, hyperglycemia and mild hyperammonemia only during concurrent infections or illnesses<sup>10-12</sup>. The majority of children diagnosed by the neonatal screening test have been reported to have remained asymptomatic so far<sup>6,13,14</sup>.

3MCC deficiency is inherited as an autosomal recessive trait. Therefore, the importance of screening for the defect in the asymptomatic siblings of affected patients has been

established<sup>15</sup>. Otherwise, we are usually not concerned with the parents of the proband. However, several asymptomatic 3MCC-deficient mothers have been identified only by abnormal results in the neonatal screening test from their unaffected babies<sup>4,13</sup>, which was observed in our case. The abnormal metabolites found in the healthy infants originated from the mothers, who are unrecognized 3MCC-deficient patients, via placental transfer<sup>4</sup>. Therefore, metabolic analysis of the mother in addition to screening positive infants is recommended. The mother should have a urine organic acid analysis and a plasma acylcarnitine profile<sup>15</sup>.

There are few reports about maternal 3MCC deficiency<sup>3,4,7,9</sup>. Most affected mothers identified through their infant's abnormal screening results were asymptomatic despite having consumed an unrestricted diet throughout their life. However, one of 4 affected mothers reported significant emesis with minor illness or after high protein meals<sup>3</sup>. An additional 2 of 4 affected mothers reported by Gibson et al.<sup>4</sup> had mild symptoms such as fatigue, myopathy, weakness and elevated liver enzymes. According to the report by Grunert et al.<sup>9</sup>, 1 of 8 maternal 3MCC-deficient patients had symptoms such as several metabolic crises with hypoglycemia during febrile illnesses, metabolic stroke, cardiomyopathy, and paresthesias. In a Korean case report<sup>7</sup>, the affected mother was asymptomatic, which is the same as our case.

Supplementation with oral L-carnitine and a leucine-restricted diet is the treatment for 3MCC deficiency, but the efficacy of these approaches is unproven<sup>15</sup>. Moreover, there is consensus that leucine-restricted diets are not indicated for asymptomatic mothers and that the decision regarding restricted diets in symptomatic mothers should be individualized<sup>15</sup>. Because the mother of our case was asymptomatic, we did not restrict her diet or supply carnitine.

In our case, the confirmatory enzyme analysis and genetic analysis of the mother were not performed. Although, confirming the diagnosis based on the enzyme assay whenever possible is preferable, there is consensus that 3MCC deficiency can sometimes be diagnosed based on metabolite levels alone without the enzyme analysis, depending on the specific metabolites and degree of elevation<sup>15</sup>.

Moreover, the genotype does not appear to be predictive of the phenotype or metabolic risk<sup>13</sup>. Thus, DNA analysis is not yet helpful in the management of affected patients, but it can assist with the confirmation of questionable cases<sup>15</sup>.

We identified asymptomatic 3MCC deficiency in an adult detected via an abnormal neonatal screening test result of her unaffected baby. Although maternal 3MCC deficiency is uncommon and the investigation of asymptomatic mothers is difficult, we can confirm that investigating neonatal screening-positive infants and their mothers simultaneously is important.

## Conflict of interest

No potential conflict of interest relevant to this article was reported.

## References

1. Nyhan WL, Barshop BA, Ozand PT, editors. Organic acidemias. In: Nyhan WL, Barshop BA, Ozand PT, editors. Atlas of metabolic diseases. 2nd ed. London: Hodder education, 2005;66-9.
2. Frazier DM, Millington DS, McCandless SE, Koeberl DD, Weavil SD, Chaing SH, et al. The tandem mass spectrometry newborn screening experience in North Carolina: 1997-2005. *J Inherit Metab Dis* 2006;29:76-85.
3. Koeberl DD, Millington DS, Smith WE, Weavil SD, Muenzer J, McCandless SE, et al. Evaluation of 3-methylcrotonyl-CoA carboxylase deficiency detected by tandem mass spectrometry newborn screening. *J Inherit Metab Dis* 2003;26:25-35.
4. Gibson KM, Bennett MJ, Naylor EW, Morton DH. 3-Methylcrotonyl-coenzyme A carboxylase deficiency in Amish/Mennonite adults identified by detection of increased acylcarnitines in blood spots of their children. *J Pediatr* 1998;132(3 Pt 1):519-23.
5. Jung CW, Lee BH, Kim JH, Kim GH, Lee J, Choi JH, et al. Uneventful clinical courses of Korean patients with methylcrotonylglycinuria and their common mutations. *J Hum Genet* 2012;57:62-4.
6. Kwak JY, Park JY, Nam KA, Son SH, Seo SS. Isolated 3-methylcrotonyl CoA carboxylase deficiency detected by newborn screening program using tandem mass spectrometry. *Korean J Pediatr* 2005;48:561-64.
7. Kim SJ. Maternal metabolic disease detected by newborn screening program using tandem mass. *Korean J Inher Metab Dis* 2003;3:97-9.
8. Baumgartner MR, Almashanu S, Suormala T, Obie C, Cole RN, Packman S, et al. The molecular basis of human 3-methylcrotonyl-CoA carboxylase deficiency. *J Clin Invest* 2001;107:495-504.
9. Grunert SC, Stucki M, Morscher RJ, Suormala T, Burer C, Burda P, et al. 3-methylcrotonyl-CoA carboxylase deficiency: clinical, biochemical, enzymatic and molecular studies in 88 individuals. *Orphanet J Rare Dis* 2012;7:31.
10. Baykal T, Gokcay GH, Ince Z, Dantas MF, Fowler B, Baumgartner MR, et al. Consanguineous 3-methylcrotonyl-CoA carboxylase deficiency: early-onset necrotizing encephalopathy with lethal outcome. *J Inher Metab Dis* 2005;28:229-33.
11. Ficiocioglu C, Payan I. 3-Methylcrotonyl-CoA carboxylase deficiency: metabolic decompensation in a noncompliant child detected through newborn screening. *Pediatrics* 2006;118:2555-6.
12. Oude Luttikhuis HG, Touati G, Rabier D, Williams M, Jakobs C, Saudubray JM. Severe hypoglycaemia in isolated 3-methylcrotonyl-CoA carboxylase deficiency; a rare, severe clinical presentation. *J Inher Metab Dis* 2005;28:1136-8.
13. Stadler SC, Polanetz R, Maier EM, Heidenreich SC, Niederer B, Mayerhofer PU, et al. Newborn screening for 3-methylcrotonyl-CoA carboxylase deficiency: population heterogeneity of MCCA and MCCB mutations and impact on risk assessment. *Hum Mutat* 2006;27:748-59.
14. Uematsu M, Sakamoto O, Sugawara N, Kumagai N, Morimoto T, Yamaguchi S, et al. Novel mutations in five Japanese patients with 3-methylcrotonyl-CoA carboxylase deficiency. *J Hum Genet* 2007;52:1040-3.
15. Arnold GL, Koeberl DD, Matern D, Barshop B, Braverman N, Burton B, et al. A Delphi-based consensus clinical practice protocol for the diagnosis and management of 3-methylcrotonyl CoA carboxylase deficiency. *Mol Genet Metab* 2008;93:363-70.