


## Case Report

# Persistent wheezing caused by carvedilol overdose in a non-asthmatic man

Misuzu Nakanishi, Akira Kuriyama,  and Mutsuo Onodera

Emergency and Critical Care Center, Kurashiki Central Hospital, Okayama, Japan

**Background:** Cardiovascular dysfunction is the main manifestation of  $\beta$ -blocker intoxication; however, respiratory manifestations have rarely been reported.

**Case Presentation:** A 41-year-old man, who had ingested 300 mg carvedilol in a suicide attempt, was transferred to our emergency department. The patient had wheezing on arrival; however, he had no known history of bronchial asthma. In the absence of signs of heart failure, we gave the patient inhaled procaterol, a short-acting  $\beta_2$  agonist. The wheezing disappeared approximately 60 h after carvedilol ingestion and did not recur thereafter.

**Conclusion:** We report a case of wheezing caused by carvedilol intoxication. Although rare, clinicians should recognize that wheezing or bronchospasm can develop following  $\beta$ -blocker intoxication, for which a short-acting  $\beta_2$  agonist could be indicated.

**Key words:**  $\beta$ -blocker, bronchospasm, carvedilol, procaterol, wheezing

## INTRODUCTION

CARVEDILOL IS A non-selective  $\beta$ -adrenergic blocker with an  $\alpha$ -adrenergic-receptor blocking effect. It is widely used to treat ischemic heart disease, atrial fibrillation, and chronic heart failure.<sup>1</sup> Intoxication of  $\beta$ -blockers mainly manifests as cardiovascular dysfunction, but respiratory manifestations have rarely been reported. Here, we report a case of a 41-year-old man who ingested 300 mg carvedilol in a suicide attempt and developed wheezing that persisted for approximately 60 h. He was treated with a short-acting  $\beta_2$  agonist (SABA).

## CASE PRESENTATION

A 41-year-old man was transferred to our emergency department (ED) with a deteriorated level of consciousness. The patient had a cardiac resynchronization therapy defibrillator implanted for dilated cardiomyopathy

8 years prior and was treated with paroxetine for major depression. He did not have underlying bronchial asthma or episodes of acute exacerbation of cardiac failure. The patient's family reported that he had ingested 300 mg carvedilol and 7 mg lorazepam, which were his usual medications, along with alcohol, in a suicide attempt after a quarrel with his mother 8 h before arriving at the hospital.

The patient's vital signs on arrival to the ED were as follows: blood pressure, 72/44 mmHg; pulse, 90 b.p.m.; respiratory rate, 26 breaths/min; oxygen saturation, 80% on ambient air; and Glasgow Coma Scale score 13 (E3V4M6). On physical examination, the wheezing was audible with normal cardiac sounds. Arterial blood gas analysis under 5-L facial mask oxygen showed mild respiratory acidosis (pH 7.32; PaO<sub>2</sub>, 92.1 mmHg; PaCO<sub>2</sub>, 52.0 mmHg; and HCO<sub>3</sub>, 26.2 mmol/L). The level of B-type natriuretic peptide was 9.3 pg/mL and other laboratory examinations were within the normal limits. Chest X-ray showed no infiltrate or cardiac enlargement (Fig. 1). The electrocardiogram showed sinus rhythm followed by ventricular pacing (Fig. 2). We suspected that the hypotension was due to hypovolemia, because ultrasonography showed a collapsed inferior vena cava and the blood pressure increased to 90 mmHg following administration of 500 mL fluid.

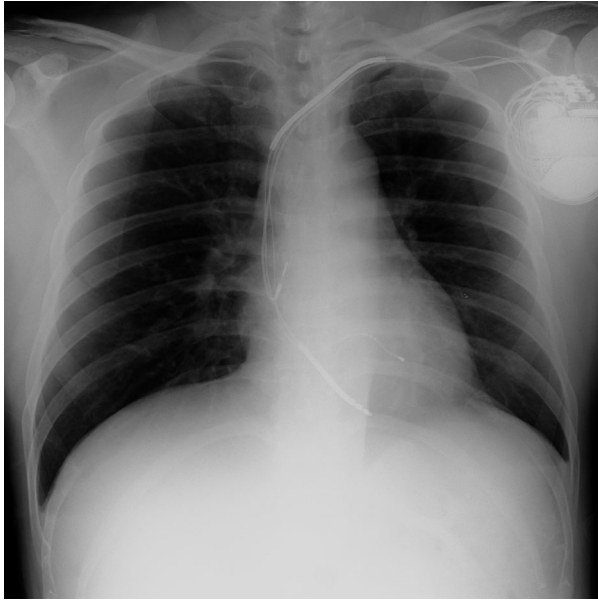
The wheezing and hypoxia persisted, requiring oxygen supplementation. The patient was admitted to our intensive care unit for continued monitoring of respiratory status.

**Corresponding:** Akira Kuriyama, MD, MPH, Emergency and Critical Care Center, Kurashiki Central Hospital, 1-1-1 Miwa Kurahsiki Okayama 710-8602, Japan. E-mail: ak13568@kchnet.or.jp.

Received 13 Sep, 2019; accepted 16 Nov, 2019; online publication 14 Dec, 2019

### Funding information

No funding information provided.

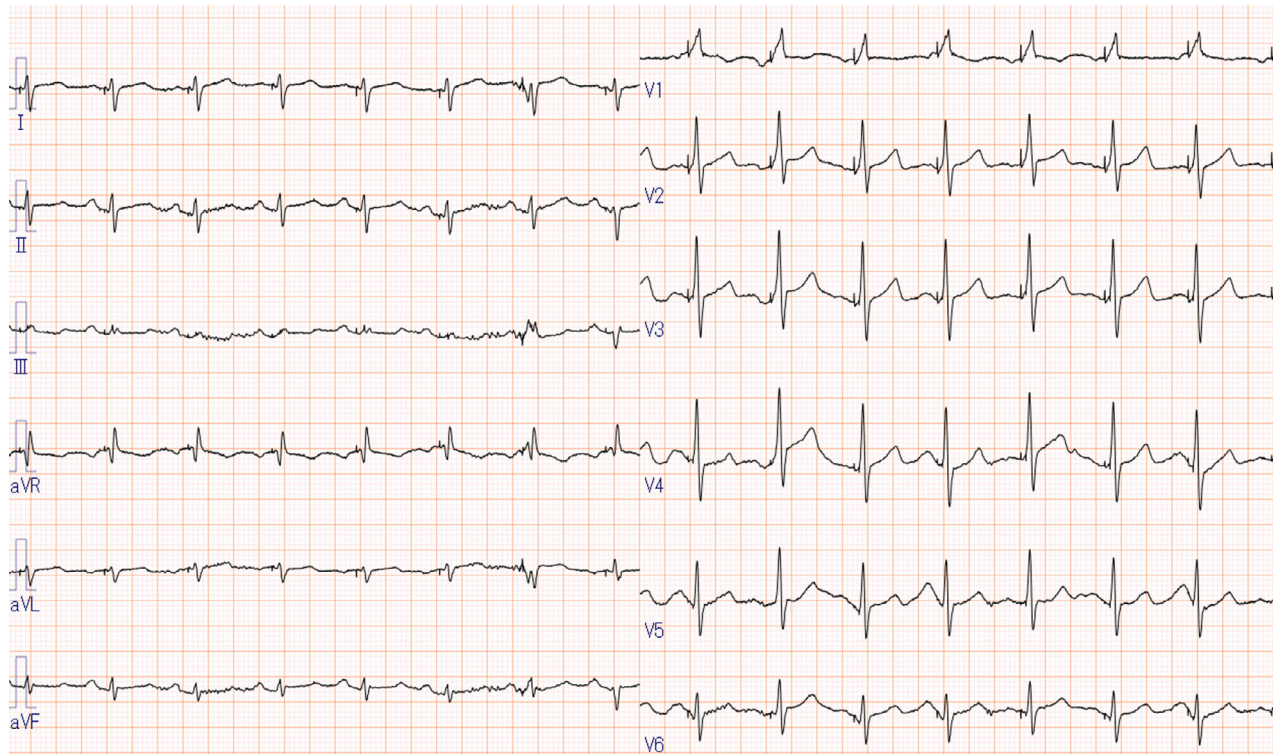


**Fig. 1.** Chest X-ray showing no cardiac enlargement or pulmonary edema in a 41-year-old man with persistent wheezing caused by carvedilol overdose.

Cardiac ultrasonography showed reasonable left ventricular contraction (ejection fraction rate of 45–50%) and respiratory collapse of the inferior vena cava, indicating a hypovolemic status. In the absence of a known diagnosis of bronchial asthma, we suspected that the wheezing or bronchospastic reaction was triggered by carvedilol. The patient was treated with inhaled procaterol hydrochloride hydrate on demand in addition to activated charcoal. The patient's mental status normalized on day 2. The wheezing and hypoxia gradually improved and disappeared by the morning of day 3. The course of the hospital stay was uneventful without bradycardia or hypotension, and the patient was discharged on day 5. Because there has been no recurrence of wheezing for 2 years, a diagnosis of wheezing caused by carvedilol intoxication was supported.

## DISCUSSION

**C**ARVEDILOL IS A non-selective beta-adrenergic ( $\beta_1$ ,  $\beta_2$ ) blocker with an alpha ( $\alpha_1$ ) adrenergic receptor blocking effect that is used to treat hypertension, ischemic heart disease, atrial fibrillation, and chronic heart failure.<sup>1,2</sup>



**Fig. 2.** Electrocardiogram of a 41-year-old man with persistent wheezing caused by carvedilol overdose, showing sinus rhythm followed by ventricular pacing.

Carvedilol is lipophilic, and approximately 25–35% of the oral dose is bioavailable; its half-life ranges from 7 to 10 h following oral administration.<sup>2</sup>

Theoretically,  $\beta$ -blockers could induce bronchial smooth muscle contraction or bronchospasm and might thereby exacerbate bronchial asthma. Non-selective  $\beta$ -blockers might induce bronchospasm, reduced airway conductance, and forced expiratory volume within a second, which can exacerbate bronchial asthma and chronic obstructive lung disease.<sup>3,4</sup> However, to the best of our knowledge, there is no evidence suggesting that  $\beta$ -blockers induce bronchospasm or bronchial asthma in non-asthmatic individuals.

The primary manifestations of  $\beta$ -blocker intoxication include cardiovascular dysfunctions such as bradycardia, hypotension, and cardiac arrest, and miscellaneous symptoms such as vomiting, seizures, change in mental status, hypokalemia, and hypoglycemia.<sup>5,6</sup> In the present case, the patient had an altered mental status, hypotension, and wheezing. The deteriorated level of consciousness could be attributed to the co-ingestion of alcohol and benzodiazepines. The hypotension was attributed to the hypovolemic status or dehydration secondary to alcohol intake, as it immediately resolved following fluid administration. The patient did not develop bradycardia or it was masked by the paced rhythm generated by his cardiac resynchronization therapy defibrillator, given that the baseline rhythm was consistently sinus rhythm. A noteworthy symptom in this patient was wheezing. As stated previously, this patient had no episodes of bronchial asthma or exacerbation of heart failure. The wheezing persisted until the morning of day 3 (approximately 60 h after carvedilol ingestion) and improved following SABA treatment. No recurrence of wheezing supported the fact that it was caused by carvedilol. Weinstein et al. reported the case of a 22-year-old woman who experienced wheezing 15 min after ingesting 1,000 mg atenolol<sup>7</sup>, which also improved with SABA given within 2 h. To the best of our knowledge, this is the only reported case of wheezing caused by a  $\beta$ -blocker overdose, which makes the present case noteworthy.

This patient had significant wheezing without cardiovascular dysfunction. Although the patient denied a history of bronchial asthma, he might have had a subclinical asthmatic component.

Evidence-based consensus suggests that the lowest toxic oral dose of carvedilol for adults is 1,050 mg. The maximum single therapeutic dose is typically recommended at 50 mg.<sup>6</sup> The present patient had ingested 300 mg carvedilol, which is lower than the reported toxic dose. However, knowledge regarding carvedilol intoxication vis-à-vis propranolol intoxication is scarce.<sup>8</sup> Furthermore, the main symptom in this case of wheezing was significant relative to

the carvedilol dose, which is reasonable given that the blood concentration of a  $\beta$ -blocker was previously shown to have no association with the severity of  $\beta$ -blocker intoxication.<sup>5</sup> However, the time for which the wheezing and hypoxia persisted (maximum 60 h) was reasonable given the half-life of the drug. Thus, any patient who has ingested a supratherapeutic dose of carvedilol should be cautiously monitored for complications such as wheezing.

There are some proposed treatment options for  $\beta$ -blocker intoxication.<sup>9</sup> Pharmacological therapies include glucagon and catecholamines given i.v.<sup>9</sup> Glucagon exerts positive inotropic and chronotropic effects on the myocardium by stimulating adenylyl cyclase, similar to catecholamines. Cardiovascular symptoms are the main reported indications of glucagon. Because it was unclear as to how the wheezing would respond to glucagon in the present case, we gave only inhaled procaterol to our patient. Activated charcoal could also be used for intoxication in general. Non-pharmacologic therapies include cardiac pacing to maintain the heart rate; in addition, extracorporeal circulatory support and an aortic balloon pump could be considered for a prolonged and refractory cardiovascular compromise.<sup>9,10</sup> The present case suggests that the repeated use of SABA might be effective while wheezing persists. There is some evidence indicating that non-invasive positive pressure ventilation could lead to clinical improvement of acute asthma.<sup>11</sup> Given that  $\beta$ -blocker intoxication is theoretically reversible, non-invasive positive pressure ventilation can be an option for managing bronchospasm caused by  $\beta$ -blocker intoxication that is refractory to SABA.

## CONCLUSION

**W**E REPORT A case of wheezing caused by carvedilol intoxication, which was successfully treated with SABA. Although the reported manifestations of  $\beta$ -blocker intoxication are mostly cardiac dysfunctions, clinicians should also recognize that wheezing or bronchospasm can develop following  $\beta$ -blocker intoxication, for which SABA could be indicated.

## ACKNOWLEDGMENTS

**N**ONE.

## DISCLOSURE

Approval of the research protocol: N/A.

Informed consent: Informed consent was obtained from the patient.

Registry and registration no. of the study/trial: N/A.

Animal studies: N/A.

Conflict of interest: None.

## REFERENCES

- 1 DiNicolantonio JJ, Hackam DG. Carvedilol: a third-generation beta-blocker should be a first-choice beta-blocker. *Expert Rev. Cardiovasc. Ther.* 2012; 10: 13–25.
- 2 Stafylas PC, Sarafidis PA. Carvedilol in hypertension treatment. *Vasc. Health Risk Manag.* 2008; 4: 23–30.
- 3 Loth DW, Brusselle GG, Lahousse L, Hofman A, Leufkens HG, Stricker BH. beta-Adrenoceptor blockers and pulmonary function in the general population: the Rotterdam Study. *Br. J. Clin. Pharmacol.* 2014; 77: 190–200.
- 4 Morales DR, Jackson C, Lipworth BJ, Donnan PT, Guthrie B. Adverse respiratory effect of acute beta-blocker exposure in asthma: a systematic review and meta-analysis of randomized controlled trials. *Chest* 2014; 145: 779–86.
- 5 Frishman W, Jacob H, Eisenberg E, Ribner H. Clinical pharmacology of the new beta-adrenergic blocking drugs. Part 8. Self-poisoning with beta-adrenoceptor blocking agents: recognition and management. *Am. Heart J.* 1979; 98: 798–811.
- 6 Wax PM, Erdman AR, Chyka PA *et al.* beta-blocker ingestion: an evidence-based consensus guideline for out-of-hospital management. *Clin. Toxicol. (Phila)* 2005; 43: 131–46.
- 7 Weinstein RS, Cole S, Knaster HB, Dahlbert T. Beta blocker overdose with propranolol and with atenolol. *Ann. Emerg. Med.* 1985; 14: 161–3.
- 8 Bouchard NC, Forde J, Hoffman RS. Carvedilol overdose with quantitative confirmation. *Basic Clin. Pharmacol. Toxicol.* 2008; 103: 102–3.
- 9 Kerns W 2nd. Management of beta-adrenergic blocker and calcium channel antagonist toxicity. *Emerg. Med. Clin. North Am.* 2007; 25: 309–31; abstract viii.
- 10 Koschny R, Lutz M, Seckinger J, Schwenger V, Stremmel W, Eisenbach C. Extracorporeal life support and plasmapheresis in a case of severe polyintoxication. *J. Emerg. Med.* 2014; 47: 527–31.
- 11 Soma T, Hino M, Kida K, Kudoh S. A prospective and randomized study for improvement of acute asthma by non-invasive positive pressure ventilation (NPPV). *Intern. Med.* 2008; 47: 493–501.