

A Curious Case of Coil-Angitis

Jasna I. Beard, MD¹, Sharif Murphy, MD¹, and George Philips, MD¹

¹College of Medicine, University of Tennessee, Chattanooga, TN

ABSTRACT

A 43-year-old man with a history of pedestrian-truck collision 18 months prior presented with right-sided abdominal pain and chills. His trauma consisted of orthopedic injuries and a grade 4 liver laceration. Surgical liver repair was complicated by a biloma requiring common bile duct stenting. Postendoscopy hemobilia led to extensive coiling of a hepatic artery pseudoaneurysm. Remaining hospitalization was relatively uneventful, and he was lost to follow-up. Repeat presentation was marked by leukocytosis and obstructive transaminitis. Computed tomography raised concern for a dilated 14-mm common bile duct with migrated coil mass near the pancreatic head. The patient underwent urgent endoscopic retrograde cholangiopancreatography with cholangioscopy and successful removal of a coil mass measuring approximately 4 × 3 cm without injury to the common bile duct or vascular structures. His pain was relieved, and he was discharged with a common bile duct stent and outpatient follow-up.

INTRODUCTION

Coil embolization is an increasingly popular tool for control of bleeding, especially effective in cases of liver injury.¹ Although it has an 86% success rate, it carries a high risk of complications (58%), most commonly bleeding, bile leakage, liver necrosis, or intra-abdominal abscess.² Injury to bile ducts and surrounding vasculature can be seen with laparoscopic procedures such as cholecystectomies where embolization is often the least invasive course of action.^{2,3}

Nontraumatic use of coil embolization is often seen with bleeding malignant lesions or arteriovenous malformations such as those of hereditary hemorrhagic telangiectasia.⁴ Liver is the most commonly injured organ in blunt abdominal trauma with mortality as high as 54%. Better imaging has allowed for more effective risk stratification of polytraumas allowing some centers to manage up to 80% of cases with liver injuries nonsurgically—often using coil embolization.^{3,5} Implants such as coils (and even clips) can later lead to biliary obstruction or stone nucleation, often by migrating in the dynamic tissue of surgical beds or by necrosis and fistulization of nearby structures.⁵⁻⁹

CASE REPORT

A 43-year-old man with a history of trauma after pedestrian-truck collision 18 months prior presented with severe right-sided abdominal pain, nausea, and chills. History of trauma consisted of extensive fractures and a grade 4 liver laceration requiring surgical repair. The course was complicated by development of a biloma requiring common bile duct stenting with persistent hemobilia documented on subsequent esophagogastroduodenoscopy. He underwent extensive coiling of a hepatic artery pseudoaneurysm. Remaining hospitalization was relatively uneventful, and he was lost to follow-up. Evaluation at the time of admission was notable for fever, severe right upper quadrant tenderness, elevated white blood cell count, and elevated bilirubin level at 6.6 mg/dL with associated obstructive pattern of liver enzymes. Computed tomography raised concern for dilated common bile duct at 14 mm with a radiopaque obstructing mass near the pancreatic head, supporting the diagnosis of obstructive acute ascending cholangitis (Figure 1). The patient underwent urgent endoscopic retrograde cholangiopancreatography with cholangioscopy and successful removal of a coil mass measuring approximately 4 × 3 cm without injury to the common bile duct or vascular structures (Figures 2 and 3). His pain was relieved, and he was discharged with a common bile duct stent and outpatient follow-up.

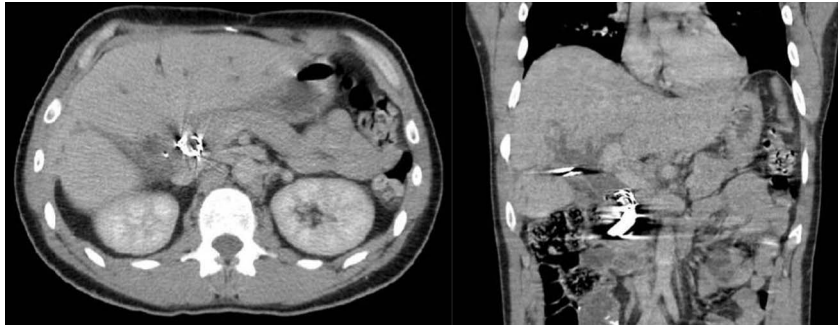


Figure 1. Computed tomography showing a mass at the hepatic confluence near the pancreatic head, raising concern for biliary obstruction by foreign body or coils.

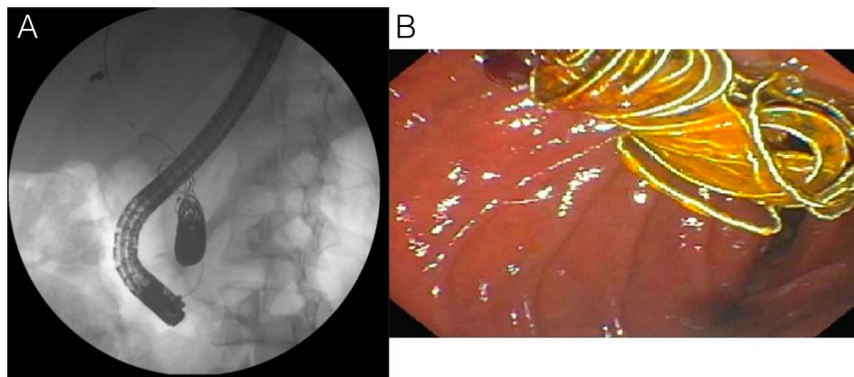


Figure 2. (A) Fluoroscopic image of a large radiopaque mass within the common bile duct. (B) Endoscopic view showing coils emerging into the duodenum through ampulla.

DISCUSSION

The use of coils in treatment of lesions deemed high risk for bleeding has a lengthy and growing list of indications.² Liver (and thereby biliary and vascular) injuries commonly occur in traumatic

and nontraumatic settings, increasing the risk of bleeding lesions that may require use of coiling. Although very successful and often least invasive, coiling carries the possibility of delayed complications due to the dynamic nature of surgical beds or traumatic injuries with local tissue necrosis, subsequent surrounding fistulization, and resultant coil migration. Similar complications have been noted after coiling in various structures, including pulmonary arteriovenous malformations with expectoration of the coil material.^{11–13,14} Our patient represents one of a likely increasing number of cases of a delayed complication with high associated mortality risk, warranting a great degree of suspicion and need for detailed documentation of prior interventions. The case additionally illustrates the importance of a multidisciplinary approach involving the input of radiologic, gastroenterologic, and surgical teams in the management of complications of intrahepatic coils, just as at that time of the initial injury.

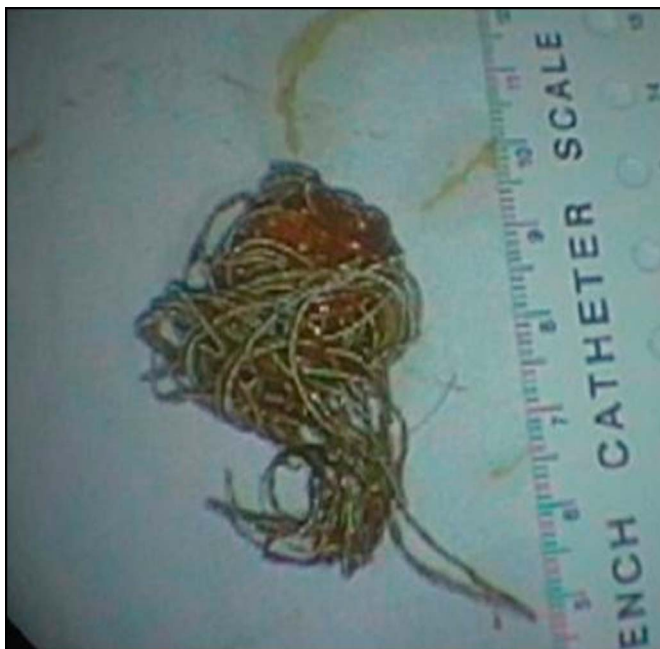


Figure 3. Large coil mass removed safely from common bile duct after eroding through vasculature into the biliary tract.

DISCLOSURES

Author contributions: JI Beard wrote the manuscript, provided the images, and is the article guarantor. S. Murphy wrote and edited the manuscript. G. Philips approved the final version.

Financial disclosure: None to report.

Informed consent was obtained for this case report.

Received December 13, 2018; Accepted February 28, 2019

REFERENCES

1. Chien LC, Lo SS, Yeh SY. Incidence of liver trauma and relative risk factors for mortality: A population-based study. *J Chin Med Assoc.* 2013;76(10):576–82.
2. Bilbao JI, Martínez-Cuesta A, Urtasun F, Cosin O. Complications of embolization. *Semin Interv Radiol.* 2006;23(2):126–42.
3. Slotta JE, Justinger C, Kollmar O, Kollmar C, Schäfer T, Schilling MK. Liver injury following blunt abdominal trauma: A new mechanism-driven classification. *Surg Today.* 2014;44(2):241–6.
4. Schwarzer D, Mader I, Petrovitch A, Leonhardi J, Bonnet R. Expectoration of embolization coils 15 years after embolization of pulmonary arteriovenous malformations in a patient with hereditary hemorrhagic telangiectasia. *Pneumologie.* 2014;68(4):282–5.
5. Tessier DJ, Fowl RJ, Stone WM, et al. Iatrogenic hepatic artery pseudoaneurysms: An uncommon complication after hepatic, biliary, and pancreatic procedures. *Ann Vasc Surg.* 2003;17(6):663–9.
6. Turaga KK, Amirlak B, Davis RE, Yousef K, Richards A, Fitzgibbons RJ Jr. Cholangitis after coil embolization of an iatrogenic hepatic artery pseudoaneurysm: An unusual case report. *Surg Laparosc Endosc.* 2006;16(1):36–8.
7. Soape MP, Lichliter A, Cura M, Lepe-Suastegui MR, Burdick JS. Rare duodenal varix coil erosion post TIPS creation and coil embolization of mesenteric–systemic shunt. *Dig Dis Sci.* 2017;9(62):2601–3.
8. Walker WE, Avant GR, Reynolds VH. Cholangitis with a silver lining. *Arch Surg.* 1979;114(2):214–5.
9. Avant X, Molina E, Larsen MF. Cholangitis secondary to migrated metallic coils in the common bile duct. *Acta Gastroenterol Latinoam.* 2013;43(2):146–8.
10. Wilseck Z, Savastano L, Chaudhary N, et al. Delayed extrusion of embolic coils into the airway after embolization of an external carotid artery pseudoaneurysm. *BMJ Case Rep.* 2017;2017.
11. Zaafour H, Hasnaoui A, Essghaier S, et al. Ascending Cholangitis secondary to migrated embolization coil of gastroduodenal artery pseudoaneurysm a case report. *BMC Surg.* 2017;17(1):30.
12. Raashed S, Chandrasegaram MD, Alsaleh K, Schlaphoff G, Merrett ND. Vascular coil erosion into hepaticojunostomy following hepatic arterial embolisation. *BMC Surg.* 2015;15:51.
13. Sadek M, Rockman CB, Berland TL, et al. Coil embolization of a gastroduodenal artery pseudoaneurysm secondary to cholangitis. *Vasc Endovascular Surg.* 2012;46(7):550–4.

Copyright: © 2019 The Author(s). Published by Wolters Kluwer Health, Inc. on behalf of The American College of Gastroenterology. This is an open-access article distributed under the terms of the Creative Commons Attribution-Non Commercial-No Derivatives License 4.0 (CCBY-NC-ND), where it is permissible to download and share the work provided it is properly cited. The work cannot be changed in any way or used commercially without permission from the journal.