

*Case Report*

## Refractory uraemic pleuropericarditis treated successfully with corticosteroid therapy

So-Young Lee, Gi-youn Hong, Jun Gu Chung, Dong Ho Yang and Hyung-Jong Kim

Department of Internal Medicine, College of Medicine, CHA University, Seongnam, Korea

Correspondence and offprint requests to: Hyung-Jong Kim; E-mail: khj04@cha.ac.kr

### Abstract

Uraemic pleuritis and pericarditis are frequently observed in chronic renal failure patients and tend to improve with continued haemodialysis. However, certain cases have been reported that do not respond to continued haemodialysis alone. A 67-year-old female on long-term haemodialysis was diagnosed with uraemic pleuropericarditis and treated with intensive haemodialysis and given a non-steroidal anti-inflammatory drug to which she showed no response. We report a case of uraemic pleuropericarditis refractory to traditional therapy, which was treated successfully with corticosteroid therapy.

**Keywords:** pericarditis; pleuritis; refractory; uraemic

### Introduction

The development of pleural or pericardial effusion in end-stage renal disease (ESRD) patients is a relatively common occurrence arising from various causes. Uraemic pleuritis or pericarditis is usually characterized by serosanguineous or haemorrhagic exudate, and continued haemodialysis is known to be the most effective treatment method for this [1]. Repeated fluid aspiration, pleurodesis or decortication is a secondary option. However, these are invasive and unreliable [2]. Recently, two cases of refractory uraemic pleuritis and pericarditis that successfully responded to corticosteroid have been reported [3–4]. Herein, we report the third case of refractory uraemic pleuropericarditis that showed complete remission upon corticosteroid therapy.

### Case report

A 67-year-old woman with recurrent dyspnoea lasting for 2 weeks was referred. The patient was diagnosed with hypertension 25 years ago and had been receiving haemodialysis for the last 10 years. She was diagnosed with uraemic pleuropericarditis just 1 month ago and had been receiving intensive haemodialysis at our hospital (high-flux dialyser:

FMC F60S and the surface area: 1.3 m<sup>2</sup>, blood flow rate: 250 mL/min, dialysate flow rate: 500 mL/min, HD duration and frequency; for 4 h four times a week, no heparin use).

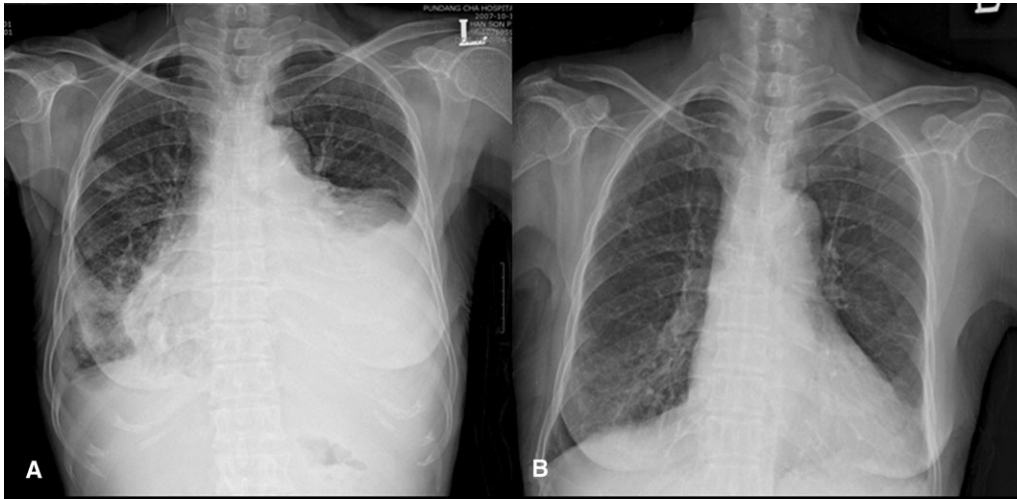On admission, her blood pressure was 160/90 mmHg, pulse rate was 110/min and body temperature was 37.9°C. Physical examination of her chest revealed decreased breathing sound on both lower lung fields. A simple chest x-ray demonstrated cardiomegaly, and loss of both costophrenic angles and echocardiography revealed a large amount of pericardial effusion. Laboratory data revealed a white blood cell count of 10 730/mm<sup>3</sup>, the haemoglobin concentration of 9.3 g/dL, the platelet count of 161 000/mm<sup>3</sup>, blood urea nitrogen of 43.0 mg/dL and serum creatinine of 6.1 mg/dL. The serum C-reactive protein (CRP) level was 6.08 mg/dL and the serum albumin level was 4.1 g/dL. No pathogenic bacteria were isolated from her sputum and blood cultures. Serologic tests revealed the absence of human immunodeficiency virus and hepatitis A, B and C virus. The anti-nuclear antibody, anti-neutrophil cytoplasmic antibody and anti-glomerular basement membrane antibody were all absent.

Upon thoracentesis, a haemorrhagic lymphocyte-predominant exudate was retrieved, and cytologic examination, bacterial culture and acid-fast staining all revealed negative findings. Adenosine deaminase (ADA) was slightly increased (75 IU/L) in pleural effusion. There was no significant difference between the findings of pleural and pericardial effusion.

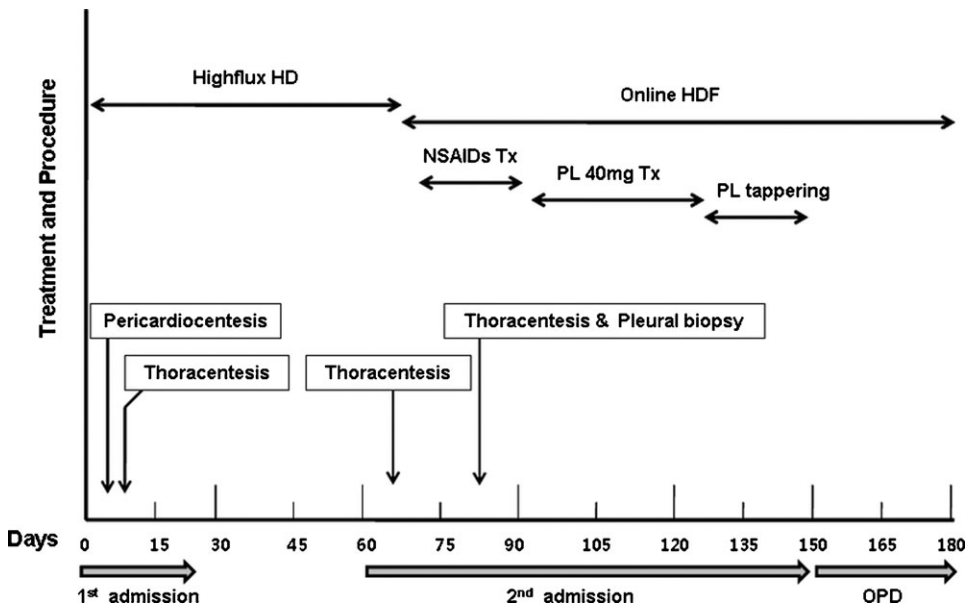
We diagnosed her as having recurrent uraemic pleuropericarditis and started treatment with on-line haemodiafiltration for 4 h each for four to six times a week without using heparin (dialyser: FMC F60S and the surface area: 1.3 m<sup>2</sup>, blood flow rate: 250 ml/min, dialysate flow rate: 500 ml/min, substitution dialysate flow rate: 180 ml/min).

Despite of administration of antibiotics and NSAIDs, no significant improvement was observed. She required repeated thoracentesis and pericardiocentesis for relief of symptoms, and the CRP level was as high as 30.50 mg/dL on the 58th hospital day.

A pleural biopsy was performed and thick fibrinous pleuritis was identified without evidence of infection or malignancy. After that, we administered prednisolone 40 mg/dL



**Fig. 1.** (A) Initial chest x-ray reveals cardiomegaly and both pleural effusion. (B) Follow-up chest x-ray 1 month after corticosteroid therapy shows completely improved pleural effusion and cardiomegaly.



**Fig. 2.** The clinical course of procedures and treatments. (HD, haemodialysis; NSAIDs, non-steroid anti-inflammatory drug; PL, prednisolone; OPD, outpatient department).

(1 mg/kg/day) orally. The patient's symptoms had abated by 1 week after the start of prednisolone therapy, and pleural and pericardial effusion had decreased (Figure 1). We maintained prednisolone at its initial dose for 36 days and tapered it by 10 mg a week. On the 71st hospital day, she was discharged without any symptoms, and the CRP level had decreased to 2.08 mg/dL (Figure 2).

## Discussion

The incidence of pleural or pericardial effusion in ESRD patients is ~20% [1–2]. Before making the diagnosis of uraemic pleuritis or pericarditis, other causes, such as overhydration, congestive heart failure, coronary artery disease,

infection, collagen vascular disease, malignancy etc., must be ruled out [1–2].

In our case, the diagnoses of infection, collagen vascular diseases or malignancy were ruled out both serologically and histopathologically. We also excluded heart problems because echocardiography revealed normal left ventricular systolic function without any regional wall motion abnormality. In uraemic pleuritis, pleural effusion is typically a serosanguineous or haemorrhagic lymphocyte-predominant exudate with pleural tissue exhibiting chronic fibrinous pleuritis [5], which was exactly the case with our patient.

The pathogenesis of uraemic pleuritis or pericarditis remains uncertain but underdialysis is proposed to be a reason considering the fact that the intensified continued

haemodialysis regimen has almost always been effective [1–2]. The prognosis of uraemic pleuritis or pericarditis is generally good. However, several cases refractory to continued haemodialysis that evolved into more severe clinical entities, such as pulmonary restriction or cardiac tamponade, have been reported [6]. Even though surgical decortication was suggested for the treatment of refractory pleuritis, this surgical procedure is dangerous for ESRD patients with comorbidity. Alternative therapeutic interventions for refractory uraemic pericarditis include pericardiocentesis, pericardiostomy with or without instillation of intrapericardial glucocorticoids, pericardial window and pericardiectomy [2]. NSAIDs have been found to have limited success in refractory uraemic pericarditis [2].

In our case, continued on-line haemodiafiltration, antibiotics and NSAIDs all proved futile in treating pleuropericarditis. Because the CRP level went on increasing, we made a decision to administer corticosteroid orally (1 mg/kg/day) to suppress nonspecific inflammation. Corticosteroid therapy showed an immediate effect on her disease progression and symptoms. Iyoda [3] and Kim [4] had reported cases of refractory pleuropericarditis and pleuritis successfully treated with corticosteroid. The patients had been on haemodialysis therapy for 5 and 13 years each before admission. In our case, the length of haemodialysis treatment before admission was 10 years. Including our patient, these three patients improved completely by corticosteroid therapy. This may imply that nonspecific inflammation might have been involved in the development of uraemic pleuropericarditis in long-term haemodialysis patients. Along with prednisolone, our patient took a proton

pump inhibitor due to a history of gastric ulcer. The patient has not experienced adverse effects of steroids including gastric ulcer recurrence.

To our knowledge, this is the third case report of conventional therapy-resistant uraemic pleuropericarditis that was successfully treated with systemic corticosteroid. Terminal complications of uraemic pleuropericarditis such as pulmonary restriction or constrictive pericarditis call for surgical intervention. However, except in those extreme cases, systemic corticosteroid therapy may be considered for the treatment of refractory pleuropericarditis.

*Conflict of interest statement.* None declared.

## References

1. Bakirci T, Sasak G, Ozturk S *et al.* Pleural effusion in long-term hemodialysis patients. *Transplant Proc* 2007; 39: 889–891
2. Maisch B, Seferović PM, Ristić AD *et al.* Task Force on the Diagnosis and Management of Pericardial Diseases of the European Society of Cardiology. Guidelines on the diagnosis and management of pericardial diseases executive summary. *Eur Heart J* 2004; 25: 587–610
3. Iyoda M, Ajiro Y, Sato K *et al.* A case of refractory pleuropericarditis—successful corticosteroid treatment. *Clin Nephrol* 2006; 65: 290–293
4. Kim KM, Cho JM, Park HJ *et al.* A case of refractory uremic pleuritis improved completely with corticosteroid treatment. *Clin Nephrol* 2008; 70: 451–452
5. Jarratt MJ, Sahn SA. Pleural effusions in hospitalized patients receiving long-term hemodialysis. *Chest* 1995; 108: 470–474
6. Gilbert L, Ribot S, Frankel H *et al.* Fibrinous uremic pleuritis: a surgical entity. *Chest* 1975; 67: 53–56

*Received for publication: 25.6.09; Accepted in revised form: 13.7.09*