

Scrotal Tissues: The Perfect Material for Urogenital Reconstruction

Ruben T. Adamyany, MD, PhD*†
 Armais A. Kamalov, MD, PhD*†
 Misak M. Ehoyan, MD, PhD*†
 Olesya I. Starceva, MD, PhD*†
 Eduard N. Urshevich, MD, PhD*†
 Mikhail Y. Sinelnikov, MD, PhD*†

Background: Correction of male urogenital pathology of different severity is complicated by the anatomical aspects of the penis. Skin texture, internal structures, and perfusion dynamics of the urogenital area make it a difficult area to reconstruct. We provide our experience with axial scrotal flaps for correction of penile defects of different severity and believe that these local flaps offer sufficient tissue characteristics for proper restoration of this complex region.

Methods: Forty-eight patients were divided into 3 groups depending on penile defect genesis and severity. Axial scrotal flap reconstruction was used for the correction of defects in all cases, when necessary in combination with other flaps.

Results: Axial scrotal flaps for total and subtotal penile reconstruction serve as valuable material for reconstruction of the urogenital area, and are to be combined with other flaps for restoration of bulk tissues. Localized defects of the penis and urethra reconstructed by axial scrotal flaps provide excellent aesthetic results with minimal scarring, stable perfusion dynamics, and high satisfaction rate.

Conclusions: Scrotal tissues provide an excellent reconstruction material for penile defects because of their highly similar tissue structure as that of the penis. Scrotal axial flaps do not provide excess bulking in the postoperative period and are recommended for reconstruction of urethral and localized penile defects. Multistage surgery is recommended in cases of severe tissue damage, in combination with other flaps (inguinal, thoracodorsal, and radial). (*Plast Reconstr Surg Glob Open* 2020;8:e2948; doi: 10.1097/GOX.0000000000002948; Published online 24 July 2020.)

INTRODUCTION

Correction of urogenital pathology in plastic surgery remains an important subject. Congenital deformities, trauma, and other acquired defects of the urogenital zone require specialized treatment. Methods for correction of urogenital defects range from autodermoplasty, rotational flaps, mucosal flaps to more complex microsurgical procedures.¹ Severity of the defect dictates the choice of reconstruction, and in some instances, when traditional reconstructive methods are ineffective, or the choice for

free flaps is limited, the surgeon must still choose the best donor site for defect closure.² Individualization of surgical protocol is necessary for a positive treatment outcome.³ When microsurgical reconstruction is unavailable, or not possible, we believe that axial scrotal tissues are excellent reconstructive material for surgical correction of urogenital defects in males.

Scrotal perfusion is based on 2 separate arterial pools: 1 from the external iliac artery and 1 from the internal iliac artery (Fig. 1). Blood from these vascular pools supplies the anterior and posterior scrotal surfaces.^{4,5} Current knowledge of scrotal perfusion indicates 3 perfusion zones: 2 lateral and 1 central. The central zone includes the midline raphe and receives blood supply from septal arteries. Previous knowledge that the perineal arteries provide blood supply only to the posterior scrotal surface proved to be incorrect. All of the scrotal skin up to the midline penile raphe receives blood supply from the perineal arteries and their branches.⁶ Understanding anatomical aspects of these branches is required for proper flap mobilization. The perineal arteries branch from the internal pudendal arteries considerably deep and are not damaged during primary incision and superficial dissection.⁷

Several authors have used the updated knowledge of scrotal anatomy to improve patient care, effectively

From the *Department of Plastic and Reconstructive Surgery, Petrovsky National Research Centre of Surgery, Moscow, Russian Federation; †Department of Oncology, Radiotherapy and Plastic Surgery, Sechenov University, Moscow, Russian Federation; and ‡Institute of Regenerative Medicine, Sechenov University, Moscow, Russian Federation.

Received for publication January 7, 2020; accepted May 8, 2020.

Presented at the VIII National Plastic Surgery Congress, December 5-7, 2019, Moscow, Russian Federation.

Copyright © 2020 The Authors. Published by Wolters Kluwer Health, Inc. on behalf of The American Society of Plastic Surgeons. This is an open-access article distributed under the terms of the [Creative Commons Attribution-Non Commercial-No Derivatives License 4.0 \(CCBY-NC-ND\)](https://creativecommons.org/licenses/by-nc-nd/4.0/), where it is permissible to download and share the work provided it is properly cited. The work cannot be changed in any way or used commercially without permission from the journal.

DOI: 10.1097/GOX.0000000000002948

Disclosure: The authors have no financial interest to declare in relation to the content of this article.

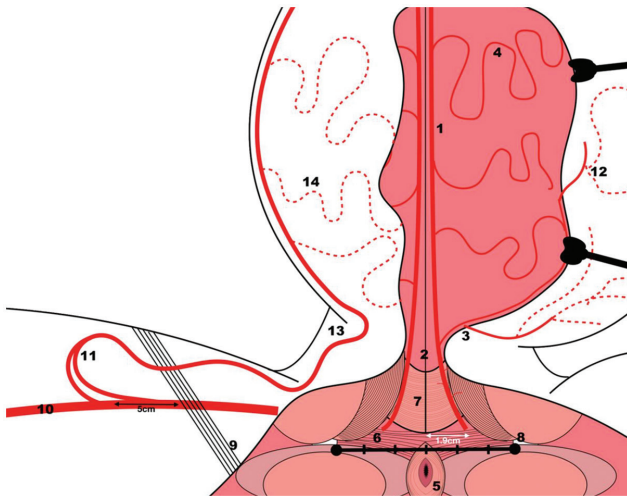


Fig. 1. Schematic of scrotal perfusion. 1, Great branch of perineal artery; 2, median raphy; 3, cutaneous branch of perineal artery; 4, septal arteries; 5, anal sphincter; 6, superficial transverse perineal muscle; 7, bulbospongiosus muscle; 8, ischial tuberosity; 9, inguinal ligament; 10, femoral artery; 11, superior and inferior external pudendal arteries; 12, anastomosis between perineal and external pudendal vascular systems; 13, midpoint of scrotal base (entry of external pudendal artery—becoming the anterior scrotal artery); 14, numerous branches from external pudendal arteries feeding skin.

applying scrotal flaps with axial perfusion in their clinical work. Guo et al⁸ provide a series of 17 patients showing the effectiveness of a 2-stage penile reconstruction with scrotal flaps. Pungrasmi et al⁹ conducted an anatomical and functional outcomes study after applying a bilateral scrotal flap in penile reconstruction for the treatment of penile foreign-body granuloma. The authors provide an 18-patient series with positive results, concluding that a 1-stage bilateral scrotal flap is a good option for penile reconstruction.⁹ Scrotal flaps have been successfully applied in the treatment of concealed penis congenital deformity. Han

et al¹⁰ evaluated 12 patients who underwent penile reconstruction with advanced musculocutaneous scrotal flaps. The scrotal flaps provided high aesthetic results and high postoperative satisfaction with high flap viability.¹⁰ Moussa et al¹¹ provided a valuable insight on the importance of scrotal flaps, even in regions with limited specialist availability, advocating the effectiveness, easiness, and reliability of this method in clinical practice. Our study outlines the vast applicability of scrotal flaps for the treatment of various urogenital defects of different severity.

METHODS

Forty-eight male patients (aged 23–57 years) who underwent urogenital reconstruction with scrotal flaps were included in this study. Prerequisites for the choice of this reconstruction method were complex phalloplasty and/or urethroplasty procedures, with intact scrotal donor-site zone and patient consent. Axial cutaneous scrotal flaps were used for reconstruction of penile, urethral, and combined defects. Preoperative evaluation of scrotal tissue viability was performed via ultrasound examination of 2 main vessels: the external pudendal artery and the perineal artery. Any noted damage to these vessels would undermine the efficacy of the procedure. Intraoperative findings on vascular anatomy aspects were documented, and these played a significant role in the advancement of further clinical cases. Each patient was monitored for 12 months after surgical procedure, with routine checkups and evaluation of function restoration.

Forty-eight patients were divided into 3 distinct groups according to preoperative diagnosis (Table 1). Group 1 included patients with total and subtotal penile amputation due to oleogranulematosis (4 patients), mechanical trauma (3 patients), electric trauma (1 patient). Group 2 included patients with localized soft tissue penile defects due to trauma (28 patients), infection (6 patients), and iatrogenic pathology (2 patients). Group 3 included 4 patients with urethral defects due to polyacrylamide gel injection.

Table 1. Treatment Results

	Total and Subtotal Penile Amputation (Group 1)	Soft-tissue Penile Defect (Group 2)	Urethral Defect (Group 3)	Total
No. patients (N)	8	36	4	48 (100%)
Mild complications				
Large scar without functional defect	1	2	0	3 (6.25%)
Bulky flap	0	1	0	1 (2.08%)
Transitory perfusion-related complications	1	2	0	3 (6.25%)
Urethritis	0	1	1	2 (4.17%)
Group subtotal	2 (25.00%)	6 (16.67%)	1 (25.00%)	—
Moderate complications				
Fistula	1	0	0	1 (2.08%)
Abscess formation	1	0	0	1 (2.08%)
Marginal flap necrosis	0	2	0	2 (4.17%)
Hematoma	0	1	0	1 (2.08%)
Group subtotal	2 (25.00%)	3 (8.33%)	1 (25.00%)	—
Severe complications				
Urethral stricture	0	2	0	2 (4.17%)
Urethral necrosis	1	0	0	1 (2.08%)
Bleeding	0	1	0	1 (2.08%)
Group subtotal	1 (12.50%)	3 (8.33%)	0 (0%)	—
Overall complication rate	5 (62.50%)	12 (33.33%)	1 (25.00%)	18 (37.50%)
Flap loss rate	1	0	0	1 (2.08%)
Revision rate	2	6	1	9 (18.75%)
Patient satisfaction median (according to 6 mo survey)	88.75%	83.89%	87.5%	86.71%

Table 2. Total and Subtotal Penile Amputation Group (Group 1)

Pathology	No. Patients	Surgical Procedure	Complications	Total Complication Rate
Oleogranulematosis	4	Sanation + reconstruction with axial scrotal flaps and intrascrotal tunnel flap modification	Total flap loss (1) Fistula, abscess (1) Urethral necrosis (1)	5 (62.5%)
Mechanical trauma	3	Reconstruction with axial scrotal flaps and intrascrotal tunnel flap modification or thoracodorsal flap or radial flap	Transitory perfusion-related complications (1)	
Electric trauma	1	Axial flaps + inguinal flap	Large scar (1)	

Table 3. Localized Soft Tissue Defect Group (Group 2)

Pathology	No. Patients	Surgical Procedure	Complications	Total Complication Rate
Trauma	9	Double axial scrotal flaps	Large scar (2) Marginal flap necrosis (2) Hematoma (1)	12 (33.33%)
	19	Single-sided axial scrotal flap	Transitory perfusion-related complications (1) Bleeding (1) Urethral stricture (1)	
Infection	6	Single-sided axial scrotal flap	Transitory perfusion-related complications (1) Urethritis (1) Urethral stricture (1)	
Iatrogenic	2	Single-sided axial scrotal flap	Bulky flap (1)	

The surgical methods used for the treatment of patients depended on defect severity and ranged from single-sided scrotal axial flap for defect closure to a combination of multistage stacked flap methods (Tables 2, 3). Scrotal axial flaps for the closure of urogenital defects of different genesis requires an intact donor site. In cases of localized penile trauma, axial scrotal flaps were used for formation of a neophallus and defect closure (Fig. 2). The chosen method provided positive cosmetic and functional recovery of the penis. Mobilized axial scrotal flaps were used to cover posttraumatic tissue defects through transposition and remodeling of the penis. Often, axial flaps were used for reconstruction of the urethra.

In the total and subtotal penile amputation group (Group 1), the main pathology was oleogranulematous deformity and strangulation of the penis (Fig. 3), which we believe plays a major role in the high complication

rate (Table 2). In patients with oleogranulematosis of the penis, surgical closure with axial flaps was possible if the scrotal tissues were intact and unaffected by injected Vaseline or polyacrylamide gel. Patients in this group presented with necrosis of the cavernous bodies with partial urethral defect. The scrotal tissues served as a plastic material to repair the urethral defect, while the integumentary tissues of the penis were formed by other methods, such as the inguinal flap and intrascrotal tunnel method modification (Fig. 4). Patients in Group 1 also included patients with traumatic total and subtotal amputation of the penis. Surgical amputation was performed on patients with complete penile necrosis. In this group, patients received reconstruction with stacked flaps. Scrotal axial flaps were used for reconstruction of the urethra, and larger flaps (inguinal, thoracodorsal, and radial flaps) were used for penile reconstruction (Fig. 5). A modification of the

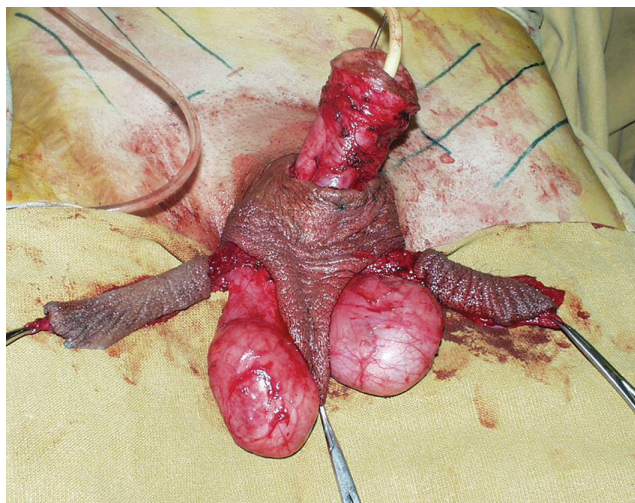

Fig. 2. Local rotational scrotal flaps for penile reconstruction.

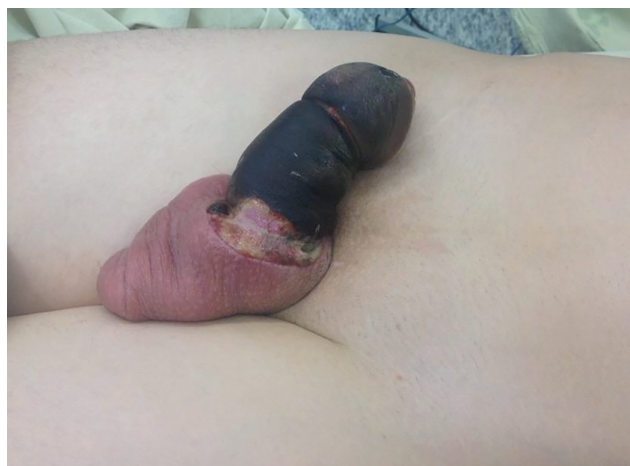

Fig. 3. Subtotal necrotic pathology of the penis, requiring subtotal amputation.

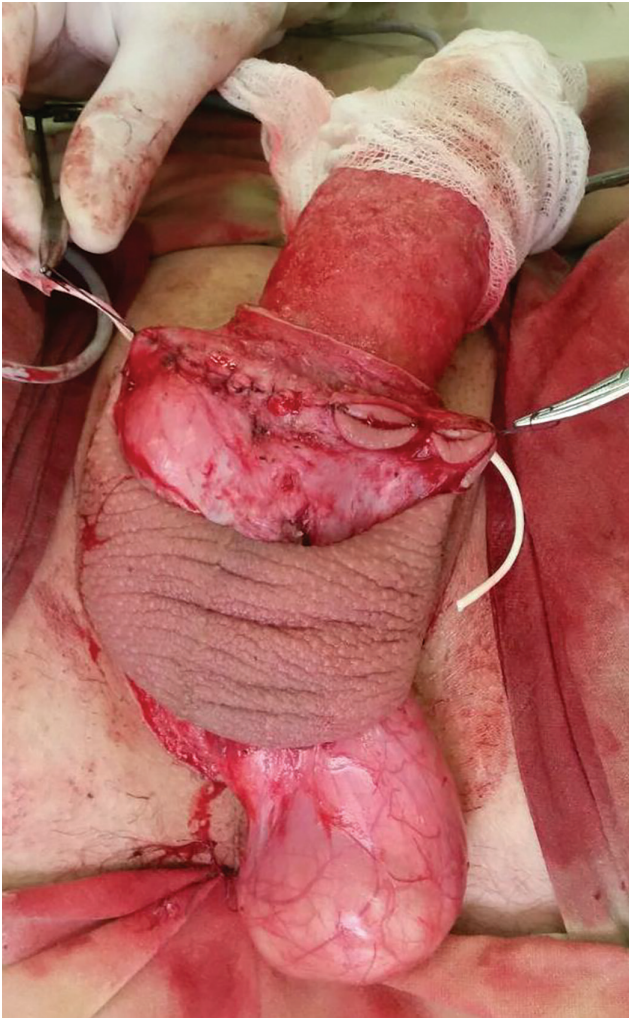


Fig. 4. Marking for intrascrotal tunneling (modified Sapozhkov's method).

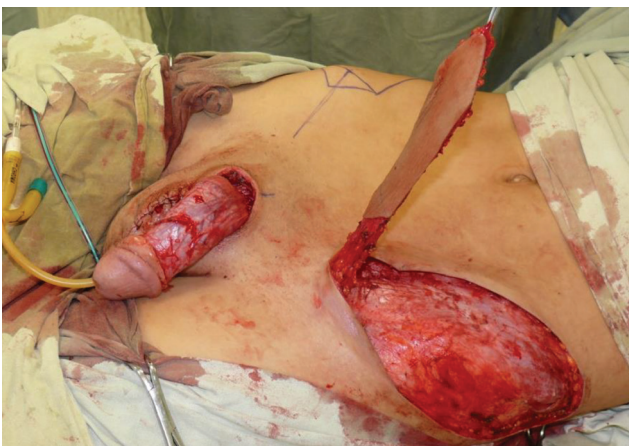

Fig. 5. Preparation of combined flaps for defect reconstruction.

intrascrotal tunnel method for reconstruction of penile body included 2 stages of surgery. During the primary stage, 2 separate scrotal tunnels are created: one longitudinal and one perpendicular near the base of the penis. The

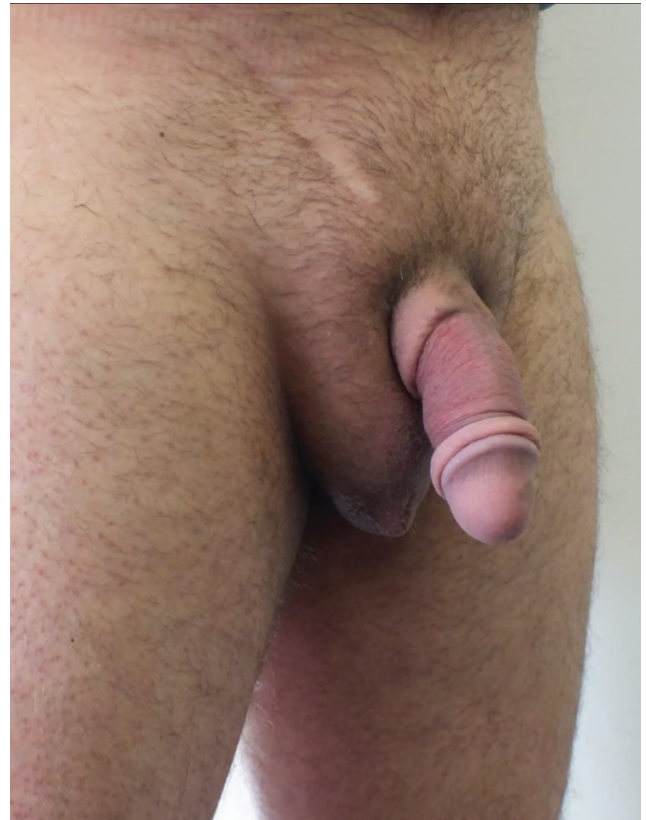


Fig. 6. Postoperative result of 2-stage reconstruction of penis by modified Sapozhkov method with scrotal flaps.

longitudinal tunnel later serves as the intrascrotal tunnel for penile burying. The perpendicular tunnel is inverted, with the skin forming the inside of the tunnel near the base of the penis. During secondary surgery, this cutaneous tunnel is opened and attached at the base of the penis, thereby eliminating the area of high risk of necrosis. The longitudinal tunnel is used for closure of the distal penile shaft. The intrascrotal tunnel is released at a later stage for providing additional closure of the distal penile shaft, allowing for foreskin creation when desired (Fig. 6).

Patients in Group 2 included patients with penile tissue traumatization of different extent but not significant enough to classify as subtotal amputation (Table 3). Patients in this group required closure of defects with axial scrotal flaps. Bilateral axial scrotal flaps were used in 9 patients, and in 27 cases, a single-sided pedicled scrotal flap was used for defect closure.

Group 3 included patients with urethral defects due to injection of polyacrylamide gel. These patients are considerably rare, and axial scrotal flap closure was used for urethral defect reconstruction. Localized urethral defects in all cases required consequent reconstruction of the corpus cavernosum with local rotational inguinal flaps (Fig. 7).

Patient satisfaction was analyzed by surveying patients on their 6-month follow-up. Rating of sexual intercourse quality, overall aesthetics, urination, pain, and satisfaction with size were included in the survey. Overall satisfaction

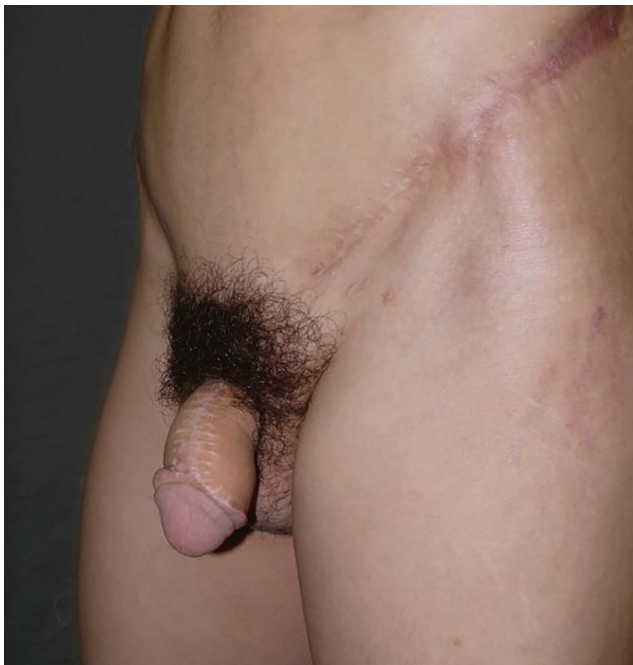

Fig. 7. Penis following combined reconstruction with stacked flaps.

was rated on a 1–10 scale by the patients, with 1 being completely dissatisfied and 10 being completely satisfied.

RESULTS

A total of 8 penile amputation (Fig. 8), 36 localized soft-tissue defect, and 4 isolated urethral lesion patients were included in this study. The results are shown in Tables 1–3. The highest complication rate was seen in the total and subtotal penile amputation patient group (62.5%), which, we conclude, is due to the complexity of the surgery and significant perfusion restructurization in bilateral scrotal flaps. Mild complications did not impact surgical outcome and occurred at an overall higher rate (18.75%) than moderate (10.42%) and severe complications (8.33%). Total flap loss rate was 2.08%, occurring in one patient with subtotal penile amputation due to oleo-granulematosis of the penis after Vaseline injection. The main reason for flap loss was inconsistency of perfusion dynamics due to restructurization of blood flow following substance migration. Patient satisfaction after surgery was high, yet in Group 1, it was lower as a result of significant penile deformation due to excision of tissues embedded with Vaseline, resulting in higher dissatisfaction with cosmetic results or excessive scarring due to electric trauma. In the second group, an exclusive case of correction of excessive circumcision yielded great functional and aesthetic results, underlying the importance of scrotal flap application in conservative penile reconstruction (Fig. 9).

In Group 2, a higher complication rate was characteristic of the double axial scrotal flap subgroup, mostly due to a larger scar and longer operating time. A dangerous complication occurred in 1 patient with a prior penile abscess; the patient developed urethritis and postoperatively an

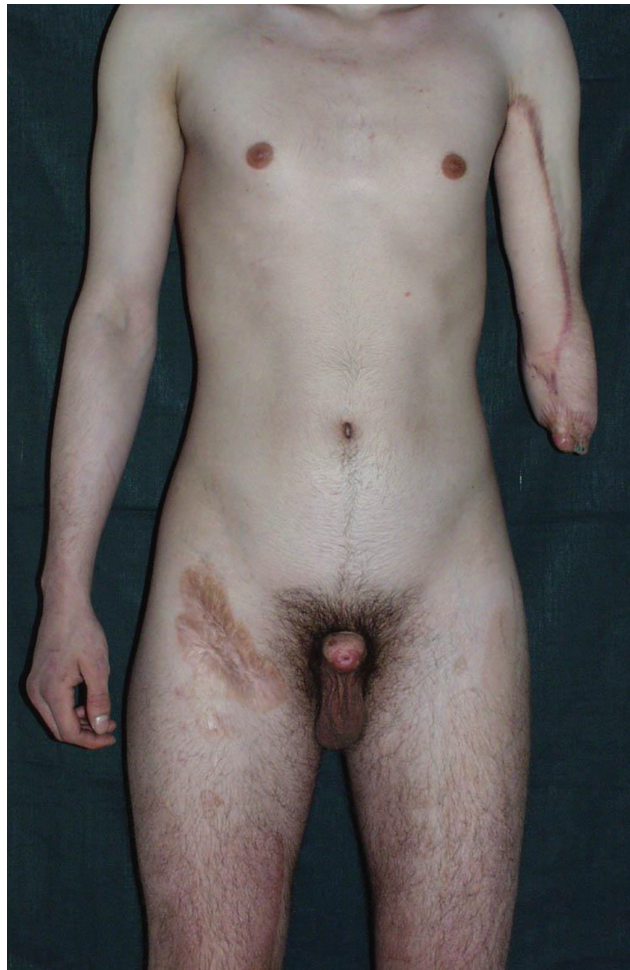

Fig. 8. Total penile amputation case.

urethral stricture, which required a revision. This was due to improper catheterization of the patient in the postoperative period. A bulky flap was seen in 1 case, due to overestimation in defect size, but this complication is easily corrected with secondary aesthetic surgery. More so, we advise adding excess tissue to close the defect to prevent postoperative contraction of the flap.

Group 3 showed the lowest complication rate, despite significant surgical difficulties accompanied with layered flaps. The axial perfusion of scrotal flaps is very stable; so no perfusion-related complications or flap necrosis were seen in the flaps covering urethral defects (Fig. 10). Overall aesthetic and functional results were satisfactory.

DISCUSSION

Our study has shown that scrotal flaps have outstanding capabilities for urogenital defect closure due to high tissue elasticity, mobility, and abundant perfusion. We have applied several different techniques for scrotal flap reconstruction: axial scrotal flaps (1-sided and 2-sided), longitudinal scrotal flap (used for urethral reconstruction), modified intrascrotal tunneling (for 2-staged reconstruction), and stacked flaps (scrotal flap combined with another flap for bulk reconstruction).

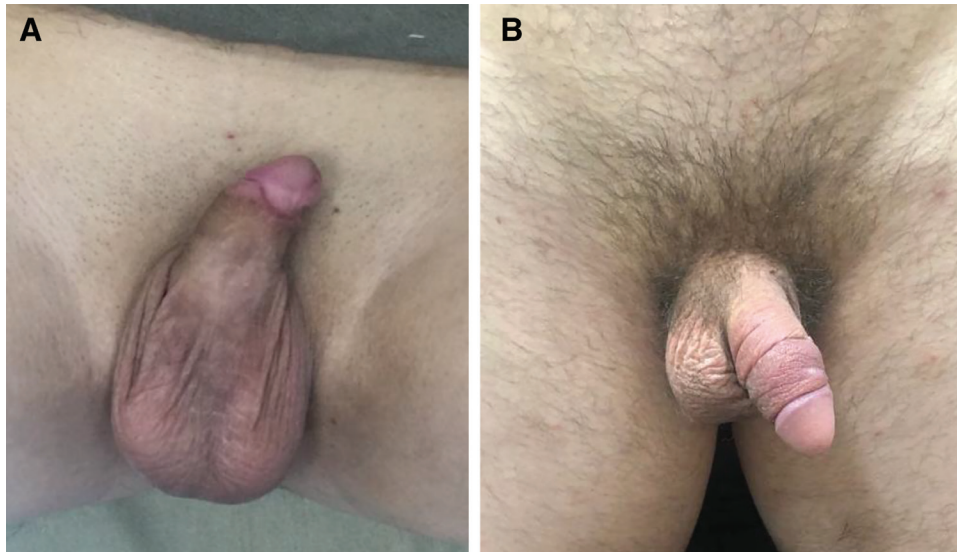


Fig. 9. Correction of excessive circumcision with scrotal axial flaps. A, Dorsal view. B, Frontal view.

The abundance of possible reconstruction methods with tissues of the scrotum is primarily due to the nature of scrotal skin vascularization. The tissue is perfused from 2 arterial pools: the peroneal artery, which continues in the scrotal tissue through the great branch of the peroneal artery, and the external pudendal arteries. The peroneal artery dominates medial perfusion, branching laterally along the septum, creating multiple anastomoses with the external pudendal artery, which enters the scrotum bilaterally. The vast interconnections between these 2 arterial pools accounts for high viability of scrotum tissues after separation, rotation, and modification in the recipient zone.

Our modification of the intrascrotal tunneling method for penile reconstruction uses the complex and abundant

vascular anatomy of the scrotum. The main drawback of previously described methods for intrascrotal tunneling is the high instances of skin flap necrosis at the penile base after reconstruction.^{8,12} The classic intrascrotal reconstruction method includes 2 stages of surgery. The primary stage involves surgical denudation of the defected tissues and burying of the exposed deep penile tissues into an intrascrotal tunnel. This tunnel is made by 2 incisions on the scrotum and by subcutaneous and subfascial tunneling. The denuded penis is then inserted into this tunnel and sutured. Before secondary surgery, the 2 formed fasciocutaneous pedicles are trained by intermittent restriction of blood flow. The resulting intermittent ischemia prepares the skin flaps for consequent division and reconstruction.¹³ The second surgical procedure involves the release of the fasciocutaneous pedicles and suturing along the penile midline. Our modification with the inclusion of a secondary intrascrotal tunnel at the base of the penis allows for preservation of penile length and aesthetic characteristics with minimization of flap necrosis (Fig. 11).

Our study helps stratify current knowledge on scrotal flaps and their application according to defect severity. Axial scrotal flaps have been successfully applied in urethral reconstruction and penile reconstruction.^{14,15} Our study shows that application for axial scrotal flaps is most effective in closure of limited urethral defects and localized soft tissue defects of the penis. The use of these flaps for reconstruction of extensive and deep defects requires secondary flaps for bulk tissue restoration.

Longitudinal scrotal flaps were solely used for urethral reconstruction. This flap has been previously described as a U-shaped scrotal flap,¹⁶ tubed scrotal flap,¹⁷ biaxial scrotal flap,¹⁸ yet we believe “longitudinal scrotal flap” better characterizes the main definitive characteristic of this flap. Longitudinal scrotal flaps provide excellent results in urethral reconstruction. For bulk penile reconstruction, the longitudinal scrotal flap provides excellent stability

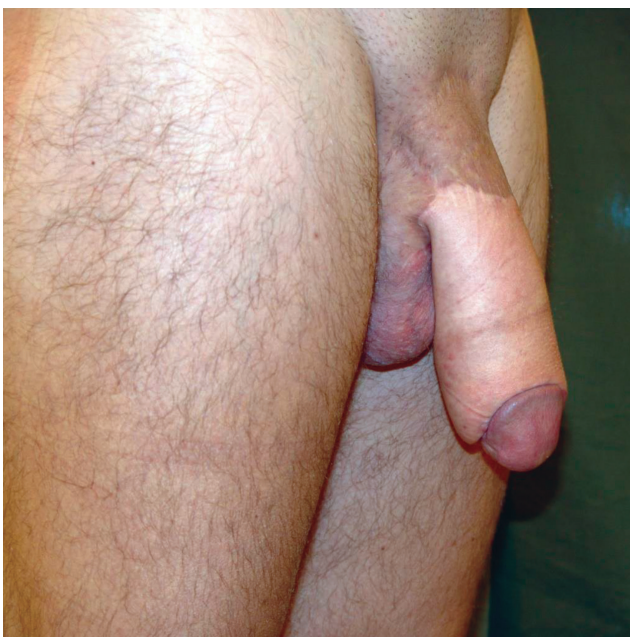

Fig. 10. Penile reconstruction with scrotal and inguinal flaps.

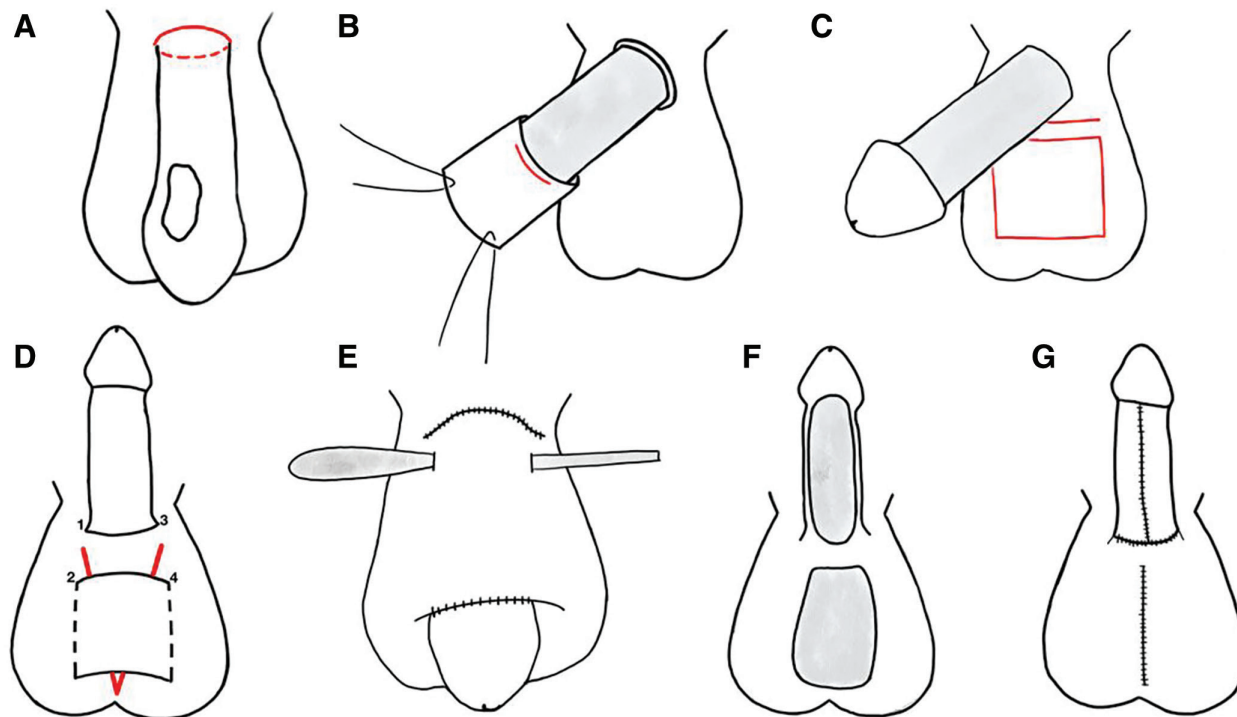


Fig. 11. Modification of intrascrotal tunneling method for penile reconstruction. A, defect of penile skin; red markings indicate penile base; B, surgical denudation; red marking indicates head of penis projection; C, marking for modified intrascrotal tunneling method; D, formation of longitudinal and perpendicular tunnels, the perpendicular tunnel is formed by tunneling the skin inward between points 1–2 and 3–4; red markings represent forceps inserted into the longitudinal intrascrotal tunnel; E, the buried denuded penis in the longitudinal intrascrotal tunnel and a stylet inserted into the perpendicular tunnel, which is located under the buried penis near the base; F, secondary surgery—separation of fasciocutaneous flaps from the scrotum and release of the perpendicular tunnel with resulting intact tissues near the penile base; G, suturing of reconstructed penis and scrotum.

and functional restoration. Postoperative catheterization is necessary for restoration of urine flow.

The localization, skin qualities, and functional stability of scrotal flap make it the perfect flap for penile reconstruction. Skin elasticity of scrotal tissues is high, which is necessary for proper erectile function in the postoperative period and facilitates better patient rehabilitation. In our clinical practice, the axial scrotal flaps have shown to provide best results in closure of localized defects, with minimal perfusion-related complications, low flap loss rate, and highly stable results. Total and subtotal penile reconstruction with scrotal flaps requires additional material for defect closure. For this reason, it is advisable to perform a 2-stage surgery with prefabrication of the neopenis via intrascrotal tunneling, thereby extending the defect closure capabilities and providing soft, elastic skin on the neopenis.

Mikhail Y. Sinebnikov, MD, PhD
 Abrikosovskiy, 2
 Moscow, Russia 119991
 E-mail: snlnkv15@gmail.com

REFERENCES

- Bertrand LA, Warren GJ, Voelzke BB, et al; TURNS. Lower urinary tract pain and anterior urethral stricture disease: prevalence and effects of urethral reconstruction. *J Urol.* 2015;193:184–189.
- Elmoghazy H, Hussein MM, Mohamed E, et al. A novel technique for repair of mid-penile hypospadias using a preputial skin flap: results of 110 patients. *Int Urol Nephrol.* 2016;48:1943–1949.
- Elmoghazy H. Use of bipediced dorsal penile flap with Z release incision: a new option in redo hypospadias surgery. *Urology.* 2017;106:188–192.
- Jiang ZY, Li XD, He QX, et al. [Application of tunica dartos flap coverage to tubularized incised plate urethroplasty]. *Zhonghua Nan Ke Xue.* 2013;19:927–930.
- Angspatt A, Pungrasmi P, Jindarak S, et al. Bilateral scrotal flap: pedicle and dimension of flap in cadaveric dissections. *J Med Assoc Thai.* 2009;92:1313–1317.
- Carrera A, Gil-Vernet A, Forcada P, et al. Arteries of the scrotum: a microvascular study and its application to urethral reconstruction with scrotal flaps. *BJU Int.* 2009;103:820–824.
- Kamalov AA, Kirpatovskiy VI, Ohobotov DA, et al. Collagen biomatrices in reconstructive urology. *Urologia.* 2015;2:103–106.
- Guo L, Zhang M, Zeng J, et al. Utilities of scrotal flap for reconstruction of penile skin defects after severe burn injury. *Int Urol Nephrol.* 2017;49:1593–1603.
- Pungrasmi P, Chayasadom A, Angspatt A. Anatomical and functional outcome after bilateral scrotal flap in penile reconstruction. *Asian Biomed.* 2014;8:83–86.
- Han DS, Jang H, Youn CS, et al. A new surgical technique for concealed penis using an advanced musculocutaneous scrotal flap. *BMC Urol.* 2015;15:54.

11. Moussa M, Abou Chakra M. Scrotal Dartos-Fascio-Myo-Cutaneous flaps for penis reconstruction after iatrogenic skin shaft sub-amputation. *J Surg Case Rep.* 2019;2019:rjz206.
12. Wilson CL, Wilson MC. Plastic repair of the denuded penis. *South Med J.* 1959;52:288–290.
13. Civelek B, Selcuk T, Bilgen E, et al. Intermittent ischaemia of skin flaps shortens time taken to divide pedicles: an experimental study in rats. *Scand J Plast Reconstr Surg Hand Surg.* 2009;43:241–244.
14. Jordan GH. Scrotal and perineal flaps for anterior urethral reconstruction. *Urol Clin North Am.* 2002;29:411–416, viii.
15. Isken T, Onyedi M, Sen C, et al. A novel application for repair of skin defects of the penis: anterior scrotal artery flap. *Plast Reconstr Surg.* 2009;124:181e–182e.
16. Blandy JP, Singh M, Tresidder GC. Urethroplasty by scrotal flap for long urethral strictures. *Br J Urol.* 1968;40:261–267.
17. Belman AB. The repair of a congenital H-type urethrorectal fistula using a scrotal flap urethroplasty. *J Urol.* 1977;118:659–661.
18. Gil-Vernet J, Arango O, Gil-Vernet A, et al. A new biaxial epilated scrotal flap for reconstructive urethral surgery. *J Urol.* 1997;158:412–420.