

Congenital erythropoietic porphyria with two mutations of the uroporphyrinogen III synthase gene (Cys73Arg, Thr228Met)

Zoran Gucev, Nevenka Slavevska, Velibor Tasic, Nevenka Laban, Nada Pop-Jordanova, Dragan Danilovski, Jacqueline Woolf¹, Duncan Cole¹

Clinical Center, Faculty of Medicine Skopje, 50 Divizija BB, 1000 Skopje, Macedonia, ¹Department of Medical Biochemistry and Immunology, University Hospital of Wales, Heath Park, Cardiff, UK

Congenital erythropoietic porphyria (CEP) is an autosomal recessive inborn error of metabolism that results from the markedly deficient activity of uroporphyrinogen III synthase (UROS). We describe a 14-year-old girl with red urine since infancy, progressive blistering and scarring of the skin, and moderate hemolytic anemia. After years of skin damage, her face is mutilated; she has a bald patch on the scalp, hypertrichosis of the neck, areas of skin darkening, and limited joint movements of the hands. Total urine excretion and fecal total porphyrin were both markedly raised above normal levels. Sequencing of the UROS gene identified two mutations causing CEP (Cys73Arg, Thr228Met). The patient lesions are progressing. Bone marrow transplantation and/or gene therapy are proposed as the next steps in her treatment. In brief, we describe a CEP with confirmed two pathogenic mutations, severe phenotype and discuss the various treatment options available.

Key words: Congenital erythropoietic porphyria, mutation of the uroporphyrinogen III synthase gene, severe phenotypes, treatment

of a specific enzyme of the heme biosynthetic pathway.^[1] Depending on the site of predominant porphyrin accumulation, the porphyrias are grouped into the following two types: erythropoietic and hepatic.^[2] The following three different erythropoietic porphyrias (EP) have been reported: erythropoietic protoporphyria (EPP, MIM 177000), congenital erythropoietic porphyria (CEP, MIM 263700), and hepatoerythropoietic porphyria (MIM 176100). CEP or Günther's disease is an autosomal recessive disease resulting from deficient uroporphyrinogen III synthase (UROS) activity.^[1] The clinical manifestations include chronic hemolysis, anemia, erythrodontia, and disfiguring cutaneous lesions.^[3] Here, we describe a 14-year-old Macedonian girl with CEP, severe cutaneous disfiguration, and a known set of mutations (Cys73Arg, Thr228Met).

Introduction

The inherited porphyrias are disorders of heme biosynthesis resulting from the deficient activity

Case Report

At the age of 6 months, the patient was referred to our hospital for investigation of episodes of red urine. She was born at term after an uneventful pregnancy and delivery. Her birth weight and length were 2 900 g and 51 cm, respectively. As a 3-week-old neonate, she received a blood transfusion for, it was believed, hemolytic anemia of the newborn. In all three of her hospital admissions, a mild hemolytic anemia was diagnosed. At the age of 6 years, she was again admitted for investigation, on this occasion with a main complaint of easy skin blistering

Access this article online

Quick Response Code:



Website:

www.ijhg.com

DOI:

10.4103/0971-6866.86199

Address for correspondence: Prof. Zoran Gucev, Medical Faculty Skopje, 50 Divizija BB, 1000 Skopje, Macedonia.
E-mail: gucevz@gmail.com

and scarring. It was noted that the intensity of the red coloration of the urine varied from day to day. Physical examination revealed multiple blistering and scarring on areas of the skin exposed to the sun [Figures 1 and 2] and hypertrichosis on the back [Figure 3]. The spleen was of normal size and physical and intellectual development was normal. Again, moderate hemolytic anemia was also found (red blood cells: 3.68×10^6 , hemoglobin: 10.6 g/dl, hematocrit: 33.0%, MCV 89.7, MCH 28.8 pg, MCHC 32.1 G/DL, platelets $124 \times 10^3 \mu\text{l}$, white blood cells: 3.6×10^3 , reticulocytes: 58 [5-15]), but did not require a blood transfusion. Further laboratory investigations were as follows: urea, creatinine, uric acid, electrolytes, and alkaline phosphatase were normal. Ultrasound examination of the kidneys and heart were normal and bone densitometry was unremarkable.

Now, aged 14 years, the severe photosensitive skin damage that had started in early childhood has led to disfiguring deformity of the face and hands [Figures 4 and 5]. Using all available measures to protect herself from the sun (hat, eyeglasses, cosmetic camouflage, and long sleeves) has not succeeded in protecting her from the mutilating effects of sun. This has caused scarring of her skin at sun-exposed sites, including the backs of the hands, her face, and ears, and has resulted in bald patches on the scalp. In addition, she has restricted hand function due to scarring of the skin and has lost some of her eyelashes, which has made her eyes prone to irritation from small particles of dust. Moderate hypertrichosis on the back of the neck was also noted and her teeth have progressively stained brownish-red.

The results of the biochemical investigations are

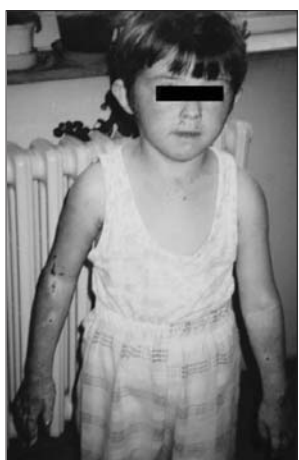

Figure 1: Age 6 years: facial appearance, blistering and scarring on the hands

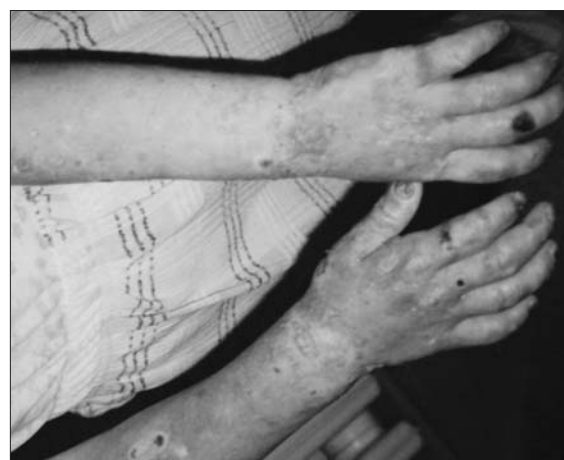

Figure 2: Age 6 years: the hands: blistering and scarring

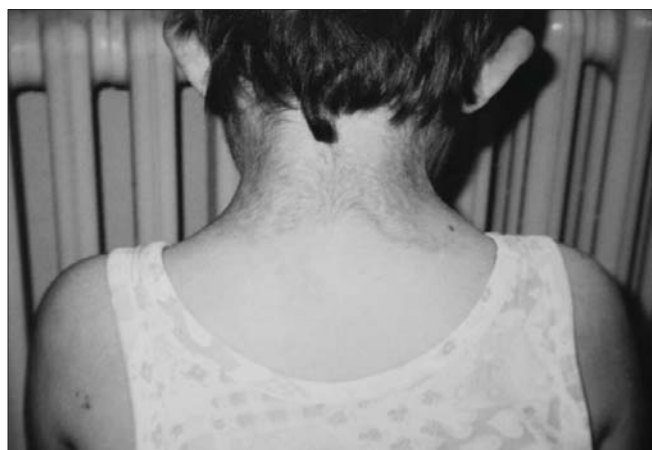

Figure 3: Age 6 years: Hypertrichosis on the back of the neck

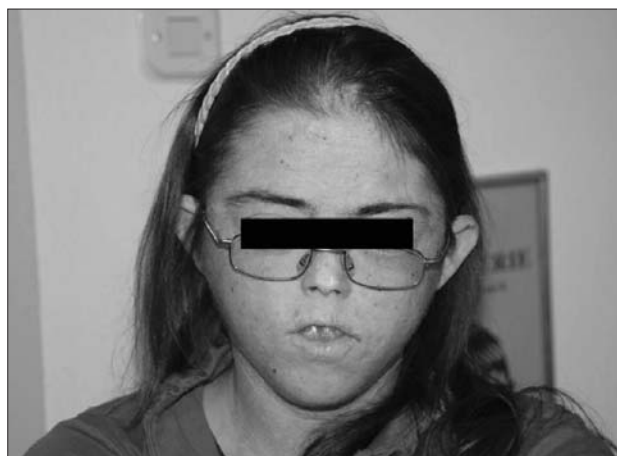

Figure 4: Age 14 years: facial appearance

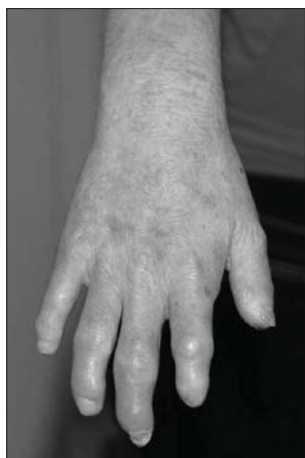

Figure 5: Age 14 years: the hands, scarring, arthrogyrosis

Table 1: High-pressure liquid chromatography of the urine demonstrated 85% of the uroporphyrin to be of isomer I type and fecal fractionation showed mainly coproporphyrin isomer I

Sample type	Analysis	Result	Units	Normal range
Urine	Porphyrin: creatinine ratio	14942	nmol/mmol	<34
"	Porphobilinogen: creatinine ratio	0.2	Umol/mmol	<1.5
"	Aminolevulinic acid: creatinine ratio	4.8	Umol/mmol	<5.2
Faeces	Total porphyrin	7544	nmol/g (dry wt)	<200
Erythrocyte	Total protoporphyrin	36.4	Umol/L	0.4-1.7
"	Zinc protoporphyrin	15	%	75
"	Free protoporphyrin	85	%	25
Plasma	Fluorescence emission	617	nm	-

summarized in Table 1. Total urine excretion^[4] and fecal total porphyrin^[5] were both markedly raised above normal levels. High-pressure liquid chromatography^[6] of the urine demonstrated 85% of the uroporphyrin to be of isomer I type and fecal fractionation showed mainly coproporphyrin isomer I [Figure 6]. Urinary aminolevulinic acid and porphobilinogen levels were within normal limits. The erythrocyte protoporphyrin level was greatly increased in both zinc and free forms. Plasma fluorescence spectroscopy revealed a prominent emission peak at 617.^[7] These results confirmed a diagnosis of CEP.

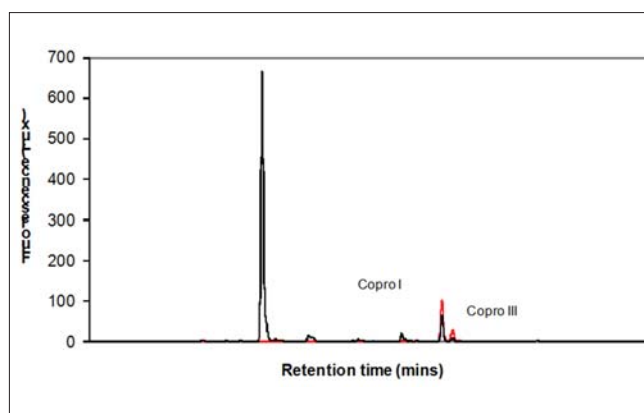


Figure 6: HPLC fractionation pattern of urine (blank trace) and fecal (red trace) porphyrin methyl esters. Uro I: uroporphyrin octamethyl ester isomer I, Copro I: coproporphyrin tetramethyl ester isomer I and Copro III: coproporphyrin tetramethyl ester isomer III.

Molecular genetic analysis of the UROS gene revealed the sequence variant c.217T>C (p.Cys73Arg) in exon 4 and c.683c>T (p.Thr228Met) in exon 10. These missense mutations have previously been described,^[8] where the patient had a moderate to severe phenotype.

Discussion

CEP has an estimated frequency of 1 in every 2 to 3 million people. As of 1997, about 130 cases had been reported.^[1] In Switzerland, only four cases of CEP from a total of 217 porphyrias of different types have been described.^[9] CEP affects males and females equally, and has no known predilection for any ethnic group.

Mutation analysis has shown a large variety of molecular lesions.^[10] Genotype/phenotype correlations have been demonstrated^[10] showing that the clinical severity of the anemia and cutaneous lesions is highly variable, ranging from mild to severe. Some patients die in early adult life and others in the neonatal period. The mutations found in our patient are relatively frequent in CEP. Cys73Arg occurs in approximately one-third of cases and Thr228Met in around 6% (Desnick and Astrin, 2002). When expressed in an *E. coli* system, these mutations have <1% of normal UROS activity.^[1] In case reports, a similar phenotype to that found in our patient has been reported, i.e., with severe photosensitivity and mild hemolytic anemia, but not transfusion-dependent.^[8]

The profound UROS deficiency^[1] leads to a lifelong overproduction of isomer I porphyrins which are deposited in many tissues causing light-sensitization and severe damage to skin. Blistering and scarring of exposed areas may lead to mutilating deformity. Hypertrichosis is sometimes severe.

Splenectomy, hypertransfusion, and orally administered drugs such as charcoal and cholestyramine, which binds porphyrins have also been used to treat CEP. Unfortunately, these classical treatments are unsatisfactory and do not effectively control the disease.

Allogeneic bone marrow transplantation (BMT) resulted in long-term biochemical and clinical effectiveness in severely affected patients. In the last decade, gene therapy with hematopoietic stem cells (HSCs) was shown to be curative in a number of diseases. So far, gene therapy for severe combined immunodeficiency diseases due to common γ chain (SCID-X1) ([MIM 300400]) or adenosine deaminase (SCID-ADA) ([MIM 102700]) deficiencies, Gaucher disease ([MIM 230800]), and chronic granulomatous disease (CGD) ([MIM 306400]) have been shown to be effective. Full correction of the disease phenotype and clinical benefit has been achieved in SCID-X1, SCID-ADA, and CGD.

In murine models, oncoretroviral and lentiviral vectors were used to successfully transduce HSCs, allowing full metabolic and phenotypic correction of both EPP and CEP mice.^[11,12] These results form the basis for gene therapy clinical trials in severe forms of EP.

In conclusion, we have described a 14-year-old girl with CEP, with defined UROS mutations and severe phenotype. BMT and gene treatment have been discussed with the parents as further treatment options.

References

1. Desnick RJ, Astrin KH. Congenital erythropoietic porphyria:

advances in pathogenesis and treatment. *Br J Haematol* 2002;117:779-95.

2. Gross U, Hoffmann GF, Doss MO. Erythropoietic and hepatic porphyrias. *J Inher Metab Dis* 2000;23:641-61.
3. Robert-Richard E, Moreau-Gaudry F, Lalanne M, Lamrissi-Garcia I, Cario-André M, Guyonnet-Dupérat V, et al. Effective Gene Therapy of Mice with Congenital Erythropoietic Porphyria Is Facilitated by a Survival Advantage of Corrected Erythroid Cells. *Am J Hum Genet* 2008;82:113-24.
4. Deacon AC, Elder GH. Frontline tests for the investigation of suspected porphyria. *J Clin Pathol* 2001;54:500-7.
5. Lockwood WH, Poulos V, Rossi E, Curnow DH. Rapid procedure for fecal porphyrin assay. *Clin Chem* 1985;31:1163-7.
6. Lim CK, Peters TJ. Urine and faecal porphyrin profiles by reverse-phase high-performance liquid chromatography in the porphyrias. *Clin Chim Acta* 1984;139:55-63.
7. Poh-Fitzpatrick MB. A plasma porphyrin fluorescence marker for variegate porphyria. *Arch Dermatol* 1980;116:543-7.
8. To-Figuras J, Bedenas C, Mascaro JM, Madrigal I, Merino A, Bastida P, et al. Study of the genotype-phenotype relationship in four cases of congenital erythropoietic porphyria. *Blood Cells Mol Dis* 2007;38:242-6.
9. Schneider-Yin X, Harms J, Minder EI. Porphyria in Switzerland, 15 years experience. *Swiss Med Wkly* 2009;139:198-206.
10. Ged C, Moreau-Gaudry F, Richard E, Robert-Richard E, de Verneuil H. Congenital erythropoietic porphyria: Mutation update and correlations between genotype and phenotype. *Cell Mol Biol (Noisy-le-grand)* 2009;55:53-60.
11. de Verneuil H, Robert-Richard E, Ged C, Mazurier F, Richard E, Moreau-Gaudry F. Successful gene therapy of mice with congenital erythropoietic porphyria. *Med Sci (Paris)* 2008;24:615-20.
12. Richard E, Robert-Richard E, Ged C, Moreau-Gaudry F, de Verneuil H. Erythropoietic porphyrias: Animal models and update in gene-based therapies. *Curr Gene Ther* 2008;8:76-86.

Cite this article as: Gucev Z, Slavevska N, Tasic V, Laban N, Pop-Jordanova N, Danilovski D, Woolf J, Cole D. Congenital erythropoietic porphyria with two mutations of the uroporphyrinogen III synthase gene (Cys73Arg, Thr228Met). *Indian J Hum Genet* 2011;17:104-7.

Source of Support: Nil, **Conflict of Interest:** None declared.