



# SARS-CoV-2 Infection Is Not Associated With Pediatric Appendicitis

Yike Jiang<sup>1</sup> , MD, PhD,\* Steven C. Mehl, MD,† Ella E. Hawes, BS,\* Allison S. Lino, MPH,\* Kristy L. Rialon, MD,‡ Kristy O. Murray, DVM, PhD,\*§ and Shannon E. Ronca<sup>1</sup> , PhD, MPH\*‡§

**Abstract:** Although case reports have suggested an association between severe acute respiratory distress syndrome coronavirus 2 and appendicitis, we found that the overall incidence of appendicitis was stable throughout the pandemic at our tertiary pediatric hospital. Furthermore, we did not find evidence of CoV2 infection in 9 appendicitis tissues. Therefore, we conclude that severe acute respiratory distress syndrome coronavirus 2 infection of the appendix is not a common etiologic cause of pediatric appendicitis

**Key Words:** appendicitis, COVID-19, SARS-CoV-2, epidemiology, viral infection, pediatrics

(*Pediatr Infect Dis J* 2022;41:e321–e323)

## INTRODUCTION

The impact of the severe acute respiratory distress syndrome coronavirus 2 (CoV2) pandemic on human health and disease has yet to be fully realized. While CoV2 is known to cause severe respiratory disease, the virus also has demonstrable enteric tropism. CoV2 fecal shedding persists longer than shedding from the nasopharynx and can be detectable in over 40% of patients with COVID-19.<sup>1</sup> Enterocytes not only express angiotensin converting enzyme 2, the receptor for CoV2, but they also express mucosa-specific serine proteases that promote viral entry.<sup>2</sup> These data readily explain the gastrointestinal symptoms that manifest in 1 in 5 adult patients with COVID-19. However, whether enteric infection with CoV2 leads to specific gastrointestinal pathology remains unclear.

Appendicitis is the most common indication for emergency surgery in childhood. Direct luminal obstruction (by fecalith and lymphoid hyperplasia, etc.) can cause appendicitis but is rarely identified.<sup>3</sup> Intraluminal bacterial overgrowth follows obstruction leading to ischemia, inflammation and eventual perforation. Less commonly, inflammation due to direct infection of the appendix has been reported with enteric pathogens, such as adenovirus, rubella virus and Epstein-Barr virus.<sup>4–6</sup> During the pandemic, several studies reported an increase in the severity of acute appendicitis cases and suggested an association with CoV2 infection.<sup>7,8</sup> Therefore, given the enteric tropism of CoV2 and accelerated global transmission, we

Accepted for publication April 15, 2022

From the \*Department of Pediatrics, Texas Children's Hospital and Baylor College of Medicine, Houston, Texas, †Department of Surgery, Texas Children's Hospital and Baylor College of Medicine, Houston, Texas, ‡Department of Microbiology and Immunology, Baylor College of Medicine, Houston, Texas, and §William T. Shearer Center for Human Immunobiology, Department of Pediatrics, Texas Children's Hospital, Houston, Texas

This study was supported by the William T. Shearer Center for Human Immunobiology at Texas Children's Hospital. This study was also supported by the Pediatrician-Scientist Pilot grant provided by Baylor College of Medicine.

The authors have no conflicts of interest to disclose.

Kristy O. Murray and Shannon E. Ronca are considered as co-senior authors.

Supplemental digital content is available for this article. Direct URL citations appear in the printed text and are provided in the HTML and PDF versions of this article on the journal's website ([www.pidj.com](http://www.pidj.com)).

Address for correspondence: Shannon Ronca, PhD, MPH, Department of Pediatrics, Baylor College of Medicine, 1102 Bates Ave Suite 310 Houston TX 77030. E-mail: [ronca@bcm.edu](mailto:ronca@bcm.edu)

Copyright © 2022 Wolters Kluwer Health, Inc. All rights reserved.

ISSN: 0891-3668/22/4108-e321

DOI: 10.1097/INF.00000000000003575

postulated that CoV2 infection of the appendix causes appendicitis. To test this, we collected epidemiologic data on pediatric appendicitis cases and examined appendicitis surgical samples for CoV2.

## METHODS

### Epidemiologic Data Collection

We retrospectively collected data on pediatric patients seen at Texas Children's Hospital with acute appendicitis between February 3rd, 2020, and December 13th, 2021. Acute appendicitis was defined by international classification of disease-10 codes K35, K36 and K37 with the omission of “typhlitis”, “chronic appendicitis” and “cecum rupture.” Complicated appendicitis was additionally defined by the inclusion of abscess, perforation or rupture. If duplicate medical record number (MRN) entries were present, the earliest encounter date was used, and the other entries were omitted. If multiple diagnoses existed for an MRN, the most severe or specific diagnosis was used. All patients at our institution are preoperatively surveillance tested with nasopharyngeal (NP) real-time polymerase chain reaction (RT-PCR) for CoV2. Community cases of CoV2 were extracted from publicly available databases curated by Harris County Public Health and Houston Health Department (<https://covid-harriscounty.hub.arcgis.com>). We used combined Harris County and City of Houston data from the “Epi Curve of Cases Over Time”, which was last accessed on December 9th, 2021.

### Appendicitis Surgical Sample Collection.

We preoperatively recruited 9 patients with positive NP CoV2 testing results and acute appendicitis between April 6th, 2021 and September 2nd, 2021. All participants provided informed written consent for their involvement in this study. Blood, rectal swabs sampling stool and appendix tissue samples were taken at the time of appendectomy, immediately processed, and stored at  $-80^{\circ}\text{C}$ . This study was approved by the Institutional Review Board at Baylor College of Medicine (H-48474).

### Live Co-culture

Surgical appendectomy tissues were homogenized with a metal bead using TissueLyser II (Qiagen) at a concentration of 200–500 mg per ml of in Eagle's Minimum Essential Medium. Appendicitis homogenate was then co-cultured with a loosely confluent monolayer of Vero E6 cells in the presence of penicillin, streptomycin and amphotericin. Cells were imaged daily by light microscopy for 3–21 days to look for cytopathic effect and monolayer integrity. Processing, culture and microscopy for the live co-culture experiments were performed at Biosafety Level-3.

### RNA Extraction

Homogenized tissue samples or fecal swabs were inactivated in 2X DNA/RNA Shield in a 1:1 ratio. DNA/RNA was extracted using the Quick DNA/RNA Pathogen MiniPrep extraction protocol (Zymo Research).

### RT-PCR

A 20  $\mu\text{L}$  reaction contained 5  $\mu\text{L}$  of RNA, 12.2  $\mu\text{L}$  of water, 1  $\mu\text{L}$  of TaqPath 1-Step Multiplex Master Mix (Thermo Fisher

Scientific), 0.8 μL of E-Sarbeco Forward Primer, 0.8 μL of E-Sarbeco Reverse Primer and 0.2 μL of E-Sarbeco Probe (primer and probe set detailed in Corman et al, 2020). Thermal cycling was performed at 25°C for 2 min, 55°C for 10 min, 95°C for 3 min, then 40 cycles of 95°C for 10 sec and 58°C for 30 sec. Reactions were run on the QuantStudio 3 or QuantStudio 5 (Thermo Fisher Scientific).

**ELISA**

Anti-CoV2 IgG in the serum was detected using the SCoV-2 Detect IgG enzyme linked immunoassay (InBios) according to manufacturer instructions (<https://inbios.com/scov-2-detect-igg-elisa-kit-2>).

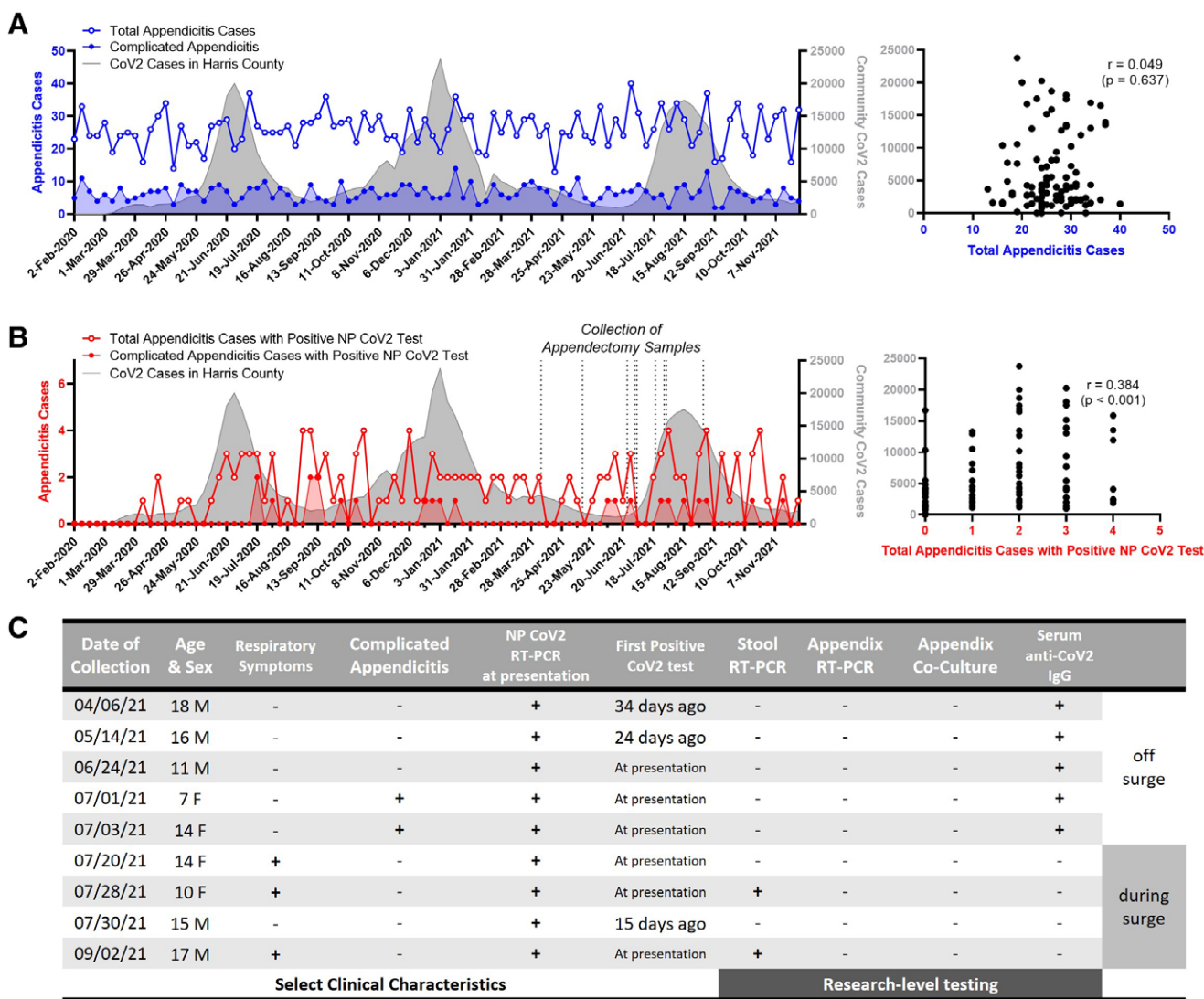
**Statistical Methods**

Epidemiologic data were analyzed using GraphPad Prism (version 9.3.1). The correlation between weekly cases of appendicitis and community CoV2 was computed using two-tailed Pearson correlation coefficients with a confidence interval of 95%.

**RESULTS**

**Total Appendicitis Cases did not Change with the CoV2 Pandemic**

First, we looked at total appendicitis cases presenting to our hospital during the pandemic (Fig. 1A) and found that neither total



**FIGURE 1.** Epidemiology of appendicitis at a Tertiary Pediatric Hospital. (A) Weekly total appendicitis cases (blue) and (B) weekly appendicitis cases who tested positive for CoV2 by NP swab (red) were graphed relative to community CoV2 cases in Harris County (gray). Blue and red shaded areas represent weekly numbers of complicated appendicitis cases. Correlations between appendicitis cases and community cases are shown on the right. (C) Table of clinical characteristics of patient cohort and virologic data of related biospecimens. Nine appendectomy samples with paired stool and serum were collected. CoV2 RT-PCR was performed on appendicitis tissue and stool. Live co-culture of appendicitis tissue with Vero cells was done to look for cytopathic effect. Anti-CoV2 IgG in the serum was also assessed. Retrospective chart review excluded prior CoV2 vaccination and reduced likelihood of re-infection as explanations for the seroconversion. Designation of “off surge” or “during surge” was made based on community cases in Fig. 1A. NP indicates nasopharyngeal.

appendicitis nor complicated appendicitis cases correlated with CoV2 cases in the community. These results suggest that the CoV2 pandemic did not affect overall appendicitis incidence or severity.

### Appendicitis Cases with Positive Nasopharyngeal CoV2 Tests Correlate with Community CoV2 Cases

We compared appendicitis cases who were positive by NP RT-PCR testing for CoV2 within a day of appendectomy and community cases of CoV2 (Fig. 1B), and we found a positive and significant correlation ( $P < 0.001$ ). Complicated appendicitis cases with positive CoV2 testing also correlated with community cases ( $P = 0.047$ ). These results suggest that either CoV2 plays a role in the pathophysiology of appendicitis or that positive CoV2 testing was an incidental finding that reflected community transmission.

### No Virologic Evidence of CoV2 Infection in Appendiceal tissue

We collected blood, stool and surgical appendectomy tissue from 9 patients with appendicitis and positive CoV2 NP testing (Fig. 1C). Both RT-PCR and live co-culture of the appendiceal tissue were negative for viral genome and cytopathic effect, signifying that CoV2 was absent in the appendix. We also found that 2/9 (22%) of the stool samples were positive for CoV2 by RT-PCR and that 5/9 (44%) of the serum were positive for CoV2 IgG.

## DISCUSSION

Our study aimed to investigate the relationship between CoV2 infection and acute pediatric appendicitis, specifically whether CoV2 infection of the appendix could cause appendicitis. This study was limited by the small cohort size for biospecimen sampling. We assumed that patients who tested positive for CoV2 via NP testing would be more likely to have gastrointestinal infection with CoV2 and potential involvement of their appendix. Thus, we were also limited by only biosampling patients who were positive for CoV2 via NP testing.

A prior study described appendicitis cases with positive CoV2 testing peaking 2 weeks after the CoV2 community surge, leading them to postulate a postinfectious role for CoV2 in appendicitis.<sup>10</sup> In our data, we also see a peak of appendicitis cases with positive NP CoV2 after the first wave of CoV2 in the community. However, this pattern does not recur after the second or third CoV2 waves. While our data may support this theory since 5/9 (56%) of our cohort had developed anti-CoV2 IgG, we interpreted the anti-CoV2 IgG data differently. Whether a patient had anti-CoV2 IgG was highly associated with the time of collection and community case counts at that time. The samples collected between April 6th and July 3rd, 2021 occurred between the second and third wave of CoV2 in the community. These samples collected “off surge” were 5/5 positive for anti-CoV2 IgG. Given that community transmission is relatively low during this time, we speculate that these positive NP tests represent nonacute infection since respiratory CoV2 RT-PCR tests can remain positive for 11 weeks after symptom onset.<sup>11</sup> Retrospective chart review excluded prior CoV2 vaccination and reduced likelihood of re-infection as explanations for the seroconversion. Comparatively, the samples collected between July 20th and September 2nd, 2021 were collected during the Delta variant surge, and 0 of 4 patients had anti-CoV2 IgG. Given that community transmission is relatively high during the surge, it stands to reason that these positive NP CoV2 tests reflect acute infection. This is further supported by 2 of 4 patients having positive stool RT-PCR results and 3 of 4 patients having respiratory symptoms during the surge. Therefore, the seroconversion percentage in our

cohort was determined by when the patient samples were collected. Regardless of acute or nonacute CoV2 respiratory infection, we did not find evidence of CoV2 infection in appendix tissue. If appendicitis is a postinfectious manifestation of CoV2 infection, the current epidemiologic and clinical data are insufficient to support this hypothesis.

While there has been speculation and limited case reports suggesting an association between appendicitis and CoV2 infections, our study did not demonstrate CoV2 infection in appendicitis tissue in 9 pediatric patients. To date, 4 case reports have attempted to detect CoV2 in surgical samples from appendicitis cases (Table, Supplemental Digital Content 1, <http://links.lww.com/INF/E736>), and CoV2 in the appendix was detected in 2 of 3 cases, including 1 case in a child.<sup>12–14</sup> The fourth case did not directly test appendix tissue but did test peritoneal washings from an appendicitis case which was found to be negative.<sup>15</sup> Our study demonstrated that the total number and complexity of appendicitis cases did not change during the pandemic. Therefore, while CoV2 infection of the appendix may be possible, our study suggests that it is rare and does not impact overall incidence of appendicitis. Altogether, we conclude that there is no association between CoV2 infection and pediatric appendicitis.

## REFERENCES

- Cheung KS, Hung IFN, Chan PPY, et al. Gastrointestinal manifestations of SARS-CoV-2 infection and virus load in fecal samples from a Hong Kong Cohort: systematic review and meta-analysis. *Gastroenterology*. 2020;159:81–95.
- Zang R, Gomez Castro MF, McCune BT, et al. TMPRSS2 and TMPRSS4 promote SARS-CoV-2 infection of human small intestinal enterocytes. *Sci Immunol*. 2020;5:eabc3582.
- Carr NJ. The pathology of acute appendicitis. *Ann Diagn Pathol*. 2000;4:46–58.
- Lopez-Navidad A, Domingo P, Cadafalch J, et al. Acute appendicitis complicating infectious mononucleosis: case report and review. *Rev Infect Dis*. 1990;12:297–302.
- Porter HJ, Padfield CJ, Peres LC, et al. Adenovirus and intranuclear inclusions in appendices in intussusception. *J Clin Pathol*. 1993;46:154–158.
- Paik SY, Oh JT, Choi YJ, et al. Measles-related appendicitis. *Arch Pathol Lab Med*. 2002;126:82–84.
- Angeramo CA, Dreifuss NH, Schlottmann F, et al. More severe presentations of acute appendicitis during COVID-19. *J Gastrointest Surg*. 2021;25:1902–1904.
- Meyer JS, Robinson G, Moonah S, et al. Acute appendicitis in four children with SARS-CoV-2 infection. *J Pediatr Surg Case Rep*. 2021;64:101734.
- Corman VM, Landt O, Kaiser M, et al. Detection of 2019 novel coronavirus (2019-nCoV) by real-time RT-PCR. *Eurosurveillance*. 2020;25:2000045.
- Malhotra A, Sturgill M, Whitley-Williams P, et al. Pediatric COVID-19 and Appendicitis: A Gut Reaction to SARS-CoV-2? *Pediatr Infect Dis J*. 2021;40:e49–e55.
- Wang W, Zhou Y, Zhong L, et al. RAS-associated Autoimmune Leukoproliferative disease (RALD) manifested with early-onset SLE-like syndrome: a case series of RALD in Chinese children. *Pediatr Rheumatol*. 2019;17.
- Ahmad S, Ahmed RN, Jani P, et al. SARS-CoV-2 isolation from an appendix. *J Surg Case Rep*. 2020;2020:rjaa245.
- Serra AM, Ventura AMC, Xavier LF, et al. SARS-CoV-2 identification in an acute appendicitis case: acute abdomen as manifestation of Multisystem Inflammatory Syndrome in a child with COVID-19. *Braz J Infect Dis*. 2021;25:101651.
- Wolf B, Pietsch C, Radosa M-P, et al. No SARS-CoV-2 detected in the vermiform appendix of a COVID-19 patient with appendicitis: a case report. 2020.
- Ngaserin SH, Koh FH, Ong BC, et al. COVID-19 not detected in peritoneal fluid: a case of laparoscopic appendectomy for acute appendicitis in a COVID-19-infected patient. *Langenbecks Arch Surg*. 2020;405:353–355.