

Received: 2016.02.09
Accepted: 2016.05.05
Published: 2016.07.26

ISSN 1941-5923
© Am J Case Rep, 2016; 17: 535-537
DOI: 10.12659/AJCR.897989

Isolated Unilateral Tongue Atrophy: A Possible Late Complication of Juxta Cephalic Radiation Therapy

Authors' Contribution:
Study Design A
Data Collection B
Statistical Analysis C
Data Interpretation D
Manuscript Preparation E
Literature Search F
Funds Collection G

ABCDEF 1 **Saeed A. Alqahtani**
CDE 2 **Caroline Agha**
DEF 2 **Ted Rothstein**

1 National Institute of Neurological Disorders and Stroke (NINDS), National Institutes of Health (NIH), Bethesda, MD, U.S.A.
2 Department of Neurology, The School of Medicine and Health Sciences, The George Washington University, Washington, DC, U.S.A.

Corresponding Author: Saeed A. Alqahtani, e-mail: saeedqanea@hotmail.com
Conflict of interest: None declared

Patient: **Male, 51**
Final Diagnosis: **Radiation therapy induced unilateral tongue atrophy**
Symptoms: —
Medication: —
Clinical Procedure: **EMG**
Specialty: **Neurology**

Objective: **Rare disease**

Background: Isolated unilateral hypoglossal nerve injury is extremely rare. It may be caused by radiation therapy targeting neoplasms of the cephalic region.

Case Report: A 51-year-old man with synovial sarcoma of the left upper arm status post extensive radiation therapy in 1980 presented in late 2014 with gradual onset of speech difficulty and difficulty moving his tongue for a couple of weeks. Neurological examination revealed isolated left-sided unilateral tongue atrophy. Postradiation residual extensive cicatrix with erythema over the whole left upper extremity extending to the neck on the affected side was noticed. On head magnetic resonance imaging (MRI) before and after administration of gadolinium, he was found to have asymmetrically fatty striations, atrophy, and fibrosis in the left tongue consistent with radiation toxicity. The patient's tongue weakness persisted without improvement.

Conclusions: The diagnosis of unilateral hypoglossal nerve injury is usually difficult. Detailed neurological examinations and thorough investigations including head MRI are very helpful. Previous exposure to radiation therapy is a potential cause of hypoglossal nerve injury. To our knowledge, this is the first case report that presents isolated unilateral tongue atrophy as a late complication of juxta cephalic radiation therapy.

MeSH Keywords: **Abnormalities, Radiation-Induced • Hypoglossal Nerve • Magnetic Resonance Imaging**

Full-text PDF: <http://www.amjcaserep.com/abstract/index/idArt/897989>



768



X



X



XX



Background

Isolated unilateral hypoglossal nerve injury is extremely rare. It may be caused by radiation therapy targeting neoplasms of the cephalic region. However, juxta cephalic radiation therapy can cause hypoglossal nerve palsy. In this report, we present a case of isolated unilateral tongue atrophy possibly related to juxta cephalic radiation exposure.

Case Report

A 51-year-old man presented in late 2014 to the neurology clinic for follow-up after being evaluated in the emergency department multiple times for speech difficulty with unremarkable workup including head magnetic resonance imaging (MRI) and computed tomography angiogram of the head and neck. He complained of a gradual onset of difficulty speaking and articulating words over a period of a couple of weeks. His symptoms worsened slowly and progressively, and he became unable to touch his left inner cheek with his tongue. Foods would get stuck in the left side of his mouth, and he had to manually dislodge foods after meals. He denied drooling or difficulty opening his mouth or jaw. His wife noted his slurring of speech, difficulty pronouncing certain words, and having trouble saying what he wanted to say correctly and consistently, although she was able to understand him. He was able to understand her without difficulty. Review of systems was normal, and there was no family history of neurological disease or similar presentation. His past medical history was remarkable for hypertension and synovial sarcoma of the left upper arm status post surgical resection, chemotherapy, and radiation therapy in 1980 with an unknown dose of radiation therapy. Neurological examination revealed mild difficulty expressing certain sounds and words with slurring speech.

Inspection of the tongue disclosed left-sided unilateral atrophy and protrusion to the left (Figure 1). A few fasciculations were present along the lateral aspect of the affected side. There was no facial weakness or sensory impairment, and the palate elevated symmetrically, his uvula elevated in the midline, and the gag reflex was present. There was no weakness of sternocleidomastoid or trapezius muscles. There was a postradiation residual extensive cicatrix with erythema over the whole left upper extremity extending to the base and lateral aspect of the neck on the affected side. Dedicated high-resolution MRI of the neck soft tissue and brain before and after administration of gadolinium and a head and neck magnetic resonance angiogram were obtained. The imaging findings were unremarkable except for asymmetrically prominent fatty striations, atrophy, and fibrosis in the left tongue (Figure 2). No mass lesions were seen within the tongue or in the hypoglossal foramen. Needle electromyography (EMG) of the tongue showed

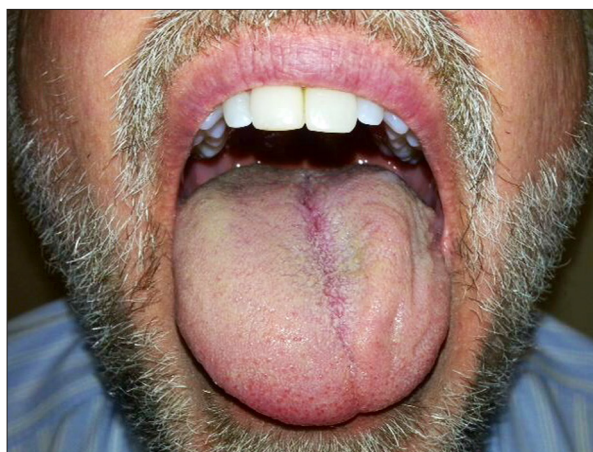


Figure 1. Note the left unilateral tongue atrophy with deviation to left.

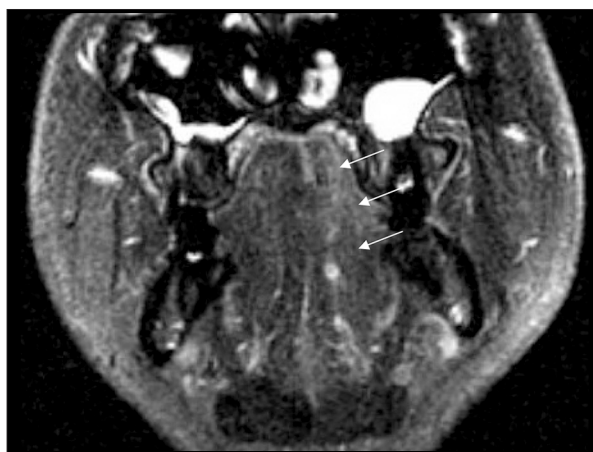

Figure 2. Coronal T2-weighted image showing asymmetrical prominent fatty striations and fatty atrophy on the left side of the tongue due to radiation toxicity (arrows).

denervation changes confined to the muscles supplied by the left hypoglossal nerve. There was no evidence of widespread motor neuron disease or myokymia, and EMG findings in the right side of the tongue and cervical muscles were normal. The patient's slurred speech and dysarthria have persisted, and he continued to follow up with a speech therapist.

Discussion

The hypoglossal nerve (cranial nerve XII) innervates the musculature of the tongue. Should the hypoglossal nerve be damaged, denervation atrophy of the tongue can result. Radiation-induced hypoglossal nerve palsy is very rare. There are reports of nerve injury when radiation therapy is targeted to neoplasms of the cephalic region (head and neck). Herein, we report a case of an isolated unilateral hypoglossal nerve palsy associated with juxta cephalic tumor irradiation of unknown

dose and duration. It would appear that the patient received extensive radiation given the degree of fibrosis and postradiation cicatrix ipsilateral to the affected side.

Fortunately, technical progress in radiation therapy with newer protocols has reduced the incidence of cranial nerve palsy in the last decade [1]. As a result, there are very few cases reported of hypoglossal nerve palsy after definitive radiotherapy. An extended latent period has been noticed clinically, resulting in cranial nerve palsies that can appear several years after radiotherapy. Unfortunately, most of the cases with cranial nerve involvement are progressive and irreversible [2–5]. The pathological mechanisms include direct nerve damage by radiation toxicity and extensive perineural fibrosis associated with postradiation changes, as seen in our case. Fibrosis may lead to ischemia of vessels supplying the nerves. Focal radiation and avoiding excess radiation to muscle and soft tissue

are recommended [4]. In general, the diagnosis of isolated hypoglossal nerve palsy remains difficult to establish.

Conclusions

Radiation therapy can cause cranial nerve palsy with variable late onset and manifestation. Isolated hypoglossal nerve palsy may appear years after exposure to radiation therapy. It is important to understand that such a diagnosis can be very challenging, and the link with previous exposure to radiation is usually difficult to establish.

Conflict of interest disclosures

None reported.

References:

1. Parsons JT, Bova F, Fitzgerald C et al: Radiation optic neuropathy after megavoltage external-beam irradiation: Analysis of time – dose factors. *Int J Radiat Oncol Biol Phys*, 1994; 30: 755–63
2. Cheng VS, Schultz MD: Unilateral hypoglossal nerve atrophy as a late complication of radiation therapy of head and neck carcinoma: A report of four cases and a review of the literature on peripheral and cranial nerve damages after radiation therapy. *Cancer*, 1975; 35(6): 1537–44
3. Kong L, Lu JJ, Liss AL et al: Radiation-induced cranial nerve palsy: A cross sectional study of nasopharyngeal cancer patients after definitive radiotherapy. *Int J Radiat Oncol Biol Phys*, 2011; 79(5): 1421–27
4. Lin YS, Jen YM, Lin JC: Radiation-induced CNP in patients with nasopharyngeal carcinoma. *Cancer*, 2002; 95: 404–9
5. Boban M, Brinar VV, Habek M et al: Isolated hypoglossal nerve palsy: A diagnostic challenge. *Eur Neurol*, 2007; 58(3): 177–81